

Study Effect Of Omega 3 Some Histopathological Changes In The Knee Joint of Juvenile Rats That Treated With Levofloxacin By Lactation

دراسة تأثير استخدام زيت السمك على بعض التغيرات المرضية النسيجية في مفصل الركبة للجرذان الرضعية المعالجة بمضاد الليفوفلوكساسين بواسطة الرضاعة

Assit.Lec .Al-Jebori Mohammed Jassim J.

Physiology & Pharmacology Dep.- Veterinary Medicine College /Kerbala University

Abstract

This study included the in to ten lactating rats and adapted then in similar environmental condition and divided two groups 6 lactating rats for drainage and four rats for control group , then they were drained after they were parturated with levofloxacin 500 mg /ml per a day for ten days according to body weight as a therapeutic dose. After the final dosing the blood were collected and the half of juvenile rats were scarified for histopathological study of knee joint cartilages. The results showed the presence of fibrosis with degenerative changes in epiphyseal cartilages growth plate with shrunken chondrocytes in comparative with control group. The last part of experiment the treated (6 lactating rats) were divided two groups, 3 lactating with omega 3 for ten days and three lactating leaved with out treated , the treated group with omega 3 showed regeneration of chondrocytes and less fibrosis in comparative with untreated group by omega 3 .

الخلاصة

اشتملت الدراسة على أخذ عشرة أنثى جرذان حوامل وبعد تطبيعها لظروف مناسبة ومتساوية و تم فصلها الى ثلاثة مجاميع مجموعة سيطرة 4 اناث ومجموعتين ضمت كل منهما 3 اناث مرضعات تم تجريب مجموعتين بعد ولادتها بأسبوع بمضاد الليفوفلوكساسين 500 ملغم/مل في حين جرعت المجموعة الثالثة بالماء المقطر والتي تعتبر مجموعة سيطرة وأعطيت الجرعة حسب أوزان الجرذان لجرعة واحدة يوميا كجرعة علاجية و بعد عشرة أيام تم سحب الدم وقتل نصف الجرذان الرضعية ودراسة التأثيرات على غضاريف مفصل الركبة وأظهرت النتائج وجود تليفات وتنكسات في الغضاريف و انكماش الخلايا الغضروفية بالمقارنة بمجموعة السيطرة. اما المجاميع المتبقية فقد تم فصل المجموعة المعالجة بمادة الليفوفلوكساسين الى جزئين كل جزء يضم 3 اناث مرضعات ، جزء عولج بمادة زيت السمك في حين ترك الجزء الاخر بدون علاج لمدة عشرة ايام بعد ذلك قتلت الجرذان الرضعية لكل المجاميع واجري التقطيع النسيجي لمفصل الركبة واطهرت المجموعة المعالجة بزيت السمك تغيرات جيدة مثل اختفاء التليف والتكس مقارنة بالمجموعة غير المعالجة بزيت السمك.

Introduction

In the last few years, there has been increasing pressure to use fluoroquinolones in paediatric patients, since these antibiotics offer the advantage of an oral treatment regimen on an out-patient basis. However, even although this class of antibiotics generally remains well-tolerated, the restriction of fluoroquinolone use in children on a compassionate basis, which derives from their potential to cause cartilage toxicity(1)

Juvenile articular cartilage consists of three distinct zones of chondrocytes with a characteristic regular arrangement inside a basophilic articular matrix. The superficial zone consists of tangentially flattened chondrocytes. The intermediate zone has radially arranged chondrocytes and the deep zone has hypertrophied chondrocytes inside lacunae(2)

The epiphyseal growth plate cartilage consists of four distinct zones; reserve zone (Rz) formed of chondrocytes arranged singly or in small clusters surrounded by a large amount of moderately basophilic stained matrix The proliferative cell zone (Pz) formed of chondrocytes which undergo successive mitotic divisions to form the columns of chondrocytes separated by strongly basophilic

stained matrix rich in acid proteoglycans The hypertrophic zone (Hz), where the cells undergo hypertrophy, become vacuolated and lose their ability to divide with calcification of the matrix. The mineralized Hz adjacent to the metaphysis gets partially resorbed by the chondroclasts forming the mineralized calcified zone (Mz), which constitutes the scaffold for the deposition of metaphyseal trabecular bone(3).

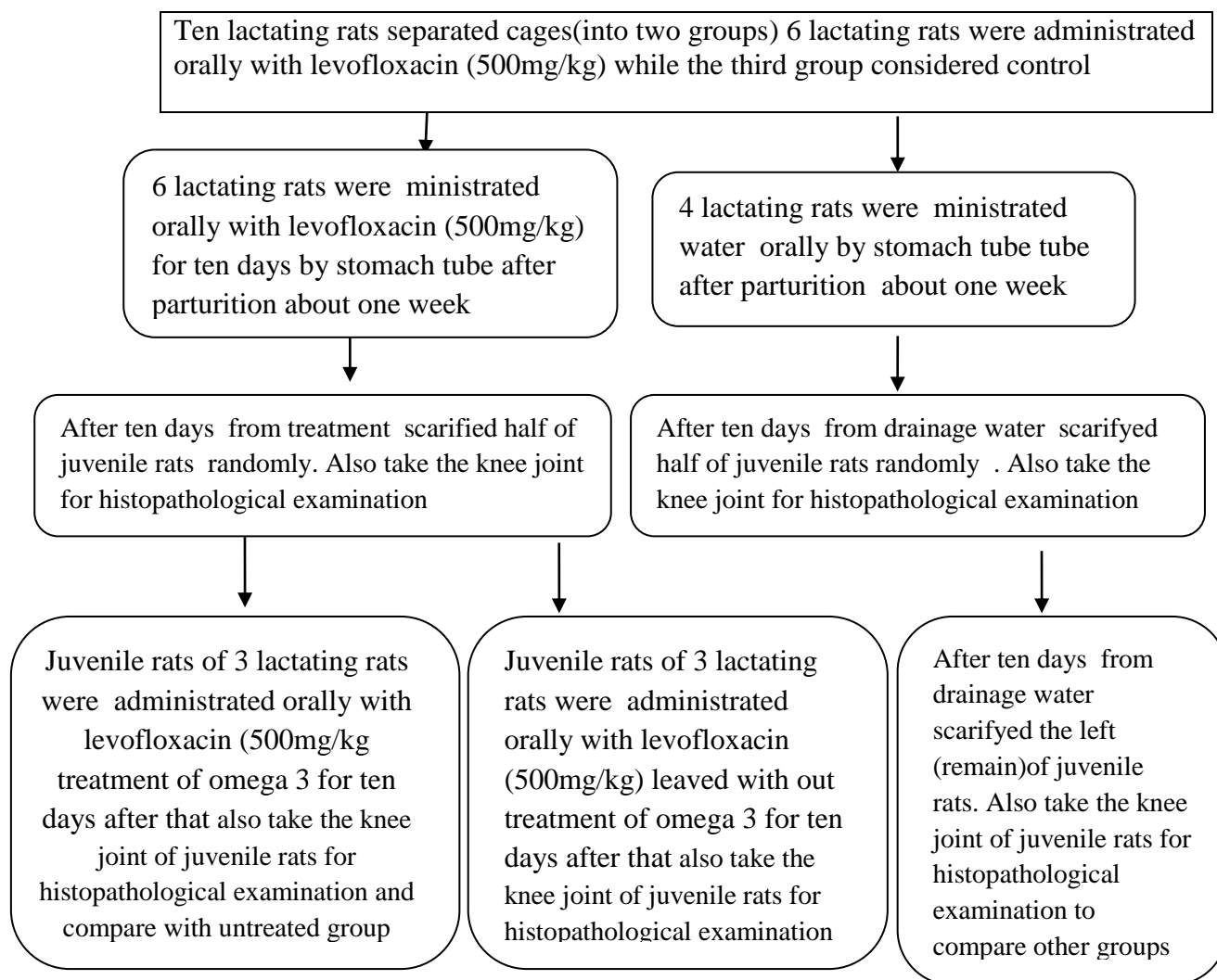
Quinolones possess favorable antibacterial activity and are often used as anti-infective agents in adults. However, they are contraindicated in children and adolescents because of their damaging effect on weight-bearing joints in juvenile animals. In addition, they possess a tendotoxic potential(4)

Although quinolone antibiotics are extensively utilized as an antimicrobial chemotherapy, they are only prescribed to pediatric patients for treatment of life threatening diseases such as cystic fibrosis, chronic suppurative otitis media complicated urinary tract infections and enteritis caused by invasive multidrug-resistant pathogens(5). Another study reported that levofloxacin inhibited glycosaminoglycan synthesis initially and DNA synthesis and mitochondrial function secondarily at actual arthropathic concentrations in cultured rabbit chondrocytes but that these changes were reversible and not enough to kill the cells (6) . The aim of this study refer to ability omega3 to repair degenerative cartilage of knee joint of juvenile rats affecting by levofloxacin through lactation .

Materials and methods

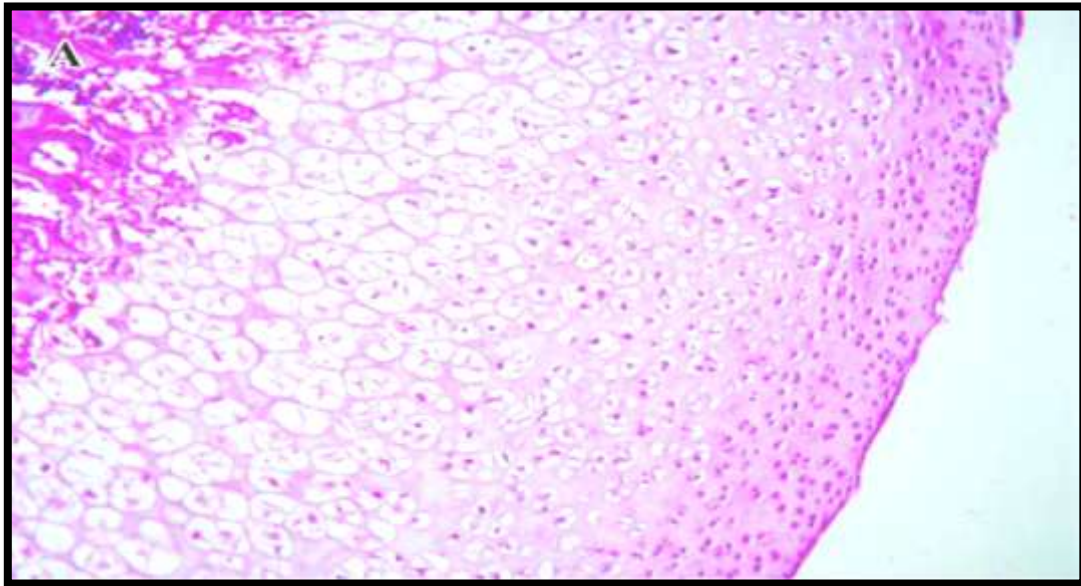
Ten lactating rats were adapted in the animal house in separated cages(into three groups) under similar environmental conditions , 2 groups were administrated orally with levofloxacin (500mg/kg) according weighted of rats once daily for ten days ,while the third group considered control. After the final dosing the immature (juvenile) rats randomly taken from treated and control groups were collected & left half of juvenile for complete the experiment ,blood were withdrawn and collected from animals (2ml/animal) for the biochemical analysis for measuring creatinephosphocinase and then were killed ,the knee joint was removed ,fixed in 10% formalin ,and stored .cartilage was obtained from the knee join, the joint samples were decalcified and embedded in paraffin ,serially sectioned in a sagittal plane at 8µm and routinely-stained with hematoxyln and eosine (H&E) four tissue section were used randomly for the histopathological examination for one animal .the last part of the experiment the leaved lactating rats , take 3 lactating rats treated omega 3 for ten days and leaved anther three lactating with out treatment for ten days also , and then were scarified immature (juvenile) rats for all groups ,the knee joint was removed ,fixed in 10% formalin ,and stored .cartilage was obtained from the knee join, the joint samples were decalcified and embedded in paraffin ,serially sectioned in a sagittal plane at 8µm and routinely-stained with hematoxyln and eosine (H&E) for the histopathological examination after then compare among groups .

Figure (1) explain experimental design

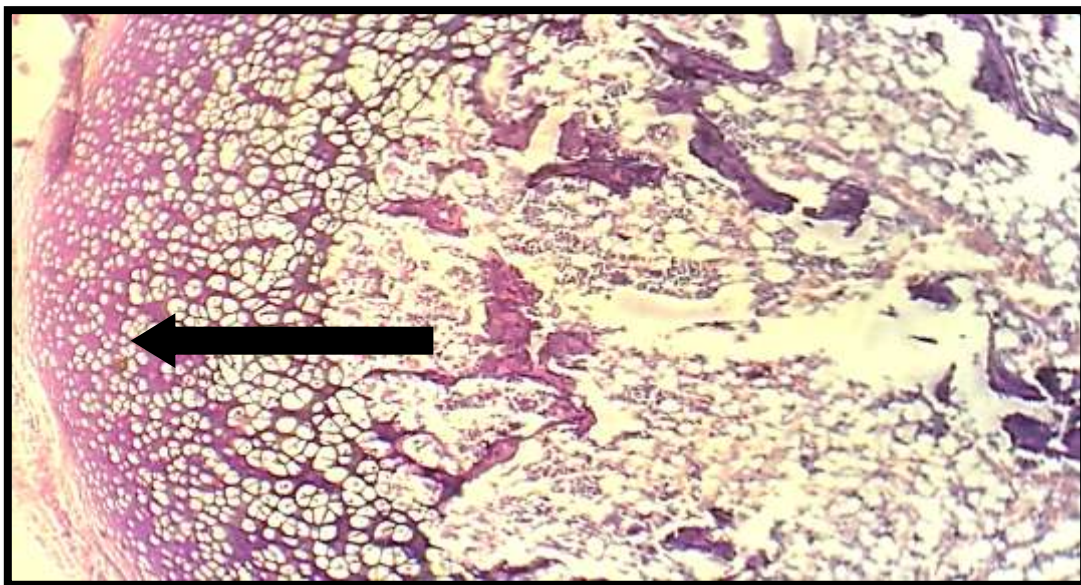


Results

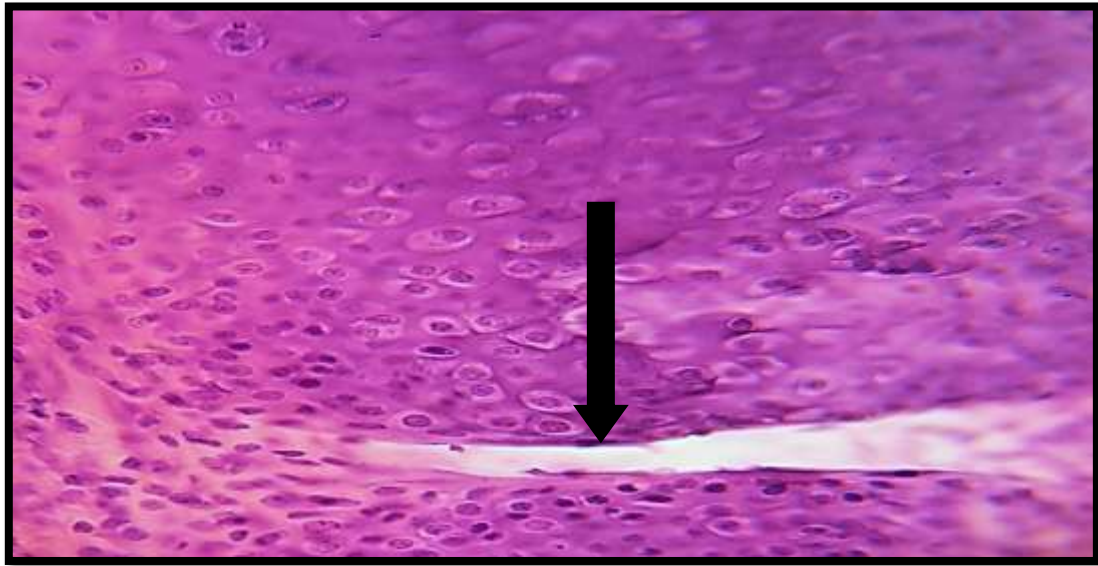
After the oral administration of levofloxacin to lactating rats (6 rats) for ten days , the juvenile rats showed changes in their behavior include depression,loss of appetite,weakness and swelling of knee joint of treated groups in compare with control group ,and dead of three juvenile rats from two groups that were treated with levofloxacin and after final dosing administration the half juvenile rats scarified , after that histopathological examination of the knee joints of the juvenile rats from treated groups showed the knee epiphyseal growth plate cartilage revealed decrease in thickness with loss of chondrocyte as compared with control figure(2&3). And also showed the articular cartilage revealed some collagen fibers running into clefts between chondrocyte columns figure(4). And also showed irregularity of articular surface it also revealed cavity formation surrounding by shrunken chondrocyte with pyknotic nuclei figure(5). After that's the half of treated group (3 lactating rats) were drainage by omega 3 and then the other treated group left with out drainage omega 3 for ten days also after that scarified all groups and removed knee joints of the juvenile rats and then done histopathological examination, the group drainage omega 3 showed smooth surfaces and regular staining affinity of the articular matrix and around the chondrocytes with decreased cavities between chondrocytes figure (7) ,when the group with out drainage omega 3 showed decreased staining affinity of the articular matrix and around the chondrocytes figure (6).



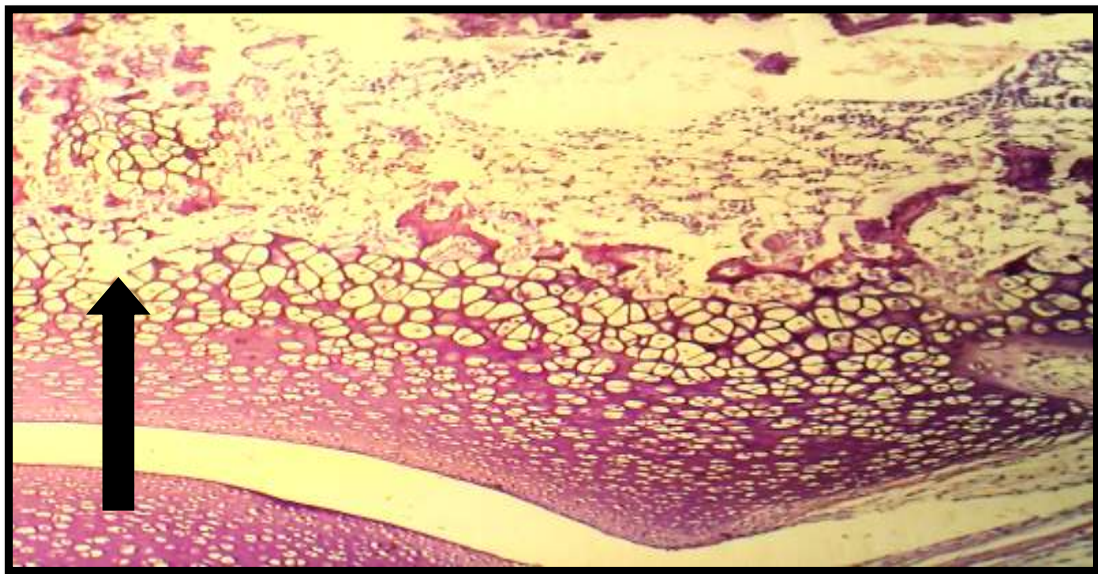
Fig(2) Normal histological section of articular cartilage of knee joint of control rat showed the normal thickness of epiphyseal plate (H&E 40x) .



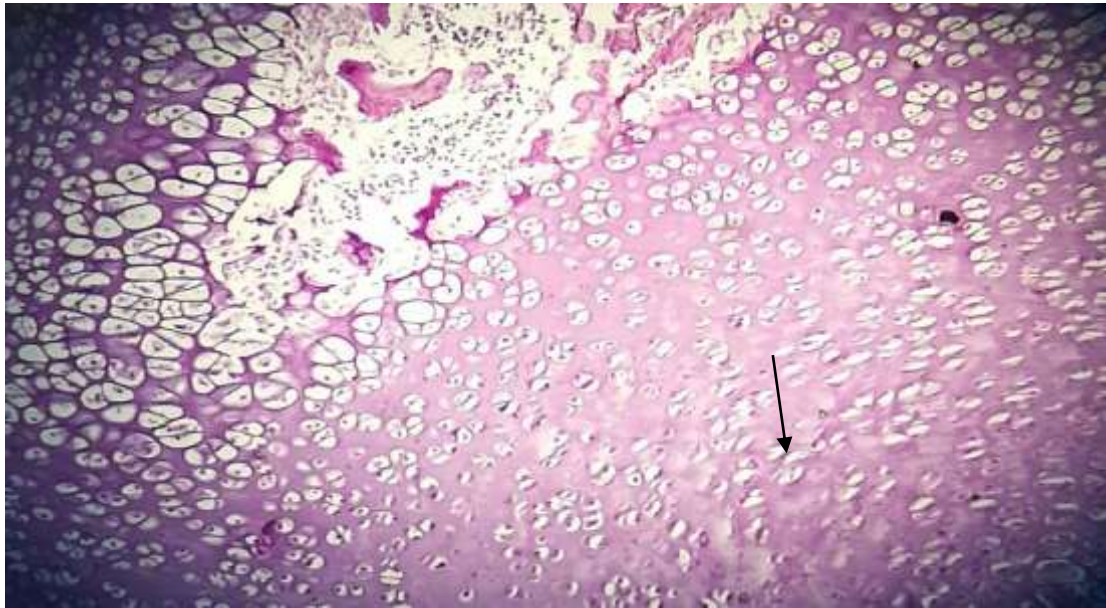
Fig(3) Histological section of articular cartilage of knee joint showed the decrease of thickness of articular surface of juvenile rat from levofloxacin treated group (H&E 40 x) (←→) .



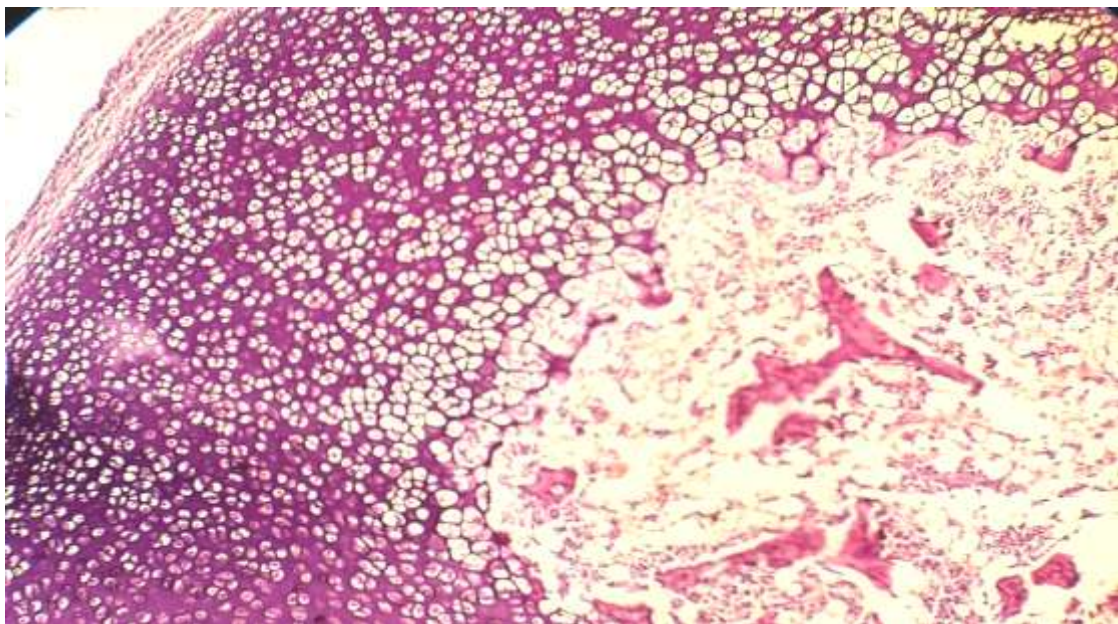
Fig(4)Histological section of articular cartilage of knee joint showed appearance of some collagen fibers covering surface of articular cartilage and running into clefts between chondrocytes (juvenile rat from levofloxacin treated group) (H&E 40x) ↓ .



Fig(5) Histological section of articular cartilage of knee joint showed cavities between shrunken chondrocytes (juvenile rat from levofloxacin treated group)(H&E 40x) ↑ .



Fig(6) Histological section of articular cartilage of knee joint showed decreased staining affinity of the articular matrix and around the chondrocytes (juvenile rat from levofloxacin treated group)
↓(H&E 40x)



Fig(7) Histological section of articular cartilage of knee joint showed smooth surfaces and regular staining affinity of the articular matrix and around the chondrocytes with decreased cavities between chondrocytes (juvenile rat from Omega 3 treated group) (H&E 40x).

DISCUSSION

levofloxacin is one of the most commonly used antibiotics for different kinds of infections. However, it is contraindicated in pregnancy and children due to its adverse effects such as hepatotoxicity, nephrotoxicity and damage of the growing cartilage in young animals. Juveniles are especially sensitive to quinolones with affection of the articular cartilage and/or epiphyseal growth plate, depending on the developmental stage(7).reported that chondrocytes located in the middle zone have the largest synthesizing capacity, where mitosis can be seen in growing cartilage. They clarified that these cells were sensitive to the DNA gyrase inhibitory effect of quinolones resulting

in chondrocyte degeneration and cavity formation(8,9). Coinciding with these results other authors(10,11)found that, single high oral dose and multiple low doses of levofloxacin were chondrotoxic in juvenile rats inducing scars and erosions of the joint surface .Furthermore some researchers(12,13)observed that levofloxacin induced cartilage damage in experimental animals when administered during certain developmental stages via changes of the cytoskeletal morphology. They attributed levofloxacin induced articular damage to the formation of levofloxacin-chelate complexes, which possess the potential to induce a deficiency of the functionally available magnesium resulting in cytoskeletal changes. Thus, the fluoroquinolone which has a low affinity for magnesium might be the least chondrotoxicone(12,14) On the same line, other authors(15)stated that magnesium deficiency could induce arthro-pathogenic effects with cartilage lesions identical to that of quinolones in juvenile rats.In this work it was noticed that levofloxacin-treated group showed appearance of some collagen fibers covering the surface of the articular cartilage or surrounding the cavities as well as running into the clefts between the chondrocyte columns of the epiphyseal plate cartilage. Similar findings were previously reported by other workers(7)who observed some collagen fibers oriented parallel to the joint surface, adjacent to the cavities or running perpendicularly into them with aggregation of collagen fibers in some of the severely compressed cases. Another study(16)revealed an increased number of fibroblasts with collagen deposition in the matrix of synovial membranes and tendon sheaths suggesting that quinolones have toxic potentials in the muscle, tendon and synovial membrane rather than the articular cartilage. between the chondrocyte columns of the epiphyseal plate cartilage. it was observed that the lesion of the articular as well as the epiphyseal growth plate cartilages did not cleared, but shrunken chondrocytes were observed with a significant diminution of the articular cartilage thickness indicating irreversibility of the lesion under these experimental conditions. These results were consistent with previous workers who found that ofloxacin-induced dose dependant arthropathy that was irreversible in juveniles(17). Irreversible chondrotoxicity of fluoroquinolones in pediatric patients provokes an urgent clinical question for identifying chondoprotective agents. Hence, this work aimed to study the possible protective role of Omega -3 against levofloxacin chondrotoxicity. Addition of Omega -3 in the current work revealed favorable results, where the articular cartilage of knee joint preserved its smooth articular surface and the characteristic well defined three zones of chondrocytes.(18) Moreover, concomitant administration of Omega -3 with levofloxacin in this experimental study provided a better histological picture of the growing epiphyseal plate, which was confirmed by a significant increase of the growing epiphyseal plate thickness as compared to levofloxacin alone. These results were in agreement with other workers .(19)

Recently, Baker et al (20)reported an investigation into relationships between plasma levels of long chain omega-6 (n-6) and omega-3 (n-3) fatty acids and MRI evidence of synovitis in the knees of patients with OA enrolled in the Multicentre Osteoarthritis Study (MOST). The results of the study by Baker and colleagues(20) suggest that availability of arachidonic acid for production of inflammatory eicosanoids could be a predisposing factor for synovitis in early OA. A reciprocal relation ship exists between the concentrations of long chain omega-3 fatty acids and plasma and tissue levels of arachidonic acid.

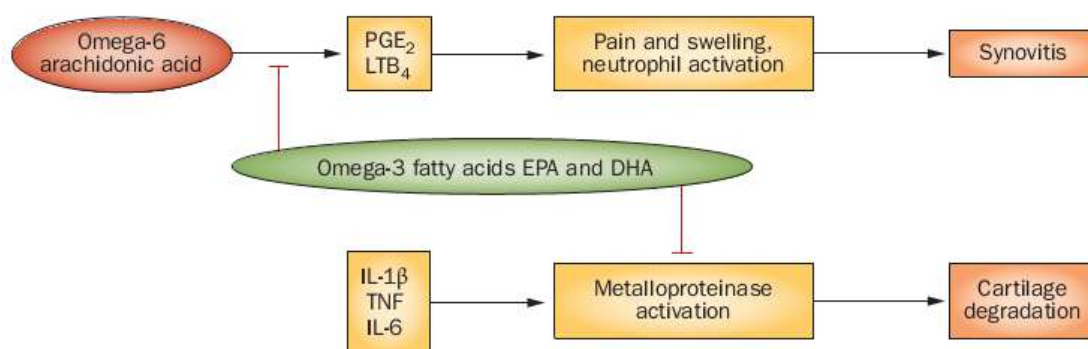


Figure (8)Potential protective actions of omega-3 fats in OA.(21)

The omega-3 fats in dietary fish oil EPA and DHA, are homologues of arachidonic acid, the omega-6 fatty acid precursor of proinflammatory prostaglandins and leukotrienes such as PGE 2 and LTB4. Competitive inhibition of arachidonic acid metabolism by EPA and DHA could reduce inflammation, pain and synovitis. EPA and DHA suppress chondrocyte metalloproteinases production *in vitro* and dietary fish oil has a protective effect on cartilage and subchondral bone in animal models of OA. (22) (23).

These results are compatible with our results when we find the effects of long chain omega-3 fatty acids *in vitro* and in animal models of OA provide mechanism-based support for undertaking human studies. For example, EPA and DHA reduced expression of degradative enzymes and inflammatory cytokines in an *in vitro* cartilage model of OA.

References

- 1-Cuzzolin L, Fanos V. (2002). Safety of fluoroquinolones in paediatrics. *Expert Opin Drug Saf* ; 1: 319-24.
- 2-Sakano Y, Terada N, Ueda H, Fujii Y, Hamada Y, Akamatsu N and Ohno S. (2000): Histological study of articular cartilage in experimental rat knee arthritis induced by intracapsular injection of cationic polyethyleneimine. *Med. Electron. Microsc.* ;33(4):246-257.
- 3-Channa HM, Ashfaq M, Bangash R, Abbasi A and Qureshi MA. (2008): Preventive role of zinc chloride against toxicity of ciprofloxacin on the growing cartilage of Wistar albino rat litter. *J. Ayub Med. Coll. Abbottabad* ;20(4):77-81.
- 4-Sendzik J, Lode H and Stahlmann R. (2009): Quinolone-induced arthropathy: An update focusing on new mechanistic and clinical data. *Int. J. Antimicrob. Agents* ;33(3):194-200.
- 5-Takizawa T, Hashimoto K, Minami T, Yamashita S and Owen K. (1999): The comparative arthropathy of fluoroquinolones in dogs. *Hum. Exp. Toxicol.* Jun;18(6):392-399.
- 6-Forster C, Kociok K, Shakibaei M, Merker HJ and Stahlmann R. (1996): Quinolone-induced cartilage lesions are not reversible in rats. *Arch. Toxicol.* ;70(8):474-481.
- 7-Stahlmann R. (2003). Children as a special population at risk- quinolones as an example for xenobiotics exhibiting skeletal toxicity. *Arch. Toxicol.* Jan;77(1):7-11.
- 8-Cavusoglu I, Kahveci Z, Noyan S and Minbay Z. (2000). Quinolone arthropathy induced by ofloxacin in juvenile rats: A light microscopic study. *Turk. J. Med. Sci.* ;30(5):441-447
- 9-Kato M, Takada S, Ogawara S and Takayama S. (1995): Effect of levofloxacin on glycosaminoglycan and DNA synthesis of cultured rabbit chondrocytes at concentrations inducing cartilage lesions *in vivo*. *Antimicrob. Agents Chemother.* Sep;39(9):1979-1983.
- 10-Forster C, Schwabe R, Lozo E, Zippel U, Vormann J, Gunther T, Merker HJ and Stahlmann R. (1997). Quinolone-induced arthropathy: Exposure of magnesium-deficient aged rats or immature rats, mineral concentrations in target tissues and pharmacokinetics. *Arch. Toxicol.* ;72(1):26-32.
- 11-Forster C, Kociok K, Shakibaei M, Merker HJ and Stahlmann R. (1996). Quinolone-induced cartilage lesions are not reversible in rats. *Arch. Toxicol.* ;70(8):474-481.
- 12-Walter I, Egerbacher M, Wolfesberger B and Seiberl G. (1998). Confocal laser scanning microscopy of chondrocytes *in vitro*: Cytoskeletal changes after quinolone treatment. *Scanning* Oct;20(7):511-515.
- 13-Egerbacher M, Seiberl G, Wolfesberger B and Walter I. (2000). Ciprofloxacin causes cytoskeletal changes and detachment of human and rat chondrocytes *in vitro* . *Arch. Toxicol.* Jan,73(10-11):557-563 .
- 14-Takizawa T, Hashimoto K, Minami T, Yamashita S and Owen K. (1999). The comparative arthropathy of fluoroquinolones in dogs. *Hum. Exp. Toxicol.* Jun;18(6):392-399.
- 15-Stahlmann R, Forster C, Shakibaei M, Vormann J, Gunther T and Merker HJ. (1995). Magnesium deficiency induces joint cartilage lesions in juvenile rats which are identical to quinolone-induced arthropathy. *Antimicrob. Agents Chemother.* Sep;39(9):2013-2018.
- 16-Kashida Y, Kato M. (1997): Toxic effects of quinolone antibacterial agents on the musculoskeletal system in juvenile rats. *Toxicol. Pathol.* Nov-Dec;25(6):635-643.

- 17- Yabe K, Satoh H, Ishii Y, Jindo T, Sugawara T, Furuhashi K, Goryo M and Okada K. (2004): Early pathophysiologic feature of arthropathy in juvenile dogs induced by ofloxacin, a quinolone antimicrobial agent. *Vet.Pathol.* ;41(6):673-681.
- 18-Pfister K, Mazur D, Vormann J and Stahlmann R. (2007): Diminished ciprofloxacin-induced chondrotoxicity by supplementation with magnesium and vitamin E in immature rats. *Antimicrob.Agents Chemother.* ;51(3):1022-1027.
- 19-Halawa H.A.(2010). Effect of Ciprofloxacin on the Articular Cartilage and Epiphyseal Growth Plate Cartilage in the Growing Albino Rats . *Egypt. J. Histol.* Vol. 33, No. 3: 569 – 582.
- 20-Baker, K. R.et al(2012).Association of plasma n-6 and n-3 polyunsaturated fatty acids with synovitis in the knee: the MOST study.*Osteoarthritis Cartilage* .01.021.
- 21-Zainal, Z.et al.(2009).Relative efficacies of omega-3 polyunsaturated fatty acids in reducing expression of key proteins in a model system for studying osteoarthritis. *Osteoarthritis Cartilage* 17, 896–905 .
- 22-Baker, K. R. et al. (2010).Relation of synovitis to knee pain using contrast enhanced MRIs. *Ann. Rheum. Dis.* 69, 1779–1783.
- 23-Cleland, L. G. & James, M. J. (2012). Omega-3 fatty acids and synovitis in osteoarthritic knees *Nat. Rev. Rheumatol.* 8, 314–315 .