

Sprengel's Deformity Associated with Omovertebral bar between Inferior angle of the scapula and the Cervical spine: A Case Report

Mousa Imran Alghazali*

الخلاصة

تشوه سيرنكل يعرف بأنه الوضع العالي غير الطبيعي لعظم اللوح، من الممكن أن تشمل عظم لوح واحد أو كلا عظمي اللوح. وهناك أسباب كثيرة لعدم نزول عظم اللوح الى مكانه الطبيعي (بين الفقرة الصدرية الثانية و السابعة).

تم تسجيل حالة مرضية لمريض يبلغ من العمر 10 سنوات غير مثبتته تتميز بوجود شريط رابط بين الزاوية السفلية لعظم اللوح و الفقرة العنقية، و كذلك غياب العضلات المعينية الرئيسة و الثانوية مع ضعف العضلة شبه المنحرفة و المنشارية الأمامية حيث تم اجراء العملية الجراحية اللازمة لذلك و تم الحصول على نتائج جيدة للمريض من حيث المنظر و الحركة للكنتف.

من هذا يمكن الاستنتاج أن تشوه سيرنكل من الممكن أن يكون بسبب إرتباط شريط بين الزاوية السفلية لعظم اللوح مع الفقرات العنقية و نقص و ضعف بعض العضلات المجاورة لعظم اللوح.

Abstract

Background; Sprengel's deformity is a rare congenital anomaly of the shoulder girdle. The deformity is due to failure of descent of the scapula in intrauterine life.

Case Presentation; We report a case of unilateral Sprengel's deformity Sprengel's Deformity Associated with omovertebral bar between inferior angle of the scapula and the cervical spine ,absence of rhomboid major and rhomboid minor muscles, weakness of trapezius and serratus anterior in a 10-year-old boy.

Conclusion; Sprengel's deformity can be associated with omovertebral bar between inferior angle of the scapula and the cervical spine with other musculoskeletal abnormalities.

Introduction

Sprengel's deformity is defined as abnormally high placed scapula [1–5]. Eulenberg described this condition in 1863 for the first time [2, 3]. It is named for Ott springel (6). It may involve one or both scapulas. The affected bone lies at a higher level than normal. The scapula appears at the 5th week of gestation at C5-T1. The deformity results from failure to descent of the scapula from the C5-T1 position to the T2-T7 position at birth [2, 4]. Failure of descend of the scapula caused by;

1-Too great an intrauterine pressure.

2-Abnormal articulation of scapula with the spine (omovertebral bar).

*Orthopedic surgeon ,surgical department, Alqadisyia medical college.

3- Defective musculature of the scapulothoracic region.4-Arrest of development due to ineffective muscular tension. Congenital anomalies of other systems are also commonly associated. These include diastomata myelia, tethered cord, lumbosacral lipoma, renal anomalies(7), abnormalities of thoracic ribs(8), absence of ribs(9), cervical spinabifida, syringo-myelia, platybasia, etc. Those with minor cosmetic deformity or minimal functional impairment need no surgery as the benefit may be minimal(10). Various surgical methods have been advocated by different authors. The "Wood-ward" procedure and the modified "Green" procedure are the currently most used procedures(8,10). Although the ideal age suggested for surgical correction is 3-8 years, age is no longer a specific contra-indication(10).

The association of Sprengel's deformity with congenital scoliosis, fusion of the cervical vertebrae, and congenital heart disease has been described before [11]. But to our knowledge, its association with omovertebral bar between inferior angle of the scapula and the cervical spine has not been reported previously.

Case Presentation

A 10-year-old boy was brought by his parents to our clinic with the chief complaint of shortness of neck, head and neck deviation to the left side, and apparent limitations of left shoulder movements in abduction and elevation. His parents said that they had noticed the asymmetry in their child's shoulders when he was about 6 months, but they had been aware of his limited neck motion at much earlier time due to the difficulty in positioning the child for breast feeding. Familial history was unremarkable for any congenital disorder. On clinical examinations, left shoulder was apparently upper than the right shoulder in a standing position (Figure 1). His neck is shorter than normal in anterior view. Shortness of neck and elevation of left shoulder were apparent also from posterior view. Severe restrictions of active and passive rotation and lateral bending of the neck and abduction and external rotation of left shoulder were observed. . Physical examination of the right shoulder is normal. The patient was admitted with the plan of surgery. Some routine diagnostic measures were done for him such as CXR, shoulders X-ray, and abdominal sonography. Radiological investigations (Figure 2) demonstrated an obvious skeletal deformity. Right shoulder was upper than the left side. The patient went through operation (release of the medial border of the scapula, excision of the omovertebral bar between inferior border of the scapula and the cervical spine, resection of the supraspinous part of the scapula and suturing of the inferior pole of the scapula to the thoracic cage into pocket of the latissimus dorsi muscle have been performed to improve the results). The shoulder range of motion and the cosmetic appearance of the shoulder are much better after surgery(Figure 3).

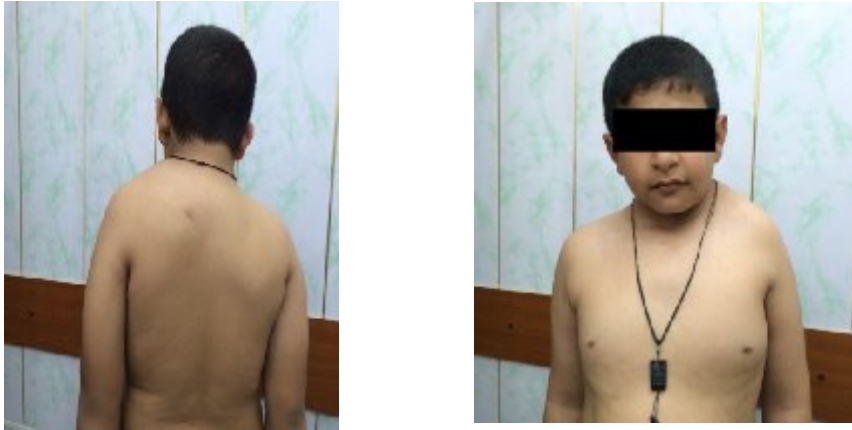

Figure 1: Photograph of the patient's body at 10 years of age. Congenital elevation of the left shoulder (Sprengel's deformity) apparent deformity is approximately severe and repair with surgery is needed.

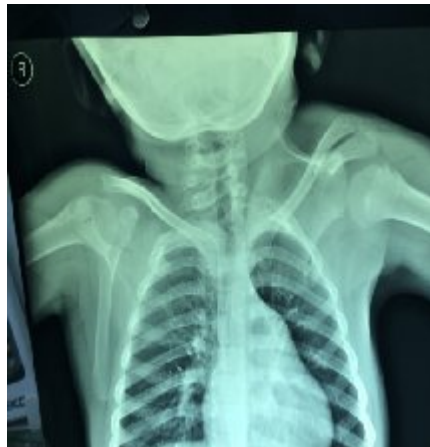

Figure 2: Anteroposterior radiography. This radiography shows left Sprengel's deformity with prominent superior angle of the scapula in the web of the neck.

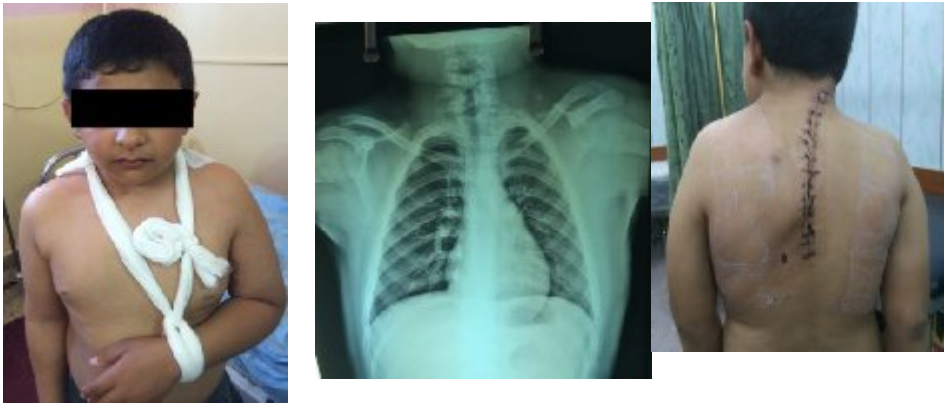


Figure 3. Photograph of the patient's body and radiograph postoperatively

Discussion

The scope of abnormalities that were present in this case is different from what has been described by other authors. Congenital high scapula was an isolated problem in the cases introduced by S. V. Hodgson and McMurtry I. [8, 9]. Although Klippel Feil syndrome is usually responsible for the limitation of neck motion in these patients, we did not find any vertebral fusion in our patient but the omovertebral bar between inferior angle of the scapula and the cervical spine seems to be responsible for this problem. Hegde and Shokeir [10] reported a case of Sprengel's deformity associated with pectoralis major agenesis. Most cases of absent pectoralis major muscle are associated with symbrachydactyly (Poland's disease), and renal failure is also known to be accompanied by this syndrome but the combination of congenital high scapula, with omovertebral bar between inferior angle of the scapula and the cervical spine and congenital absence of rhomboid major and minor muscles has not been reported before.

Conclusion

Sprengel's Deformity Associated with omovertebral bar between inferior angle of the scapula and the cervical spine with absence of rhomboid major and minor muscles is so rare and we could not find a similar case reported so far in orthopedic literature. Although this congenital abnormality is so rare but it should not be ignored in a society and we must find these cases and solve their problem either as functional or cosmetic aspect.

References

- 1- S. G. Lungu, "Undescended scapula," Medical Journal of Zambia, vol. 36, no. 3, pp. 136–139, 2009.
- 2-A. H. Crenshaw, Campbell's Operative Orthopedics, C.V. Mosby Company, St Louis, Mo, USA, 5th edition, 1971.
- 3-M. T. Legeyt and K. Dabney, "Sprengel's Deformity, Clinical Case Presentation," 1996, <http://gait.aidi.udel.edu/educate/sprengle.htm>.
- 4-O. D. Enersen, "Otto Gerhard Karl Sprengel," <http://www.Whonamedit.com/doctor.cfm/2144.Html>.
- 5-M. L. Kulkarni, "Sprengel's Deformity," <http://www.indianpediatrics.net/>.
- 6-O.K.Sprengel.Die angeborene Verschiebung des schulterblattes nach oben.Archiv fur klinische Chirurgie,Berlin,1891,42;545-549
- 7-Wilson MG, Mikity VG, Shinno NW. Dominant inheritance of Sprengel's de-formity. J Pediatr 1971, 79: 818-821.
- 8-Leibovic SJ, Ehrlich MG, Zaleske DJ. Sprengel deformity. J Bone Joint Surg 1990, 72A: 192-197.
- 9-Singh H. Sprengel's deformity with ab-sent ribs. Indian Pediatr 1933, 30: 800- 802.
- 10-Grogan DP, Stanley EA, Bobechko WP. The congenital undescended scapula. Surgical correction by the Woodward procedure. J Bone Joint Surg 1983, 65B: 598-605.
- 11-S. V. Hodgson and D. C. Chiu, "Dominant transmission of Sprengel's shoulder and cleft palate," Journal of Medical Genetics, vol. 18, no. 4, pp. 263–265, 1981. View at Scopus