

CASE REPORT

Trapped Fourth Ventricle: Case Study and Review of the Literature

Ali HikmatAzeez

ABSTRACT:

BACKGROUND:

A trapped fourth ventricle is diagnosed when the fourth ventricle is no longer communicates with the third ventricle and the basal cisterns. The resultant obstruction leads to persistent and progressive dilatation of the fourth ventricle.

CASE REPORT :

This 20-year-old male known to have right sided ventriculo-peritoneal shunt placed three years back after the diagnosis of obstructive hydrocephalus. On January, 2013 the patient was presented with headache, vomiting and blurred vision. CT scans of the brain showed well-decompressed lateral ventricles with a large and dilatation of the fourth ventricle. The diagnosis of trapped fourth ventricle was done and a shunt system was placed directly in the fourth ventricle. Postoperative period was uneventful and the patient was discharged well.

DISCUSSION:

The concept of trapped fourth ventricle is a well described entity. Different causes have been postulated and different therapeutic approaches were attempted to solve this problem.

CONCLUSION:

Direct ventriculo-peritoneal shunt in trapped fourth ventricle can efficiently resolve this condition.

KEY WORDS: trapped 4th ventricle, hydrocephalus, ventriculoperitoneal shunt.

INTRODUCTION:

A dilated fourth ventricle due to outlet obstruction is a clinical-radiologic entity with symptoms similar to those of a posterior fossa space-occupying lesion. Indeed, blockage of the foramina of Luschka and Magendie and of the aqueduct results in a "trapped" fourth ventricle. Continued cerebrospinal fluid (CSF) production within the fourth ventricle leads to cystic dilatation of the fourth ventricle ⁽¹⁾.

A diagnosed "trapped" fourth ventricle is symptomatic for brainstem compression, cerebellar signs or the resultant secondary hydrocephalus ⁽²⁾.

Patients with prolonged infection or multiple shunt operations are particularly at risk for this syndrome. ⁽³⁾(youmans Isolated Fourth Ventricle Syndrome)

Here a case of trapped fourth ventricle after repeated shunt infection is reported.

CASE REPORT:

This 20-year-old male has right sided ventriculo-peritoneal shunt placed three years back after the diagnosis of obstructive hydrocephalus without apparent cause. Eight months later, symptoms of increased intracranial pressure with altered consciousness started again. Brain computerized tomography (CT) scan revealed dilatation of the left lateral ventricle. Left sided ventriculo-peritoneal shunt was inserted with subsequent relief of the symptoms. On January, 2013 the patient was admitted again because of headache, vomiting and blurred vision. These symptoms were subacute at onset and progressive in nature. Two successive CT scans of the brain showed well-decompressed lateral ventricles with a large and progressive dilatation of the fourth ventricle causing brain stem compression. The diagnosis of trapped fourth ventricle was made and a separate shunt system was placed directly in the fourth ventricle through sub-occipital burr hole. Postoperative period was uneventful and the patient was discharged well.

DISCUSSION:

The term entrapped fourth ventricle, called also isolated fourth ventricle syndrome, has been used to describe the situation in which the fourth ventricle no longer communicates with the third ventricle, as well as the basal cisterns.

It is thought that secondary aqueduct stenosis from adhesions, obstruction of the exit foramina, or infective debris pooling in the basal cisterns

Specialist Neurosurgeon, Neurosurgical Unit
Ibn Sena Teaching Hospital. Mosul, Iraq.

TRAPPED FOURTH VENTRICLE

may be responsible for this condition. Patients may have the typical symptoms and signs of hydrocephalus or more atypical symptoms such as lower cranial nerve dysfunction. Occasionally, an entrapped fourth ventricle is an incidental finding on imaging.³

Occasionally, compartmentalization of the ventricular system can be noted after CSF shunting. For instance, after shunt placement in the lateral ventricles there may be persistent and progressive dilatation of the fourth ventricle with associated brain stem and cerebellar dysfunction.⁽⁴⁾ However, many cases are asymptomatic and are discovered as incidental findings on CT scan.^(5, 6)

Patients with entrapped fourth ventricle with Ataxia, lethargy, diplopia, nystagmus, mental confusion, dysarthria, and multiple cranial nerve palsies.⁽⁷⁾ However, Many cases are asymptomatic and are discovered as incidental findings on CT scan.⁽⁸⁾

CT and MRI diagnosis of isolated fourth ventricle is usually accurate. The most striking finding is the presence of a very large fourth ventricle, accompanied by very small or "slit-like" lateral and third ventricles.⁽⁹⁾ The fourth ventricle appears rounded or ballooned, the brain stem is displaced ventrally, and posterior fossa subarachnoid spaces and cisterna magna are reduced in size or obliterated⁽⁷⁾.

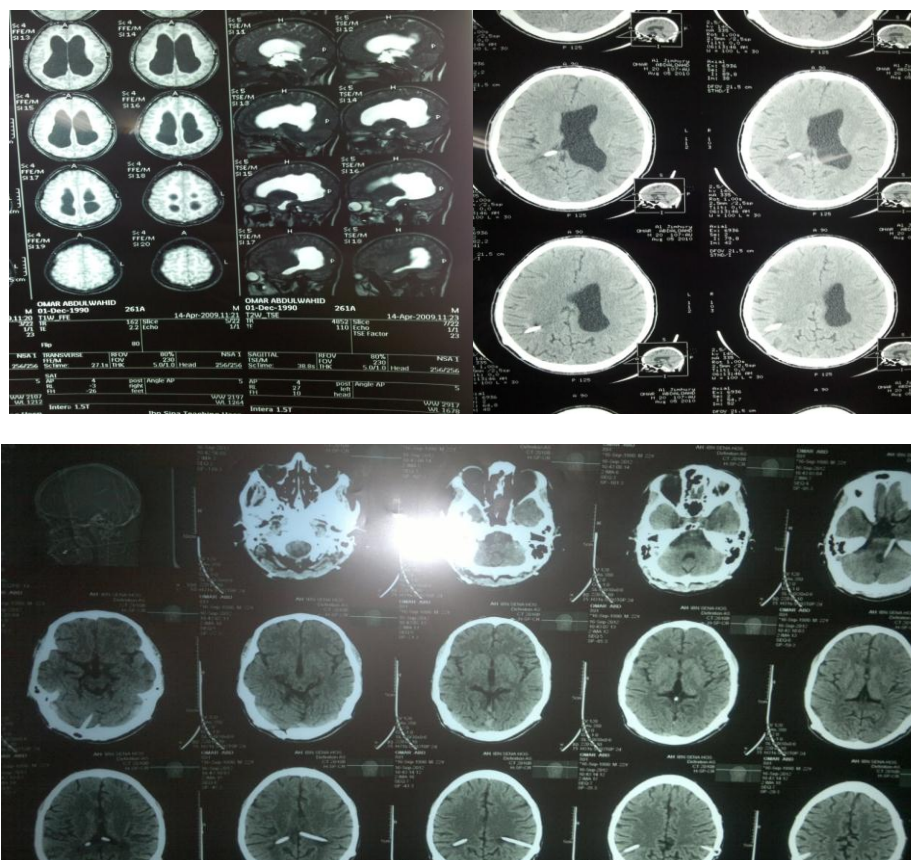
Treatment options for isolated fourth ventricle include: fourth ventricle-peritoneal shunting, direct microsurgical approach, veil excision (usually an arachnoid veil) and open aqueduct canalization or outlet fenestration of the fourth ventricle.⁽⁷⁾ Endoscopic approaches include aqueductoplasty, aqueductal stenting, and cystoventricular fenestration.⁽¹⁰⁾ Regarding revision of the existing shunt, the literature does not reveal any successful management strategy

that utilizes manipulation of valve pressure to effect relief of a functional obstruction.⁽¹⁰⁾

Some authors favored a direct microsurgical opening of the outlet of the fourth ventricle, without insertion of a fixed foreign body, as the preferred primary surgical option for entrapment of the fourth ventricle, concluding that foramen magnum decompression is an effective treatment alternative.⁽¹¹⁾ However, most authors consider shunting of the fourth ventricle as the less invasive and more effective approach.^(7,9) Placement of the new fourth ventricular catheter could be through midline or lateral and may then be connected to a preexisting lateral ventriculoperitoneal shunt catheter tubing if feasible⁽¹⁰⁾. To improve the safety and effectiveness of shunting, some authors recommended cannulating the posterior fossa cyst under direct stereotactic technique or ultrasound or endoscopic guidance [21] to avoid possible direct trauma to the brain stem and to ensure exact placement.^(12, 13) Although not done in our patient due to lack of availability of Y connector, it is important to connect the fourth ventricular catheter with a Y connector to the pre-existing ventriculoperitoneal shunt.⁽⁷⁾ The use of Y connector helps prevent the creation of a pressure gradient between the infra and supratentorial compartment, with possible onset of terrible, disabling headaches triggered by the move from reclining to upright standing.

It is interesting to note that the placement of a new shunt system in the fourth ventricle in our case significantly alleviated the symptoms of raised intracranial pressure without the development of any complications related to the fourth ventricular shunting. Post-operative course was uneventful and complications were not noticed in the 6 months follow-up period.

TRAPPED FOURTH VENTRICLE



CONCLUSION:

That direct placement of a new shunt in the trapped fourth ventricle is simple, safe and effective in controlling the symptoms and signs of trapped fourth ventricle cases.

REFERENCES:

1. Enrique Ferrer, Matteo de Notaris. Third Ventriculostomy and Fourth Ventricle Outlets Obstruction. *World Neurosurg.* 2013;79:2S:S20. e9-S20.e13.
2. Suhas Udayakumar&DilipPanikar. Postulating the concept of compensated trapped fourth ventricle: a case-based demonstration with long-term clinicoradiological follow-up. *Childs NervSyst* 2012;28:661–64.
3. NicoleC. Keong, Marek Czosnyka, ZofiaCzosnyka, John D. Pickard. Clinical evaluation of adult hydrocephalus. In: H Winn (ed). *Youmans Neurological Surgery.* 6th Edition, Saunders, 2011.
4. Alia Hdeib, Alan R. Cohen. Hydrocephalus in Children and Adults. In: Richard Ellenbogen, SaleemAbdulrauf, LaligamSekhar (eds). *Principles of Neurological Surgery.* 3rd Edition, Saunders, 2012.
5. Dollo C, Kanner A, Siomin V. Outlet fenestration for isolated fourth ventricle with and without an internal shunt *Child's NervSyst* 2001;17:483-86.
6. James HE Spectrum of syndrome of the isolated fourth ventricle in post hemorrhagic hydrocephalus of the premature infant. *PediatrNeurosurg* 1990;16: 305-8.
7. Pietro Spennato, Giuseppe Cinalu, Giuseppe Carannante, Claudio Ruggiero, Maria Laura Del Basso de Caro. Multiloculated Hydrocephalus. In: Cinalli G.Maixner, W.J., Sainte-Rose C. (eds). *Pediatric Hydrocephalus.* Springer-Verlag Milan 2005.

TRAPPED FOURTH VENTRICLE

8. Dollo C, Kanner A, Siomin V: Outlet fenestration for isolated fourth ventricle with and without an internal shunt. *Child's NervSyst* 2001;17:483-86.
9. James HE: Spectrum of syndrome of the isolated fourth ventricle in posthemorrhagic hydrocephalus of the premature infant. *PediatrNeurosurg* 1990-91;16:305-8.
10. Beng Ti Ang Paul Steinbok D. Douglas Cochrane. Etiological differences between the isolated lateral ventricle and the isolated fourth ventricle. *Childs NervSyst* 2006;22:1080-85.
11. Suhas U, Xiao Bo, Liat Ben Sira, Shlomi C. Unusual subacutediencephalic edema associated with a trapped fourth ventricle: resolution following foramen magnum decompression. *Childs NervSyst* 2009;25:1517-20.
12. Eder HG, Leber KA, Gruber W: Complications after shunting isolated fourth ventricle. *Child's NervSyst* 1997;13:13-16.
13. Montes JL, Clarke DB, Farmer JP: Stereotactic transtentorial hiatus ventriculoperitoneal shunting for the sequestered fourth ventricle. *J Neurosurg* 1994;80:759-61.