

## The Effect of Aspirin on Histology of Placenta

Eman Ghanim Sheet Al-Hylli

### ABSTRACT:

#### BACKGROUND :

Preeclampsia (PE) is a potentially life-threatening hypertensive disorder affecting 2-7% of all pregnancies, It is a leading cause of maternal mortality, and associated with high perinatal mortality and morbidity, including intrauterine growth restriction (IUGR) and prematurity. A daily low dose of aspirin (60-80 mg /day) may be used for prevention and treatment of PE and fetal growth retardation in pregnant women at risk.

#### OBJECTIVE:

To assess the influence of aspirin therapy on the histology of placenta from mothers with PE and to correlate the findings with those from pre-eclamptic mothers but not using aspirin during their pregnancy and with placenta from normal Pregnancies.

#### METHODS:

This study was carried out on one hundred twenty pregnant women, thirty five with uncomplicated pregnancy and eighty five mothers with PE, fifty of these hypertensive women on aspirin therapy since first trimester.

#### RESULT:

It was found that mothers with pre-eclampsia either take aspirin or not had relatively smaller, irregular placentae. Histological features of vascular insufficiency like thrombosis, cytotrophoblastic cellular proliferation, fibrin plaque formation etc. were present in more or less similar amount in both groups of hypertensive placentae. Babies of such mothers were mostly small for date.

#### CONCLUSION :

Despite the little improvement in outcomes of the aspirin treated pregnancy, histologic evidence of placental pathology persisted in the majority of women with PE. so aspirin therapy is not effective in preventing and treatment PE

**KEY WORDS :** hypertension, aspirin, histology, placenta.

### INTRODUCTION:

Aspirin (acetylsalicylic acid) is the most frequently consumed drug in pregnancy, a daily low dose of aspirin (60-80 mg) may markedly reduce the incidence of hypertensive disorders and fetal growth retardation in pregnant women at risk<sup>(1)</sup>.

Preeclampsia (PE) is a potentially life-threatening hypertensive disorder affecting 2-7% of all pregnancies, It is a leading cause of maternal mortality<sup>(2)</sup>. The prevalence of the condition varies between 5% and 10%, but could be as high as 18% in developing countries<sup>(3,4)</sup>. Moreover, preeclampsia is associated with high perinatal mortality and morbidity<sup>(5)</sup>.

PE originates in the placenta, probably as the result of under-perfusion of the uteroplacental circulation associated with structural and occlusive changes in the spiral arteries.<sup>(6)</sup>

In recent years, it has been revealed that there is a substantial relationship between confined placental mosaicism and foetal growth retardation<sup>(7)</sup> an estimated 70% of the excess foetal deaths in PE can be ascribed to large placental infarcts and markedly small placental size<sup>(8)</sup>. Consequently, if prophylaxis against preeclampsia were effective, it might prevent not only that disorder but also some cases of IUGR without overt preeclampsia.

PE is associated with deficient intravascular production of prostacyclin and with excessive production of thromboxane." These findings and the evidence for activation of the clotting system

Department of Anatomy- Histology -Nineveh Medical College.

in preeclampsia and IUGR with early involvement of the platelets " have led to the use of antiplatelet agents<sup>(9)</sup>. Low-dose aspirin (60-150 mg / day) is a widely used and well-tolerated antiplatelet treatment, which irreversibly inhibits almost all platelet cyclooxygenase activity, there by blocking synthesis of the vasoconstrictor and platelet-aggregating<sup>(9)</sup>. The potential antiplatelet effect of aspirin derives from inhibition of the platelet production of thromboxane. so use for prevention and treatment of PE<sup>(10)</sup>.

Therefore, we aimed to assess the influence of aspirin therapy on the histology of placenta from mothers with PE and to correlate the findings with those from pre eclamptic mothers but not using aspirin during their pregnancy and with placenta from normal pregnancies.

### **MATERIAL AND METHOD:**

A prospective study of 120 pregnant women ,thirty-five mothers were normotensive (NT) and eighty-five mothers complicated by preeclampsia(PE) (defined by a blood pressure >140/90 mm Hg occurring after 20 weeks of gestation) . these groups were selected from indoor patients attended to Al-batool Gynaecological and obstetrical teaching hospital in Mosul City. The women were self referred or referred by general practitioner or by private clinics from 1st september 2012 till 1st septemper 2013. The patients summated between ages of 18 years and 45 years, primi and para 2 to 5. Among the hypertensive group , 50 patient had history of hypertension in previous pregnancy or had ultrasonographic evidence of abnormal placentation diagnosed by uterine artery Doppler studies. So their doctors were put them on aspirin treatment in a dose of 75- 100mg / day since first trimester.

patients asked for: name, age, family history, medical history ,history of past illness, history of previous child birth , drug history ,etc). all Mothers were examined clinically (for height, weight, blood pressure, pulse, anaemia, jaundice etc.) Mothers with hypertension had their blood pressure ranging from 140/90 mm. to 160/110 mm of Hg .. All members of the study groups were delivered by normal vaginal delivery or by planned cesarean section .

After delivery placentae were collected for histopathological studies.Placentas were collected from PE women who:

(i) Had no history of hypertension before pregnancy or during the first (20) weeks of gestation,

(ii) Had a positive dipstick test for proteinuria (at least +1) in freshly voided urine.

All control subjects had no history of raised blood pressure at any stage during their life and had no evident of proteinuria prior to the pregnancy.

The size, shape, weight of placentae were noted along with the inspection of marginal veins for any thrombus.

Full-thickness samples were taken from the central part of placenta and from Umbilical cord. The excised part of tissue was immersed in 10% neutral-buffered formalin for 24 hours, washed, dehydrated, cleared and embedded in paraffin. Then, five  $\mu$ m sections were stained with hematoxylin and eosin (H&E) stain then examined under light microscope<sup>(11)</sup>.

### **Statistical Analysis**

The results were statistically analyzed using paired-samples t-test .Values were expressed as Mean $\pm$  Standard Deviation<sup>(12)</sup>

### **RESULTS:**

The mean age of PE pregnancy, were 31.5 $\pm$ 5.98 years, showed that there were no significant ( $p\leq 0.05$ ) differences compared with the mean age of normotensive(NT) pregnancy year 28.26 $\pm$ 3.62. (table-1).

The PE is more frequent in multigravida than in primigravida women. (fig 2). The mean systolic blood pressure (SBP) and diastolic blood pressure (DBP) in women with PE without aspirin 160.50 $\pm$  9.13 and 105.25 $\pm$ 12.48 and in women with PE on aspirin 155 $\pm$ 10. 13 and 95.51  $\pm$ 9.12 mmHg are significantly higher when compared to those in NT pregnancy 115.75 $\pm$ 12.90 and 75.00 $\pm$ 7.25 mmHg respectively. Figure (3) and table (2)

Mean birth weight (MBW) of new born babies: - was 3.2 Kg + 0.32 Kg in the control group and it was 2.09 + 0 .48 Kg in the hypertensive group without aspirin and 2.2kg $\pm$ 0.21 in group of aspirin treatment. Also mean placental weight, were significantly ( $p>0.01$ ) smaller in thehypertensive group than in the control(table 2).

### **Histopathological Study**

On microscopic examination of haematoxiline and eosin stained slides, found that : In placental tissue of normotensive pregnancy after delivery shows normal placental villi with central connective tissues core covered by trophoblastic cell layers . each villous was rich with fetal

## EFFECT OF ASPIRIN ON OF PLACENTA

capillaries. Also, villi were separated from each other by intervillous spaces filled with maternal blood (Figures 3-1, 2).

Specific histological changes were seen in the preeclamptic placentae.

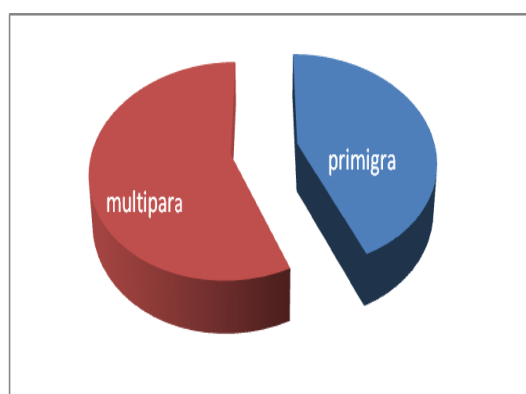
placental tissues of PE pregnancy whose not use aspirin show : hypertrophy of the smooth muscle of the artery wall and hyperplasia of the endothelium, fibrinoid necrosis ( fig4-1), Hydropic changes in chorionic villi ( fig 4-2) Sectioned syncytial strands or sprouts are

identifiable by the absence of any villous core and cytotrophoblastic cellular damage with fibrosis and hyalinised villous spots (Fig4-3) Fetal capillaries have usually disappeared in most villi; however, fetal capillary remained recognizable occasionally .

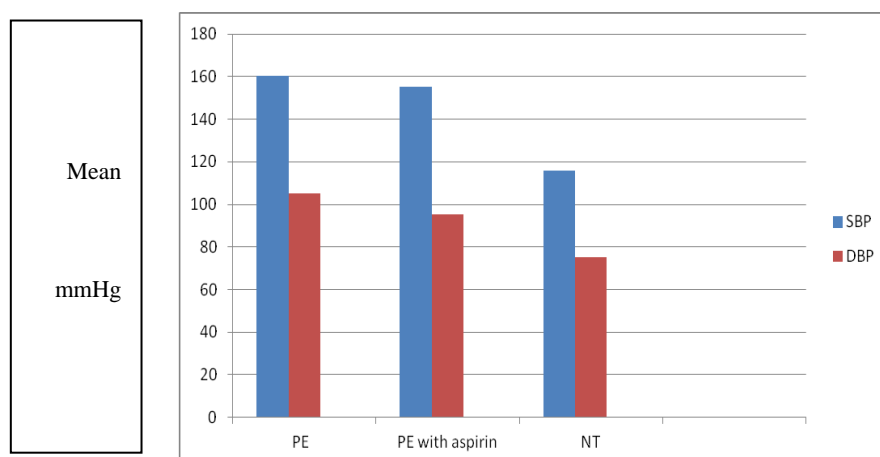
The placental tissue of preeclamptic mothers who use aspirin during their pregnancy show: congestion and fibrosis of chorionic villi, (5-3) thick wall blood vessels(5-1) and deposition of fibrin and decrease of blood vessels lumen(5-2)

**Table 1: Data are presented as mean  $\pm$  sd and a value of  $P < 0.05$  was considered statistically significant. NS, not significant.**

variable	control $\pm$ sd	PE (without aspirin) $\pm$ sd	P value
Maternal age (year)	28.26 $\pm$ 3.62	31.5 $\pm$ 5.98	NS



**Figure 1: PE is more frequent in multigravida 45/80 (58.82%) than in primigravida 35/80 (41.18%).**



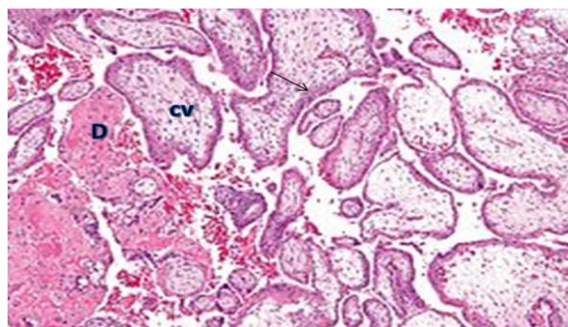
**Fig 2: The mean systolic blood pressure and diastolic blood pressure between pre-eclampsia and normotensive pregnancy.**

## EFFECT OF ASPIRIN ON OF PLACENTA

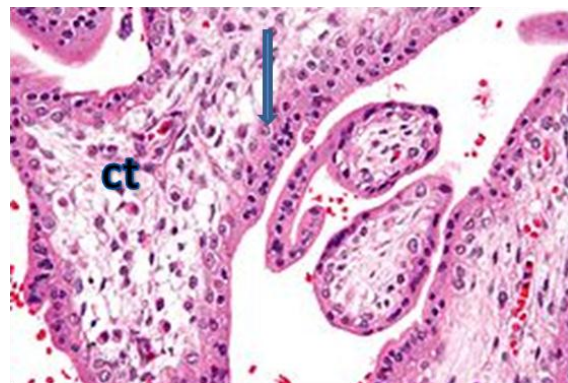
**Table 2: The mean of blood pressure (systolic and diastolic) , birth wt, placental wt between pre-eclampsia (both groups) and normotensive pregnancy.**

variable	Control mean±sd	PE without aspirin. mean±sd	PE with aspirin. mean±sd	Statistical Significance P > 0.01
Blood presu				
SBP	115.75±12.90	160.50± 9.13	155±10. 13	significant
DBP	75.00±7.25	105.25±12.48	95.51 ±9.12	significant
Birth wt in kgm	3.2 Kg ± 0.32	2.09 ± 0 .48	2.09 + 0 .48	significant
Placental wt in gm	515±57	395±62	405±55	significant

sd: standard deviation



**Figure 3-1: Placenta; normal chorionic villi CV which show trophoblasts (□) with Center loose connective tissue . decidua basalis D.**



**Fig3-2: Normal chorionic villi which show trophoblastic cells ( → )with loose connective tissue( ct).**

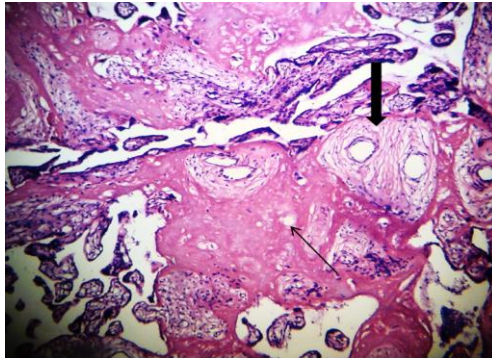


Fig 4-1: Section of PE placenta shows chorionic villi were decreased of blood vessels diameter (□) and deposition of fibrin (□).

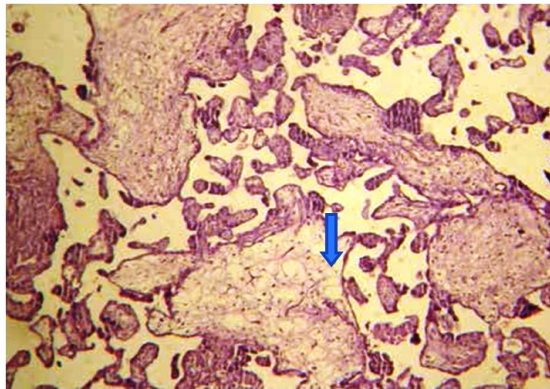


Fig 4-2: Part of placental from PE pregnancy in which the chorionic villi show hydropic degenerative change

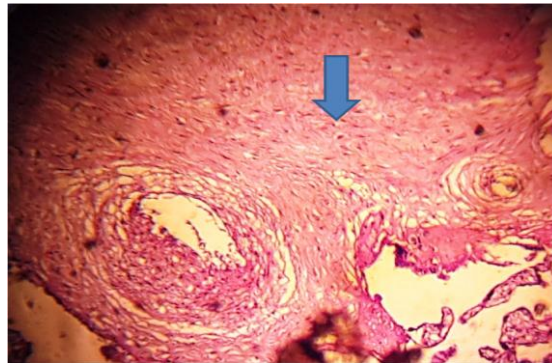


Fig 4-3: Section of PE placenta shows chorionic villi were fibrosed (□) and damage in trophoblastic.

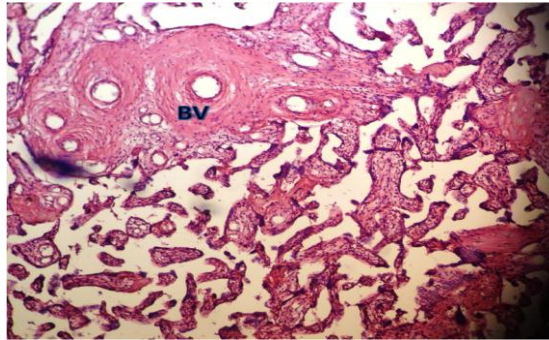


Fig 5-1: Chorionic villi in placenta from PE with aspirin showing decreased of blood vessels diameter (□) and deposition of fibrin (□).

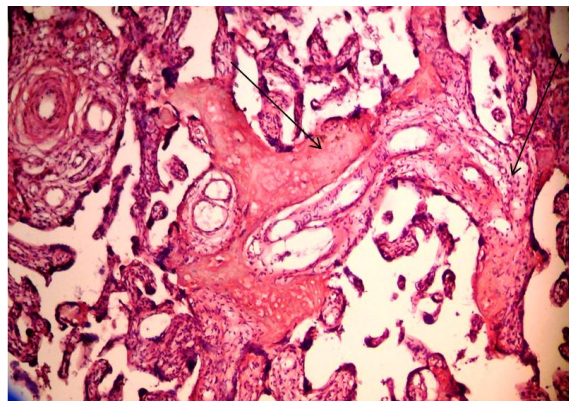


Fig 5-2: Chorionic villi in placenta from PE pregnancy on aspirin shows Deposition of fibrin (□) and decreased blood vessels diameter.

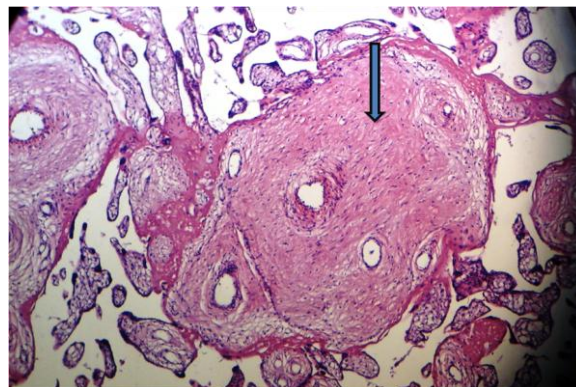


Fig 5-3: Chorionic villi in placenta from PE pregnancy with aspirin shows fibrosis( → ).

**DISCUSSION:**

PE is a multisystem disorder usually associated with raised blood pressure and proteinuria. It's relatively common complication of the second half of pregnancy affects 2-8% of pregnancies<sup>(13)</sup>, it remains a major cause of morbidity and mortality for both woman and

child. Although the causes of pre-eclampsia are unknown, it is primarily a placental disorder<sup>(14)</sup>. During implantation, deficient trophoblast invasion of the maternal spiral arteries leads to under perfusion of the uteroplacental circulation and placental ischaemia. The resulting placental

damage is thought to be responsible for the release of, as yet unknown, factors into the maternal circulation, which then alter endothelial cell function and cause widespread circulatory changes<sup>(15)</sup>. Women with the pre-eclampsia have excessive production of thromboxane, a vasoconstrictor<sup>(16)</sup> and platelet agonist. and thus aspirin has long been tried for both prevention and treatment of pre-eclampsia<sup>(1)</sup> and reductions in more substantive outcomes, such as perinatal death and intrauterine growth restriction.<sup>(17)</sup>

Present study revealed that the fetal weight is significantly less in the hypertensive groups with or without aspirin than the control group. The weight of placenta show significantly lower values in the PE patients. These findings corroborate well with that of the other studies.<sup>(18,19)</sup>

Some investigators show that early trials of low dose aspirin (60-150 mg/day) for preventing and treating pre-eclampsia suggested a considerable reduction in the risk of pre-eclampsia.<sup>(20)</sup>

our study show that all placentas obtained from the PE pregnancies with or without aspirin reveal a number of histological changes which are more or less similar in both groups. These changes are: damage in trophoblastic cells, congestion, fibrosis in chorionic villi, deposition of fibrin and decrease of blood vessels diameter with thickening of blood vessel wall.

It is well accepted that the primary defect in PE must be in the Placenta, whereas the decreased in placental perfusion is thought to lead to fetoplacental ischemia. This ischemic placenta may produce certain circulating agents which cause the wide spread dysfunction of the maternal vascular endothelium that leads to the systemic manifestation of PE<sup>(21)</sup>. These results are similar to the findings of many other works<sup>(22,23)</sup>.

The lesions of the placenta will be due to ischemia and subsequent reaction of the placental tissue to ischemia. however some researcher found that aspirin may cause disorders in septum of blood vessels of placenta in mice<sup>(24)</sup>.

### CONCLUSION:

Although low dose aspirin appears to be safe, for most women, it is not effective in preventing or treating pre-eclampsia and its complications. Despite an improvement in outcomes in the aspirin treated pregnancy, histologic evidence of placental pathology persisted in the majority of women with a prior complicated pregnancy demonstrating similar placental lesions.

### REFERENCES:

1. Vainio M, Kujansuu E, Iso-Mustajarvi M, Maenpaa J. Low doseacetylsalicylic acid in prevention of pregnancy-induced hypertension and intrauterine growth retardation in women with bilateral uterine artery notches. *BJOG* 2002;109:161–67.
2. WHO. Risking death to give life. Geneva: World Health Organization;2005.
3. Helewa ME, Burrows RF, Smith J, Williams K, Brain P, Rabkin SW. Report of the Canadian Hypertension Society Consensus Conference: 1. Definitions, evaluation and classification of hypertensive disorders in pregnancy. *CMAJ* 1997;157:715–25.
4. Geographic variation in the incidence of hypertension in pregnancy. World Health Organization International Collaborative Study of Hypertensive Disorders of Pregnancy. *Am J Obstet Gynecol* 1988;158:80–83.
5. Khan KS, Wojdyla D, Say L, Gulmezoglu AM, Van Look PF. WHO analysis of causes of maternal death: a systematic review. *Lancet* 2006;367:1066–74.
6. Pijnenborg R, Dixon G, Robertson WB, Brosens I. Trophoblastic invasion of human decidua from 8 to 18 weeks of pregnancy. *Placenta* 1980;1:3–19.
7. Kalousek DK, Langlois S. The effects of placental and somatic chromosomal mosaicism on foetal growth. In: Ward RHT, Smith SK, Donnai (eds). *Early foetal growth and development*. RCOG Press, London.1994:245-56.
8. Naeye RL, Friedman EA. Causes of perinatal death associated with gestational hypertension and proteinuria. *Am J Obstet Gynecol.* 1979;133:8-10.
9. Ebrashy A, Ibrahim M, Marzook A, Yousef D. Usefulness of aspirin therapy in high-risk pregnant women with abnormal uterine artery Doppler ultrasound at 14–16 weeks pregnancy: randomized controlled clinical trial. *Croat Med J* 2005;46:826–31.
10. Duley L, Henderson-Smart DJ, Meher S, King JF. Antiplatelet agents for preventing pre-eclampsia and its complications. *Cochrane Database Syst Rev* 2007;18:CD004659.
11. Bancroft, J. and Stevens, A.. *Theory and Practice of histological techniques*. 2nd Ed., Churchill Livingstone, Edinburg,London1982.

## EFFECT OF ASPIRIN ON OF PLACENTA

---

12. Sorli, D.E.. Medical biostatistical & epidemiology: Examination & board review, 1st ed. Appleton&Lange 1995:47-88.
13. World Health Organization International Collaborative Study of Hyper-tensive Disorders of Pregnancy. Geographic variation in the incidence of hypertension in pregnancy. *Am J Obstet Gynecol* 1988;158:80-83.
14. Roberts JM, Redman CWG. Pre-eclampsia: more than pregnancy- induced hypertension. *Lancet* 1993;341:1447-51.
15. Knight M, Duley L, Henderson-Smart D, King J(1998). The effectiveness and safety of antiplatelet agents for the prevention and treatment of pre-eclampsia (Cochrane protocol). In: Cochrane Collaboration. *Cochrane Library*. Issue 3. Oxford: Update Software,
16. Young, B. C.; Richard, J. L. and Karumanchi, S. A. Pathogenesis of Preeclampsia. *Ann. Rev. Path.: Mechan. Dise*, 2010;5:173-92.
17. ECPPA Collaborative Group. ECPPA: randomized trial of low dose aspirin for the prevention of maternal and fetal complications in high risk pregnant women. *BJOG* 1996;103:39-47.
18. Siddiqui, I. A.; Anila, J.; Waleed, T. and Al Kadri, H. M. F. Role of oxidative stress in the pathogenesis of Preeclampsia. *Arch. Gynecol. Obstet.* 2010;282:469-74.
19. Vinnars, M.; Josefine, N.; Sam, G.; Magnus, W. and Nikos, P. The severity of clinical manifestations in preeclampsia correlates with the amount of placental infarction. *Nord. Feder. Soci. Obstet. Gynecol.* 2011;90:19-25.
20. Rotchell YE, Cruickshank JK, Gay MP, Griffiths J, Stewart A, Farrell B, et al. Barbados Low Dose Aspirin Study in Pregnancy (BLASP): arandomised trial for the prevention of pre-eclampsia and its complications. *Br J Obstet Gynaecol* 1998;105:286-92.
21. Yuan, H.; David, H. and Karumanchi S. A.. Angiogenic factors in the pathogenesis of Preeclampsia. *Curr. Topi. Develo. Bio.* 2005;71:297-312.
22. Naeye RL, Friedman EA. Causes of perinatal death associated with gestational hypertension and proteinuria. *Am J Obstet Gynecol.* 1979;133:8-10.
23. Fox H. The placenta in intra uterine growth retardation. In: Ward RHT, Smith SK, Donnai D (Eds). Early foetal growth and development. RCOG Press, London. 1994:223-35.
24. Soheyla. Jafarpur ; Mokhtar. Jafarpur . Effects of aspirin on microstructure of placenta of mouse.