

The Role of Pometone (Pomegranate seed oil) in Ameliorating the Deleterious Effect of Methionine Overload on Some Histological Aspects of heart and aorta in Female Rabbits (Part-II)

Baraa Najim Al-Okaily[@] and Lekaa Najim Abdulla

*Department of Physiology and Pharmacology, College of Veterinary Medicine, University of Baghdad, Iraq

E-mail: baraanajim@yahoo.com

Accepted on: 28/5/2014

Summary

This experiment was aimed to investigate the role of pomegranate seed oil (PSO) in ameliorating the deleterious effects of methionine overload on some histopathological structure of heart and aorta in adult female rabbits. Thirty-Two female rabbits divided into four groups eight animals each, and treated for 42 days daily as follows: the first groups were drenched drinking corn oil, serving as control (group C), second group (group T1) were intubated orally with methionine 100mg/kg. B.W, while the third group (group T2) were intubated orally with methionine 100mg/kg. B.W and pomegranate seed oil (PSO) 30 mg /Kg. B.W, and the animals in group T3 were intubated orally with pomegranate seed oil 30 mg /Kg. B.W. At the end of the experiment rabbits were sacrificed. Serial sections from the heart and aorta were prepared and examined microscopically. Histological examination of heart and aorta of methionine overload treated group (T1) showed edema, RBCs and few neutrophils infiltration, with vacuolar degeneration of cardiac muscle cells, fragment of muscle fiber, congested blood vessels between muscle fibers. An increase in thickness of intima, erosion and mononuclear cells infiltration in sub intima of aorta were also observed. Histological sections of heart and aorta in T2 and T3 groups showed the absence of histopathological lesions in aortic tissue with moderate edema between muscle fiber of T2 group as comparing to group T1. In conclusion, the results confirm the cardioprotective role of pomegranate seed oil by ameliorating the effect of methionine overload on cardiac muscle and aorta.

Keywords: Pomegranate seed oil, Methionine overload, Cardiac muscle, Aorta.

Introduction

Methionine is required for much physiological process. In principle excess could lead to generation of toxic sulfur metabolites (1). The richest sources of methionine is proteins of animal origin (2 and 3). It is used to prevent liver damages due to different agents like acetaminophen poisoning, methotrexate, lipid accumulation in the liver and improve the flow of bile and hepatic lipidosis (4 -6). Homocysteine (Hcy) is a sulfur containing amino acid extensively formed as an intermediate product in metabolism of methionine. Methionine in the diet is the main source of hyperhomocysteinemia (HHcy) in the blood (7). HHcy is a condition in which the regulation of intracellular Hcy level is disrupted and Hcy export to the plasma compartment is accelerated (8). Several studies have suggested that HHcy is one of the independent risk factor for cardiovascular

disease and coronary artery disease including coronary, carotid, aortic, peripheral vessels and deep venous thrombosis (9-11). Chronic alcohol intake (12 and 13), smoking cigarettes (14 and 15), hypothyroidism and malignancies (16 and 17) and coffee consumption (18 and 19) are seems to be linked with elevation in Hcy levels.

Many evidence demonstrated that there is a link between oxidative stress and cardiovascular disease, ROS-induced oxidative stress and plays a role in various cardiovascular diseases such as atherosclerosis, ischemic heart disease, hypertension, cardiomyopathies, cardiac hypertrophy and congestive heart failure (20-23) and abnormalities in myocyte function (24 and 25).

Pomegranate seed oil (PSO) is a potent source of punicalic acid, an Omega 5 conjugated fatty acid, beneficial phytoestrogen and a rare plant based source of CLA (conjugated

linoleic acid). The CLA in pomegranate seed oil is an especially potent anti-inflammatory and anti-carcinogenic agent (26). Mirmiran *et al.*, (27) explained that patients consumed pomegranate seed oil caused a significant decrease in their serum triglycerides and LDL-cholesterol level with risen in HDL-cholesterol concentrations (28). Consumption of pomegranate juice reduced progression of arterial wall thickening among patients with the highest degree of oxidative stress and the most severe disturbances in their lipid profiles (29). The role of PSO against methionine overload has not so far been studied. Therefore, this study was carried out to investigate: The histological alteration in heart and aorta induced by methionine overload in female rabbits and the role of PSO in protecting the heart and aorta against the induced changes.

Materials and Methods

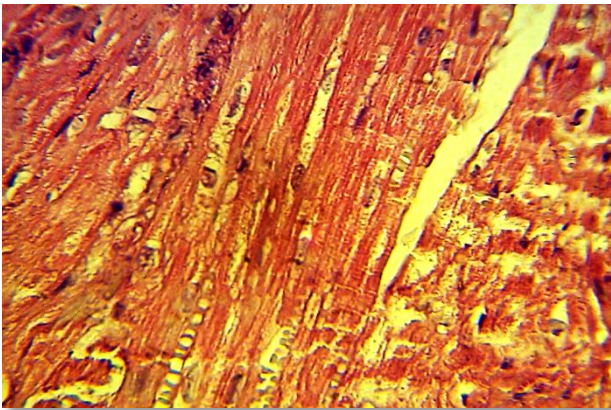
Thirty two adult female local rabbit with a body weight ranging from 1250 to 2000 g. Rabbits were housed in cages in air conditioned room (22-25°C) in the animal house of College of Veterinary Medicine-University of Baghdad for the period from November 2012 up to February 2013. They were left for two weeks for adaptation with the experimental conditions. Rabbits were fed the standard balanced pellets and supplied with tap water *ad libitum*. Thirty-Two female rabbits were divided into four equal groups, eight animals each, and treated for 42 days daily as follows: the first group were administered corn oil, serving as control (group C), second group (group T1) were intubated orally with methionine 100mg/kg. B.W, while rabbits in the third group (group T2) were intubated orally with methionine 100mg/kg. B.W plus pomegranate seed oil (PSO) 30 mg /Kg. B.W, and the animals in (group T3) were intubated orally with pomegranate seed oil 30 mg /Kg. At the end of the experiment rabbits were sacrificed. The abdominal wall was opened longitudinally, the heart and aorta were taken and fixed tissue sections were processed by using histological techniques of tissue preparation for histopathological examination changes (30). Histological sections 5 µm thick

were stained with hematoxyline and eosin. Light microscope, photographs of histological sections and digital camera was used.

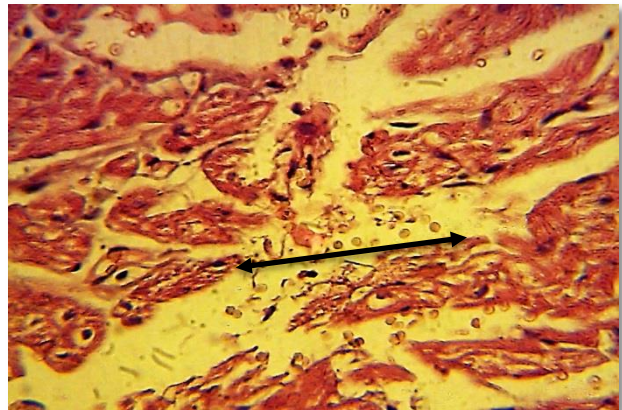
Results and Discussion

Comparing to control group (fig.1) histological sections of heart of rabbits exposed to methionine (group T1) showed edema, RBCs, and inflammatory cell particularly neutrophils between bundle of cardiac muscle in addition to vaculation in the cytoplasm of the muscle cell of myocardium (fig. 2), sever congestion and fragment of the myocardium were observed (fig.3). Congestion of the capillary blood vessels between muscle fiber in addition to facular degeneration and fragmentation of muscle fiber (fig. 4, 5 and 6) were also observed in group T1. While microscopic examination of the cardiac muscle of rabbits treated with methionine plus PSO for 42 days (group T2) showed moderate edema between muscle fiber (fig.7) and no clear lesion were observed in the same group (fig.8) comparing to the methionine treated group Heart of the rabbits belongs to group of animal treated with PSO only (group T3) along the experimental period manifested normal structure of heart, besides no clear lesions were noted (fig. 9).

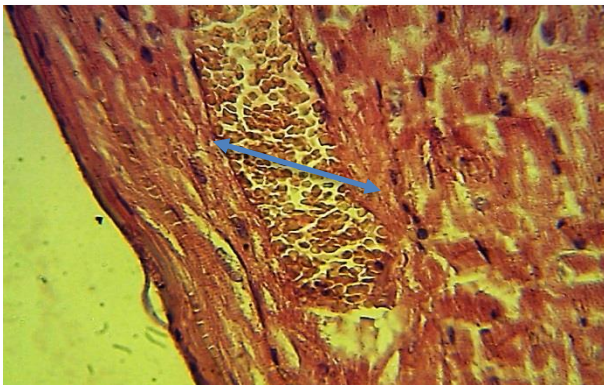The microscopic study of the aorta in group T1 which received methionine for 42 days showed histological changes represented by increase thickness of intima due to aggregation of facular cell in subintima (Fig.11), and an erosion of intima and inflammatory cells infiltration in subintima of the aorta (Fig. 12) comparing to the control (Fig.10). Section of aorta in rabbits of group T2 received methionine plus pomegranate seed oil (Fig.13 and 14) manifested normal structure of aorta and no clear lesion were observed comparing to the control group (Fig. 10). Besides, section of rabbits treated with pomegranate seed oil (group T3) showed no clear lesion (Fig. 15) comparing to the aorta of control group (Fig. 10). From the above results for histological section of the heart and aorta of rabbits of group T2 it should be manifested that pomegranate seed oil decrease the deleterious effect of the methionine over load on heart and aorta.



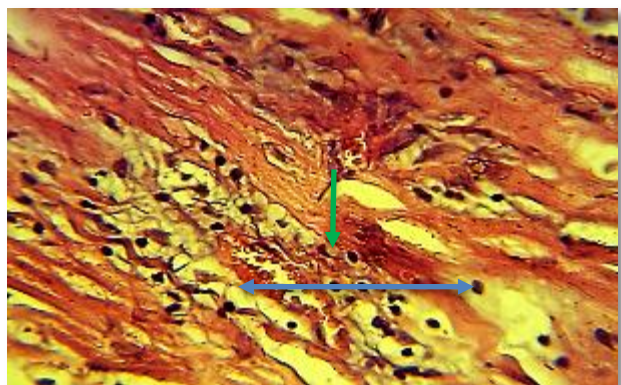
Figure,1: Section in the cardiac muscle of rabbits of control group. Note: no clear lesions (H&E stain 40X)



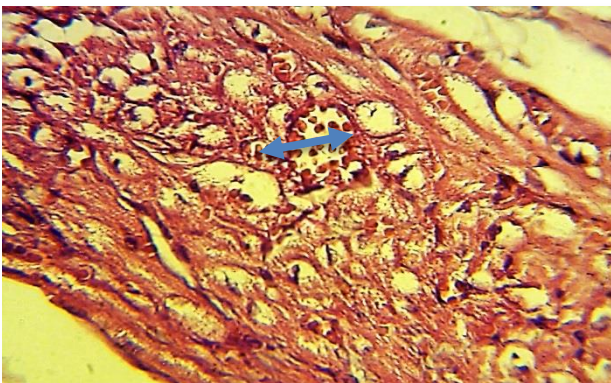
Figure,2: Section in the cardiac muscle of rabbit treated with methionine over load (T1) for 42 day show edema, RBCs and few neutrophils infiltration between cardiac muscle bundle, in addition to vacuolar degeneration of muscle cells (H &E stain 40X)



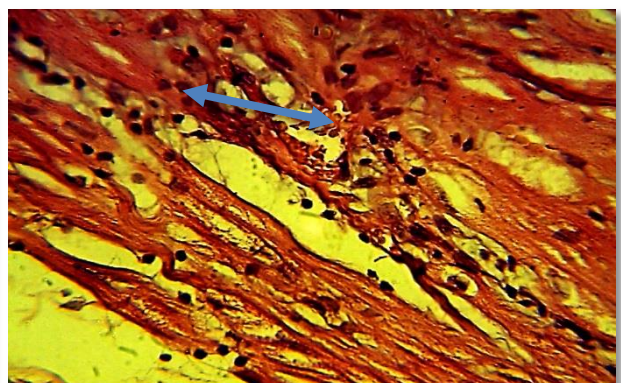
Figure,3: Section in the cardiac muscle of rabbit treated with methionine over load (T1) for 42 days show edema and severe congestion of blood vessels between cardiac muscle cells (H &E stain 40X).



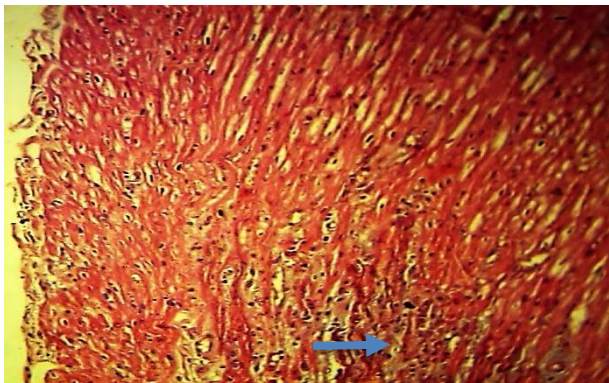
Figure,4: Section in the cardiac muscle of rabbit treated with methionine over load for 42 days (group T1). Note: inflammatory cells infiltration particularly neutrophils and macrophages and congestion capillaries blood vessels → in addition to vacuolar degeneration and fragment of muscle fiber ← (H &E stain 40X)



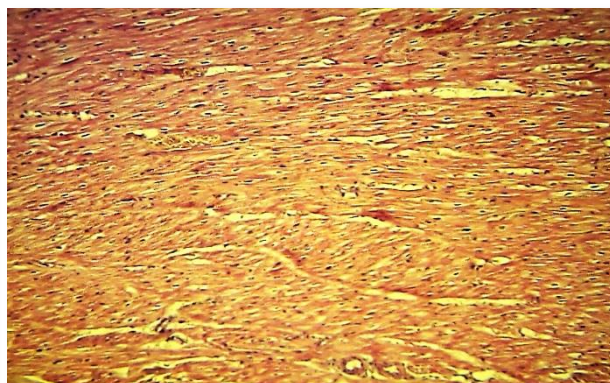
Figure,5: Section in the cardiac muscle of rabbit treated with methionine over load at the end of experiment (group T1). Note: congestion of blood vessels with inflammatory cells in their lumen as well as vacuolar degeneration of muscle cells (H &E stain 40X).



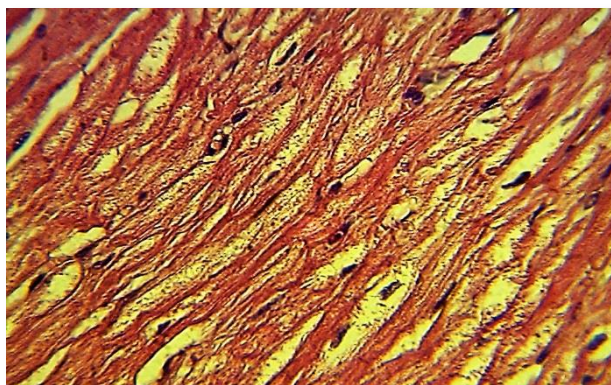
Figure,6: Section in the cardiac muscle of rabbit after 42 day of treatment with methionine over load (group T1). Note: congestion of blood vessels with inflammatory cells infiltration and fragment of muscle fiber (H &E stain 40X).



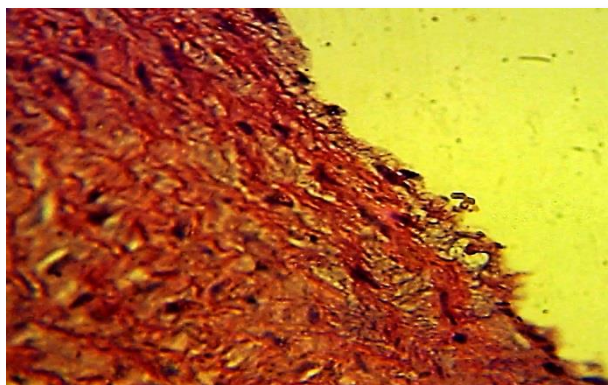
Figure,7: Section in the cardiac muscle of rabbit after 42 days of treatment with methionine over load and pometon (group T2). Note: moderate edema between muscle fiber (H &E stain 40X).



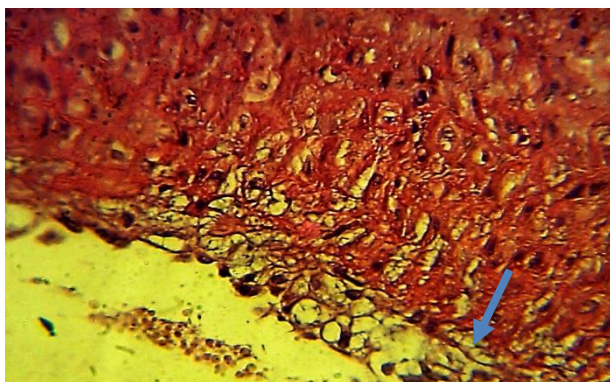
Figure,8: Section in the cardiac muscle of rabbit after 42 day of treatment with methionine over load and pometon (group T2). Note: congestion and no clear lesions (H &E stain 40X).



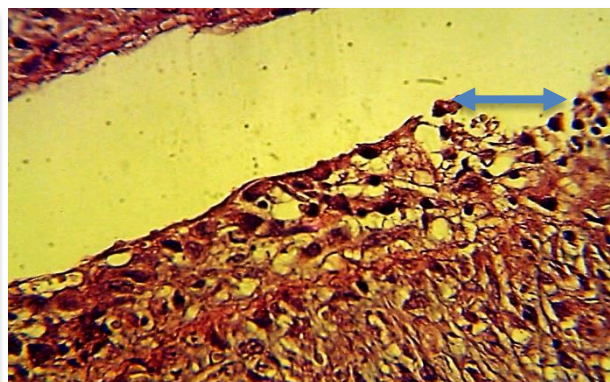
Figure, 9: Section in the cardiac muscle of rabbit treated with pometon (PSO) only for 42 day (group T3) . Note: no clear lesions (H &E stain 40X).



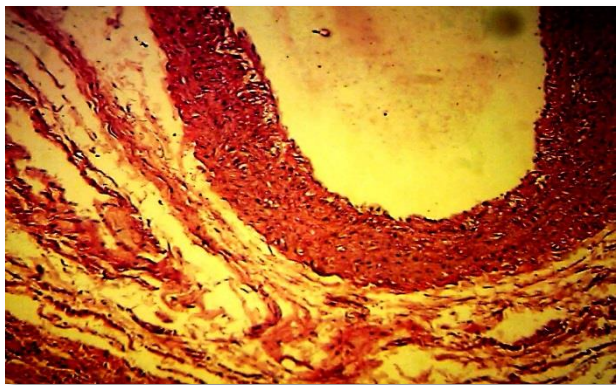
Figure,10: Section in the aorta of rabbit of control group shows no clear lesions (H&E stain 40X).



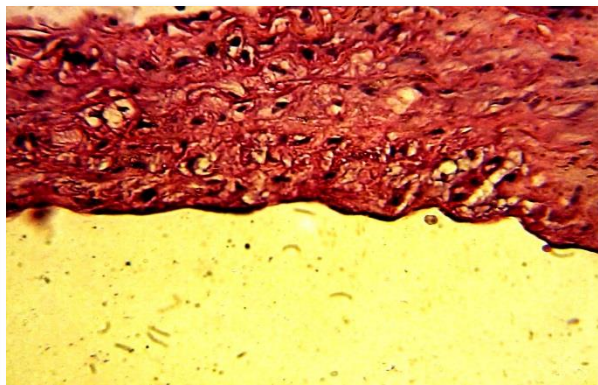
Figure,11: Section in the aorta of rabbit after 42 day of treatment with methionine over load (group T1) .Note: increase thickness of intima due to vacuolar cells aggregation in subintima (H &E stain 40X).



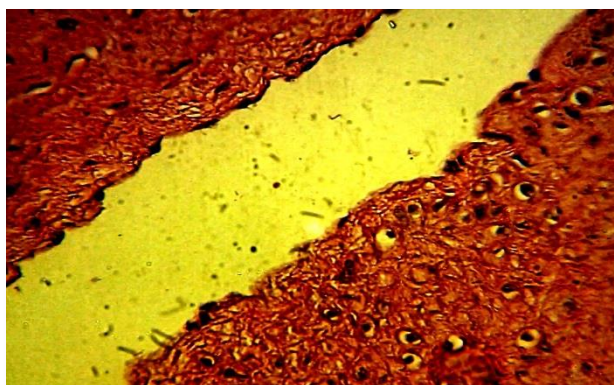
Figure,12: Section in the aorta of rabbit at after 42 of treatment with methionine over load (group T1).Note: increase thickness of intima, erosion and mononuclear cells infiltration in subintima (H &E stain 40X).



Figure,13: Section in the aorta of rabbit after 42 day of treatment with methionine over load and pometon (group T2) . Note: clear lesions (H &E stain 40X).



Figure,14: Section in the aorta of rabbit after 42 day of treatment with methionine over load and pometon (group T2). Note: no clear lesions (H &E stain 40X).



Figure,15: Histopathological section in the aorta of rabbit after 42 day of treatment with pometon (group T3) Note: no clear lesions (H &E stain 10X)

The present study pointed that intubation of rabbits with methionine (group T1) for 42 days, resulted in the appearance of athermanous lesion with structural changing in the aorta, suggesting that methionine overload in rabbits may be evoked HHcy, which impairs endothelium –dependent relaxation of vessels produced by mechanism associated with increased oxidative stress. The functional role of oxidative stress induced by free ROS like H₂O₂ in endothelial dysfunction and the resultant atheroma was reported (31-33). Besides, the occurrence of oxidative stress with methionine overload and corresponding a state of HHcy induced ROS (34).

The development of typical atherosclerotic or pre-atherosclerotic in all homocysteinemic animals is composed of proliferation of smooth muscle cells surrounded by large amount of collagen, elastic fibers, glycosaminoglycan and sometimes lipid (35

and 38), thereby HHcy leads to atherosclerosis and increased collagen production in a dose-dependent manner (37). In addition to an increase the arterial wall thickness, lead to loss of elasticity (38). Similar results are seen with HHcy which caused elastinolysis and decrease elastic compliance of the vessels (39), through an increase in inducible NOS activity as a key contributor to HHcy – mediated collagen / elastin switch and leading to decrement in aortic compliance. Additionally, HHcy is associated with vascular disease in general, but particularly in subjects with significant carotid stenosis (40).

HHcy stimulates the expression of myocytes to chemotactic protein -1, vascular cell adhesion molecule -1 and E-selection, this lead to increase monocyte adhesion to the aortic endothelium, which may contribute significantly to the development of atherosclerosis (41). It has been reported that

HHcy in rats produced by folate depletion impairs endothelium-dependent relaxation and is accompanied by increased arterial permeability and arterial stiffening (42). In contrast, the lesion observed in aorta and heart of rabbit supplementation with pomegranate seed oil for 42 days showed a lesser extent than in methionine overload rabbits (group T2).

Pomegranate seed oil may have had a potential antiatherogenic effect and reduce the size of lesion due to its antioxidant properties (43 - 45) which caused significant reduction in oxidative stress by inhibiting lipid peroxidation (43 and 46). The antioxidant capacity of PSO to alleviate the lesions in aorta and heart in group T3 may be due to photochemistry and pharmacological actions of pomegranate compounds which suggest a wide range of clinical application for the treatment and prevention of disease (47). Pomegranate reduced oxidation of serum LDL and increased PON-1 activity (48) due to the high concentrations of polyunsaturated fatty acids (PUFA) such as linoleic acid and linoleic acid, as well as other lipids (49 - 51). As well as, both punicalagin and punicalin can be hydrolyzed to ellagic acid; a natural phenol with high antioxidant activity, thus prolonging the release of this acid into the blood (46) may increase the antioxidants properties of PSO against atherosclerosis (52).

Furthermore, pomegranate fruit Pomegranate extract (PFE) rich in polyphenolic antioxidant, reduces the expression of oxidation-sensitive genes and increasing endothelial NO synthase (eNOS) (53), reduction in an aortic sinus and coronary artery atherosclerosis in mice by PSO has been documented (54). As well as its a meliorative effect on abnormality of ECG components induced by methionine overload has been proved in rabbits (55).

Recently, consumption of Pomegranate juice (PJ) by atherosclerotic mice caused significantly reduced cholesterol accumulation, foam cell progression of atherosclerosis. This may be due to the impressive inhibitory effect of pomegranate juice on macrophage cholesterol uptake and accumulation of cholesterol ester as evidence

by attenuation of cholesterol influx and by enhanced macrophages cholesterol efflux (56).

References

1. Shoob, H.; Reoger, D and Sargen, J. (2001). Dietary methionine is involved in the etiology of neural tube defect related pregnancies in humans. *Journal on nutrition*. 131: 2653.
2. Lewis, A. and Baley, H. (1995). Amino acid bioavailability of nutrients. *J. Agric. Food Chem.*, 35-65.
3. Hoeler, D.; Rademacher, M. and Mosenthin, R. (2005). Methionine requirement and commercial methionine sources in growing pigs. *Advances in pork production*, 16:109-117.
4. Mato, J.M.; Corrales, F.J.; Lu, S. and Avila, M. A. (2002). S-Adenosyl methionine synthesis: molecular mechanisms and clinical implications. *Pharmacol Thera.*, 73:265-280.
5. Olivero, M.; Ruggero, T.; Saviozzi, S.; Rosola, A.; Coltella, N.; Crispi, S.; Cunt, F.; Calogero, R. and Renzo, F. (2006). Genes regulated by hepatocyte growth factor as targets to sensitive ovarian cancer cells to cisplatin. *Mol. Ther.*, 5(5):1126-1135.
6. Van-Saun, R.; Callihan, B. and Tornquist, S. (2000). Nutritional support for treatment of hepatic lipidosis in Alms. *J. Amr. Veterinary Medical*, 217(10):1531-1535.
7. Mato, J.M.; Martinez-Chantar, M. and Lu, S.C. (2008). Methionine metabolism and liver disease. *Annu. Rev. Nutr.*, 28:273-293.
8. Schwab, U.; Torronen, A.; Meririnne, E.; Saarinen, M.; Alfthan, G.A. and Usitupa, M. (2006). Orally administered betaine has an acute and dose dependent effect on serum betaine and plasma Homocysteine concentration in healthy humans. *J. Nutr.*, 136:34-38.
9. Sundstrom, J. and Vasan, R. (2004). Homocysteine and heart failure. *Clin. Chem. Lab. Med.*, 43:53.
10. Suematsu, N.; Ojaimi, C.; Kinugawa, S.; Wang, Z.; Xu, X.; Koller, A.; Recchia, F.A., and Hintz, T.H. (2007). Hyperhomo-

- cysteinemia alters cardiac substrate metabolism by impairing nitric oxide Bioavailability through oxidative stress. *Circulation.*, 115:255-262.
11. Hillenbrand, R.; Hillenbrand, A.; Liewald, F. and Zimmermann, J. (2008). Hyperhomocysteinemia and carotid stenosis. *Cardiovascular Disorders.*, 8:1.
 12. Huliberg, B.; Berglund, M.; Anderson, A. and Frank, A. (2005). Elevated plasma Homocysteine in alcoholic in plasma Homocysteine with parallel increase in plasma S- Adenosyl. *Alcoholic. Clin. Exp. Res.*, 17:786-689.
 13. Robinson, G.; Narasimhan, S.; Weatherall, M. and Beasley, R. (2005). Raised plasma Homocysteine levels in alcoholism: increasing the risk of heart disease and dementia? *N Z Med J.*, 118:1190.
 14. Baccarelli, A.; Zanobetti, A.; Martinelli, L. Grillo, P.; Hou, L.; Guido, G.; Mannucci, P.; Pier Alberto, A and Schwartz, J.(2007). Air pollution, smoking, and plasma Homocysteine. *Envi. Health Per.*, 115:176-181.
 15. Collinges, B.; Raitakari, O.T.; Hutri-Kahonen, Juonala, N.M.; Mansikkaniemi, Collings, K.; Marniemi, J. A. and Viikari, J.S. (2008). The influence of smoking and homocysteine on subclinical atherosclerosis is modified by the connexin37 C1019T polymorphism - The Cardiovascular Risk in Young Finns Study. *Clin. Chem. Lab. Med.*, 46(8):1102-8.
 16. Kuo, H.K.; Sorond, F.A.; Chen, J.H.; Hashmi, A.; Milberg, W.P. and Lipsitz, L.A. (2005). The role of homocysteine in multisystem age-related problems: a systematic review. *J. Gero. .Sci .Med.*, 60:1190-1201
 17. Gatt, A.; Makris, A.; Cladd, H.; Burcombe, R.J.; Smith, J.M. ; Cooper, P.; Thompson, D. and Makris, M. (2007). Hyperhomocysteinemia in women with advanced breast cancer. *Inter. J. Lab. Hem.*, 29(6): 421-425.
 18. Symons, J.D.; Rutledge, J.C.; Simonsen, U. and Pattathu, R.A. (2006). Vascular dysfunction produced by Hyperhomocysteinemia is more severe in the presence of low folate. *Am. J. Phys. Heart. Circ. Physio.*, 290(1):181-191.
 19. Verhoef, P.; Pasman, W.; Van Vliet, T.; Urget, R. and Katan, M.(2007). Contribution of Caffeine to the Homocysteine rising effect of coffee: a randomized controlled trial in humans. *Am. J. Clin .Nutr.*, 76(6):1244-1248.
 20. Kukreja, R.C. and Hess, M.L. (1992).The oxygen free-radical system-From equations through membrane-protein interactions to cardiovascular injury and protection. *Cardiovasc. Res.*, 26:641-655.
 21. Dhalla, N.S.; Temsah, R.M. and Netticadan, T. (2000). Role of oxidative stress in cardiovascular diseases. *J. Hypertens.*, 18:655-673.
 22. Berry, C.E. and Hare, J.M. (2004). Xanthine oxidoreductase in the cardiovascular system: Molecular mechanisms and pathophysiologic implications. *J Physiol.* 555:589-606.
 23. Hare, J.M. and Stamler, J.S. (2005). NO/redox disequilibrium in the failing heart and cardiovascular system. *J. Clin. Invest.*, 115: 509-17.
 24. Li, H.G. and Forstermann, U. (2000). Nitric oxide in the pathogenesis of vascular disease. *J. Pathol.*, 190:244-254.
 25. Valko, M.; Leibfritz, D.; Moncola, J.; Cronin, M.; Mazura, M. and Telser, I. (2007). Free radicals and antioxidants in normal physiological functions and human disease. *Int. J. Biochem. Cell Biol.*, 39(1): 44-84.
 26. Facciola and Stephen. (1990). *Cornucopia: a Source Book of Edible Plants.* Kampong Publications,. pp. 166-167.
 27. Mirmiran, P.; Mohammad, R.F.; Golaleh, A.; Abbas, S. and Fereidoun, A. (2010). Effect of pomegranate seed on hyperlipidaemic subjects: A double-blind placebo-controlled clinical trial. *Br. J. Nutr.* 104(3):402-406.
 28. Esmailzadeh, A.; Tahbaz, F.; Gaieni, I.; Alavi-Majd, H. and Azadbakht, L. (2004). Concentrated pomegranate juice improves lipid profiles in diabetic patients with hyperlipidemia. *J. Med. Food Fall.*, 7(3):305-308.
 29. Davidson, M.H.; Maki, K.C.; Dicklin, M.R. Feinsein, S.B.; Witchger, M.; Bell, M.; McGuire, D.K.; Provost, J.C.; Liker, H. and

- Aviram, M. (2009). Effects of consumption of pomegranate juice on carotid intima-media thickness in men and women at moderate risk for coronary heart disease. *Am. J. Cardiol.*, 104(7):936-942.
30. Luna, L.G. (1968). Manual of histologic staining methods; of the Armed Forces Institute of Pathology. Edited by ,Armed Forces Institute of Pathology (U.S.)
31. Khudiar, K.K. (2000). The role of aqueous extraction of olive (*Allium Sativum*) in ameliorating the effects of experimentally induced atherosclerosis in rats. PhD Thesis, College of Veterinary Medicine, University of Baghdad.
32. Berndt, C.; Lillig, C.H. and Holmgren, A. (2007). Thiol –based mechanism of the thioredoxin and glutaredoxin systems: implications for disease in the cardiovascular system. *Am. J. Physiol. Heart Circ. Phys.*, 292: I227-I236.
33. Kokusho, Y.; Komaru, T.; Takeda, S.; Takahashi, K.; Koshida, R.; Shirato, K.; and Shimokawa, H. (2007). Hydrogen peroxide derived from beating heart mediates coronary microvascular dilation during tachycardia arteriosclerosis. *Thro. Vas. Bio.*, 27 :1057.
34. Kerkeni, M.; Addad, F.; Farhat, M.; Miled, A.; Trivin, F. and Maaroufi, K. (2008). Hyperhomocysteinemia and parameters of antioxidant defence in Tunisian patients with coronary heart disease. *Ann. Clin. Bio.*, 45:193-198.
35. Harker, L.A.; Ross, R.; Slichter, S.J. and Scott, C.R. (1976). Homocystine induced arteriosclerosis. The role of endothelial cell injury and platelet response in its genesis. *J. Clin. Invest.*, 58(3): 731–741.
36. Troen, A.M.; Lutgens, E.; Smith, D.E.; Rosenberg, I.H. and Selhub, J.(2003). The atherogenic effect of excess methionine intake. *100 (25): 15089–15094.*
37. Majors, A.; Ehrhart, L.A. and Pezacka, E.H. (1997). Homocysteine as a risk factor for vascular disease. Enhanced collagen production and accumulation by smooth muscle cells. *Arterioscler Thromb. Vasc. Biol.*, 17(10):2074-2081.
38. Booth, A.D.; Wallace, S.; McEniery, C.M.; Yasmin, B.J.; Jayne, D.R. and Wilkinson, I.B. (2004). Inflammation and arterial stiffness in systemic vasculitis: a model of vascular inflammation. *Arthritis Rheum. Feb.*, 50(2):581-588.
39. Steed, M.M. and Tyagi, S.C. (2011). Mechanisms of cardiovascular remodeling in hyperhomocysteinemia. *Antioxid. Redox Signal.*, 15(7):1927-1943.
40. Streifler, J.Y.; Rosenberg, N.; Chetrit, A.; Eskaraev, R.; Sela, B.A.; Dardik, R.; Zivelin, A. ; Ravid, B.; Davidson, J.; Seligsohn, U. and Inbal, A.(2001). Cerebrovascular Events in Patients With Significant Stenosis of the Carotid Artery Are Associated With Hyperhomocysteinemia and Platelet Antigen-1 (Leu33Pro) Polymorphism. *Stroke.*, 32: 2753-2758
41. Wang, G.; Woo, C.W.; Sung, F.L.; Siow, Y.L. and O, K. (2002). Increased monocyte adhesion to aortic endothelium in rats with hyperhomocysteinemia: role of chemokine and adhesion molecules. *Arterioscler Thromb Vasc Biol.*, 1;22(11):1777-1783.
42. Symons, D.; Mullick, A.E.; Ensunsa, J.L.; Ma, A.A. and Rutledge, J.C. (2002). Hyperhomocysteinemia evoked by folate depletion: effects on coronary and carotid arterial function. *Arterioscler Thromb Vasc Biol.*, 22(5):772-780
43. Aviram, M.; Dornfeld, L.; Rosenblat, M.; Volkova, N.; Kaplan, M.; Coleman, R.; Hayek, T.; Presser, D. and Fuhrman, B. (2000). Pomegranate juice consumption reduces oxidative stress, atherogenic modifications to LDL and platelet aggregation: Studies in humans and in atherosclerotic apolipoprotein E-deficient mice. *Am. J. Clin. Nutr.*, 71(5): 1062-1076.
44. Guo, C.J. (2003). Antioxidant activities of peel, pulp and seed fractions of common fruits as determined by FRAP assay. *Nutr Res.*, 23(12): 1719-1726.
45. Singh, R.P.; Murthy, K.N. and Jayaprakasha, G.K. (2002). Studies on the antioxidant activity of pomegranate (*Punica granatum*) peel and seed extracts using *in vitro* models. *J. Agric. Food Chem.*, 50(1): 81-86.
46. Dikmen, M.; Ozturk, N. and Ozturk, Y.(2011). The antioxidant potency of

- Punica granatum* L. Fruit peel reduces cell proliferation and induces apoptosis on breast
47. Lansky, E.P. and Newman, R.A. (2007). *Punica granatum* (pomegranate) and its potential for prevention and treatment of inflammation and cancer Journal of Ethnopharmacology., 109: 177–206
48. Aviram, M.; Rosenblat, M.; Gaitini, D.; Nitecki, S.; Hoffman, A.; Dornfeld, L.; Volkova, N.; Presser, D.; Attias, J.; Liker, H. and Hayek, T.(2004). Pomegranate reduces the intima media thickness size of the artery, while also reducing blood pressure and LDL oxidation. Clin Nutr., 23(3):423-433
49. Gil, M.I.; Tomàs-Barberà, F.A.; Hess-Pierce, B. ; Holcroft, D.M. and Kader, A.A. (2000). Antioxidant activity of pomegranate juice and its relationship with phenolic composition and processing. J. Agric. Food Chem., 48:4581–4589.
50. Kulkarni, A.P.; Mahal, H.S.; Kapoor, S.; Aradhya, S. M. (2007). *In vitro* studies on the binding, antioxidant, and cytotoxic actions of punicalagin. J. Agric. Food Chem., 55(1):491-500.
51. Vroegrijk, O.C.; Van Diepen, J.A.; and Vvan den Berg, S. (2011). Pomegranate seed oil, a rich source of punicalic acid, prevents diet-induced obesity and insulin resistance in mice,” Food and Chemical Toxicology, 49(6):1426–1430
- cancer. J. Med. Food, 14(12):1638-1646.
52. Sacheck, J. (2008). Pediatric obesity: an inflammatory condition? JPEN J. Parenter. Entera. Nutr., 32(6): 633-637.
53. De Nigris, F.; Balestrieri, M.L.; Williams-Ignarro, S.; D'Armiento, F.P.; Fiorito, C.; Ignarro, L.J. and Napoli, C.(2007). The influence of pomegranate fruit extract in comparison to regular pomegranate juice and seed oil on nitric oxide and arterial function in obese Zucker rats. Nitric Oxide., 17(1):50-4.
54. Al-Jarallah, A.; Igdoura, F.; Zhang, Y.; Tenedero, C.B.; White, E.J.; Macdonald, M.E.; Igdoura, S.A. and Trigatti, B.L. (2013). Pomegranate extract reduced aortic sinus and coronary artery atherosclerosis in SR-BI/apoE dKO mice. Atherosclerosis, 228(1):80-89.
55. Abdulla, L.N. and Al-Okaily B.N. (2014). Cardioprotective role of Pometone (Pomegranate seed oil) on electrocardio- graphy in methionine overload rabbits (Part I). Internat. Interdisciplinary J. 6: 21 – 36.
56. Kaplan, M.; Hayek, T.; Raz, A.; Coleman, R.; Dornfeld, L.; Vaya, J and Aviram, M. (2001). Pomegranate juice supplementation to atherosclerotic mice reduces macrophage lipid peroxidation, cellular cholesterol accumulation and development of atherosclerosis. J. Nutr. Aug., 131(8):2082-2089.

دور البوميتون (زيت بذور الرمان) في تقليل أذى فرط الميثيونين على بعض الجوانب النسيجية للقلب والأبهر في إناث الأرانب

براء نجم العقيلي و لقاء نجم عبدالله

فرع الفلسفة والأدوية، كلية الطب البيطري، جامعة بغداد

الخلاصة

صممت هذه الدراسة لمعرفة الدور الايجابي لزيت بذور الرمان في تقليل التأثيرات الضارة لفرط الميثيونين (كعامل مؤكسد) على بعض التغيرات النسيجية المرضية للعضلة القلبية في اناث الارانب البالغة. تم استخدام (32) من اناث الارانب وقُسمت عشوائياً إلى أربعة مجاميع متساوية وعوملت لمدة 42 يوم كالاتي: اعطيت المجموعة الأولى زيت الذرة وعدت كمجموعة سيطرة (C)، في حين جرعت حيوانات المجموعة الثانية (T1) فرط الميثيونين 100 ملغم/كغم من وزن الجسم، أما حيوانات المجموعة الثالثة (T2) فقد جرعت فموياً فرط الميثيونين 100 ملغم/كغم بالإضافة إلى زيت بذور الرمان بجرعة 30 ملغم/كغم من وزن الجسم، في حين جرعت حيوانات المجموعة الرابعة (T3) زيت بذور الرمان بجرعة 30 ملغم/كغم من وزن الجسم من وزن الجسم. في نهاية التجربة تم ذبح الحيوانات واخذت مقاطع من القلب والشريان الابهر لدراسة التغيرات النسيجية المرضية. بينت نتائج الفحص المجهرى للقلب والشريان الابهر للحيوانات المعاملة بفرط الميثيونين (T1) وذمة مع ارتشاح كريات الدم الحمراء والقليل من الخلايا الالتهابية الحامضية بين الياف العضلة القلبية، فضلاً عن انحطاط حويصلي لخلايا العضلة القلبية، احتقان الاوعية الدموية بين الياف العضلة القلبية، من جهة اخرى اظهر الفحص النسيجي وجود زيادة في سمك الطبقة الحشوية للأبهر، تآكل إضافة لارتشاح الخلايا وحيدة النواة في الطبقة تحت الحشوية للأبهر. في حين اظهر الفحص النسيجي للقلب والشريان الابهر لمجموعتي T2, T3 اختفاء التغيرات المرضية لنسيج الابهر وعودة نسيج الابهر الى التركيب الطبيعي مع وجود وذمة متوسطة بين الالياف العضلية القلبية لمجموعة (T2) مقارنة بمجموعة T1. يستنتج من هذه الدراسة ان لفرط الميثيونين تأثير ضار على العضلة القلبية والأبهر تمثل بحدوث تغيرات نسيجية مرضية وقد عزز الدور الوقائي للقلب لزيت بذور الرمان من خلال المحافظة على التركيب النسيجي الطبيعي للعضلة القلبية والأبهر.

الكلمات المفتاحية: زيت بذور الرمان، فرط الميثيونين، العضلة القلبية، الأبهر.