

Sonographic Findings In Scrotal Swellings

مشاهدات فحص السونار في حالات تورم كيس الصفن

Haider Najim Aubaid , Assistant Professor, F .I.B.M.S. and D.M.R.D, Radiology, College of Medicine, Kufa University. Radiologist in Al-Sadir Medical City, Najaf, Iraq. Email: haidernajim@yahoo.com

Raid Al-Garawy, Assistant Professor, F.I.C.S- Urosurgery, College of Medicine, Kufa University. Urosurgen in Al-Sadir Medical City, Najaf, Iraq.

Mohammed Hussien Hamed. D.M.R.D, Radiology. Al-Diwanya Teaching hospital, Al-Diwanya, Iraq.

Abstract

Background:

Based on physical examination alone, it is often difficult to decide whether a palpable scrotal swelling arises from testicle itself or from extra testicular elements in scrotum. **Aim of the study:** To evaluate the causes of scrotal swellings in different age groups using sonography.

Patients and method: One hundred patients, with age ranging between 1-77 years (mean age of 31 +/- 7 years), presented with scrotal swellings were examined by real-time ultrasound during the period from October 2011 to April 2012 in Al-Sadir Medical City at Al-Najaf government-Iraq

Results: Sonographic examination was normal (could not detect any lesion) in 7 patients (7%). The commonest sonographic finding was hydrocele (33.1%) while the next common findings were varicocele (20.3%) and epididymal cysts (14.4%). Inflammatory causes were detected in 14 patients (11.8%). Of the 8 (6.7%) patients with scrotal trauma, 5 cases showed features of hematocele and 3 cases extra-testicular hematoma. Least sonographic findings were testicular torsion, scrotal hernia and solid intratesticular mass (2.6% for each). Most of scrotal swellings were unilateral (right more than left) and 8% showed contralateral incidental findings.

Conclusion: Majority of causes of scrotal swellings were benign with the hydrocele being the commonest cause among all age groups. The least common causes of scrotal swellings were scrotal mass, hernia and testicular torsion. Although most of causes of scrotal swellings were benign, some were serious requiring urgent intervention, particularly testicular torsion, necessitating no delay in ultrasound examination for evaluation of patients with acute scrotal pain and swelling. To overcome limitations of this study, future study encompassing larger sample, including emergency cases, is recommended.

Keywords: Sonography, scrotal, testicular

المقدمة والأهداف:

بناءً على الفحص السريري وحده، غالباً ما يكون من الصعب تحديد ما إذا كان تورم كيس الصفن واضحاً ناشئاً من الخصية نفسها أو من العناصر الإضافية في كيس الصفن. تهدف هذه الدراسة إلى تقييم حالات تورم كيس الصفن بواسطة الفحص بالأمواج فوق الصوتية (السونار) وتحديد أسبابه في فئات عمرية مختلفة. **الطريقة:** شملت الدراسة مائة مريض في سن تتراوح بين 1-77 عاماً قدموا إلى شعبة السونار مع تورمات الصفن (اكتشفت سريريا) حيث تم فحصهم بواسطة السونار العالي الدقة خلال المدة من تشرين الأول 2011 إلى نيسان 2012 في مدينة الصدر الطبية في محافظة النجف الأشرف. **النتائج:** لم يظهر فحص السونار أية آفة أو سبب مرضي في 7 من كل المرضى الذين اقبلوا لتقييم تورم الصفن المكتشف سريريا. بالنسبة للمشاهدات الإيجابية، كان السبب الأكثر شيوعاً هو القيلة المائية (33,1%) تلاه الدوالي (20,3%) والكيس البريخي (14,4%)، والتهاب (11,8%) و الصدمات (6,7%). بينما شكل كل من التواء الخصية و الفتق الصفني و ورم صلب داخل الخصية الأسباب الأقل شيوعاً و بنسبة 2,6% لكل منها.

الإستنتاج: الغالبية العظمى من أسباب انتفاخ الصفن كانت حميدة وكانت القيلة المائية السبب الأكثر شيوعاً لدى مختلف الأعمار بينما أقل الأسباب الشائعة لتورمات الصفن كانت ورم الخصية و الفتق و التواء الخصية. بالرغم انه في معظم الحالات كان التورم في جانب واحد وخصوصاً على الجانب الأيسر الا انه وجدت مشاهدات في الجانب الاخر أيضاً (في 8%). **التوصيات:** رغم ان أكثر اسباب تورم كيس الصفن هي حميدة. الا انه منها ما هو خطير و يتطلب تدخل علاجي سريع (كالتواء الخصية) مما يدعو الى عدم التأخر في فحص حالات تورم كيس الصفن الحاد مع الالم بالسونار لتشخيص المشكلة في مرحلة مبكرة. توصي الدراسة أيضاً بإجراء دراسة أخرى في المستقبل على عينة أكبر و تشمل حالات طارئة أكثر من تورم كيس الصفن.

Background

Sonographic anatomy of the testis

The testes appear by ultrasound as oval structures having a homogeneous granular echotexture with uniform medium-level echoes. The mediastinum may be identified as linear echogenic band running superolaterally. The appendix of the testis may be identified on high resolution images, especially if outlined by fluid. The head of the epididymis is seen to rest on the upper pole posteriorly. The body of the epididymis is seen posterolateral to the testis, and the spermatic cord is medial to the epididymis. A small amount of anechoic fluid may surround the normal testis. The appendix of the epididymis may be seen if fluid is present⁽¹⁾.

The tortuous veins of the pampiniform plexus may be seen related to the cord above the upper pole. Slow venous flow can be demonstrated by colour Doppler techniques⁽¹⁾.

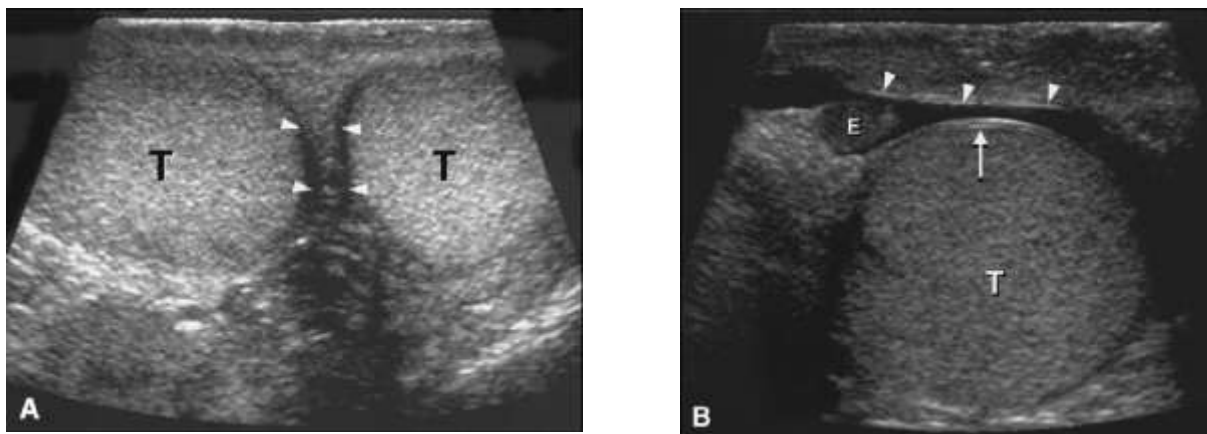


FIG. 1. Normal scrotal sonographic anatomical appearance A. The testes (T) with the median scrotal raphe (arrowheads). B. The tunica vaginalis (arrowheads) covering the scrotal wall and tunica albuginea (arrow) are seen. (E =epididymis).⁽¹⁾

Role of ultrasound in scrotal disease

There are wide range of causes of scrotal swellings and by using adequate history, clinical examination & laboratory tests differential diagnosis can greatly be narrowed, however to rule out the suspected cause, another investigation is required. Ultrasound is usually the modality of choice because of superficial location, making the scrotum is easy to be examined is well suited to study the scrotal content because it is simple to perform, rapid, non-invasive, relatively inexpensive, widely available and does not involve irradiation of gonads.⁽²⁾

These criteria in addition to the wide variability in the causes of scrotal swellings that enabled the ultrasound to be the first and the imaging modality of choice in evaluation of scrotal abnormalities, particularly emergency presentations⁽³⁾.

Objectives of the study

1. To determine the causes of scrotal swelling in our hospital using sonography.
- 2-To evaluate the relationship between patients demographics and sonographic findings in scrotal swellings.

Patients and Methods

This is a cross-sectional, prospective descriptive study done between October 2011 and April 2012, on 100 patients who were presented with scrotal swellings and referred from the urosurgical department and the outpatient clinic of Al-Sadir Medical City, for scrotal evaluation by ultrasound and /or color Doppler examination. Patients were questioned about the duration of swelling as well as presence of other symptoms of pain, tenderness, fever, history of trauma, infertility and history of undescended testis.

Ultrasound examination was performed by placing the patient in supine position with the scrotum supported on a rolled towel to hold the scrotum anteriorly, with another towel to hold the penis on the anterior abdominal wall. The inguinal region and para-aortic region were also scanned when indicated.

Patients were examined by either Siemens Acusion 500 or Toshiba istyle ultrasound devices with use of high resolution (7.5 MHZ) probes. Color Doppler sonography was performed on 52 cases, including those with varicocele, testicular torsion, epididymo-orchitis, testicular trauma and testicular masses.

In cases of suspected varicocele or hernia the patients were examined additionally in the erect position and during the Valsalva maneuver.

Results

A total of 100 patients with scrotal swellings were examined, with age range of 1 - 77 years. The third and fourth decades constituted 44% of all cases (table-1).

The most common clinical presentation was painful swelling (37%) followed by painless swelling (34%) while the remaining patients were complaining, in addition to the swelling, from infertility (17%), pain and fever (4%) and history of local trauma (8%) as represented in figure (2).

As seen in table-2, 7 (7%) of the referred patients were normal and some patients of the remaining positive 93 cases, presented with one or more pathological findings in the same or other side (for example hydrocele and epididymal cyst) so that a total of 111 sonographic findings were seen in the 93 patients. The abnormal findings were right sided in 44% , left sided in 41% and bilateral in 15% of cases.

Hydrocele was the commonest ultrasound finding (33.1%), followed by varicocele as the 2nd common finding (20.3%), epididymal cysts (14.4%), inflammatory causes(11.8%), while testicular focal lesions, testicular torsion and scrotal hernia were the least common (2.6% for each) findings. Table (3).

Regarding the relation of findings to age of patients (table 7), although hydrocele was the commonest finding in all age groups, the most frequently affected were those between 31-40 years (25.6%). Table (3).

Most common age for varicocele was 21-30 year (50% of varicocele cases). Epididymal cysts were mostly seen at 41-50 years age group (29.4%). Table (3).

Inflammatory cause of scrotal swellings was most commonly seen in 11-20 and 41-50 age groups (28.5% for each). Table (3).

In patients with scrotal trauma, hematocele was found in 62.5% followed by extra-testicular hematoma in 37.5%, (table-4).

Table (1) Age group classification of the studied patients.

Age group	Number of cases	Percentage
1-10	14	14.0%
11-20	8	8.0%
21-30	22	22.0%
31-40	22	22.0%
41-50	17	17.0%
51-60	11	11.0%
61-70	3	3.0%
71-80	3	3.0%
Total	100	100%

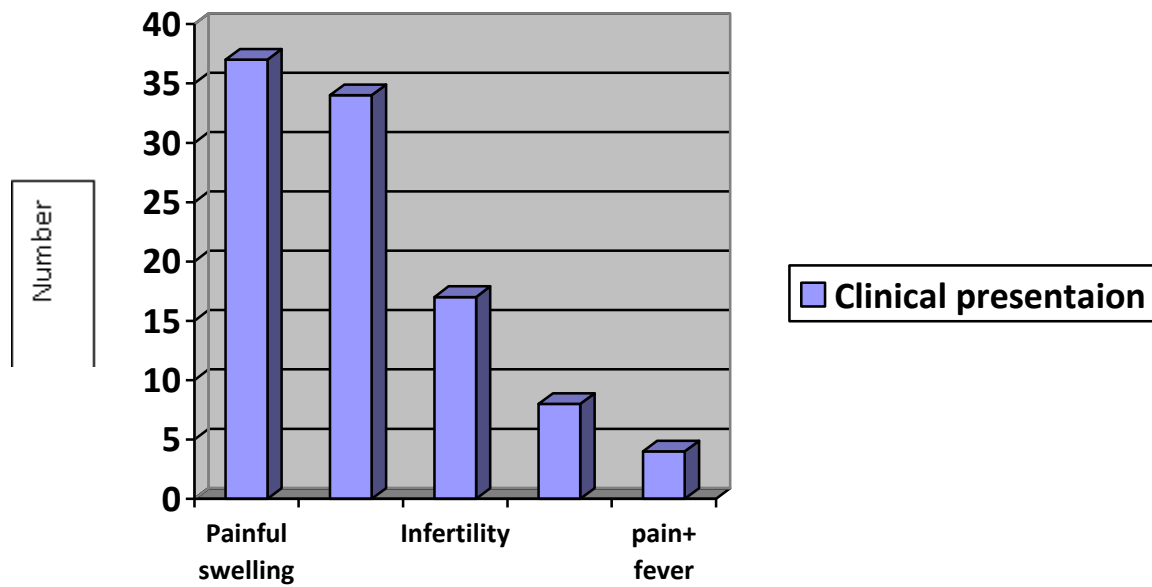


Figure (2): Distribution of patients according to the prevalence of clinical presentation.

Table(2): Distribution of findings according to side affected

Findings	Right	Left	Bilateral	Total	%
Hydrocele	21	8	10	39	33.1%
Varicocele	-	20	4	24	20.3%
Scrotal hernia	3	-	-	3	2.6%
Torsion	1	2	-	3	2.6%
Epidydmitis	4	2	1	7	5.9%
Epidydm- orchitis	5	2	-	7	5.9%
Testicular focal lesion	2	1	-	3	2.6%
Epidydmal cyst	9	7	1	17	14.4%
Hematoma	4	4	-	8	6.7%
Normal (no lesion deteced)	-	-	-	7	5.9%
Total	49	46	16	118	100%

Table(3) :Distribution of sonographic findings according to the age of patients.

Age years	Hydrocele		Varicocele		Scrotal hernia		Torsion		Epididymitis		Epididymorchitis		Epidyd. Cyst		Test. focal lesion		hematoma		Normal	
	N	%	N	%	N	%	N	%	N	%	N	%	N	%	N	%	N	%	N	%
1-10	8	20.5	0	0	0	0	0	0	1	14.3	0	0	0	0	0	0	3	37.5	3	42.8
11-20	3	7.7	2	8.3	0	0	2	66.7	1	14.3	2	28.5	0	0	0	0	0	0	1	14.3
21-30	4	10.3	12	50	2	66.7	1	33.3	1	14.3	1	14.3	2	11.8	0	0	3	37.5	1	14.3
31-40	10	25.6	5	20.8	1	33.3	0	0	1	14.3	1	14.3	3	17.6	1	33.3	2	25	1	14.3
41-50	7	17.9	4	16.7	0	0	0	0	2	28.5	2	28.5	5	29.4	1	33.3	0	0	0	0
51-60	4	10.3	1	4.2	0	0	0	0	1	14.3	0	0	4	23.5	0	0	0	0	1	14.3
61-70	2	5.1	0	0	0	0	0	0	0	0	1	14.4	1	5.9	0	0	0	0	0	0
71-80	1	2.6	0	0	0	0	0	0	0	0	0	0	2	11.8	1	33.4	0	0	0	0
TOTAL	39	100	24	100	3	100	3	100	7	100	7	100	17	100	3	100	8	100	7	100

Table 4: Sonographic findings in post traumatic scrotal swellings.

U/S Finding	N	%
Extra-testicular hematoma	3	37.5
Hematocele	5	62.5
Intratesticular hematoma	0	0
Total	8	100

Discussion

Regarding the side of lesions, 8 cases were referred as unilateral scrotal swelling clinically while on ultrasound examination, incidental findings were seen on the contralateral asymptomatic side. Minayoshi et al⁽⁴⁾, showed that the left side was affected in 78-93% of cases of varicocele, while bilateral varicoceles occurred in 7-22% and this was consistent with this study where left sided varicocele constituted 83.33% and bilateral varicocele constituted 16.67% of patients.

Inflammatory scrotal processes tend to be unilateral, with slight Rt. sided predominance while testicular torsion has a Lt. sided predominance and no side predilection for tumors⁽⁵⁾, our study also found inflammatory scrotal swellings to be unilateral in 92.28% of cases, with the right side affected in 69.23% and of all testicular torsions, 66.66% were on Lt. side too. In contrary, our study showed a right sided predilection for focal testicular masses (66.66%), although this could not be considered of statistical significance because they were few (3 cases only) and were not confirmed histopathologically.

Sonographic findings:

1. Hydrocele. Imaging is important in large hydrocele with query underlying malignancy in the testis (which is not palpable)⁽⁶⁾. Hydrocele were the most common fluid collection of the scrotum in this study and was consistent with finding of Krone K.D et al⁽⁷⁾.

Regarding echogenicity of hydrocele, finding of an anechoic hydrocele in 56.41% of patients and a hydrocele with internal echoes in 23.07% in this study, was generally close to that of Black et al⁽⁸⁾.

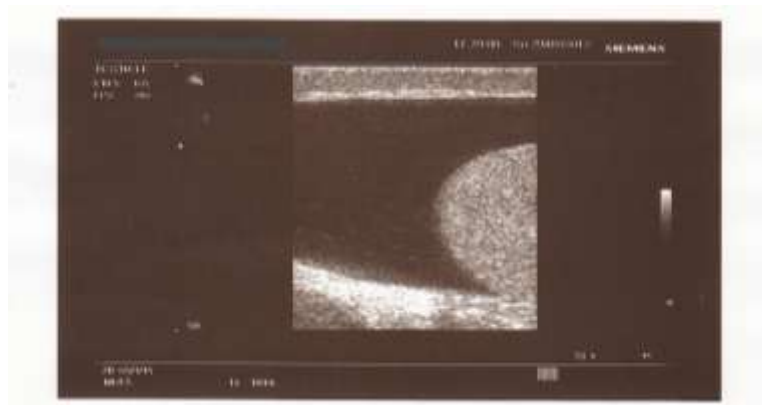

Figure 13-Hydrocele in a 42 years patient with painless Rt. Scrotal swelling.

2. Epididymal cysts. Epididymal cysts and spermatoceles are probably the most common abnormalities identified on the epididymal sonography and can be seen in adults of all ages⁽⁸⁾. In a study on 75 patients done by Joseff L.⁽⁹⁾, epididymal cysts constituted 8% of scrotal swellings which was less than this study (14.4%).

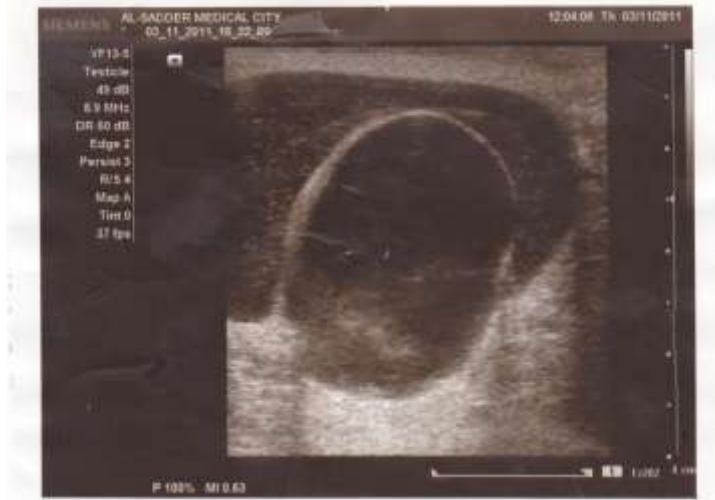

Figure -14-Epididymal cyst: painless RT scrotal swelling in 41 years patient.

3. Scrotal hernia. The prevalence of hernias in this study (2.6%) was less than in Joseff L . study(10%)⁽⁹⁾, may be due to difference in age of patients included in either studies.

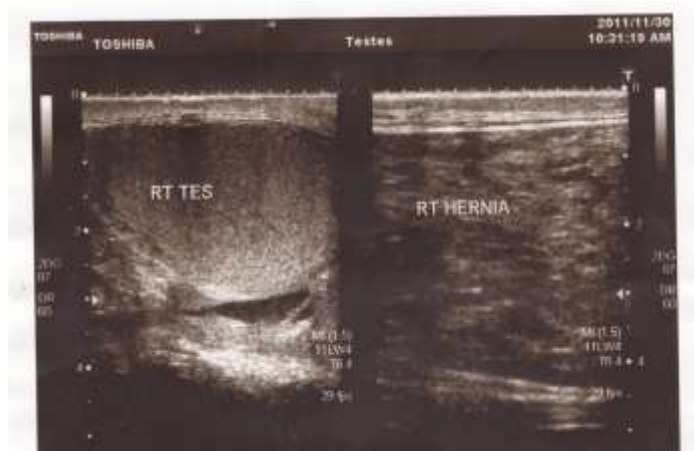

Figure-15- A case of Rt. scrotal hernia.

4. **Traumatic swellings.** Joseff L.⁽⁹⁾ found two patients (66.7%) of traumatic scrotal swelling to have an extra-testicular hematoma that is less than this study which showed 3 cases (37.5%) with extratesticular hematoma. Five patients of traumatic scrotal swelling (62.5%) showed a hypoechoic non-homogeneous area with internal echoes between the two layers of tunica vaginalis, consistent with diagnosis of hematocele⁽¹⁰⁾

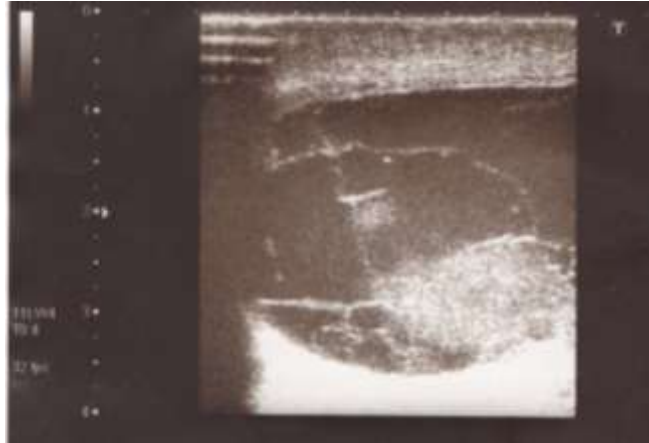


Figure 16- Hematocele in a 8 years child after trauma.

5. **Testicular Focal lesions.** The sonographic appearance of intra-testicular masses is more often focal and hypoechoic⁽¹¹⁾, which is comparable with our study where all the visualized testicular lesions were hypoechoic and focal, although their exact nature was not proved histopathologically.

Three patients (2.6 %) diagnosed by ultrasound and color Doppler as solid masses, where the lesions appeared hypoechoic and homogenous with a pseudocapsule (which is demonstrated as an echogenic band surrounding the mass). On color Doppler they were hypervascular in comparison with the normal testicular parenchyma and this coincides with the ultrasonic appearance of seminoma according to Gerscovich E.⁽¹²⁾

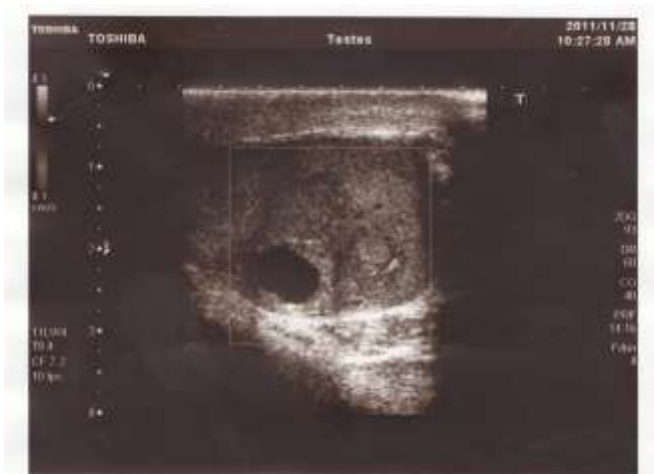

Figure 17- A case of hypervascular intratesticular mass

6.Inflammation.The enhanced diagnostic accuracy of color Doppler imaging compared with clinical assessment alone has highlighted that epididymo-orchitis is the principal etiology of acute scrotal pathology and that acute torsion is a less common cause than what was previously thought⁽¹³⁾.

In this study, 14 patients (11.8%) showed findings of inflammation, with the 3rd and 5th decades of life having the highest incidence (28.5%). This agreed with other studies where epididymitis and epididymo-orchitis were most common after puberty^(14&15)

Comparative study had been done in Iraq on 2001⁽¹⁶⁾ showed that 14% of scrotal swellings were caused by inflammatory process which is rather higher than this study (11.8%). Ten patients (71.42%) gave a history of urinary tract infection , while the remaining four (28.58%) had no previous history of any underlying pathology.

Reactive hydrocele is often present and thickening of the scrotal skin may be seen in cases of epididymo-orchitis⁽⁸⁾ supporting this study where the associated reactive hydrocele & scrotal wall thickening have been seen in 64.42% & 42.85% of patients respectively.

Seven patients (50%) were diagnosed as acute epididymitis. All of them showed a swollen and poorly echogenic epididymis with a normal testis. The remaining 7 patients (50%) showed sonographic features of epididymo-orchitis, the epididymis and testis were large with of decreased echogenicity with increased vascularity on colour imaging.

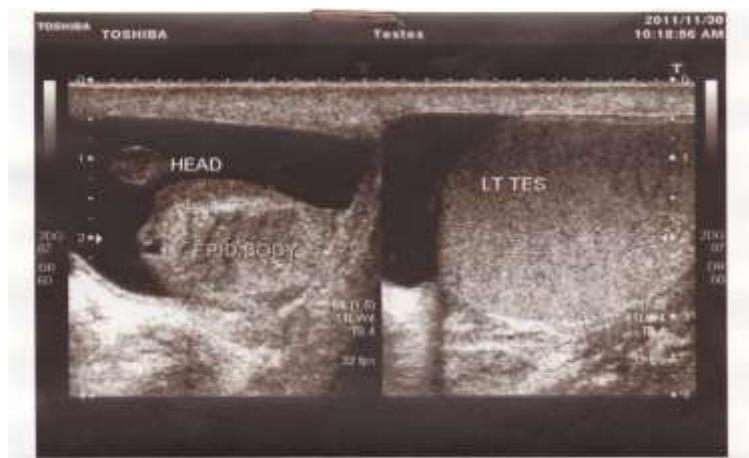


Figure 18-A cases of epididymo-orchitis.

7. Testicular torsion.Because one of the important roles of duplex ultrasound is the early detection of serious but reversible diagnoses like testicular torsion where treatment is greatly dependable upon time factor, it is considered as the primary and first line investigation in evaluation of acute scrotum^(17 & 18). Yagil Y. et al reported a high validity for Doppler ultrasound in the diagnosis of testicular torsion during evaluation of acute scrotum⁽¹⁹⁾

In this study, only 3 patients (2.6%) were diagnosed as testicular torsion and proved by surgery. This small number of testicular torsion cases may be because the study did not include those patients who present at late day time and night to emergency unit and /or those who had only scrotal pain without swelling.

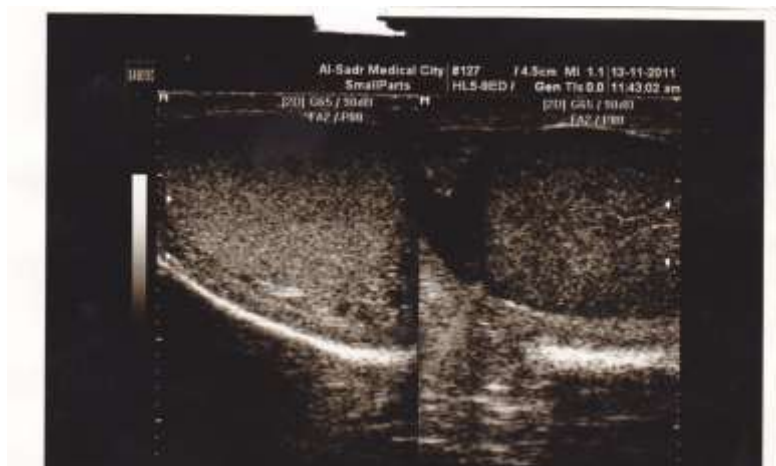

Figure 19- A case of left testicular torsion.

8. Varicocele. Physical examination has limited sensitivity & specificity & less accurate in diagnosis of varicocele compared to ultrasonography (25). In current study, ultrasonography detected features of a varicocele in 24 patients (20.3%), 18 of them (75%) presented as painless scrotal swelling while 17 (70.83%) had an associated infertility. Four patients (16.7%) showed bilateral varices while no case was seen purely on Rt side.

Primary varicoceles occur usually between the ages of 15 and 25 years⁽¹⁵⁾. This study showed that 50% and 20.8% of patients with varicoceles presented in the 3rd and 4th decades respectively. Mohammed⁽¹⁶⁾ showed a very close results with 71.2% of cases presented in the 3rd and 4th decade.

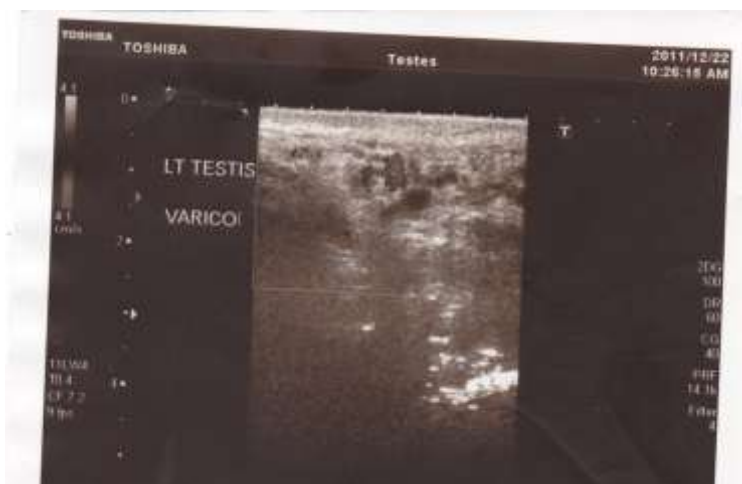

Figure 20- A case of Lt. sided varicocele, showing dilated & tortuous pampiniform venous plexus.

Conclusions and recommendations

The largest number of patients with scrotal swelling was within the 21-40 year age group. The most common cause of scrotal swellings and in all age groups was hydrocele. The least common causes of scrotal swellings were scrotal mass, hernia and testicular torsion respectively. In most cases of scrotal swellings, the abnormality was unilateral and more on the right side.

A future study that encompasses larger sample and at wider time range to include acute emergency cases, is recommended.

References:

- 1-Stephanie R., Michelle M., Stephen E. The testis, epididymis and spermatic cord. Anatomy for diagnostic imaging, 2nd edition 2004-232-235
- 2- O'Mara EM, Rifkin MD. Scrotum and contents. In: Resnick MI, Rifkin MD, eds. Ultrasound of the Urinary Tract, 3rd ed. Baltimore: Williams & Wilkins; 2006:386–435.
- 3-Blaivas M, Sierzenski P, Lambert M. Emergency evaluation of patients presenting with acute scrotum using bedside ultrasonography. Acad Emerg Med. 2001;8(1):90-93.
- 4- Minayoshi K.E., Okoda 14.1., Fujisawa M.A., et al. Hemodynamic evaluation of left testicular varicocele by scrotal scintigraphy. Eur. Urol 2001 ;39:030-035.
- 5- Brigitte M., MD, and Jacqueline C., MD. Ultrasonography of the acute scrotum. J. Clin Ultrasound 1997; 15: 37-44.
- 6- Hricak H, Frilly RA. Sonography of the scrotum. Invest Radiol. 1993; 18: 112-121.
- 7- Krone K.D., Carroll B.A. Scrotal ultrasound. Radiol Clin North Am. 1995; 23 : 121-139
- 8- Black J.A.R. & Pate A. Sonography of the abnormal extratesticular space. AJR 1996;167:507-511.
- 9- Joseff L. The role of ultrasound and color Doppler in the evaluation of scrotal swellings,. Unpublished thesis presented to Iraqi Board of medical specialization, 2006. Chapter 6, pages-44-45.
- 10- Gutman H; Golimbu M; Subramanyam B. R. Diagnostic ultrasound of scrotum. Urology: 1998 27(1). 72-79.
- 11- Wayne C. L. Scrotum in: Diane M-Kawamura. Diagnostic medical sonography, abdomen & superficial organ. 2 ed. New York. Lippincott, 1997;719-764.
- 12- Gerscovich E.O. High- resolution ultrasonography in the diagnosis of scrotal pathology: II. Tumors. J Clin. Ultrasound. 1993; 21: 375-386.
- 13- Groski M. , Holiman A. S.. The acute paediatric scrotum. EJR 1998; 6:183-193.
- 14-. Feld R., Middleton WD. Recent advances in sonography of the testis and scrotum. Radiol Clin. North Am. 1992; 30: 1033-1051.
- 15- Stewart R., Carrll B.A. The scrotum . In Diagnostic ultrasound, vol 1. St. louis, Mosby yearbook; 1991.
- 16- Mohammed A. K. The role of ultrasound and color Doppler in the evaluation of scrotal lesions, Diploma thesis , medical college ,Baghdad University ,2001 (unpublished thesis presented to Baghdad university in high diploma in radiology).
- 17-Vijayaraghavan SB. Sonographic differential diagnosis of acute scrotum: real-time whirlpool sign, a key sign of torsion. J Ultrasound Med 2006; 25:563–574.
- 18-Schalamon J, et al. Management of acute scrotum in children: the impact of Doppler ultrasound. J Pediatr Surg. 2006; 41:1377–1380.
- 19- Yagil Y. et al . Role of Doppler Ultrasonography in the Triage of Acute Scrotum in the Emergency Department J Ultrasound Med 2010; 29:11–21
- 20- Sakamoto H, et al. Color Doppler ultrasonography as a routine clinical examination in male infertility. Int J Urol. 2006 Aug;13(8):1073-8.