

Estimation of some oxidative stress parameters in the serum and cerebellum of ovariectomized rats

قياس بعض معايير الاجهاد التاكسدي في مصل ومخيخ الجرذان مزالة المبايض

Al-Bazii W.J

Environmental Health department ,college of Applied Medical science ,university of Kerbala

Abstract

There is growing evidence that oxidative stress and estrogen deprivation after menopause or ovariectomy represent two main risk factors closely related to the development of Alzheimer's disease .The aim of this study was to evaluate the effect of ovariectomy on some oxidative stress markers and pathological lesions in the cerebellum of adult rats. Twenty rats were randomly divided into two groups (10/group) control(C) and overctomized group (OVX).After three months estimated levels of Malondialdehyde(MDA), Nitroxide (NO) and glutathione peroxidase (GPX) in the serum and cerebellum and sections of the cerebellum was removed histopathological study . The results Showed a significant increase ($P<0.05$)in the (MDA), (NO) and (GPX) levels and significant decrease($P<0.05$) in (GSH) level and(CAT) activity in the serum and cerebellum tissue of the overctomized group compare with that in the control group . The microscopical examination was shown in the cerebellum tissue in the overctomized group characterized by decrease in the purikinje and granular cells in the gray matter . Vacuoles were present in the white matter with microglial cells infiltration in the pia mater .For conclusion The overctomy in adult rats an showed increase in the oxidative stress markers and pathological lesions in the gray and white matters in the cerebellum .

Key words :- Overctomized, Oxidative stress , Cerebellum ,rats .

الخلاصة :-

إن انخفاض مستوى الايستروجين بعد فترة سن اليأس او إزالة المبايض يشكل عامل خطورة للإصابة بمرض الازهايمر . هدف الدراسة :- دراسة تأثير إزالة المبايض على بعض معايير الاجهاد التاكسدي والافات المرضية في مصل الدم ونسيج المخيخ .

مواد وطرائق العمل :- قسمت عشوائيا 20 من اناث الجرذان البالغة الى مجموعتين (10/مجموعة) اعتبرت الاولى مجموعة سيطرة (C) وتم ازالته المبايض المجموعة الثانية (OVX) ، وبعد مرور ثلاثة اشهر تم قياس مستوى المالنديهايد MDA واوكسيد النتترات NO وفعالية انزيم الالكاتيليز CAT و انزيم بيروكسيد الكلوتاتايون GPX في مصل الدم ونسيج لمخيخ . النتائج :- بعد مرور ثلاثة اشهر من التجربة لوحظ زيادة معنوية ($P<0.05$) في مستوى ال MDA ، NO و GPX وانخفاض معنوي ($P<0.05$) في مستوى فعالية انزيم الكاتيليز CAT في مصل الدم ونسيج المخيخ لاناث الجرذان مزالة المبايض مقارنة مع السيطرة ، ام بالنسبة للفحص النسجي لوحظ قلة في اعداد خلايا بركينجي والخلايا الحبيبية في المادة السنجابية مع وجود حويصلات في المادة البيضاء وارتشاح للخلايا الدبقية في نسيج الام الحنون . الاستنتاج : ان إزالة المبايض في اناث الأرانب البالغة تؤدي الى زيادة في دلالات الإجهاد التاكسدي والافات المرضية في المادة السنجابية والبيضاء في المخيخ .

مفتاح الكلمات :- ازالة المبايض ، الاجهاد التاكسدي ، المخيخ ، الجرذان

Introduction

Oxidative stress is a state of imbalance in favor of pro-oxidants versus antioxidants ,resulting in cellular damage that is often irreversible and can be observed in disease such as Osteoporosis, respiratory disease ,atherosclerosis ,chronic renal failure ,diabetes mellitus and Alzheimer disease(1,2). The nervous system – including the brain, spinal cord, and peripheral nerves – are rich in both unsaturated fatty acids and iron. The high lipid content of nervous tissue, coupled with its

high aerobic metabolic activity, makes it particularly susceptible to oxidative damage .Neurodegenerative disorders remain an important source of morbidity and suffering for the human(3).The oxidative stress is increased and some antioxidants are decrease in relation to menopause in which estrogen diminishes (4,5,6), oxidative stress may play an important role in the pathology of postmenopausal disease and that supplementation with antioxidants may be beneficial in the treatment of these conditions(7,8)

Analyses of memory function in postmenopausal women indicate that estrogen replacement therapy given immediately following surgically induced menopause can prevent memory deficits induced by a loss in circulating estrogen (9). In fact, changes in cognitive functioning have long been associated with menopause (10). The impact of estrogen on the mechanisms of memory in both animals and humans (11). Estrogen has been shown to be equivalent in potency and efficacy to the commonly known antioxidant atocopherol (vitamin E) and this has been suggested as protective mechanism, whereby estrogen may help control ,the onset or progression of AD.

Menopause is a risk factor in initiation of Alzheimer disease and cardiovascular disease as result of estrogen deprivation (12).Estrogen promote neural repair and regeneration and it is also reduce oxidative damage and increase cerebral blood flow (13,14). Generation of highly reactive oxygen species (ROS) is an integral ,feature of normal cellular function like mitochondria respiratory chain , phagocytosis , arachidonic acid metabolism ,ovulation , fertilization also ROS released from many pathological noxious stimuli to the cerebral tissues (15). The high lipid content of nervous tissue coupled with its high aerobic metabolic activity makes it particularly susceptible to oxidative damage ,increase iron caused by brain cell injury(16,17). Brain rich in catecholamines , adrenalin ,nor adrenaline and dopamine can consecountly break down to free radicals or can be metabolized to radicals by endogenous enzymes such as MAO (Monamin oxidase) (3). Biological systems have evolved with endogenous defense mechanisms to help protect against free radical induced cell damage(4,18) Damage due to free radicals caused by ROS leads to several damaging effects as they can attack lipids, protein/ enzymes, carbohydrates, and DNA in cells and tissues. They induce undesirable oxidation, causing membrane damage, protein modification, DNA damage, and cell death induced by DNA fragmentation and lipid peroxidation (19)

The central nervous system is specially sensitive to free radicals oxidative damage in the brain high consumption of oxygen rich content easily oxidizable fatty acids with low content of antioxidant and high iron make it a prime substrate for damage by free radicals (20). The mechanism of action of the neuroprotective antioxidant activity of estrogens is dependent on the presence of the hydroxyl group in the C3 position on the A ring of the steroid molecule (21) . The main objective of the present study was to evaluate the effect of estrogen deprivation in the spinal cord of ovariectomized rats by estimation of some oxidative stress parameters like MDA, GSH ,GPX , NO levels and CAT enzyme levels in cerebellum tissue and in the serum .

Material and methods

A total of 20 three-month-old female rats (200–250 gm) were obtained from the animal house of Bagdad university . The animals were kept in cages at room temperature with 12-hour light and dark cycle. The rats were allowed to access water ad libitum and standard animals chow. After three weeks of acclimatization, the rats were randomly divided into two groups with ten animals each group, control group (C) and ovariectomized animals group (OVX) .

The rats were ovariectomised, under anaesthesia with intramuscular injection of combination of xylazil (50mg/kg), ketamin (50mg/kg) and xylazine (6mg/kg). The lower part of the back was shaved and a single 1.5 to 2 cm incision was made in the skin to expose the back muscles. A small 1 to 2 cm incision was made in the muscles overlying the ovaries on both sides, and the ovaries were isolated, tied off with sterile suture, and removed. The muscles and the skin were sutured separately, To prevent wound damage from other animals .Theses were caged separated for post surgery and care was given by daily wounds cleaning with povidone iodine and treated with antibiotic ampicillin 5% intramuscularly for 7 days .

Ninety days after surgery , overnight fasting, 5ml Blood samples were collected by cardiac puncture in plane tubes from all rats. The blood sample tubes were centrifuged at 3000 rpm for 2-5 minutes then serum separated to be stored at (-20°C) to determine GSH,GPX, NO and MDA and CAT enzyme in the serum. Cerebellum removed and (0.5 g) was homogenized in ice-cold physiological phosphate buffer, pH 7.4. The homogenate was hydrolysed by 3.4 M NaOH solutions to release MDA, which was bound to the membrane phospholipids. This was followed by the addition of 3.4 M HClO₄ and centrifugation at 10 000 xg for 10 min. The supernatant obtained was used for the determination of lipid peroxidation as reported (22). Two ml of glacial acetic acid and 2 ml of 1% thiobarbituric acid were added to 0.2 ml of the supernatant. The tube was stoppered loosely and immersed in boiling water for 15 min and swirled slightly at intervals; the mixture was cooled and centrifuged at 5000 xg at room temperature for 10 min. The absorbance of the supernatant obtained was read at 532 nm against the reagent blank.

All analytical methods such as, photometric enzymatic, flourometric and HPLC methods, that was used to determine tissues homogenate, erythrocyte and serum glutathione (GSH) depend on the action of sulfhydryl groups . Principle:- 5, 5 Dithiobis (2-nitrobenzoic acid) (DTNB) is a disulfide chromogen that is ready reduced by sulfhydryl group of (GSH) to an intensity yellow compound . The absorbance of the reduced chromogen is measured at 412 and is directly proportional to the GSH concentration.(23).

Crebellum and serum glutathione peroxidase (GPx) was determined colorimetrically according to the method of (24)using NADPH-coupled reduction of GSSG catalyzed by GR which can be measured at 340 nm.

- Cerebellum and serum catalase (CAT) activity was determined colorimetrically , according .to the method of (25). The assay is based on catalase–catalyzed reaction of a known quantity of H₂O₂ with DHBS and AAP to form a chromophore, which has a color intensity inversely proportional to the amount of catalase in the original sample which can be measured at 510 nm.

For histological studies sections of the cerebellum was removed and impressed in 10% neutral buffered formaldehyde for 24 hours. Serial coronal paraffin sections were cut at 4 μm thickness for Hematoxylin and Eosin (H&E) staining.

Statistical analysis

experiments were performed induplicate measurements and the results are shown as the mean ± S.E. Statistical analysis of data was performed with repeated measures analysis of variance (ANOVA) and P<0.05 were considered to be significant also used LSD and SPSS statistical program , (26),

Results and Discussion

The tables (1 and 2) illustrated the mean values of MDA (33.65u/mg) and NO (36.81 μm/mg) in the cerebellum and serum of the rats are significant increased (p<0.05)in overctomized rats group when compared to the control group . However no significant difference mean value of GPX . The tables showed a significant decrease(p<0.05) in the activity of the CAT enzyme and GSH level were observed in overctomized group when compared to the control values in the cerebellum tissue and serum .

Table (1) Effect of ovariectomy in the cerebellum lipid peroxidation(GPX,MDA,NO ,GSH and CAT) in overctomized adult female rats

Groups Parameters	C	OVx
GPX u/mg	10.23±2.11	14.11±3.25
MDA nμ/m	12.90±3.75	33.65±2.47*
NO μm/mg	9.11±3.69	36.81±6.30*
CAT nμ/m	44.27±4.27	16.60±5.82*
GSH μm/m	29.61±3.22	9.82±1.96*

Mean ±SE * significant differences (p<0.05) c(control group),ovx (overctoomized rats)

Table (2) Effect of ovariectomy in the serum lipid peroxidation(GPX,MDA,NO ,GSH and CAT) in overctomized adult female rats

Groups Parameters	C	OV
GPX u/mg	2.72±0.98	3.24±0.47
MDA nμ/m	4.25±0.9	9.36±1.00*
NO μm/mg	40.11±6.18	87.35±2.47*
CAT nμ/mg	55.39±9.62	27.18±8.59*
GSH μm/m	13.92±1.49	5.18±1.06*

Mean ±SE * significant differences (p<0.05) C(control group),OVX (overctoomized rats s)

Microscopic examination of a section of cerebellum in control animals showed outer gray matter which include molecular cells layer , Purkinje cells layer and granular cells layer and inner whit matter (figure 1).While figure (2) shows decrease in the number of prekejy cells and vacuoles present in the gray matter in the overctomized animal group with vacuoles lesion in the whit matter ,figure (2) also revealed microglial cells infiltration in the molecular layer of cerebellum

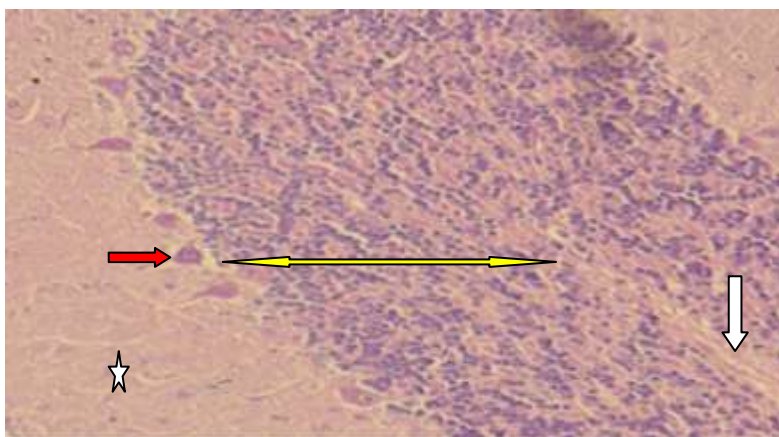


Figure (1)Histological section in the cerebellum of animal control group ,shows outer gray(molecular ☆ , purkinje cells → and granular layers ↔ and inner whit matter ↓(H&EX40).

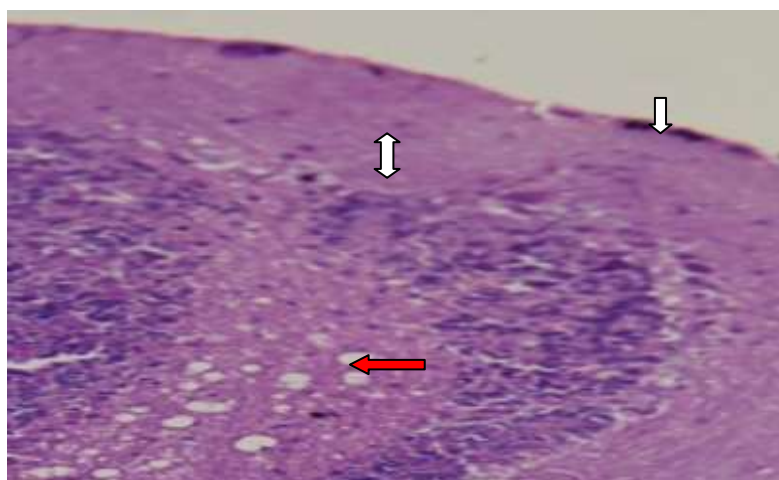


Figure (2) histological section in cerebellum of overctomized rats group shows decrease in the number of purkinje cells ↔, found vacuoles ← in the white matter and microglial infiltration ↓ . (H&EX40).

The present study revealed the significant increase in MDA,NO, GPX while there was significant decrease in GSH level and CAT activity in the serum and cerebellum in ovariectomized rats. The result study agree well with previous studies removing ovaries to induce estrogen deprivation to increase free radical production as well as lipid peroxidation and brain tissue damage (27,28,29,30).

The possible mechanism of bone loss in ovariectomised rats might be due to oxidative stress produced by the high hydrogen peroxide and lipid peroxidation levels and reduced antioxidant enzyme activities(31) .Lipid peroxidation is one of the primary effects induced by oxidative stress and may occur readily in the brain due to presence of membranes that are rich in polyunsaturated fatty acids (19) Thus ,the brain may be a target organ for imbalance between oxidants and antioxidants to word oxidants , decrease levels of blood estrogen hormone (endogenous antioxidant), which are known to induce oxidative tissue damage(13).

The brain contains membranes that are composed of proteins and an abundant amount of phospholipids. These phospholipids contain oxidizable polyunsaturated fatty acids (PUFAs), such as arachidonic acid and docosahexaenoic acid. These PUFAs are vulnerable to attack by free radicals because they contain hydrogen ions held together by weak double bonds that serve as a target for reactive oxygen radicals and the generation of irreversible oxidative damage (2)

There is growing evidence that oxidative stress and estrogen deprivation after menopause or ovariectomy represent two main risk factors closely related to the development of Alzheimer's disease(21,32)

The rapid hormonal changes occurring at menopause, including estrogen depletion and elevated LH levels, are thought to play a role in the increased susceptibility to Alzheimer's disease (AD) in women (33,34).These hormonal changes are believed to promote the accumulation of the neurotoxic β -amyloid ($A\beta$) peptide and increase susceptibility to $A\beta$ -induced neurotoxicity (33,35,36)

Our study showed a significant decrease in the levels of GSH in the serum , an cerebellum tissue ,Glutathione is an important cellular antioxidant and exerts its antioxidant activity through several mechanisms, including scavenging free radicals (37) . Synergistic interaction between estrogen and glutathione (an intracellular reducing agent) has been reported that may increase the antioxidant potency of estrogens (38). Evidence suggests that hippocampal blood flow is increased over time in women receiving HRT(Hormone Therapy) (39)

Increase in free radicals production such as nitric oxide level in overctomized rats in the present study may induce mitochondrial-dependent cell death as the damaged mitochondria are unable to maintain the energy demands of the cells (33). Estrogens exert protective effects against oxidative stress by inhibiting lipid peroxidation and subsequently preserving Ca^{2+} homeostasis, mitochondrial membrane potential, and ATP levels(40) Neurons are particularly sensitive to free radicals Nitric oxide- (NO-) dependent oxidative stress results in mitochondrial ultrastructural alterations and DNA damage in cases of Alzheimer disease (AD) (41) . Increase levels of serum MDA ,NO and GPX are in current agreement with widely examined blood samples for evidence of a systemic oxidative effect, with changes in membrane fluidity(42) platelet activation (43) and more specifically, reports of leukocyte oxidation(33).

Functional studies showed the blood-brain barrier (BBB) is grossly intact in patients with AD,(44,45) ,but there are several reports of abnormal small-vessel structure, particularly affecting the endothelium, which could affect BBB function (46,47) This might contribute to the presence of oxidative products in the systemic circulation, and changes in blood components that are in contact with the altered microvasculature.

The cerebellum histological sections showed decrease in the number of the prukije cell in the gray matter compare with control group and apoptosis found in the section as a result of increase in the markers lipid peroxidation (increase in the MDA and decrease in GSH leves). Estrogen can regulate expression of antiapoptotic genes, such as increasing bcl-2 expression. Lastly, estrogen can increase microglial uptake of β - amyloid to potentially decrease amyloid load in the brain. (48,49)

Estrogen can regulate both the generation of and the toxicity of amyloid. In addition, estrogen can decrease the damage induced by free radicals generated by amyloid and microglial. Estrogen can protect against the secondary insult induced by excessive leakage of glutamate from damaged neurons to reduce intracellular calcium levels (50).

Reference

1. Sies , H. (1997).Oxidative stress :oxidants and antioxidants .*Exp.physiol.*,82:291-5.
2. Sinclair, A.; Bayer, A.; Johnston, J.;Warner,C.and Maxwell; S.(1998).Altered plasma antioxidant status in subjects with Alzheimer's disease and vascular dementia. *Int J Geriatr Psychiatry*, 13:840–5.
3. Singh, R. P.; Sharad ,S. and Kapur, S. (2004) .Free Radicals and Oxidative Stress in Neurodegenerative Diseases: Relevance of Dietary Antioxidants. *JACM*, 5(3): 223.
4. Halliwell, B and Gutteridge, J. (1992)Role of free radicals and catalytic metal ions in human disease and an overview. *Brain Injury*, 6: 203-12.
5. Packer, L.; Prilipko, L. and Christen, Y.(1992). Free radicals in the brain. Heidelberg, Germany: Springer-Verlag,.
6. Green, P.S.; Yang, S.H. and Simpkins, J.W.(2000). Neuroprotective effects of phenolic A ring oestrogens. *Novartis Found. Symp*, 230: 202–220.
7. Basu,S.; Mishaelsson, K; Olfasson, H; Johansson, S and Melhus ,H. (2001). Association between oxidative stress and bone mineral density *Biochem.Biophys.Res. Commum*,288:275-9.
8. Melhus, ;Y, Meichalesson ,K.; Holmberg , L.; Wolk,A. and Ljungha, S.(1999). Smoking ,antioxidant vitamins and risk of hip fracture *J,Bone Miner Res.*,14:129-35.
9. Phillips, S.M. and Sherwin, B.B. (1992). Effects of estrogen on memory function in surgically menopausal women. *Psychoneuroendocrinolgy* ,17: 485–495.
10. Neurgaren, B.L. and Kraines, R.J. (1965). Menopausal symptoms in women of various ages. *Psycho. Med.*, 27: 266–273.
- 11.Brinton, R.D.; Chen, S.; Zhang, S.; Minaya, J; Oji, G.; Kim, J and Lorient, V.(1998).Comparative analysis of estrogen replacement therapy and the SERM raloxifene on neural plasticity and neuroprotection . *Soc.for Neurosci.*, 15:134-137
12. Zheng, H.; Xu, H.; Uljon, S.; Gross, R.; Hardy, K.; Gaynor, J.; Lafrancois, J.; Simpkins, J.; Refolo, L.; Petanceska, S.; Wang, R. and Duff, K. (2002). Modulation of A β peptides by estrogen in mouse models. *J Neurochem* ,80:191–196.
13. Garcia-Segura, L. M.; Azcoitia, I. and Don Carlos, L. L. (2001). Neuroprotection by estradiol. *Prog. Neurobiol.* 63:29–60.
14. Cimarosti, H.; Ionara, R.; Lauren, L.;Melissa, N.; Rodrigo, B.; Rudimar , F. C. ; Carlos, A. and Christianne,S. (2005).Neuroprotection and Protein Damage Prevention by Estradiol Replacement in Rat Hippocampal Slices Exposed to Oxygen- Glucose Deprivation. *Neurochemical Research.* 30(4) : 583–589.
15. Shuster, L.; Gostout, B.;Grossardt, B. and Rocca, W. (2008).Prophylactic oophorectomy in premenopausal women and long-term health. *Menopause Int.*,14:111-116.
16. Burke, W.J; Li,W; Chung, H.D. ; Ruggiero, D. A.; Kristal, B. S.; Johnson, E. M.; Ampe, P.; Kumar,V. ; Franko, M.; Williams E .and Rama Rand Davalos, A.(2002).Iron intake increase volume after permanent middle cerebral artery in rats .*BrainRes.*11,956(1)1.
17. Marino,E.;Gorz,K. ; Mmonssa ,B.; Youdim ,A.and Peter ,R.(2004). The relevance of iron in the pathogenesis of Parkinsons disease metals in Redox active metals in neurological disorder.*Ann.NT.Acad.Sci*,1(12):188-193.
18. Halliwell, B. (1989).Oxidants and the central nervous system: some fundamental questions. Is oxidant damage relevant to Parkinson's disease, Alzheimer's disease, traumatic injury or stroke. *Acta Neurol Scand*,126:23-3.
19. Tuppo, G. and Forman, R.(2001). Free radical oxidative damage JAOA . 101 (12):S11

20. Floyd, R.(1999)Antioxidants, oxidative stress, and degenerative neurological disorders. *Proc Soc Exper Biol Med*,222(3):236-245.
- 21.Behl, C. ; Moosmann, B.; Manthey, D. and Heck, S.(2000)The female sex hormone oestrogen as neuroprotectant: Activities at various levels. *Novartis Found. Symp*, 230: 221–234.
22. Gutteridge, J. and Wilkins, S.(1982). Copper- dependent hydroxyl radical damage to ascorbic acid. *FEBS Lett.*, 137: 327-329.
23. Burtis ,C. and Ashwood, E. (1999). Textbook of clinical chemistry. 3d Ed.London. 941.
24. Medina, D.; Lane, H.W. and Oborn, C. J.(1982) . Uptake and localization of selenium-75 in mammary epithelial cell lines in vitro. *Cancer Lett.*, 5:301-310,..
25. Aebi, M. (19980. The internal skeletal fixation system ;A new treatment of thoracolumbar fractures and other spinal disorders.*Clin Orthop* ,227; 30-43.
26. Dunean, R.C.; Knapp R.G. and Millerill, M.C. (1980). Introductory biostatistics for the health sciences (2nd Ed). Wiley Medical publication.
27. Gould,E.;Woolley,C.S.;Frankfurt,M.; McEwen, B.S.(1990). Gonadal steroids regulate dendritic spine density in hippocampal pyramidal cells in adulthood. *J. Neurosci*, 10: 1286–1291.
28. Goodman ,Y; Bruce, A. ; Cheng, B. and Mattson, M. (1996). Estrogens attenuate and corticosterone exacerbates excitotoxicity, oxidative injury and amyloid betapeptide toxicity in hippocampal neurons. *J Neurochem* ,66:1836–1844.
29. Gunter, T.E. and Pfeiffer, D.R. (1990) . Mechanisms by which mitochondria transport calcium. *Am J Physiol*, 258:C755–C786.
30. Melov, S. (2000). Mitochondrial oxidative stress. Physiologic consequences and potential for a role in aging. *Ann NY Acad Sci.* ,908:219–225.
31. Barron, A.M; Fuller, S.J ; Verdile, G. and Martins, R.N.(2006). Reproductive hormones modulate oxidative stress in Alzheimer’s disease. *Antioxid Redox Signal* ,8:2047–2059.
- 32.Behl,C. (1999) .Alzheimers disease and oxidative stress implications for novel therapeutic approaches *Prog.Neurobiol.*,57:301-323.
33. Mecocci, P.; Cherubini, A.; Senin, U.(1997) Increased oxidative damage in lymphocytes of Alzheimer's disease patients. *JAGS*, 45:1536–7.
34. Munch, G.; Thome, J.; Foley, P.; Schinzel ,R. and Riederer, P. (1997).Advanced glycation endproducts in ageing and Alzheimer's disease. *Brain Research Reviews*, 23:134–43.
35. Subbarao, K.; Richardson, J. and Ang, L. (1990). Autopsy samples of Alzheimer's cortex show increased peroxidation in vitro. *J Neurochem*, 55:342–5.
36. Smith, C.; Carney, J. and Starke-Reed, P.(1991). Excess brain protein oxidation and enzyme dysfunction in normal aging and in Alzheimer disease. *Proc Natl Acad Sci*, 88:10540–3.
37. Meister, A. and Anderson, M. (1983). Glutathione. *Annu Rev Biochem*, 52:711–760.
38. Green, P.; Bishop ,J. and Simpkins, J. (1997). 17 alpha-estradiol exerts neuroprotective effects on SK-N-SH cells. *J Neurosci* ,17:511–515.
39. Murphy, D.G.; DeCarli, C.; McIntosh, A.R.; Daly, E.; Mentis, M.J.; Pietrini, P.; Szczepanik, J.; Schapiro, M.; Grady, C.L.; Horwitz, B. and Rapoport, S.I.(1996). Sex differences in human brain morphometry andmetabolism: an in vivo quantitative magnetic resonance imaging and positron emission tomography study on the effect of aging. *Arch. Genet. Psychiatry* , 53: 585–594.
40. James, X. A.; Perez, D.E.; Liu, R.; Yang, S.;Douglas, F. C .and James, W. S.(2006) Neuroprotective Effects of 17_ -Estradiol and Nonfeminizing Estrogens against H₂O₂ .*Toxicity in Human Neuroblastoma*, 20(4): 395–404.
41. Mecocci, P.; MacGarvey, U. and Beal ,M.(1994). Oxidative damage to mitochondrial DNA is increased in Alzheimer's disease. *Ann Neurol*, 36:747–51.
- 42.AL.Bazii,W.J.(2006). Protective and Preventive role of Olive oil in Methionine overload induced hepatic and cardiac damage in male rabbits. Ph.D thesis,Vet.medicine collage.Baghdad University.
43. Sevush, S.; Jy ,W. ; Horstman, L. ; Mao ,W.; Kolodny, L. and Ahn, Y.(1998). Platelet activation in Alzheimer disease. *Arch Neurol*, 55:530–6.

44. Friedl, R.;Yano, Y.; Budinger, T.(1983). Quantitative evaluation of blood-brain-barrier integrity in Alzheimer type dementia: positron emission tomographic studies with rubidium-82. *Eur Neurol*, 22:15–20.
45. Caserta, M.T. ; Caccioppo ,D; Lapin, G; Ragin, A. and Groothuis, D.(1998). Blood-brain barrier integrity in Alzheimer's disease patients and elderly control subjects. *J Neuropsychiatry Clin Neurosci*, 10:78–84.
- 46-Hashimura, T.; Kimura, T. and Miyakawa, T.(1991).Morphological changes of blood vessels in the brain with Alzheimer's disease. *Jpn J Psychiatr Neurol*, 45:661–5.
- 47.Buee, L. ; Hof, P.R. and Delacourte, A.(1997). Brain microvascular changes in Alzheimer's disease and other dementias. *Ann N Y Acad Sci*,826:7–24.
48. Ezzell, C.(1995). Evolutions: Alzheimer’s disease. *J. NIH Res.*, 7: 108 .
- 49.Brinton, R.D. and Yamazaki, R.S. (1998). Therapeutic advances and challenges in the treatment of Alzheimer’s disease. *Pharm. Res.* , 15: 384–397.
50. Green, P. and Simpkins, J. (2000) . Neuroprotective effects of estrogens: potential mechanisms of action. *Int J Dev Neurosci* ,18:347–358.