

# Spontaneous ovarian hyper stimulation syndrome following hydatidiform mole (A case report)

Ghada Abdul – Ghani Al – Daheen

Department of Obstetrics and Gynecology, College of Medicine, University of Mosul

(Ann. Coll. Med. Mosul 2005; 31(1): 48 - 51)

Received: 15<sup>th</sup> Oct 2003; Accepted: 18<sup>th</sup> May 2005

O HSS is an uncommon, but potentially life threatening complication of ovarian stimulation by ovulation induction agents. This condition was first described as being iatrogenic following the use of gonadotropins in ovulation induction.

While the incidence of iatrogenic OHSS varies between 0.5 – 10 %, it is very rare to occur spontaneously<sup>(1)</sup>.

OHSS is characterized by an increase in the vascular permeability leading to fluid shift from the intravascular to the extra vascular space. This leads to reduced circulating volume, depletion of albumin and electrolytes, and third space accumulation of fluid manifested by ascites and rarely by hydrothorax<sup>(1)</sup>.

Oliguria results from reduced renal blood flow as a result of hypovolaemia, which if uncorrected will ultimately result in renal failure.

The supra physiological estradiol plasma levels may be related to the hypercoagulable state. However the most important factor is likely to be haemoconcentration secondary to hypovolaemic state.

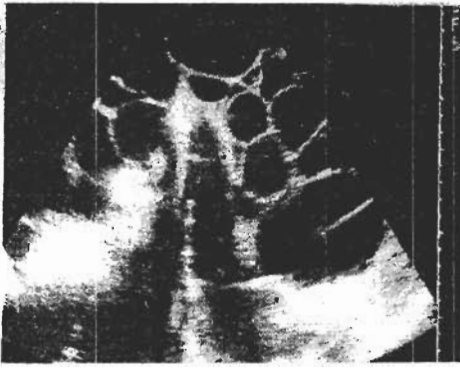Because the trigger for OHSS is human chorionic gonadotrophin (hCG) then the only certain way of preventing this syndrome is to withhold its administration and cancel the cycle<sup>(1)</sup>.

**Key words:** ovarian hyperstimulation syndrome, hydatidiform mole, ovarian cyst

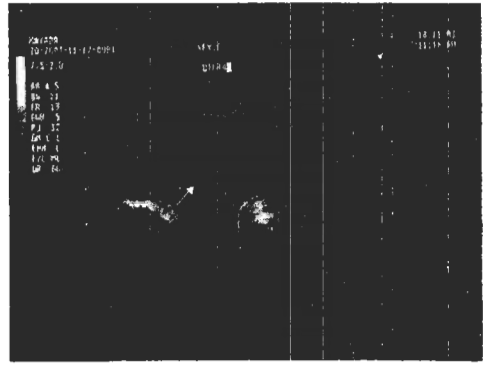
**CASE REPORT:** A twenty-five years old woman, gravida four, para three, Rh negative, from Talafar was admitted as a

diagnosed case of hydatidiform mole with a history of four missed periods. The uterus was of twenty-two weeks size. Complete emptying of the uterine cavity by suction curettage was carried-out and two liters of vesicles and blood were collected. The patient received two units of blood during the procedure. Bilateral cysts (most likely ovarian theca lutein cysts) about seven-centimeters in diameter were palpated immediately following evacuation; they were not recognized on initial ultrasound scan. The patient received 300mg of anti – D gamma globulin and was discharged on her responsibility on the first post-operative day.

She came back one week later with ill health, fainting attacks, generalized abdominal pain and distension, but no vaginal bleeding. On examination: the patient looked ill, pale, and uncomfortable. Her pulse rate was 100 beats per minute, the blood pressure was 90/50 mmHg and the temperature was 37°C. Examination of the cardio-respiratory systems was normal. Abdominal examination revealed a hugely distended, tense abdomen with big bilaterally palpable cysts filling both iliac fossae and extending upwards beyond the level of the umbilicus. Bowel sounds were normal. Pelvic examination was non-informative because of pain. Ultrasound examination confirmed big bilateral multilocular ovarian cysts beyond the screen with huge amount of free fluid in the abdomen and pelvis, while the uterus was just bulky and the cavity was empty (Figure 1).



**Figure 1:** Abdominal ultrasound scan of the patient at first day of admission to hospital.



**Figure 2:** Abdominal ultrasound scan of the patient 29 days later.

A provisional diagnosis of endogenous ovarian hyperstimulation syndrome was made. The patient was admitted to hospital and the following investigations were done:

Hemoglobin was 160g/L, PCV 48 %, WBC  $11.8 \times 10^9/L$ , platelet count was  $350 \times 10^9/L$ , serum urea 6.5mmol/L, Na 140mEq/l, K 5.7mEq/l, Creatinine 80micromol/L, alkaline phosphatase 64U/L, total bilirubin 10.3micromol/L and direct bilirubin 1.7micromol/L. PT, PTT were normal. Beta HCG was 26800 U/L (RIA). Chest X-ray and ECG were normal. The disease was graded as being moderate – severe OHSS according to PCV and ovarian size<sup>(1)</sup>, and the plan of management was towards conservative treatment.

During hospitalization: Urine output was about 20ml/hr, the patient received IV fluid (normal saline & Hartman's solution as they are the fluids of choice in such case)<sup>(1,6)</sup>. One liter was given in the first hour for rapid restoration of tissue perfusion. Plasma expanders (haemacell in this case) was given in 1000 ml over twenty-four hours. Strict monitoring of vital signs and urine output were the guides to adjust further doses of IV fluid.

Paracentesis under ultrasound guide to relieve progressive abdominal distension was carried out after the correction of hypovolaemia. The aspiration was repeated two times more because of persistent patient's discomfort. The 1<sup>st</sup> aspirate included 2000 ml of fluid, while other two included 1000 ml per day done over consecutive days. Heparin prophylaxis was given in a dose of 5000 IU subcutaneously twice daily for 15 days.

Despite treatment the patient did not improve and started to develop extensive edema at the vulva, dyspnoea, vomiting and loss of appetite. Mannitol was added five days after admission in a dose of 200ml 12hourly. Frusemide (lasix) in 20mg dose was given twice daily. treatment with both

mannitol and lasix was continued for three days.

Methotrexate(MTX) with folinic acid were added to the treatment at day eight from admission. An eight day regime of MTX (1 mg/kg IM every other day for four doses) and leucovorin rescue (0.1 mg/kg), 24 hours after each dose was given.

Clinical improvement was evident in few days following this treatment. The patient's general condition improved, appetite was better, the disabling, painful vulval edema was disappearing, abdominal distension and dyspnoea became less troublesome, as well as ultrasonic reduction in the size of the cyst and ascitic fluid volume ( 7 cm, 4cm respectively ) (Figure 2). Beta HCG assessment was another indicator of improvement which dropped to 3100 U/L fifteen days after initial assessment. The treatment course with MTX and folinic acid was repeated one week later. The patient was discharged home after one month stay in hospital in a very good health and an HCG level of 40 U/L, and she was seen for the usual follow up of hydatidiform mole which was uneventful all through the period.

## DISCUSSION

A case of OHSS occurring spontaneously following hydatidiform mole in a multiparous woman who received no medication for ovulation induction is presented.

The diagnosis was based on typical clinical features of OHSS confirmed by ultrasound findings before and after treatment (Figures 1 and 2) as well as other laboratory investigations.

Glutunbosun et al<sup>(2)</sup>, in 1996 reported three cases of spontaneous OHSS associated with pregnancy as the first cases to result in live birth. Rosen and Lew<sup>(3)</sup> in 1991 have reported other cases associated with spontaneous pregnancy.

Zaley and colleagues<sup>(4)</sup> in 1992 described

a case of OHSS associated with spontaneous pregnancy in a woman with polycystic ovarian disease. Rotmensch and Scommegna<sup>(5)</sup> in 1989 reported another case of spontaneous OHSS in an ovulatory non-pregnant patient with trisomy 21 and hypothyroidism.

The etiology and pathophysiologic characteristics of OHSS are poorly understood. Various factors including estrogen, histamine, prostaglandins, aldosterone, renin and angiotensin II have all been implicated in the development of this condition. Recent studies showed high renin-like activity and elevated angiotensin II immunoreactivity in both plasma and ascitic fluid (angiotensin II being 6-9 fold higher in ascitic fluid than in plasma). These findings are in favor of ovarian origin of the elevated renin-like activity and angiotensin II immunoreactivity in ascitic fluid of severe OHSS and suggest a stimulatory role of hCG on the ovarian renin-angiotensin system during severe OHSS.

Angiotensin II probably does not cause ascites in severe OHSS, though it may contribute to its maintenance. The efficacy of paracentesis during severe OHSS could be explained at least partially by the removal of great amounts of angiotensin II from the peritoneal cavity. Both antihistamines and indomethacin have been demonstrated to ameliorate the hyperstimulation in animal studies, but its efficacy in humans is unknown<sup>(6-10)</sup>.

One third of the patients developing OHSS after IVF-ET had no previous risk criteria. Exogenous and/or endogenous hCG is suggested as an etiologic factor<sup>(1,12)</sup>.

Isik and colleagues<sup>(12)</sup> believe that human albumin is an effective preventive measure in cases of moderate to severe OHSS. While other retrospective case analyses have shown no benefit<sup>(14)</sup>. The rationale for the use of prophylactic albumin is to act as carrier protein to prevent leakage of vasoactive substances into the extra vascular space. The use of albumin in this case was not applied because of its shortage at the time the case presented (blockade), as well as the arguments about the use of albumin in this context. The relatively small size of the molecule allows it to pass more easily into the extra vascular space, in addition to the well known risks of viral transmission and anaphylaxis associated with human blood products<sup>(1,14)</sup>. Haemacell was used instead.

Treatment with methotrexate was initiated because the patient had two recognized risk factors of gestational trophoblastic disease (GTD) i.e. the presence of persistent large theca lutein cysts and the

high B-hCG<sup>(15)</sup>. Adjuvant chemotherapy following evacuation of non malignant GTD appears to reduce the incidence of persistent disease in high risk women but not in low risk group<sup>(15-17)</sup>. High levels of hCG by themselves are known to cause and to promote an already existing state of hyper-stimulated ovaries<sup>(1)</sup>. That is why giving MTX was thought to be protective against the possible risk of further progression of the disease as well as to combat the pathology behind OHSS which is the high hCG level. A second course of MTX was thought to help further reduction in hCG levels back to normal, following the dramatic response to the first course.

## REFERENCES

1. Bonnar J. Recent Advances in Obstetrics and Gynecology; Aetiology, Prevention and Treatment of OHSS. Edinburgh, London: Churchill-Livingstone. 2001: 123-140.
2. Glatunbosun O A, Gilliland B, Brydon L A, et al. Spontaneous OHSS in four consecutive pregnancy. Clin Exp Obstet Gynecol 1996; 23(3); 127-32.
3. Rosen G F, Lew MW. Severe ovarian hyperstimulation in a spontaneous singleton pregnancy. Am J Obstet Gynecol 1991; 165(5pt1); 1312-3.
4. Zale Y, Katz Z, Caspi B. Spontaneous ovarian hyperstimulation syndrome concomitant with spontaneous pregnancy in a woman with polycystic ovarian disease. Am J Obstet Gynecol 1992; 167: 122-4.
5. Rotmensch S, Scommegna A. Spontaneous OHSS associated with hypothyroidism. Am J Obstet Gynecol 1989; 160: 1220-2.
6. Delbaere A, Bergmann P J, Gervy-Decoster C, et al. Increase angiotensin II in ascites during severe ovarian hyperstimulation syndrome: Role of early pregnancy and ovarian gonadotropin stimulation. Fertil Steril. 1997; 7(6): 1038-45.
7. Delbaere A, Bergmann P J, Gervydc M. Angiotensin II immunoreactivity is elevated in ascites during severe OHSS: Implication for pathophysiology and clinical management. Fertil Steril 1994; 62: 731-7.
8. Golan A, Ron-el R, Herman A, et al. Ovarian hyper-stimulation syndrome: An update review. Obstet Gynecol Surv 1989; 44: 430-40.
9. Itskovitz Eldor J, Kol S, Lewit N, Sealey JE. Ovarian origin of plasma and peritoneal fluid Prorenin in Early Pregnancy and in Patients with OHSS. J

- Clin Endocrinol Metab 1997; 82(2): 461-4.
10. Speroff L, Glass RH, Kase NGI. Induction of ovulation. In: Speroff L, Clinical Gynecologic Endocrinology and Infertility 5th ed. Lippincott Williams & Wilkins 1994.
  11. Delvigne A, Randromme J, Leroy F. Unpredictable case of complicated ovarian hyperstimulation in IVF. Int J Fertil Women Med 1997; 42(4): 264-7.
  12. Isik Az, Gokmen O, Zeynelogin HB, et al. Intravenous albumin prevents moderate-severe OHSS in IVF patient: a prospective randomized and controlled study. Eu J Obstet Gynecol Report Biol 1996; 70(2): 179-83.
  13. Ndukwe G, Thornton S, Fishel S et al. severe Ovarian hyperstimulation Syndrome. Is it really preventable by prophylactic intravascular albumin? Fertility, Sterility 1997; 68, 854 – 859.
  14. Cochrane Injuries group Albumin Reviewer. Human albumin administration in critically ill patients. Systematic review of randomized controlled trials. BMJ 2001; 317:235 – 239.
  15. Curry, SL, Hammond, CB, Tyrey, L, et al. Hydatidiform mole: diagnosis, management, and long-term follow up of 347 patients. Obstet Gynecol 1975; 45:1.
  16. Montz, FJ, Schlaerth, BJ, Morrow, CP. The natural history of theca lutein cysts. Obstet Gynecol 1988; 72:247.
  17. Kim, DS, Moon, KT, Moon, YJ, Hwang, YY. Effects of prophylactic chemotherapy for persistent trophoblastic disease in patients with complete hydatidiform mole. Obstet Gynecol 1986; 67:690.