

Identification of cryptosporidium among immunocompromised individuals

Abdul-Salam M. AL-Mukhtar, Nihad S. S. AL-Sherefat

Department of Microbiology, College of Medicine, University of Mosul

(Ann. Coll. Med. Mosul 2005; 31 (2): 83-86)

Received: 19th Sept 2005; Accepted: 12th Apr 2006

ABSTRACT

Objective: to investigate the occurrence of cryptosporidium oocyst in patients with malignant disease before and after receiving chemotherapy.

Methods: A follow up study of 107 patients before and after 2-3 months from receiving chemotherapy compared with 100 healthy subjects studied as a control.

Results:

1. The study revealed a significant increase of cryptosporidium oocyst (18.37%) in patients after receiving chemotherapy in comparison with (8.39%) in patients before receiving chemotherapy and (5%) in control group.
2. In our study we used Iodine stain with simple modification by using the oil immersion power for the diagnosis and in this case we obtained excellent diagnosis for Cryptosporidium oocyst. This modification has been used for the first time for better diagnosis of cryptosporidium oocysts.

Key word: Cryptosporidiosis, patients with malignant disease, Mosul city.

الخلاصة

تشخيص وجود الأبواغ الخبيثة في المرضى المصابين بالسرطان قبل وبعد العلاج بالأدوية الكيماوية والأشعة العميقة.

أجريت الدراسة على (107) مريض مصاب بالسرطان قبل وبعد تلقيهم العلاج مقارنة مع مجموعة السيطرة التي شملت على (100) شخص غير مصاب. أظهرت النتائج:

- أن هناك زيادة معنوية بالنسبة للإصابة بطفيلي الأبواغ الخبيثة (18,37%) في المرضى بعد تلقيهم العلاج المضاد للسرطان نسبة إلى مجموعة المرضى قبل تلقيهم العلاج (8,39%) ونسبة إلى مجموعة السيطرة (5%).
- أفضل طريقة للكشف على الأبواغ الخبيثة كانت عند استعمال التصبغ بالأيودين مع الغمر بالزيت للعدسة الشبكية ولأول مرة لتشخيص الأبواغ الخبيثة.

Cryptosporidiosis is a zoonotic disease was discovered early in twentieth century by Tyzzer in 1907 and in 1976, it was identified as the causative agent of human cryptosporidiosis⁽¹⁾. The disease gains increasing importance because of their presence in water supplies⁽¹⁾; the parasite is transmitted by the fecal-oral route and the oocysts are remarkably resistant to many common disinfectants, including chlorine-based compounds⁽¹⁾. *Cryptosporidium spp.* is a coccidian protozoan parasite of the intestinal tract that causes diarrheal disease in humans and intractable diarrhoea in immunocompromised patients and self limiting diarrhoeal-illness in immunocompetent individuals⁽²⁾.

In the Western world, protozoan parasites had become the chief cause of parasitic infection in immunocompromised patients with high prevalence of Cryptosporidiosis⁽³⁾. Anyone can get Cryptosporidiosis, but it causes more severe illness in persons with HIV/AIDS and others with impaired immune systems⁽⁴⁾ and for this reason Cryptosporidiosis has recently gained attention⁽²⁾. However Cryptosporidiosis has been recovered as a cause of diarrhea in patients in Arab countries⁽⁵⁻⁷⁾. This paper is the first report of Cryptosporidiosis among malignant disease patients receiving cytotoxic and radiation therapy in Mosul, Northern Iraq.

PATIENTS AND METHODS

Stool samples were collected from 107 patients before and 2-3 months after receiving anticancer therapy and 100 stool samples were collected from normal individuals as a control group. This study was conducted in Mosul Teaching Hospitals over a period of one year from May 2002 to June 2003. Stool samples were stained by five different stains e.g, cold and hot modified Ziehl-Neelsen stains^(8,9), Kinyoun stain⁽¹⁰⁾, Novel stain⁽¹¹⁾, Iron haematoxylin and iodine stain⁽¹²⁾. The latter stain which is modified for the first time in our study revealed excellent diagnosis for *Cryptosporidium* oocyst. This modification was done by making permanent slides which will be suitable for the use of oil immersion to visualize the characteristic content of *Cryptosporidium* oocyst which is the peripheral residual body and the four sporozoite nuclei. Microscopic examination was done under high power magnification, suspected oocyst examined at oil immersion for each patient; two stool samples were examined for accurate diagnosis.

Fixation & staining of permanent slides:

1. Add three drops of schaudinn's fixative on a thin film of fecal suspension for 30 minutes at 37°C.
2. Wash in running tap water for 5 minutes and treat with lugol's iodine for 5 minutes.
3. Lay the slide on a coverslip on which a drop of 20% glycerin has been placed.
4. Carefully blot the preparation and seal with paraffin wax.
5. Examination with oil immersion.

Statistical analysis: Chi-square test was used.

RESULTS

The study revealed a significant increase of *Cryptosporidium* oocyst (18.37%) in patients after receiving treatment in comparison with (8.3%) in patients before receiving treatment and (5%) in control group (Table 1). Our results revealed that the modified direct iodine stain method was the best technique in comparison to others used for the diagnosis of *Cryptosporidium* oocyst (Table 2).

Table (1): Frequency of *Cryptosporidium* spp. infection in patients before and after receiving treatment (BRT and ART).

Parasitic infection type	% control	% BRT	% ART	Control + BRT		Significance	Control + ART		Significance
				P	X		P	X	
<i>Cryptosporidium</i> spp	5	8.39	18.37	0.95	0.33	NS	4.71	0.03	S

Table (2): Stains techniques used for the diagnosis of the *Cryptosporidial* cysts.

Tech used	Medical Acid Fast (Hot)			Medical Acid Fast (Cold)			Kinyoun			Novel			Modified Direct Iodine			Direct Exam		
	E	+	%	E	+	%	E	+	%	E	+	%	E	+	%	E	+	%
Compromised BRT	107	6	5.6	107	5	4.67	107	2	1.92	107	0	0	107	8	7.47	107	0	0
Compromised ART	107	18	16.8	107	9	8.4	107	7	6.54	107	6	5.6	107	19	17.75	107	0	0
Control	100	2	40	100	2	40	100	3	60	100	0	0	100	4	80	100	0	0
Total		26			16			12			6			31				

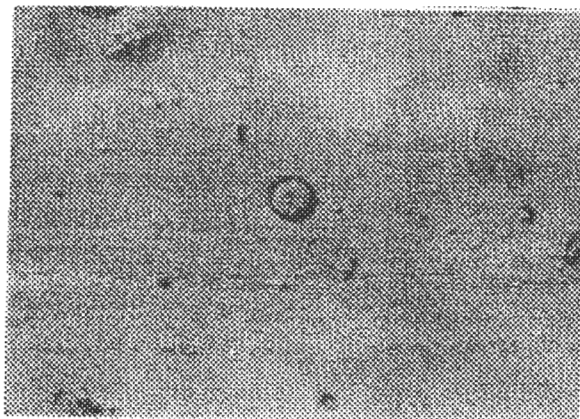


Figure (1): *Cryptosporidium* oocyst containing four sporozoites with iodine stain, (Oil immersion Lens x 1000).

DISCUSSION

Cryptosporidium parvum is the parasitic protozoan that causes human cryptosporidiosis, as well as in certain animals, including domestic livestock⁽¹⁾. In humans, it causes abdominal pain, profuse diarrhea, weight loss, loss of appetite and anorexia, but in otherwise healthy individuals the infection is usually self-limiting and resolves within a few weeks⁽²⁾. In immunocompromised patients the infection is more serious and it can become chronic and is sometimes fatal⁽⁴⁾. Cryptosporidiosis represents a classic emerging infection, previously unknown in such severity. One of the main reasons that it gained importance was due to the epidemic of HIV/AIDS, which created a pool of susceptible individuals; globally there are close to 24 million individuals either HIV+ or with AIDS⁽¹²⁾. In our results, the significant increase of Cryptosporidium oocysts in patients after receiving treatment might be attributed to that Cryptosporidium oocysts have a great predilection to infect the immunocompromised patients⁽¹³⁻¹⁵⁾. Another explanation is the high number of leukemic patients and those with advanced stages of malignancy were already immunocompromised and they exhibited sharp lowering in cytotoxicity against intracellular infection^(16,17). Another possible explanation for the high rate of infection with Cryptosporidium oocyst is the spore forming nature of the parasite which may serve in the protection of the parasite from the harmful effects of radiation and cytotoxic drugs⁽¹⁸⁻²⁰⁾. Furthermore the direct infection by the oocysts after excretion could also serve in the rapid contamination of the environment⁽²¹⁾.

Another explanation is the low infective dose of Cryptosporidium oocyst specially in immunocompromised patients which might explain the high rate of infection with this parasite⁽¹⁰⁾. On the other hand our patients in this study were hospital inpatients, so they were more prone to catch the Cryptosporidium oocyst as this parasite is a nosocomial pathogen^(18,19). Other workers also stated that Cryptosporidium oocysts are very resistant to most disinfectants⁽²⁰⁾.

Our results revealed that the modified direct iodine stain method was the best technique in comparison to others used for the diagnosis of Cryptosporidium oocyst and this could be attributed to our modification by using the oil immersion power instead of using the high magnification for the diagnosis of the very tiny and small oocysts of this parasite (2-4 μm in length)⁽⁸⁾. However this result was in

agreement with Othman⁽¹¹⁾: who reported that the direct iodine stain was the best method for the diagnosis of Cryptosporidium oocysts although he used the high magnification power in his examination of the Cryptosporidium oocyst. This finding is not in agreement with Casmore et al⁽⁹⁾ who reported modified Ziehl-Neelsen technique (hot method) is the most sensitive method while it was the second successful technique used in our study with no significant difference from the direct iodine. But this finding disagrees with Garsia and Brackner⁽¹⁰⁾ who reported Kinyuan technique as the best method for the diagnosis of the Cryptosporidium oocyst.

CONCLUSION AND RECOMMENDATION

1. Direct iodine stain by using the oil immersion power was found to be the best technique for the diagnosis of Cryptosporidium oocyst. However, the use of this technique is recommended to be performed by persons who are familiar with it, otherwise modified Ziehl-Neelsen (hot) technique is recommended for accurate differentiation between yeast cells and Cryptosporidial oocysts.
2. Patients with malignant diseases after receiving treatment were susceptible to catch Cryptosporidial infection. Those patients should be isolated and provided with a high standard of hygienic environment to avoid direct contact with animals and raw animals products, as there are no specific drugs for treatment of this parasitic infection.

ACKNOWLEDGEMENT

We would like to express our appreciation to Dr. Khalid NM. AL-Khero & Dr. Kahtahn Radwan, Medical and Oncology therapy consultants who helped us in dealing properly with patients with malignant diseases.

REFERENCES

1. Angus KW. Cryptosporidiosis in man domestic animals and birds: a review. J. R. Soc. Med. 1983, 76: 62-70.
2. Soave R, Armstrong D. Cryptosporidium and Cryptosporidiosis. Rev. Inf Dis, 1986, 8: 1012-23.
3. Shaaban WA, Omar T. Protozoan infection in immunocompromised infants and children. Mid East Paediar. 1999, 4 (2), 61-65.

4. Sabour MS. Management of infection in immunocompromised patients. *Med Forum.* 1990, 36, 15-17.
5. Robinson M. et al. Cryptosporidium as a cause of gastro enteritis in Sudanese children. *Ann. Trop. Pediat.* 1986, 6: 155-6.
6. Salem SA. et al. Detection of human Cryptosporidium in a random sample from Cairo. *J. Eegy. Soc. Parasitol.* 1987, 17: 389-95.
7. Nadham K. Mahdi et al. First report of Cryptosporidiosis among Iraqi children. *East. Med. Health. J.* 1996. 2: No. 1.
8. Deluol AM. Colour atlas of Parasitology. 2 Format Unite. France 1999. 34-63.
9. Casmore DP, Armastrong M, Jackson B. Screening for Cryptosporidium in stool, *Lancet* 1984 31: 734-735.
10. Garcia 5, Brackner DA. Diagnostic medical Parasitology, 2nd ed, Amer. Soc. Microbiol. Washington DC: 1993, 355-372.
11. Othman NF. Comparison between different laboratory methods for diagnosis of Cryptosporidium spp. MSc thesis, Medical College, University of Tikrit, 1999.
12. Wanachiwanawin P. et al. Cryptosporidiosis and Isospora among AIDS patients with chronic diarrhea in Thailand. *J Protozoal Res.* 1998, 8: 10-18.
13. Foot ABM, Oakiil A, Ott MG. Cryptosporidiosis and acute leukaemia. *Arch Dis. Child* 1980, 65(2) :236-237.
14. Lazarini P. et al. Experimental respiratory Cryptosporidiosis in immune suppressed rats, light and electron microscopy study. *J. Parasit.* 1999, 6(3): 217-222.
15. Jenkins MC. et al. Hyper immune bovine colostrum specific for recombinant Cryptosporidium parvum Antigen confers partial protection against Cryptosporidiosis in immunocompromised adult mice, *Vaccine.* 1999, 1417(19): 2453-2460.
16. Plastoucus CD. et al. Abnormal T lymphocytes sub-population in patients with B cell chronic lymphocytic leukemia: an analysis by monoclonal anti-bodies. *J. Immunol.* 1982, 129 (5): 2305-2311.
17. Freifeld PG. Infection complication in the immunocompromised host, 1993, *Hematol, Oncol, Clin*, cited by Hoffbrand et. al. 1999.
18. Henrikson SA, Pohelenz JFL. Staining of Cryptosporidium by modified Ziehl-Neelsen technique. *Acta, Vet. Scand* 1981, 189 (22): 594-596.
19. Laing RB. Nosocomial infection in patient with HIV disease. *J. Hosp. infect.* 1999, 43 (3): 179-185.
20. Barbee SL, et al. Inactivation of Cryptosporidium parvum oocyst infectivity by disinfecting and sterilization process. *Gastrointest Endosc.* 1999, 49 (5): 605-611.
21. Current WH. Cryptosporidiosis. *JAVMA* 1985, 187 (12): 1334-1338.