

TOXICOLOGICAL PATHOLOGY OF NAPROXEN (NSAIDS) ON GASTRO-INTESTINAL TRACT IN WHITE RATS

Thaer Ali, Saleh K. Majeed, Zainab W. Khudair

Department of Pathology, College of Veterinary Medicine, University of Basrah, Iraq.

(Received 20 October 2013 ,Accepted 6 November 2013)

Keywords; Naproxen sodium, White rats, Villi.

ABSTRACT

The current study was accomplished to investigate the toxicity of naproxen sodium (NAP) in white rats, and then to detect the pathogenesis of NSAIDs-induced gastrointestinal injury. The study included the usage of main effective (naproxen) on (48) male and female white rats, They were divided into four groups, and each group contained (12) rats, divided as follows. group-C, which treated with normal saline, group(L) was low dose which received (5mg/kg) of naproxen sodium, group(I) was given intermediate dose ,which received (10mg/kg) and group(H) represented high dose, which received (20mg/kg). The drug administrated by oral gavage for three months. Results of the study included the macroscopic changes such as minimal changes of the gastric mucosa or lining epithelium in the wall of stomach, also included ulceration of the small intestine, in addition there was increase length of the villi and presence of inflammatory cells in lamina propria, and also there was degeneration of mucosal epithelium and mucosal glands in the lamina propria of the stomach, There was vacuolation of mucous lining cells of the stomach, and there was inflammatory cells in the serosa, presence of prominent ganglionic cells in the distal part of muscularis externa of the stomach. The pathological changes of high dose of naproxen was more severe than intermediate dose (group-I) and low dose (group- L).

INTRODUCTIONS

Naproxen: is a propionic acid derivative related to the aryl acetic acid group of non-steroidal anti-inflammatory drugs. The chemical names for naproxen and naproxen sodium are (S)-6-methoxy- α -methyl-2-naphthaleneacetic acid and (S)-6-methoxy- α -methyl-2-naphthaleneacetic acid, sodium salt, respectively.(1).Naproxen is

extensively metabolized in the liver to 6-O-desmethyl naproxen, which is inactive. Both naproxen and 6-O-desmethyl naproxen are further metabolized to their respective acylglucuronide conjugated metabolites. Approximately 95% of naproxen is excreted in the urine with <1% as unchanged naproxen, <1% as 6-O-desmethyl naproxen, and 66-92% as their glucuronides or other conjugates (2; 3), various pathogenic mechanisms have been suggested to be involved in the development of gut lesions from NSAIDs. A model suggested by (4) proposes that the main pathogenic steps of the NSAIDs effect on intestinal mucosa include the increase of mucosal permeability that leads to inflammation, ulceration, bleeding, and gut perforation [4]. The major side effects of NSAIDs on the GIT include ulceration and bleeding. These drugs are organic acids, and there is interplay between their respective lipophilic and acidic properties that underlie their GIT ulcerogenicity [5]. On the other hand, they also inhibit the COX-1 and COX-2, both of which are involved in the pathogenic process by reducing prostaglandin production that is implicated in the frequent and early clinical relapse of quiescent inflammatory bowel diseases (IBD) [6]. Another mechanism by which NSAIDs could damage the gastro-duodenal epithelium is via the uncoupling of oxidative phosphorylation in the epithelial cells. [7,8] Various NSAIDs have been shown to uncouple mitochondrial respiration [7,8] leading to a depletion of ATP and therefore a reduced ability to regulate normal cellular functions, such as the maintenance of intracellular pH. The ability of NSAIDs to uncouple oxidative phosphorylation also appears to be related to some extent to acidic moieties (such as carboxylic acid residues), since substitution at these sites interferes with the ability of these compounds to act as uncouplers. [8].

The aim of study: To study the toxicity of naproxen [non-steroid, anti-inflammatory compound (NSAIDs)], as they are of widely used in animal and human, for field treatment, and knowledge of clinical signs, microscopic changes and histopathological changes by toxic dose of naproxen.

MATERIALS AND METHODS

Sixty laboratory animals of mature male and female white rats were housed at the animal house of the college of veterinary medicine/ Basra university in cages, the drug, naproxen administered orally for three months by syringe of insulin after removal of the needle from the syringe, where handle the rat with one hand and

dosing the laboratory animal with the other hand, all those occurred after dissolving each tablet(500 mg) in 250ml of sterile distilled water and as following gavages (1ml) for each rat as high dose of naproxen(group-H), (1/2ml) for each rat as intermediate dose(group-I),(1/4ml) for each rat as low dose of naproxen (group-L), daily for -3-months and after that at the end of experiment each rat was anesthetized and scarified for purpose of examination of the stomach and intestine as macroscopic changes examination and preparation of organs for histological techniques and staining processing such as haematoxylin and eosin stains as microscopic changes.

RESULTS

Histological changes (microscopic evaluation): as followings. the experimental rats, after three months of administration with naproxen sodium (as NSAIDs), the Microscopically Study of stomach was done. The results showed various changes in the gastric tissue, as in (figure 3,4-A,4-B as high dose of naproxen).and those results of histo-pathological examination included inflammatory cells in the serosa, presece of prominant ganglion cells in the distal part of muscularis externa, in addition to that there was vacuolation of mucous lining cells, where those results of histological changes were more severe than(group-I) of naproxen sodium, as in (figure.1-A,1-B),which showed degeneration of mucosal epithelial and mucosal gland in the lamina propria of stomach(glandular region).when compared to those results of normal gastric tissue,which have normal size and shape of mucous lining cells and also normal mucosa and serosa of stomach ,that represented in (figure-2 as untreated group), but the histo-pathological examination results of the naproxen sodium treated group as high dose for organ of small intestine, showed in(figure.7-A,7-B),the following histological changes. there was ulceration of the small intestine, where the pathological changes for high dose of naproxen was more severe than intermediate dose(group-I),as in (figure.5-A,5-B),and where the histological changes in that figures, In addition, there was increased length of the villi and presence of inflammatory cells in lamina properia, in comparison with control group(group-C),as in(figure-6) which showed normal size and shape of the villi of small intestine, and considered as(untreated group).

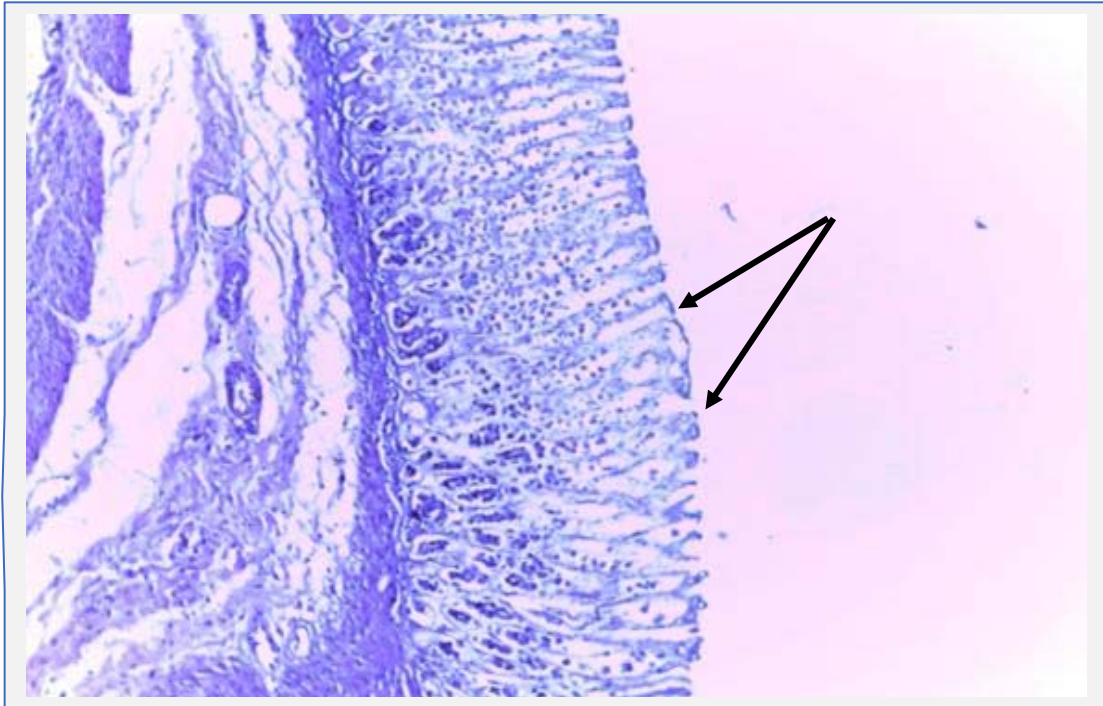


Figure (1-A) stomach(glandular region)/degeneration of mucosal epithelial and mucosal gland in the lamina propria naproxen/intermediate dose 10x(A), [H&E stain].

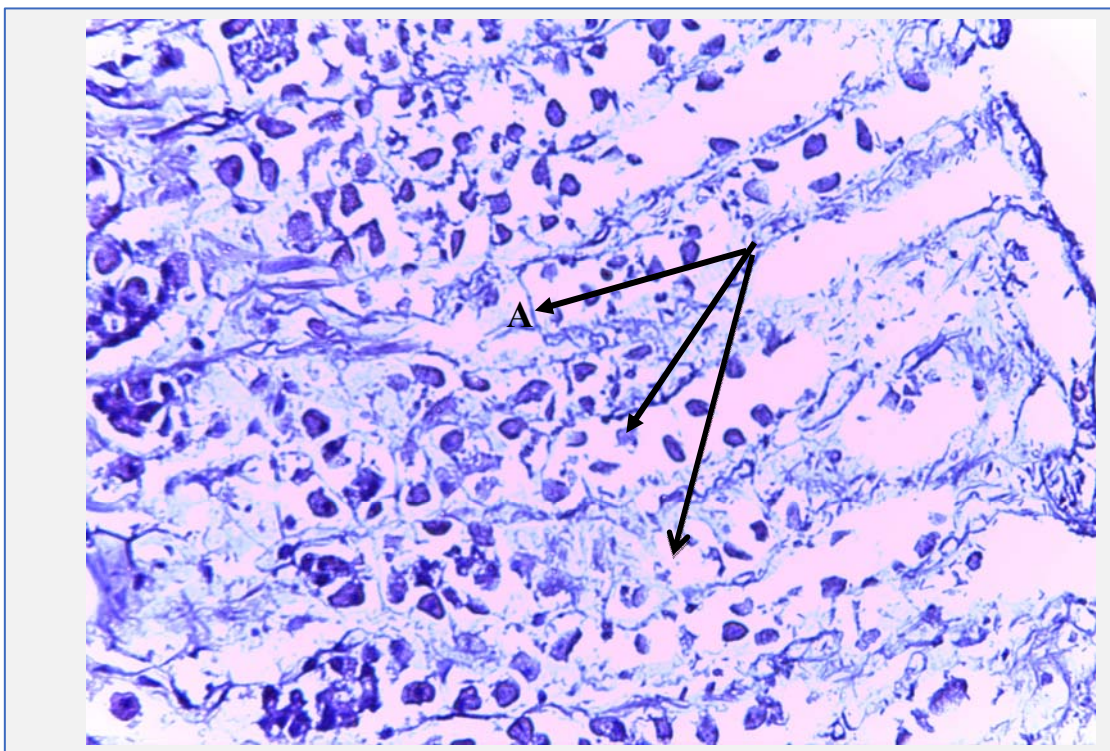


Figure (1-B)The same figure but with higher magnification/ stomach(glandular region)/degeneration of mucosal epithelial and mucosal gland in the lamina propria naproxen/intermediate dose 40x(A), [H&E stain].

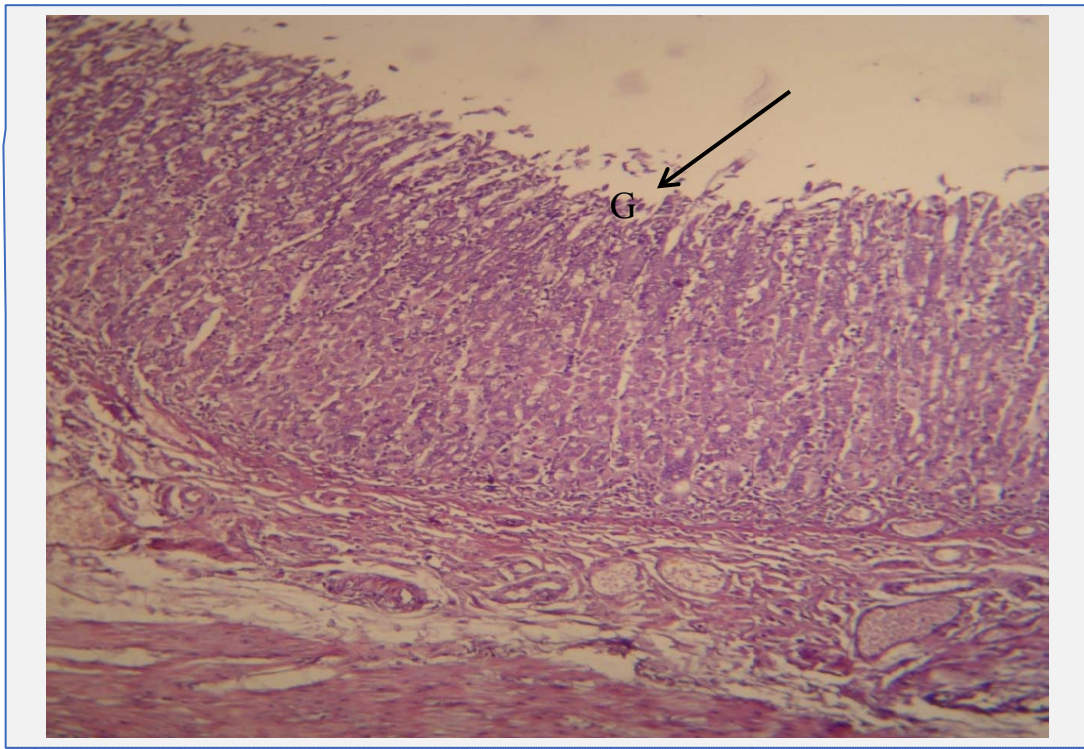


Figure (2) Normal Stomach/gastric mucosa within normal limit (G), 10X, H&E stain.

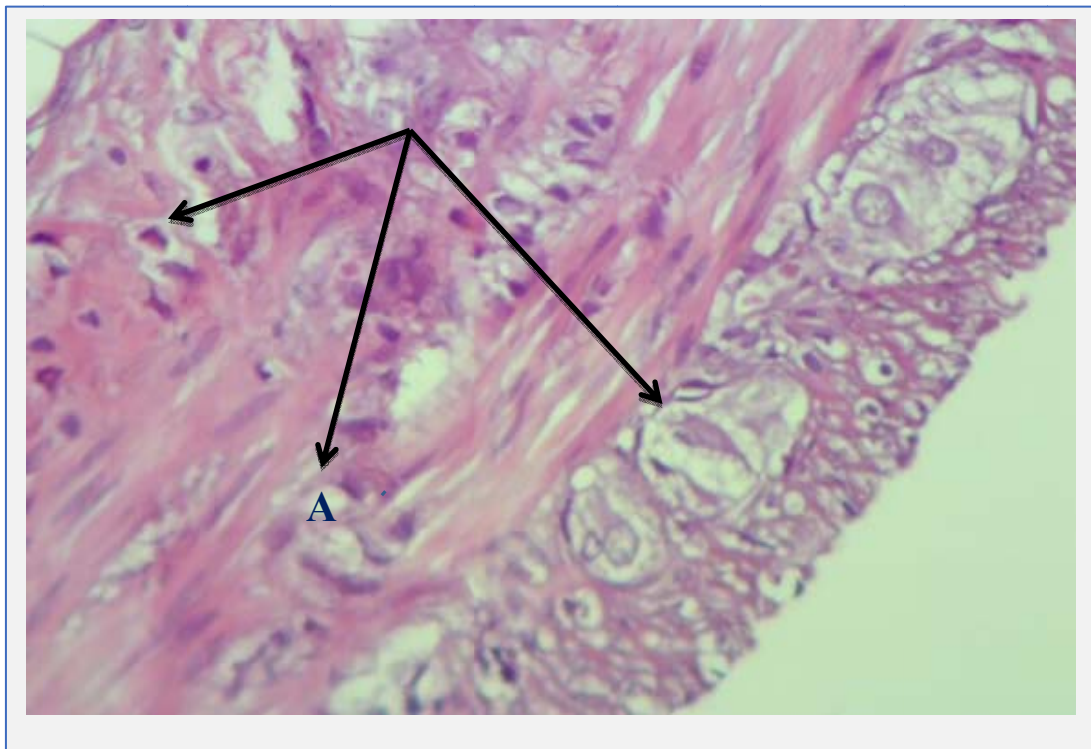


Figure (3) stomach/inflammatory cells in the serosa, note present of prominent ganglion cells in the distal part of muscularis externa 40x naproxen/high dose(A), [H&E stain].

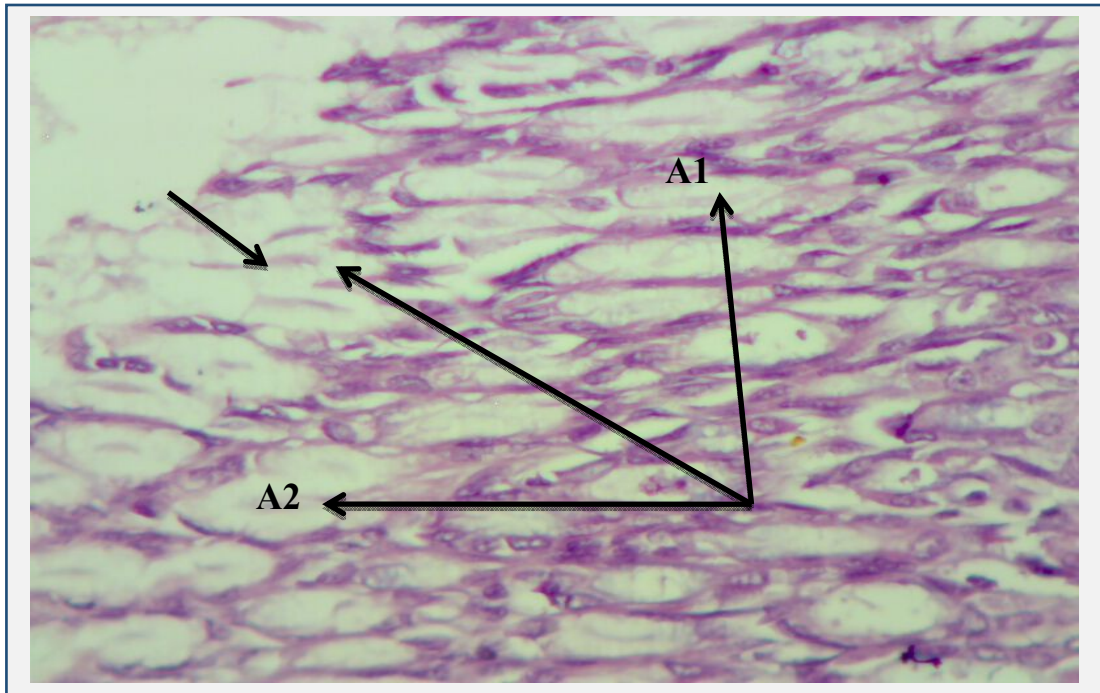


Figure (4-A) stomach/vacuolation of mucous lining cells 40x, naproxen/high dose (A1+A2, H&E stain).

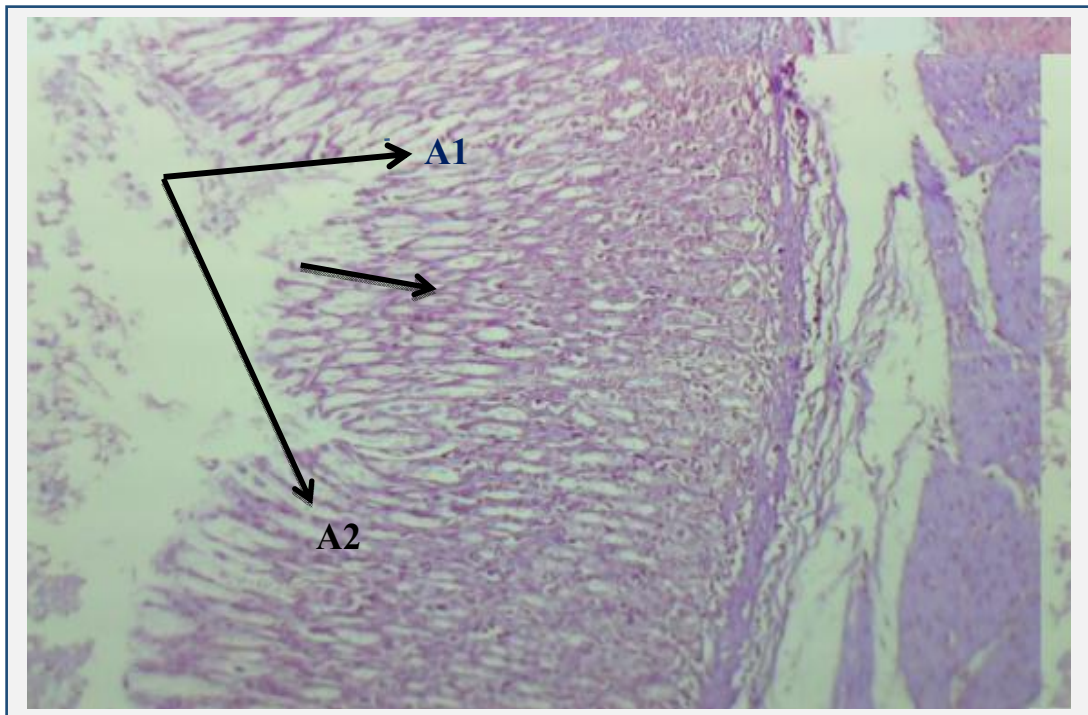


Figure (4-B)The same figure but with lower magnification/ stomach/vacuolation of mucous lining cells 10x, naproxen/high dose (A1+A2, H&E stain).

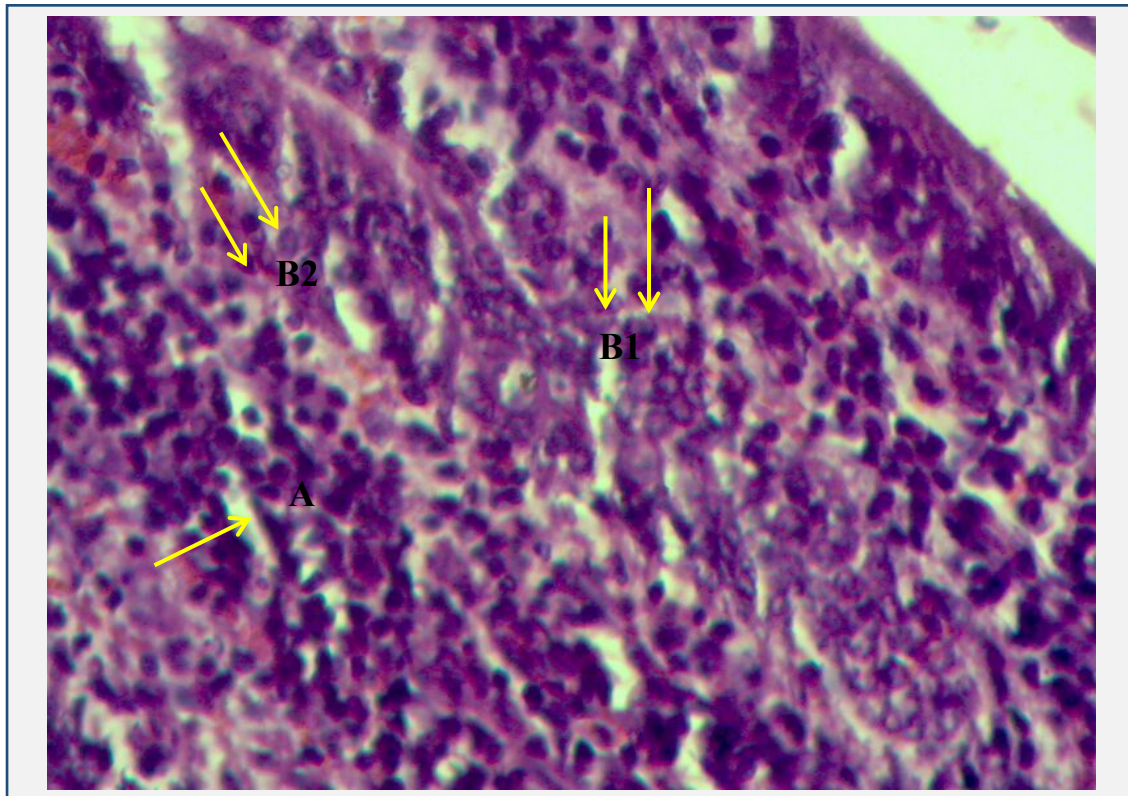


Figure (5-A) small intestine/one arrow of increase length of the villi[A1] and two arrows of inflammatory cells in lamina propria[B1+B2],40x naproxen/intermediate dose,(H&E stain).

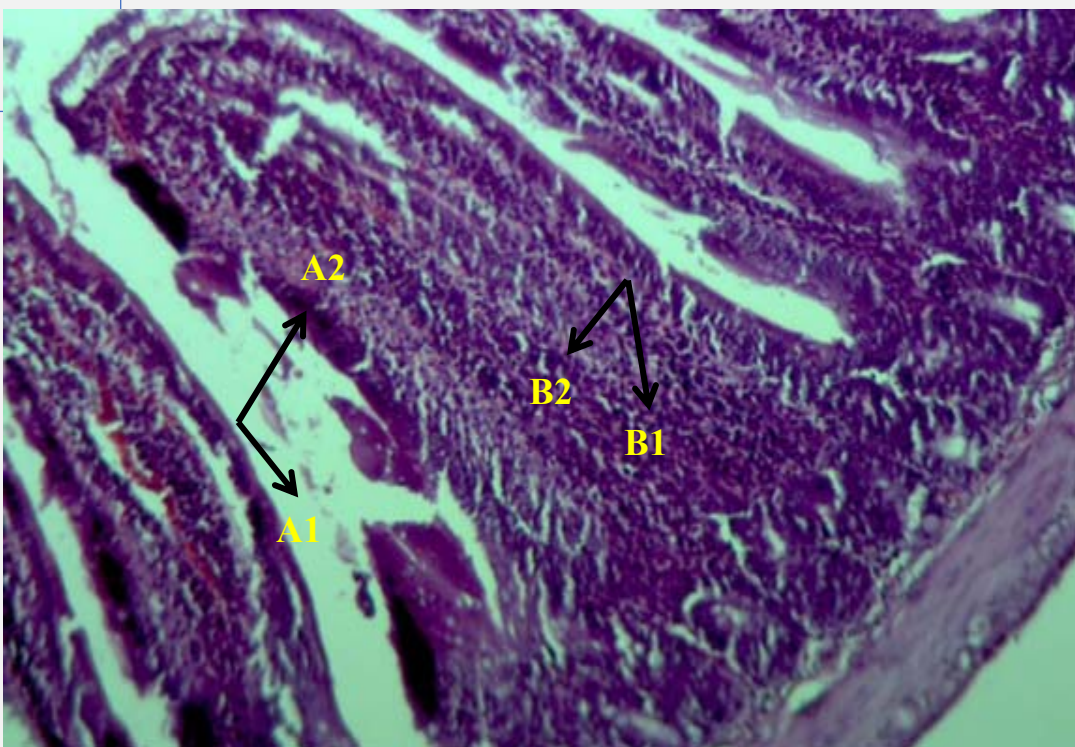


Figure (5-B)The same figure but with lower magnification/ small intestine/one arrow of increase length of the villi[A1+A2] and two arrows of inflammatory cells in lamina propria[B1+B2], 10x naproxen/intermediate dose,(H&E stain).

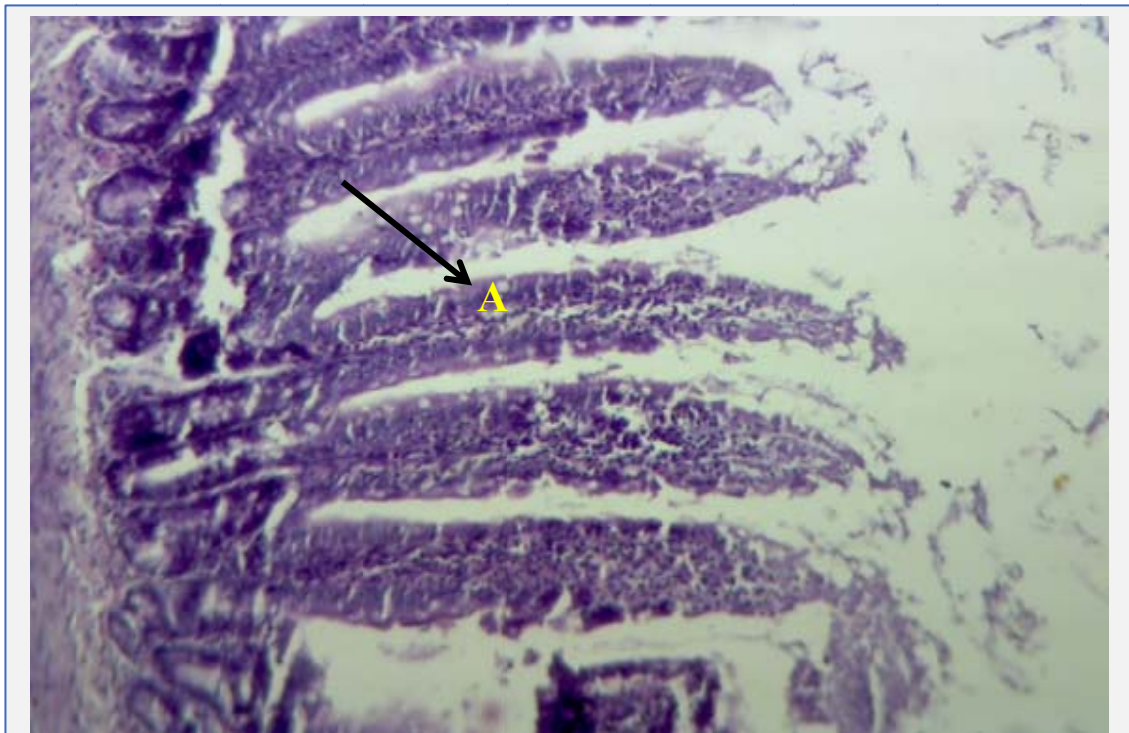


Figure (6) small intestine/control 10x(villi within normal limit,(A), [H&E stain].

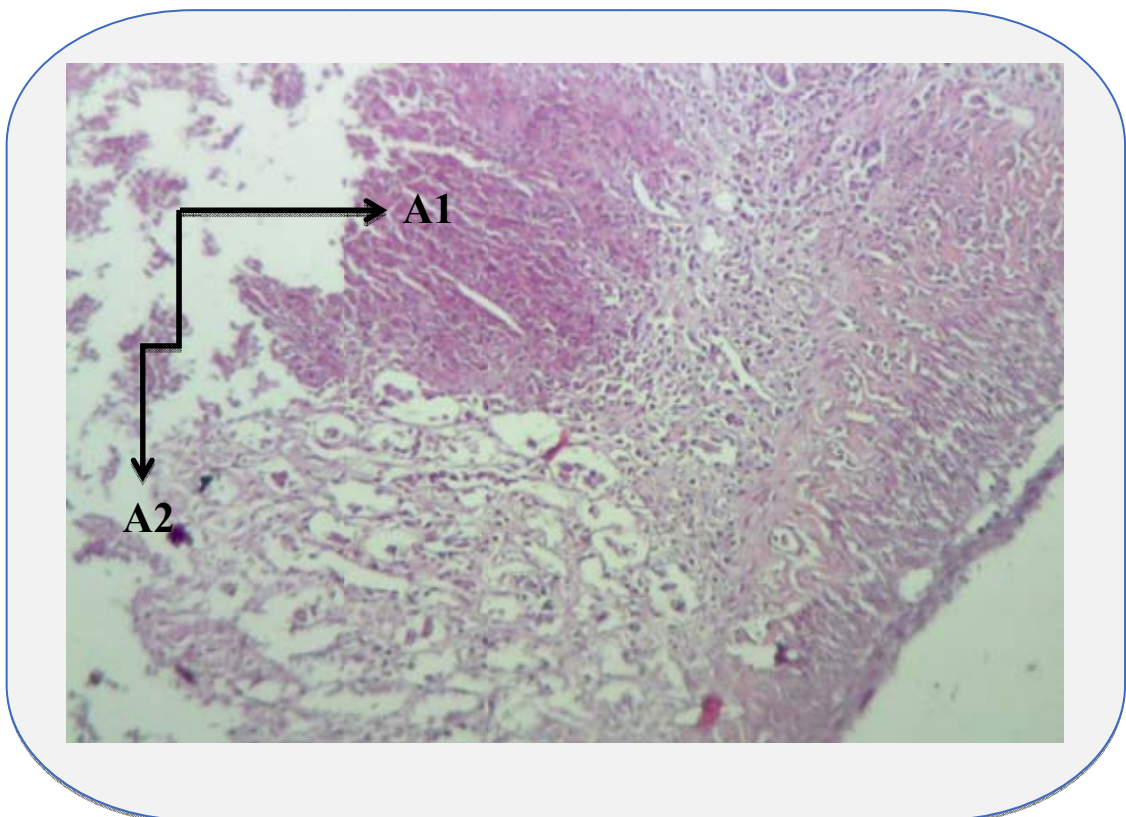


Figure (7-A) small intestine/Ulceration of the small intestine, Naproxen/high dose, 10x, (A1+A2, H&E stain).

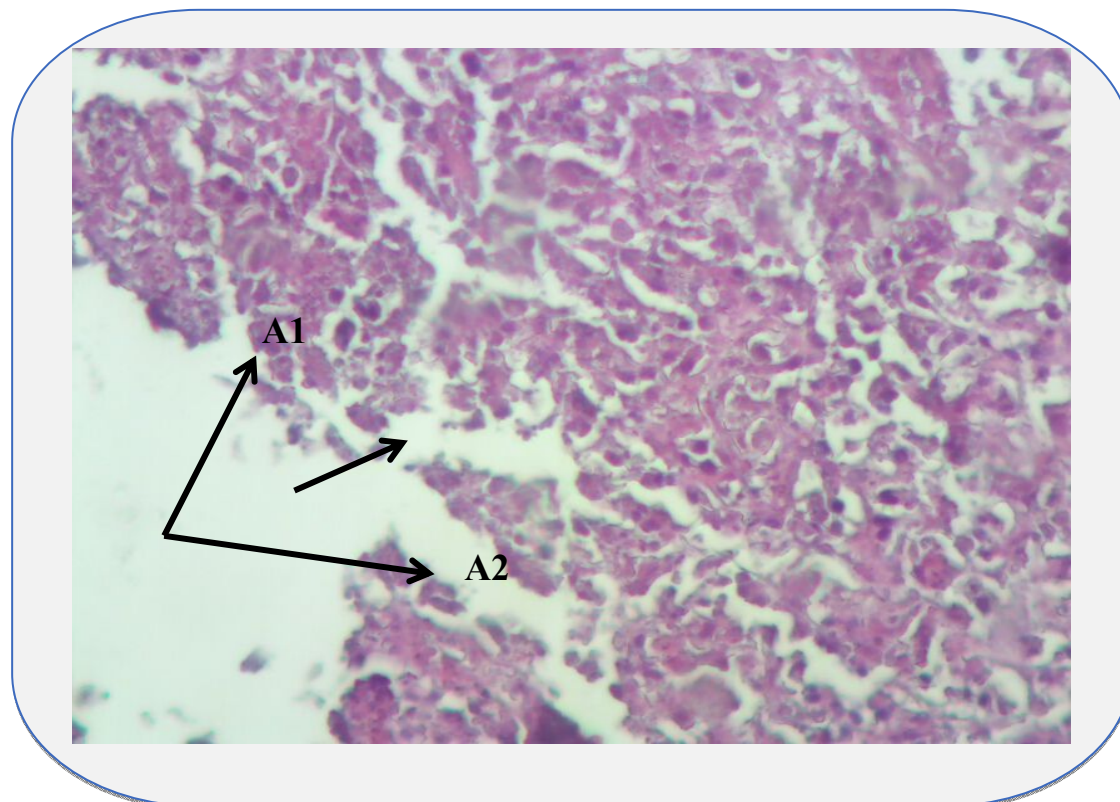


Figure (7-B)The same figure but with higher magnification/ small intestine/Ulceration of the small intestine, Naproxen/high dose, 40x, (A1+A2, H&E stain).

DISCUSSION

In the experimental rats, and after the administration of naproxen sodium(as NSAIDs),the current study observed that there were histo-Pathological changes of stomach, The microscopically study showed, various changes in the gastric tissue, and those results of histo-pathological changes included inflammatory cells in the serosa, presence of prominent ganglionic cells in the distal part of muscularis externa, in addition to that there was vacuolation of mucous lining cells, where those results of histological changes were more severe than(group-I) of naproxen sodium, which showed degeneration of mucosal epithelial and mucosal gland in the lamina propria of stomach(glandular region).Those results agreed with (Richard Haworth, *et al.*,2005),[9].There was An interesting observation in our study which was the high levels of COX-2 expression observed at the junctional ridge of the stomach, relative to the fundus and pylorus. The junctional ridge and ICJ(ileocaecal junction) share

some anatomical features in that they were functional interfaces between dissimilar parts of the GIT. The junctional ridge is known to be subjected to local damage resulting in inflammation and epithelial vacuolation. Similar susceptibility to damage and inflammation may explain the high levels of COX-2 expression at the ileocaecal junction (ICJ).,also our results of histo-pathological examination for naproxen sodium treated groups as high dose showed as another histological changes for organ of small intestine, which represented with ulceration of the small intestine, and where the pathological changes for high dose of naproxen was more severe than intermediate dose(group-I of naproxen),which included, also increase length of the villi and presence of inflammatory cells in lamina propria, Those results agreed with.(Helenie Kefalakes, *et al.*,2009),[10], which were supported various pathogenic mechanisms have been suggested to be involved in the development of gut lesions from NSAIDs. A model suggested by some researchers, proposes that the main pathogenic steps of the NSAIDs effect on intestinal mucosa include the increase of mucosal permeability that leads to inflammation, ulceration, bleeding, and gut perforation [11].

ACKNOWLEDGEMENT

I would first like to express my gratitude to college of veterinary medicine, and also would like to thank all the researchers who contributed to this research by sharing their knowledge with complete openness and enthusiasm. Finally, I would like to thank all my friends and family for offering me all the help I needed to earn my degree.

الامراضية السمية للنابروكسين (كعامل مضاد التهاب الغيرستيرويدية) على القناة المعوية في

الجرذان البيضاء

ثائر علي صالح كاظم زينب وحيد

فرع الأمراض وأمراض الدواجن، كلية الطب البيطري، جامعة البصرة، البصرة، العراق.

الخلاصة

في الجرذان البيضاء، ومن ثم الكشف (NAP) تم إنجاز الدراسة الحالية لتحقيق سمية صوديوم نابروكسين عن الآلية المرضية لإصابة المعدة والأمعاء التي يسببها المسكنات (نابروكسين) على مدى العقدين الماضيين. واستخدمت في هذه الدراسة (٤٨) جرذ. كما شملت الدراسة استخدام مضمون المواد التي يتم استئصالها مع (نابروكسين). ووضعت جميع المجموعات الحيوانية للجرذان في نفس الظروف من درجة الحرارة والرطوبة، (جرذ)، وتتضمن هذه المجاميع حسب التقسيم التالي، 12 وحيث أنها قسمت إلى أربع مجموعات، ولكل مجموعة

التي (L) وتمثل (المجموعة غير المعالجة)، الذي تعامل مع المحلول الملحي العادي، ومجموعة (C) مجموعة تمثل الجرعة المتوسطة (I) تمثل الجرعات المنخفضة (٥ مغ/كغ) من الصوديوم نابروكسين، بينما مجموعة بالجرعة العالية، التي تلقت (٢٠ مغ/كغ). وطريقة إعطاء الجرعات لهذه (H) (١٠ مغ/كغ) وتمثل المجموعة الحيوانات بواسطة التجريب الفموي واستمرت لمدة ثلاثة أشهر. أما نتائج هذه الدراسة شملت وجود تغيرات عيانية، كالتغيرات الأقل ما يمكن في البطانة المخاطية لجدار المعدة أو البطانة الطلائية لجدار المعدة، وأيضا شملت وجود تغيرات مجهرية، كالتقرح في الأمعاء الدقيقة، بالإضافة إلى وجود زيادة طول الزغابة مع وجود خلايا التهابية في الصفيحة المخصصة، وأيضا كان هناك وجود تنكسات البطانة المخاطية والغدد المخاطية في الصفيحة المخصصة، كما كان هناك تكون فجوات في خلايا البطانة المخاطية للمعدة، وكان هناك خلايا التهابية في الطبقة المصلية، مع ملاحظة وجود خلايا عقديه بارزه في الجزء الأقصى للطبقة العضلية الخارجية للمعدة، حيث وجدت التغيرات الامراضية للجرعة العالية من النابروكسين وكانت أكثر حدة من الجرعة المتوسطة والمنخفضة للنابروكسين.

REFERENCE

- 1-Runkel R, *et al.* pharmacokinetics of naproxen overdose. Clin pharmacol Therap 1976;20:269-277.
- 2-Segre EJ. Naproxen sodium (Anaprox): pharmacology, pharmacokinetics and drug interactions. J Reprod Med, 25(4 Suppl), 222(1980).
- 3-Lo, A., Addison, R.S., Hooper, W.D., Dickinson, R.G.: Disposition of naproxen, naproxen acyl glucuronide and its rearrangement isomers in the isolated perfused rat liver. xenobiotica, 31 (6), 309 (2001).
- 4-Thiefin G, Beaugerie L (2005) Toxic effects of non-steroidal anti-inflammatory drugs on the small bowel, colon, and rectum. Joint Bone Spine 72(4):286–294.
- 5-Rainsford KD (1999) Profile and mechanisms of gastrointestinal and other side effects of non-steroidal anti-inflammatory drugs (NSAIDs). Am J Med 107(6A):27S–35S..
- 6-Takeuchi K, Smale S, Premchand P, Maiden L, Sherwood R, Thjodleifsson B, Bjornsson E, Bjarnason I (2006) Prevalence and mechanism of non-steroidal anti-inflammatory drug-induced clinical relapse in patients with inflammatory bowel disease. Clin Gastroenterol Hepatol 4(2):196–202.

- 7-Somasundaram S, Hayllar H, Rafi S *et al.*** The biochemical basis of non-steroidal anti-inflammatory drug induced damage to the gastrointestinal tract: are view and a hypothesis. *Scandinavian Journal of Gastroenterology* 1995; 30: 289-299.
- 8. Mahmud T, Wriggles worth JM, Scott DL & Bjarnason I.** Mitochondrial function and modification of NSAID carboxyl moiety. *Inflammopharmacology* 1996; 42: 189-194.
- 9-Richard Haworth, *et al.*, (2005),** Differential Expression of COX-1 and COX-2 in the Gastrointestinal Tract of the Rat. Department of Pathology, Safety Assessment, GlaxoSmithKline Research and Development Ltd, Park Road, Ware, Herts SG12 0DP, United Kingdom; e-mail: richard.i.haworth@gsk.com.doi: 10.1080/01926230590906512 ,vol. 33 no. 2 239-245.
- 10-Helenie Kefalakes, (2009),** Exacerbation of inflammatory bowel diseases associated with the use of non-steroidal anti-inflammatory drugs: myth or reality. *Clinical Pharmacology*, Faculty of Medicine, University of Crete, Crete, Greece, DOI 10.1007/s00228-009-0719-3..
- 11-Thiefin G, Beaugerie L (2005)** Toxic effects of non-steroidal Anti-inflammatory drugs on the small bowel, colon, and rectum. *Joint Bone Spine* 72(4):286–294..