

Osteopetrosis Manifesting As a Femoral Fracture in Childhood:

A Case Report

Mahdi Abdul Sahib

Orthopedic surgeon / Director of Continuous Medical Education Center / Holly Karbala Health Directorate / Karbala / Iraq

Abstract

Osteopetrosis is a genetically determined bone disease that develops as a result of malfunction of osteoclastic activity leading to excessive deposition of immature bone, thickening of cortical bones and narrowing of the medullary cavities. The condition is rare; the overall incidence is estimated to be 2-10 per million populations.

We report a 9-years old child with osteopetrosis presented as pathological femoral fracture.

The clinical characteristics together with the negative family history, radiological findings of generalized osteosclerosis and laboratory results (mild anemia) suggest that our patient probably fits in to the intermediate autosomal recessive group of osteopetrosis.

Management presents a unique technical challenge in these patients because it often resulted in complications including blunting or breakage of drill bits, intraoperative fractures, delayed healing, nonunion and postoperative infections.

This report highlights for technical difficulties during surgery and, hence, prolonged operative time; therefore, preoperative planning is mandatory in the management of fracture in osteopetrotic bone.

المخلص

تصخر العظام هو مرض محددة وراثيا والذي يتطور نتيجة لخلل في نشاط الخلايا الناقضة للعظم والذي يؤدي إلى الترسيب المفرط للعظم غير الناضج ، وسماكة العظام القشرية ، وتضييق الفجوات النخاعية. هذه الحالة نادرة ؛ ويقدر المعدل العام بـ (2- 10) لكل مليون من السكان. تم توثيق حالة تصخر العظام لطفل عمره (9) سنوات في وضع كسر عظم الفخذ. الخصائص السريرية مع التاريخ العائلي السلبي والنتائج الإشعاعية والنتائج المختبرية تشير إلى أن المريض ربما ينتسب إلى المجموعة المتوسطة المقهورة من تصخر العظام. العلاج يعتبر تحديا فريدا من نوعه في هؤلاء المرضى بسبب المضاعفات التي قد تحدث في كثير من الأحيان بما في ذلك كسر من لقم الثقب ، وكسور العظم أثناء العملية ، وتأخر شفاء الكسر أو عدم الالتئام والالتهابات بعد العملية الجراحية. هذا التقرير يسلط الضوء على الصعوبات التقنية والجراحية والذي يتسبب إلى اطالة وقت العملية مما يوجب التخطيط المسبق قبل اجراء العملية ضرورياً في علاج الكسر في حالة تصخر العظام

Introduction

Osteopetrosis (also known as ivory bones, marble bones, Albers-Schönberg disease) is a genetically determined bone disease that develops as a result of malfunction of osteoclastic activity leading to excessive deposition of immature bone, thickening of

cortical bones and narrowing of the medullary cavities⁽¹⁾.

The condition is rare, the overall incidence is estimated to be 2-10 per million population and is most frequent in Costa-Rica⁽²⁻¹¹⁾, first described as a distinct entity by German radiologist Albers-Schoenberg in 1904. Approximately 300 cases of osteopetrosis have since been reported in the medical literature⁽¹²⁻¹⁵⁾.

Osteopetrosis presents with various symptoms and heterogeneous severity, from asymptomatic to fatal in infancy and has been classified into:

(1) Autosomal dominant Osteopetrosis (tarda) which is a rare condition in which patients aren't diagnosed until adulthood and life expectancy is normal. Patients with this type are characterized by short stature, either asymptomatic or with symptoms in form of fragile bones that fracture easily, pain and degenerative arthritis, tendency to develop osteomyelitis and normal hematopoiesis.

(2) Infantile autosomal recessive form of osteopetrosis (malignant). Patients with this type have neurological symptoms, hematologic abnormalities, and infection. Patients most often die during early childhood.

(3) Intermediate autosomal-recessive type of osteopetrosis is characterized by a milder course. Although this form is found in children less than 10 years of age but it usually does not lead to an early death. The patients of this group are often characterized by mild disproportionate short stature, macrocephaly, recurrent fractures, osteomyelitis and mild anaemia (2, 3, 7, 16, and 17)

This case report is of osteopetrosis with pathological femoral fracture.

Case report

In April 15, 2010 a 9-years old Iraqi child from Al-Hindyia in Karbala presented to the private clinic with a fracture of left femur due to a fall by relatively simple obstacle. Other than the last fracture he was without any problem neither orthopedic nor others. On physical examination the patient looked smaller for his age, with bossing forehead and malformed teeth (figure1). Mentality was normal and no hepatosplenomegally.

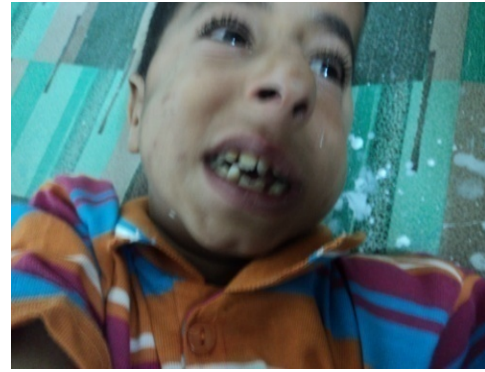

Figure 1 malformed teeth

X-ray of left femur showed short oblique fracture of upper third with abnormal increased bone density, metaphyseal widening and no differentiation between the cortex and the medulla giving chalk like appearance (Figure 2).

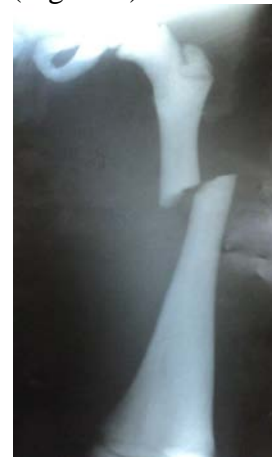

Figure 2. X-ray of left femur

Skeletal survey reveals generalized bone sclerosis affecting the skull, spine, pelvis and appendicular bones. (Figures 3)

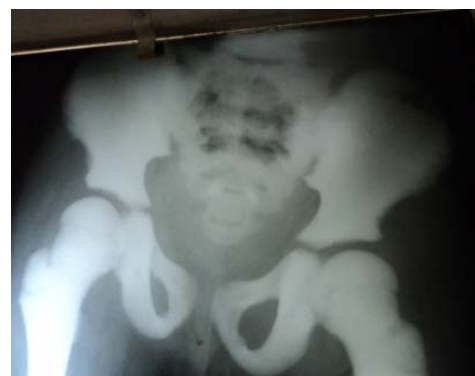

Figure 3. X-ray of pelvis showing generalized bone sclerosis

No family member was a known case of any bone disorder but, unfortunately, they refused to obtain radiographs for them.

Laboratory assessment of the child included hemoglobin of 9 g/dl, W.B.C was 11.000 / c. mm. serum electrolytes, calcium and alkaline-phosphates were normal.

The patient was admitted to the hospital. At first a pint of blood was given to correct the anemia. Under general anesthesia, open reduction through lateral approach and internal fixation of the fracture using plate and 6-screws was done in April 16, 2010.

The bone was hard, dense and the bone ends showed absent intramedullary canal (i.e. chalk-like consistency making drilling not as easy as in normal bone of similar age) (figure 4). The technique was by using a series of progressively larger drill bits, starting by 2 mm caliber drill followed by 3.2 mm drill then 4.5 mm tapping after that inserting the proper length of cortical screws, making operative time (about 75 minutes) slightly longer than the usual for such operation. No significant increase in blood loss was noted. The wound was closed and suction drain left.

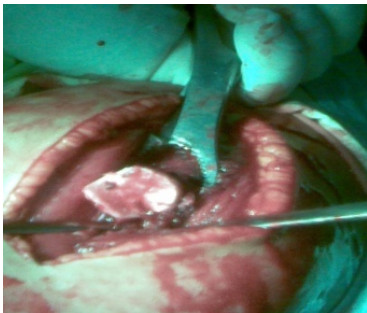


Figure 4. Operative finding showing no intramedullary canal

The immediate postoperative course was uneventful; the patient was afebrile, and after two days the drain was removed and the patient was discharged to complete his course of antibiotics at home.

On the tenth postoperative day, the wound was clean and the stitches were removed, and with thigh splint, allowing for ambulation with crutches, with non-weight bearing on his left lower extremity

Till the fourth post-operative weeks, the course was uncomplicated, X-ray of left femur showed evidence of mild callus (figure 5, 6) and with thigh splint allowing for ambulation with crutches, with partial weight bearing on his left lower extremity

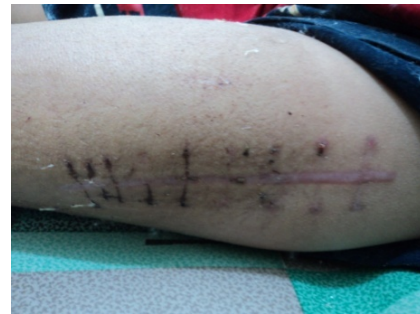

Figure 5. Fourth post- operative weeks

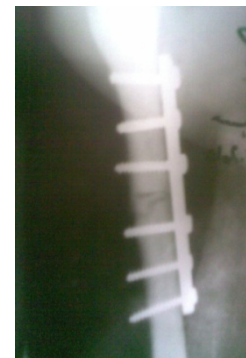

Figure 6. Fourth post-operative week clean wound incision

Unfortunately, after that the patient was lost for follow up until Jun 13, 2011 (i.e. more than one year) he came with clinical and radiological signs of complete bony union. The patient admitted and the plate and screws removed without problem (fig. 7).



Figure 7. After removal plate and screws

Discussion

The clinical characteristics (short stature) together with the negative family history, radiological findings of generalized osteosclerosis and laboratory results (mild anemia) suggest that our patient probably fits in to the intermediate autosomal recessive group of osteopetrosis.

For me this is the second patient of osteopetrosis I have seen during the 26-years of my practice in orthopedics; but the first was asymptomatic and discovered incidentally on X-rays.

To my knowledge, this is the first case of pathological femoral fracture presentation of osteopetrosis reported in Karbala. In 2009, Dr. Hussein Jassim AlKhateib has diagnosed one case in Iraq, male aged 8 years presented with generalized skeletal osteopetrosis associated with polyurea, polydipsia with neck stiffness and fever⁽¹⁸⁾. No other published case report about osteopetrosis in Iraq could be found.

Orthopedic importance in osteopetrosis is related to:-

1. The characteristic brittle "marble bone" in which pathological fractures are the main presenting feature of intermediate autosomal recessive⁽⁸⁾. Femoral fractures being the most frequent site⁽¹⁷⁾ (mostly in proximal shaft⁽¹⁹⁾), as seen in the fracture of our patient.
2. A reduced marrow space results in decrease in hematopoiesis. Extramedullary hematopoiesis occurs but is unable to compensate for the reduction in medullary blood cell production resulting in thrombocytopenia and anaemia as found in this patient.⁽²⁰⁾
3. There is a paucity of literature on the optimal management of fractures in osteopetrotic bone⁽³⁾. Management presents a unique technical challenge and orthopedic surgery is difficult⁽¹⁰⁾ in these patients because often resulted in complications including blunting or breakage of drill bits⁽¹⁰⁾, intraoperative fractures, delayed healing, nonunion,

postoperative infections and prosthesis loosening⁽¹⁷⁾.

The possible pitfalls with plate and screws are breakage of the drill and insecure hold screws.

While osteopetrotic bone may be penetrated with a drill bit, but the drill bit flutes are immediately filled with bone and this renders the drill ineffective, and generation of significant frictional heat can result in breakage of the drill^(2,3). This explains why the operative time in our patient was longer than usual because more patience and extreme care were needed to avoid both breakage of drill bits and iatrogenic fracturing the brittle bone. The hardness and fragility of the bone combined with a biomechanical inability to securely hold screws add to further difficulties for successful treatment by plate and screws⁽¹³⁾.

Regarding intramedullary fixation, obliteration of the canal and hardness of the bone make difficulty in identifying and opening the canal intraoperative for inserting standard intramedullary fixation in osteopetrotic patient. Ashby⁽²¹⁾ also found that drilling and reaming of the medullary canal to be difficult and time consuming⁽¹⁰⁾. It takes an average of 2 - 4 hours longer than a standard intramedullary nailing. Jones and Hung⁽¹⁰⁾ broke 2 drill bits while fashioning the medullary canal. Chhabra et al⁽³⁾ used a series of progressively larger drill bits to overcome this difficulty and despite this caution, several drill bits break during the procedure. Matsumo⁽¹⁰⁾ used high-speed burrs to prepare the femoral canal.

The lack of elasticity of osteopetrotic bones probably accounts for iatrogenic fractures during surgery⁽¹⁷⁾. In 1992, Ashby⁽³⁾ reported iatrogenic comminution of distal fragment, which occurred while driving the intramedullary nail into the newly formed canal. This difficulty emphasizes the overall fragility of the bone in patients with osteopetrosis despite the bone's hardness and resistance to drilling and reaming.

To avoid possible fracture or perforation, Reagon et al⁽¹⁰⁾ used instruments made from

tungsten carbide (especially femoral reamers and drills) with considerable effort, great care and under radiographic control. The metal properties of tungsten carbide are ideal because it is harder, has greater resistance to wear, and is less prone to fracture than stainless steel⁽¹⁰⁾.

The only report of external fixation of an osteopetrotic bone by Belz et al in 1988, which used a uniplanar external fixation for femoral shaft fracture applied via six lateral femoral pins.

The patient demonstrated complete osseous union of the fracture with removal of the external fixator at 13 weeks.

Fractures heal, but the healing time is often prolonged⁽²¹⁾. Yang et al⁽³⁾ in 1980 noted satisfactory callus formation after nine months postoperatively in a 21 year-old woman with osteopetrosis with a left femoral subtrochanteric fracture.

Dense, poorly vascularized bones⁽²⁰⁾ and impaired white blood cell function^(13, 22) increase the incidence of necrosis and osteomyelitis. Prolonged operative time also increase the risk of post-operative infection⁽¹⁵⁾. Ashby's⁽³⁾ second case was complicated by a deep infection postoperatively. Long bone infections, once established in patients are difficult to eradicate⁽²⁾. Great care and more effort required to minimize the risk of postoperative infection in this difficult group.

Conclusions

The condition of our patient is intermediate autosomal recessive form of osteopetrosis, presenting with pathological femoral fracture.

This report highlights for technical difficulties and surgery can be prolonged that make preoperative planning is mandatory in the management of fracture in osteopetrotic bone.

To avoid the risk of iatrogenic fracture in brittle and fragile osteopetrotic bone, more patience and caution are required during drilling and reaming for plating as well as intramedullary fixation.

Acknowledgement

The author wish to thank Dr. Saad A. Ghaban for the support in the preparation of this manuscript.

References

1. Aimun AB Jamjoom, Bakur A Jamjoom, Abrar R Waliuddin, Abdulhakim B Jamjoom. Lessons from a case of osteopetrosis oxycephaly and Chiari type I malformation: a case report. *Cases Journal* 2009, 2:6787
2. Sabrina Fudge, Rouin Amirfeyz, Donna Dimond, Martin Gargan. Marble bone disease. *Current Orthopaedics*. 2007. 21, (6) 438-44.
3. Anikar Chhabra, L. Erik Westerlund, Alex J. Kline, Robert McLaughlin. Management of Proximal Femoral Shaft Fractures in Osteopetrosis: A Case Series Using Internal Fixation.
4. C Ramulu, G Narasimha Reddy. Osteopetrosis With Osteomyelitis Of the Mandible. *Indian Journal of Orthopaedics* 1977, 11:111-113
5. <http://en.wikipedia.org/wiki/Osteoclast>. visited at 16 March, 2011.
6. Stoker DJ. Osteopetrosis. *Semin Musculoskelet Radiol* 6(4):299-305, 2002.
7. Andrea Del Fattore, Alfredo Cappariello, b and Anna Tetia. Review Genetics, pathogenesis and complications of osteopetrosis. *Bone*. Volume 42, Issue 1, January 2008, Pages 19-29.
8. Girish Baburao Kulkarni, P.K. Pal, C. Shyambabu, J.M.E. Kovoov and E. Senthilkumar. Osteopetrosis manifesting as recurrent bilateral facial palsy in childhood: A case report. *Clinical Neurology and Neurosurgery*. Volume 113, Issue 3, April 2011, Pages 230-234.
9. Ailbhe C. O'Neill and Eric J. Heffernan. Autosomal recessive osteopetrosis with Arnold Chiari malformation type 1 and syringomyelia. *European Journal of Radiology Extra*. Volume 76, Issue 1, October 2010, Pages e23-e26.
10. Reagon D. Ramiah, Richard P. Baker and Gordon C. Bannister. Conversion of Failed Proximal Femoral Internal Fixation to Total Hip Arthroplasty in Osteopetrotic Bone. *The Journal of Arthroplasty*. Volume 21, Issue 8, December 2006, Pages 1200-1202.
11. Dr Richard Draper. Osteopetrosis. Copyright © 2011 EMIS Last Updated: 21 Nov 2010. Visited at 15 March, 2011.
12. I. Semba, T. Ishigami, K. Sugihara and M. Kitano. Higher osteoclastic demineralization and highly mineralized cement lines with osteocalcin deposition in a mandibular cortical bone of

- autosomal dominant. Original article. Bone September 2000 : 27, (3), 389-395
13. Zornitza Stark and Ravi Savarirayan. Osteopetrosis. *Orphanet J Rare Dis.* 2009; 4: 5.
 14. Abdul-Latif H Hamdan, Mona M Nabulsi, Firas T Farhat, Rashid K Haidar, and Nabil S Fuleihan. When bone becomes marble: Head and neck manifestations of osteopetrosis. *Paediatr Child Health.* 2006, 11(1): 37-40.
 15. Amit Bhargava, Manesh Vagela and C.M.E. Lennox. "Challenges in the management of fractures in osteopetrosis"! Review of literature and technical tips learned from long-term management of seven patients. *Injury.* 2009, 40(11): 1167-1171.
 16. <http://www.medterms.com>. Definition of Osteopetrosis..
 17. O. D. Bénichou , J. D. Laredo and M. C. de Vernejoul. Type II autosomal dominant osteopetrosis (Albers-Schönberg disease): clinical and radiological manifestations in 42 patients *Bone.* 2000, 26(1): 87-93.
 18. Osteopetrosis (infantile, malignant Type), Marble Bone Disease: osteopetrosis in Iraq. available in <http://www.kinderradiologie>
[online.de/cgi-bin/textin/index.cgi? readmes=2929&Bereich=Diskussionsforum&lang=en](http://www.kinderradiologie) at 3 April 2011
 19. Milgram JW, Jasty M. Osteopetrosis. A morphological study of 21 cases. *J Bone Joint Surg Am.* 1982; 64:912-929.
 20. L. Lyndon Key Jr. and William L. Ries Osteopetrosis (Chapter 69) *Principles of Bone Biology (Second Edition)* 2002, 1217-1227.
 21. Ashby ME. Total hip arthroplasty in osteopetrosis: a report of two cases. *Clin Orthop.* 1992; 276:214-221.
 22. Alexandre Elias Trivellato, Michel Campos Ribeiro, Cassio Edvard Svezut, Ermanno Bonucci, Antonio Nanci, and Paulo Tambasco de Oliveira. Osteopetrosis Complicated by Osteomyelitis of the Maxilla and Mandible: Light and Electron Microscopic Findings. *Head Neck Pathol.* 2009; 3(4): 320-326.
 23. The American Heritage® Medical Dictionary Copyright © 2007, 2004, Published by Houghton Mifflin Company.