

## Laparoscopic Surgical Anatomy of Calot`s Triangle

Adnan Al Helli; CABS, Mohammad Al Tae\*\*; CABS, Majid Al Khafaji\*\*; CABS

\* Dept of Surgery, College of Medicine, University of Karbala,

\*\*Senior Surgeon in Hillia Teaching Hospital

### Abstract

**Introduction:** Calot`s triangle is an anatomical space in the subhepatic region contains the cystic duct and cystic artery. These structures are of normal arrangement and configuration in about three quarters of people. Laparoscopic cholecystectomy now is the gold standard surgical procedure for the treatment of cholecystolithiasis but is associated with significant incidence of operative injuries. Recognition of the normal and variations of the surgical anatomy in this space is essential in order to reduce the incidence of these events.

**Aims:** to start Iraqi data base, improve anatomy recognition and reduce laparoscopic complication.

**Method:** Through a prospective observational study we identified the cystic artery and cystic duct characters within Calot`s triangle during Laparoscopic Cholecystectomy operations.

**Results:** 200 cases, 96% females.

*Cystic artery;* total single artery; 179, 89%, double cystic arteries; 21, 10.5%, normal configuration; 133, 66%, total artery anomalies; 67.33.5%.

*Cystic duct;* normal ducts; 125/62.5%, total anomalies; 75/37.5% and other details.

**Discussion:** the anatomy of Calot`s triangle is puzzling and surgeons should be aware of this fact. The published studies are of variable ranges, arterial variations are more frequent than ductal anomalies. Studies implementing Laparoscopic methodology sound the most accurate. The current study denotes higher incidences of normal cystic arteries and lower incidence of normal cystic duct compared to global ranges. Probably ethnic reasons play part in these differences. It is the time to start national data base system and implement more accurate diagnostic tools to improve diagnostic and therapeutic standards.

**Key wards:** Calot`s Triangle, cystic duct and cystic artery variations, laparoscopic cholecystectomy.

### المخلص

**المقدمة:** مثلث "كالوت" تشريحيا هو منطقة تقع خارج أسفل الكبد يحوي قناة وشريان كيس الصفراء اللذان في صفات تشريحية طبيعية في ثلاثة أرباع الناس فقط.

وان كانت عملية استئصال المرارة ناظوريا هي العلاج المعياري لحصاة المرارة حاليا إلا أنها قد تصطب بمضاعفات جراحية مهمة. الإدراك الوافي للطبيعة والمتغيرات التشريحية الجراحية في هذه المنطقة ضروري خفض نسبة المضاعفات الناتجة عن هذه الجراحة.

**أهداف البحث:** المساهمة في بناء قاعدة بيانات تشريحية وطنية, لخفض نسب مضاعفات الجراحة التنظيرية.

**طريقة البحث:** من خلال إجراء عمليات استئصال المرارة ناظوريا تم تسجيل المشاهدات التشريحية ضمن نطاق هذه المنطقة التشريحية.

**النتائج:** عدد المرضى 200 الإناث منهم 96% , شريان الصفراء المنفرد (179) 89%, الشريان المزدوج: (21), 10.5%, الشكل الطبيعي للشريان (133), 66%, التغيرات الخلقية للشريان: (67), 33.5%, قناة الصفراء الطبيعي (125), 62%, التغيرات الخلقية (75) 37.5%

**المناقشة:** الصفات التشريحية لمنطقة مثلث كالوت كثيرة المتغيرات وعلى الجراح اتخاذ الحيطة والحذر.

معلومات البحوث المنشورة متباينة القيم ولكن على العموم المتغيرات التشريحية في شريان الصفراء أكثر شيوعا من حدوثها في قناة الصفراء. البحوث التي اعتمدت طريقة تنظير البطن أكثر واقعية. البحث الحالي اشر نسبة اعلي في الشريان الطبيعي وأوطأ في القناة الطبيعية من البحوث المنشورة. ربما كان بسبب هو التباين العرقي في مادة البحوث. من المهم أن نبدأ بإنشاء قاعدة بيانات وطنية للمتغيرات التشريحية وكذلك من المناسب والمهم إدخال واعتماد طرق معاصرة أكثر تطورا وكفاءة في التشخيص, وتعيين الشكل التشريحي قبل العملية والمعالجة.

## Background

The French surgeon Jean-François Calot, at 1891, first described a triangular anatomical space in the sub-hepatic area, hence it was called Calot's triangle, his original definition was not including the inferior surface of liver as a boundary, <sup>(1)</sup> Later Calot's triangle (hepatobiliary or cystohepatic triangle) became defined as an area of the cystic pedicle bordered by the common hepatic duct medially, the cystic duct inferiorly and the liver superiorly with the cystic artery within the triangle fig 1. Hepatic artery and an aberrant hepatic duct commonly passes through this triangle <sup>(2, 3)</sup>.

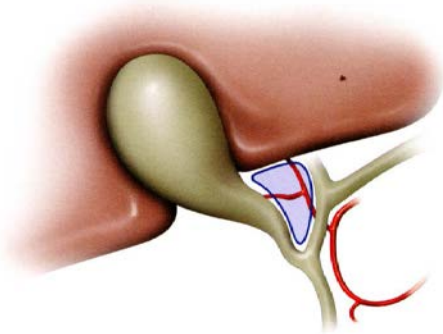


Fig 1. The boundaries of Calot's triangle

The cystic pedicle itself is a triangular peritoneal fold of hepatoduodenal omentum has continuous superior and inferior layers and anteriorly sheathing over the cystic duct. This pedicle contains; fat, cystic artery, cystic duct and Calot's (sentinel) lymph node located near the cystic artery.

**Blood vessels within Calot's triangle:** Normally in (62%-85%) the cystic artery is a single artery arises from the geniculat flexure of the right hepatic artery in the upper portion of the "Calot's" triangle, it runs postero-superior to the cystic duct but a site of origin from a more proximal or distal portion of the right hepatic artery is also considered relatively normal <sup>(1,6)</sup>. The cystic artery runs superiorly to become

adjacent to the cystic duct, here it produces 2 to 4 minor branches the "Calot's arteries" which supply part of the cystic duct and cervix of the gallbladder then divides into major superficial and deep branches at the superior aspect of the gallbladder neck Fig2,3.

The superficial branch (anterior branch) passes sub-seriously over the left aspect of the gallbladder. The deep branch (posterior branch) runs between the gallbladder and gallbladder fossa terminates at the peritoneum attached to the liver surface <sup>(7)</sup>. Anteriorly there is an anastomosis between the arterial branches of gastro duodenal and right hepatic arteries within the triangle. <sup>(8)</sup>

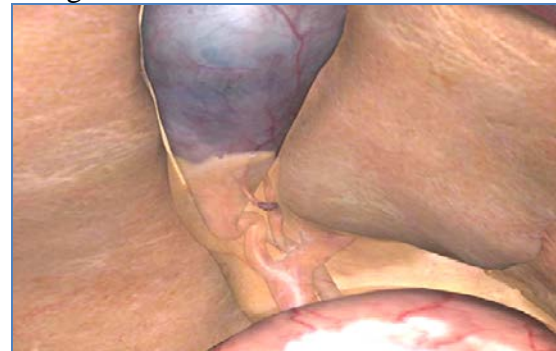

Fig 2. Lap.photo of porta-hepatis

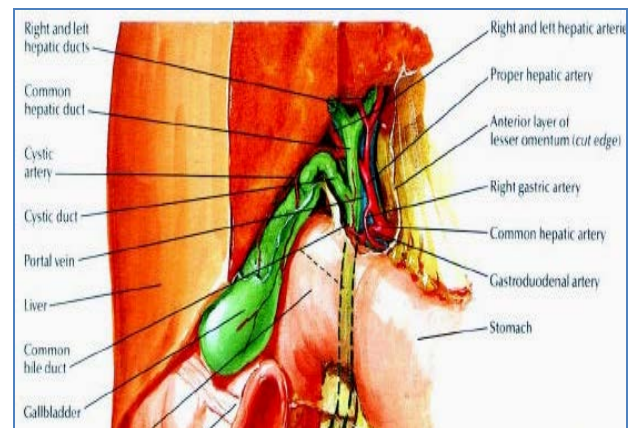


Fig 3. Porta hepatis anatomy, Ref <sup>(2)</sup>

The veins of gallbladder do not accompany the cystic artery within the triangle. Blood from the deep surface of the gall bladder drains directly into the liver through the gall bladder bed. Veins from the superficial surface unite to form the cystic vein drains also into the liver <sup>(9)</sup>.

*Ducts within Calot's triangle:* In 67%-80% of people the cystic duct joins hepatic duct on the right side by an acute angle halfway between the portal hepatic and the ampulla of Vater 3cm distal to the confluence of hepatic duct. It is 2-4 cm in length and 1-5 mm in diameter. Frequently it exhibits a tortuous serpentine course within the triangle and may cross the anterior wall of the bile duct to insert medially. The last short distance commonly parallels hepatic duct<sup>(4,10)</sup>.

Laparoscopic cholecystectomy has gained acceptance and considered the "gold standard" in treating symptomatic cholecystolithiasis. However, according to many studies the incidence of injuries during this procedure is two times as that of open cholecystectomy<sup>(11,12)</sup>. It is recognized that misidentification of normal and anomalous anatomical variations contribute to the events of complications particularly ductal and arterial injuries. Such injuries can in turn cause significant morbidity and occasionally even mortality. Concern of the surgical anatomy facts of extra hepatic biliary tract are essential in reducing the complications and morbidity rate<sup>(13)</sup>. Calot's triangle anatomy is a key significance to the surgeon during cholecystectomy in order to avoid iatrogenic operative traumas<sup>(4,5)</sup>.

There are plenty global researches presented considering these variations and anomalies, the authors implemented variable methods including cadaver's dissection, laparoscopic observations and radiological depictions<sup>(14)</sup>. Few researches issued from Middle East.

## Objectives

Start data base for the anatomical variations of Calot's triangle structures in Iraq.

Improve recognition of the surgical anatomy facts about Calot's triangle structures.

Safe laparoscopic cholecystectomy surgery.

## Subjects and methods

Prospectively an observational study was carried out during the period extended from December 2006 to February 2008. The included cases were Iraqi randomly chosen patients presented for Laparoscopic Cholecystectomy surgery. The patients were of Hilla Teaching Hospital of Babylon and Al- Husain Teaching Hospital of Karbala. The anatomical structures of Calot's triangle precisely the cystic artery and cystic duct were subjected for identification. The other extrabiliary structures were identified as possible but not included in this study. The relevant anatomical findings plotted by the operator surgeon on a specially designed illustrated format.

The included categories were the number, origin, length and courses of the cystic artery and cystic duct. The excluded cases were that with severe pathological deformities, cases converted to open cholecystectomy and those with unclear documentation.

## Results

There were 200 valid laparoscopic cholecystectomy reports.

Females patients were 182, (96%). The age range; 18-79 years, mean; 41.2 years, median; 40 ; STDV; 14.17.

*Cystic artery configuration:*

- 1.Total Single cystic artery (179, 89.5%).
- 2.Normal cystic artery; single, arises from right hepatic artery within Calot's triangle (133, 66.5%).
- 3.Total double cystic arteries (21, 10.5%).
- 4.Total anomalous cystic artery (67, 33.5%):

Single replacing cystic artery not originating from right hepatic artery,

crossing anterior to the common hepatic duct (34, 17%)

Single cystic artery originates from right hepatic artery outside Calot's triangle (10, 5%). Fig 4, 5

- i. Single short cystic artery originates from a replacing cater pillar right hepatic artery within Calot's triangle (2, 1%)
- ii. Double cystic arteries one from right hepatic artery within Calot's triangle & the other of undetermined origin (away from the dissection field of cystic pedicle) (11, 5.50%).
- iii. Double cystic arteries both were from the right hepatic artery within Calot's triangle (7, 3.50%).
- iv. Double arteries one from right hepatic artery within Calot's triangle, the other from left hepatic artery outside Calot's

triangle, cross anterior or posterior to the common hepatic duct (3, 1.50%).

5. Absent cystic artery; (0)

*Cystic duct configuration:*

1. Normal junction, course, and length (125, 62.5%)
2. Total cystic duct anomalies (75, 37.5%).
  - i. Short "<5mm" or absent cystic duct (35, 17.5%).
  - ii. Long segment of cystic duct parallel and adherent to the hepatic duct (10, 5%).
  - iii. Long segment of cystic duct parallel not adherent to the hepatic duct (12, 6%).
  - iv. High cysticohepatic junction (14, 7%).
  - v. Low cysticohepatic junction spiral or not spiral around hepatic duct (4, 2%).

There were no combined anomalies in the structures.

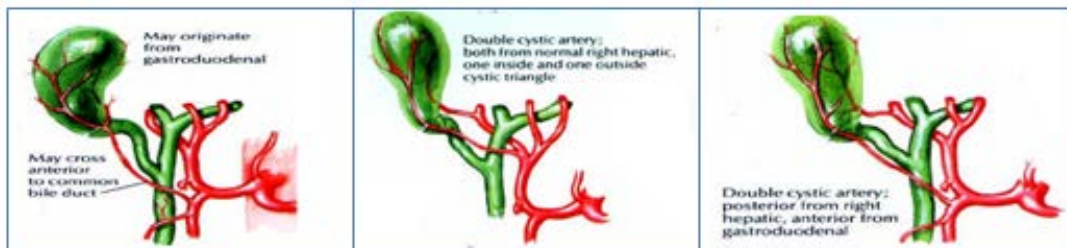


Fig 4. (2)

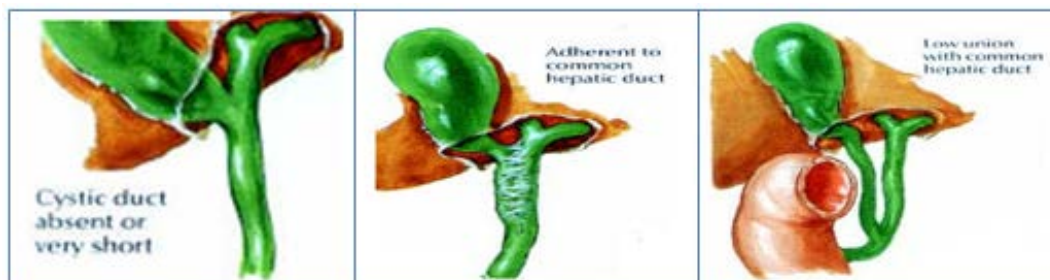


Fig 5. (2)

## Discussion

The classical description of extra hepatic biliary system is seen in less than 50 % of subjects (8). Many researches highlighted the anatomical variation of the structures within Calot's triangle. The published researches documented wide ranges of incidences with the vascular anomalies were more frequent than ductal anomalies. These facts contribute in part to the different methodology of the studies, some authors implemented cadaveric anatomical

dissection other depended the imaging modalities like (MRI, MRCP, Angiography). Laparoscopic surgeons chose the approachable real living subjects who underwent laparoscopic cholecystectomy with its advantage of magnifying technology. In fact the incidences of anomalies in the laparoscopic observational studies are higher and might be more realistic than that of radiological or cadaveric dissection studies, for example in three separate studies, (Table 1,2) the laparoscopic study



showed 62.5% of subjects had normal cystic ducts, in contrast to 67% in cadaveric dissection studies and 80% in

imaging studies. <sup>(18)</sup> The racial differences were also evidently related to the race and the geographical field of the research. <sup>(15)</sup>

Table 1; the current cystic artery variation incidences compared to the published incidences;

Cystic artery configuration	Current	Published
Total Single cystic artery	179, 89.5%	92.2%
Normal single cystic artery arises from right hepatic artery within Calot's triangle	133, 66.5%	62%-85%
Total Double cystic arteries	21, 10.5%	15%-20%
Total anomalous cystic artery:-	67, 33.5%	24.5%
Single cystic artery not from right hepatic artery crossing anterior to the common hepatic duct;	34, 17%	2.6%-15% <sup>(16,17)</sup>
Single cystic artery originate from right hepatic artery out side Calot's triangle, cross anterior to hepatic duct	10, 5%	4,5%-13.1%
Single short cystic artery originated from replacing cater pillar right hepatic artery within Calot's triangle	2, 1%	2.1%-2.6%
Double cystic arteries one from right hepatic artery within Calot's triangle & the other of undetermined origin (away from the dissection field of cystic pedicle)	11, 5.5%	1%-4% <sup>(17)</sup>
Double cystic arteries both were from the right hepatic artery within Calot's triangle	7, 3.5%	2%-14%
Double arteries one from right hepatic artery within Calot's triangle the other from left hepatic artery out side Calot's triangle	3, 1.5%	1%-2%

Table 2; the current cystic duct variation incidences compared to the published incidences;

Cystic duct configuration	Current	Published
Normal, junction, course and length	125, 62.5%	67%-80%
Total cystic duct anomalies	75, 37.5%	23%-43%
Short "<5mm" or absent cystic duct	35, 17.5%	2.6%-10%
Long segment of cystic duct parallel and adherent to the common bile duct	10, 5%	1.0%-20%
Long segment of cystic duct only parallel to common bile duct	12, 6%	10%-13%
High cysticohepatic junction	14, 7%	0.3-2.0%
Low cysticohepatic junction	4, 2%	0.5-10% <sup>(18)</sup>

Clinically many of these anomalies are significant and may be locally multiple or poly systemic with a known predisposition to relevant diseases <sup>(10)</sup>.

The anomalies of the biliary system can occur in relation to number, position or shape. Sound knowledge of the normal and anomalous anatomy is essential to avoid diagnostic/interventional misinterpretations or open

Surgical/laparoscopic complications. <sup>(10)</sup>.

The current prospective study implemented the laparoscopic observational method. The specific tracts studied here were the cystic artery and cystic duct within Calot's

triangle, there were no over needed harmful dissection in the vicinity.

Regarding cystic artery configuration, in this study, as shown in table 1, there are higher than published incidences in three comparable items (yellow color); single artery crossing anterior to common bile duct, double arteries from both right and left hepatic arteries with a second artery arises outside Calot's triangle. Surgeon should be aware in order to avoid hemorrhage or induction of bile duct stricture during clipping cystic artery close to the common bile duct while it crosses anterior to bile duct. Two categories (white

color) are within the published ranges and three (green) are below the ranges of relevant incidences. Hepatic artery is vulnerable for ligation in case of replacing caterpillar right hepatic artery.

The comparative cystic duct variations in table 2, shows a higher incidences of "short or absent ducts" and "high branching cystic- hepatic junction" than the published ranges. Less than 5mm long or absent cystic duct may render bile duct candidate for inadvertent clipping. Long, parallel cystic duct course with or without fibrous common sheath anomalies may be problematic at cholecystectomy. Mistaking cystic duct for bile duct in such a case may jeopardize hepatic duct. In addition, long cystic duct remnant (up to 6 cm in length) may be left after cholecystectomy<sup>(10)</sup>.

The other four categories (green) are within the ranges of the world wide incidences but are not away from the scope of possible injuries.

## Conclusion

The anatomy of Calot's triangle is puzzling, associated with variable anomalies. Surgeon should be alert and well prepared to deal with such events.

National data base for the anatomic variations is necessary as it is evident from the wide differences in the variations incidences between the various published foreign studies and also with our current study.

Application of high-tech imaging tools like preoperative MRCP, ERCP, CT as well as the operative cholangiography improve diagnosis and facilitate anatomical identification these in turn certainly lead to a successful and a safe surgery.

## References

1- Way LW, Stewart L, Gantert W, et al. (April 2003). "Causes and prevention of laparoscopic bile duct injuries: analysis of 252 cases from a human factors and cognitive psychology perspective". *Ann. Surg.* 237 (4): 460-9. doi:10.1097/01.SLA.0000060680.92690.E9.

PMID 12677139. PMC 1514483. <http://www.ncbi.nlm.nih.gov/pmc/articles/PMC1514483/?tool=pubmed>. Retrieved 2011-01-08.)

2- Lawrence M. Witmer, PhD Clinical Anatomy of the Biliary Apparatus: Relations & Variations Department of Biomedical Sciences College of Osteopathic Medicine Ohio University Athens, Ohio 45701 witmer@exchange.oucom.ohiou.edu 25 March 2003 (also photo reference)

3- M. Suzuki, S. Akaishi, T. Rikiyama, T. Naitoh, M. M. Rahman and S. Matsuno R. 15849341( *jurnalul de chirurgie (journal of surgery)* Issn: 15849341 Year: 2005 Volume:1 Issue:1)

4- Lamah M, Karanjia ND, Dickson GH. Anatomical variations of the Extrahepatic Biliary Tree; Review of the World Literature. *Clin Anat* 2001; 14: 167 - 72.

5- Alfred Cuschieri ;Laparoscopic cholecystectomy; Department of Surgery, Ninewells Hospital and Medical School, University of Dundee, Dundee, Scotland, U.K.J.R.Coll .Surg.Edinb., 44, June 1999, 187-92))

6- Haubrich WS (2002). " The triangle of Calot". *Gastroenterology* 123 (5): 1440. PMID 1240421.

7- Balija M, Huis M, Nikolic V, Stulhofer M. Laparoscopic visualization of the cystic artery anatomy. *World J Surg.* 1999 Jul;23(7):703-7. PMID 10390590 Wikipedia,my documents

8- Henry Gray; the biliary system; Gray's anatomy 40<sup>th</sup> Ed, 2008

9- M. Fawzi Gaballah & Zaizafon H. Badawy Professors of Anatomy, ABDOMEN PROPER Faculty of Medicine, Kasr Al Ainy, Cairo University

10- Mary Ann Turner, MD and Ann S. Fulcher, MD<sup>1</sup>From the Department of Radiology, The Cystic Duct: Normal Anatomy and Disease Processes I Medical College of Virginia, 401 N 12th St, Box 980615-MCV Station, Richmond, VA 23298. Presented as an educational exhibit at the 1999 RSNA scientific assembly. Received March 10, 2000; revision requested April 11 and received June 15; accepted June 29. Address correspondence to M.A.T. (e-mail: maturner@hsc.vcu.edu).

11- Ahrendt SA, Pitt HA: Surgical therapy of iatrogenic lesions of biliary tract. *World J Surg* 2001, 25:1360-1365

12- Targarona EM, Marco C, Balagué C, Rodriguez J, Cugat E, Hoyuela C, Veloso E, Trias M: How, when, and why bile duct occurs. A comparison between open and laparoscopic cholecystectomy. *Surg Endosc* 1998, 12:322-326. )Cal5 Gross Anatomical Variations and

- Congenital Anomalies of Surgical Importance in Hepatobiliary Surgery in Uganda)
- 13- Yun-Hua Wu, Zhi-Su Liu, Reikia Mrikhi, Zhong-Li Ai, Quan Sun, Gassimou Bangoura, Qun Qian, Cong-Qing Jiang Anatomical variations of the cystic duct: Two case reports; World J Gastroenterol 2008 January 7; 14(1): 155-157 www.wjgnet.com World Journal of Gastroenterology ISSN 1007-9327 wjg@wjgnet.com © 2008 WJG.
  - 14- Ibingira, C.B.R. : Senior Lecturer and Head of Department of Anatomy Faculty of Medicine Makerere University Gross Anatomical Variations and Congenital Anomalies of Surgical Importance in Hepatobiliary Surgeri Uganda P.O. Box 7072 KAMPALA. Email: cibingira@yahoo.com. East and Central African Journal of Surgery Association of Surgeons of East Africa and College of Surgeons of East Central and Southern Africa ISSN:1024-297X Vol. 12, Num. 1, 2007, pp. 93-98 East and Central African Journal of Surgery Vol. 12, No. 1, April, 2006, pp. 93
  - 15- Robin Kaushik, M.S. Department of Surgery Government Medical College and Hospital Chandigarh India A.K. Attri, M.S. Department of Surgery Government Medical College and Hospital Chandigarh India Hepaticocystic Duct: A Case Report; hepaticocystic duct, a case report; <http://www.ispub.com/ostia/index.php?xmlFilePath=journals/ijcs/front.xml>.
  - 16- . Donna D'Souza Replaced right hepatic artery on December 15, 2008, © 2005–2010 Radiopaedia.org.
  - 17- Hassan Saidi, Tharao M. Karanja, Julius A. Ogengo; variant anatomy of the cystic duct in adult Kenyan; Journal of clinical anatomy, 18 Oct 2007.
  - 18- Khamiso Altaf Hussain Talpur, Abdul Aziz Laghari, Sikandar Azam Yousfani, Arshad Mahmood Malik, Aamir Iqbal Memon, Sangrasi Ahmed Khan ( Liaquat University of Medical & Health Sciences, Jamshoro, Sindh. ) Anatomical variations and congenital anomalies of Extra Hepatic Biliary System encountered during Laparoscopic Cholecystectomy JPMA journal of Pakistan Medical Association; 2011.