

## THE EFFECT OF *COCONUT* OIL EXTRACT ON FULL THICKNESS WOUND HEALING ON THE FEMALE RABBITS

Batool S.H.

Department of Pathology and poultry diseases, College of Veterinary Medicine, University of Basrah, Basrah, Iraq

(Received 6 September 2012 , Accepted 14 October 2012)

**Keywords;** rabbits, wound, coconut

### ABSTRACT

Our experiment used ( 12 ) female rabbits divided into three groups every group have ( 4 ) rabbits were studied for their wound healing properties in the form of ointment, using one type wound models (full thickness incisional wounds) .The ointments of oil extraction of coconut were applied in concentration 5mg used in the present study.

The pathological examination into 3<sup>rd</sup> days of treated wound shows, there are a little hemorrhagic area ,inflammatory cells are more in number, ,plasma cells are high in numbers and very little neutrophils ,cloudy swelling in skin cells ,and hemorrhages into dermis compared with a control wound that show first stage of healing presence of hemorrhagic area and congestion ,slight inflammatory cells infiltration neutrophils, collagen fibers , and skin cells .

While after 7<sup>th</sup> days the treated wound shows absence of hemorrhagic area , presence of inflammatory cells especially macrophage cells ,plasma cells . Absence of neutrophils, granulation tissue and growth of layer, new blood vessels and bundles of collagens and re-epithelization compared with a control wound that showed a clot into hemorrhagic area , granulation tissue and growth of skin layers , bundles of collagens, vacuolated skin cells, epithelial cells, plasma cells, macrophage cells, and neutrophils debris .

After 14<sup>th</sup> days the treated wounds show debris of granulation tissue, excessive collagen bundles, with epithelial cells remodeling and macrophages found in the area while control wound showed little hemorrhagic area ,the stratum cranium formation , absorption of granulation tissue ,and vacuolated skin cells . There is a little macrophage into the margin of the wound. Aimed of my study to study the effect of coconut oil extract on the healing of skin wounds .The work of this research into Pathology and poultry diseases department - Veterinary Medicine college .

### INTRODUCTION

Normal wound healing is a staged process that comprises inflammation , cell proliferation and tissue remodeling .The inflammatory phase has an essential role in cleaning the wound of bacteria and debris ,in initiating the later stages of wound healing [ 1 ] .

Cutaneous wound healing is a complex and well-defined process which is initiated in response to injury [2] .The healing process occurs in five phases: inflammation, neovascularization, formation of granulation tissue, re-epithelization and , finally, formation of new extracellular matrix and tissue remodeling [3–6] . After healing the new tissues and

cells invade the wound space approximately 4 days after injury [5] . The structural molecules of the newly formed extracellular matrix contribute to the formation of granulation tissue by providing the mass of blood filling the gap in the tissue is, it will be noted that the surface of wound is covered with tiny red granules or buds ,resembling the nap of red velvet and giving that surface a granular appearance and cell migration [7, 8] . Collagen is the major protein of the intracellular matrix and the predominant constituent of the final scar [9] . Therefore, the synthesis, secretion and subsequent organization of this triple-helical protein in the wound's granulation tissue become significant in the healing process since enhanced cross-linking of collagen results in higher wound tissue strength [10] .

The coconut ( *Cocos nucifera* ) is belongs to the family of the Arcaceae ( palmae ) , the subfamily Cocoideae . Virgin coconut oil ( VCO )VCO-treated wounds healed much faster, as indicated by a decreased time of complete epithelization and higher levels of various skin components. Pepsin-soluble collagen showed a significant increase in VCO-treated wounds, indicating a higher collagen cross-linking. Glycohydrolase activities were also found to be increased due to a higher turnover of collagen. Antioxidant enzyme activities, and reduced glutathione and malondialdehyde levels were found to be increased on the 10th day after wounding, which were found to have returned to normal levels on day 14 in the treated wounds. The lipid peroxide levels were found to be lower in the treated wounds [ 11 ]. VCO contain fatty acid that are " middle chain " fatty acids . The lauric acid control infection by destroying all micro-organisms .these must stimulate the the production of collagen and thereby speeds wound healing with less scarring [ 12 ] .

## **MATERIALS AND METHODS**

### **-Preparation of coconut oil extraction :**

I take the coconut then cut it to extract the kernel part of coconut then grounded mechanically by using a blender for ( 4 min. ),and then dried at room temperature for 2 days under the shade. 25g of the dried crushed material were put in the thimble of soxhlets apparatus , ( 250 ml ) of chloroform (BDH Eglad) were added and extracted at 50°C for 24 hrs. . The final dryness was completed by leaving at room temperature . The results were yellowish oily material was kept in a tightly closed dark container [ 13 ] .

### **-Preparation of Animals:**

The 12 female rabbits were divided into three groups with four animals per each group [ 14, 15 ] .

- A- 3<sup>rd</sup>-day post wounding
- B- 7<sup>th</sup> -day post wounding
- C- 14<sup>th</sup> -day post wounding.

The animals were prepared which include clapping and shaving the dorsal aspect of each animal and then the area cleaned with 70% ethanol. This was followed by

anesthetized the animal by I/M injection of 10mg/kg body weight ketamine hydrochloride and 5mg/kg body weight xylazine, then at the dorsal aspect, a full thickness incisional wound including all layers of skin, after determination the area of each wound with a marker an known length 5 cm. The wounds are divided into treated wound on the left side, while control was on the right side. After determination the targeted area from the dorsal aspect of each animal, 5 cm length of full thickness incision wound including all layers of skin, wound when treated with 0.5gm oil ointment which prepared by admix the coconut oil extract with Vaseline base with ratio 1:3 respectively [ 16 ]. The control wound treated with disinfectant only by using iodine only without using ointment . The four animals anesthetized as above to collect the specimens after 3<sup>rd</sup> ,7<sup>th</sup> ,and 14<sup>th</sup> days by cutting a round the wound with full thickness then cut it into formalin 10% . The samples obtained these tissues fixed with formalin then dehydrated by graded alcohol, this is followed by dealcoholization with xylol and embedding with paraffin wax and blocking. Histological sections of 5-6  $\mu$  thickness were obtained by a microtom. Dewaxed , dehydrated, and staining by hematoxylin and eosin stain, from all chickens of all organs [17].

## **RESULT**

### **1. Microscopic Apperance**

In our study the pathological examination into 3<sup>rd</sup> days of treated wound fig [ 1 ] shows, there are a little hemorrhagic area ,inflammatory cells are more in number, bundles of collagens ,plasma cells are high in numbers and very little neutrophils , and cloudy swelling in skin cells , compared with control wound fig [ 2 ] that show first stage of healing ( prescence of hemorrhagic area and congestion ) ,slight inflammatory cells infiltration ( neutrophils ), hemorrhages into the dermis , collagen fibers , and skin cells ( plasma cells ) .

While after 7<sup>th</sup> days the treated wound fig [ 3 ] show absence of hemorrhagic area only hemorrhagic debris , presence of inflammatory cells especially macrophage cells ,plasma cells . Absence of neutrophils, bundles of collagens and re –epithelization compared with control group fig [ 4 ] that showed a clot into hemorrhagic area , granulation tissue and growth of skin layers , new blood vessels, bundles of collagens , vacuolated skin cells, epithelial cells, plasma cells, macrophage cells, and neutrophils debris .

After 14<sup>th</sup> days the treated wounds fig [ 5 ]show debris of granulation tissue, excessive collagen bundles, with epithelial cells remodeling and macrophages found in the area while control wound fig [ 6 ] showed a little hemorrhagic area ,the stratum cranium formation , absorption of granulation tissue ,and vacuolated skin cells . There is a little macrophage into the margin of the wound.

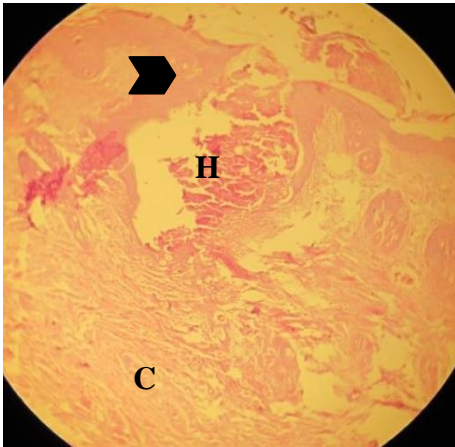


Fig .1 : treated wound after 3<sup>rd</sup> days post wounding shows little hemorrhagic area ( H ), bundles of collagen, and cloudy swelling in skin cells ( head arrow ). 100 X , H& S stain . .

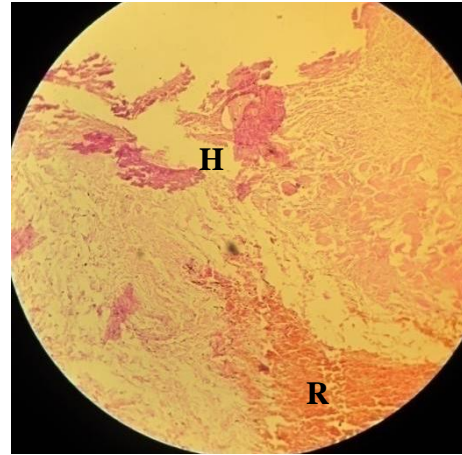


Fig . 2 : control wound after 3rd days post wounding shows hemorrhagic area ( H ), hemorrhages in the dermis ( R ), and collagen fibers. 100 X , H& S stain .

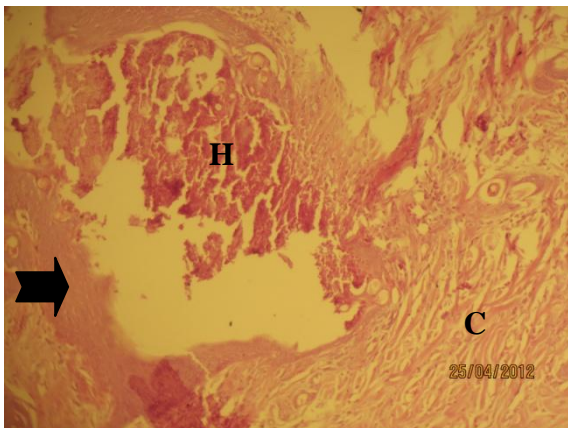


Fig . 3 : treated wound after 7<sup>th</sup> days post wounding shows hemorrhagic debris ( H ), bundles of collagens ( C ), re- epithelization ( arrow ), inflammatory cells infiltration , and new blood vessels . 400 X , H& S stain .

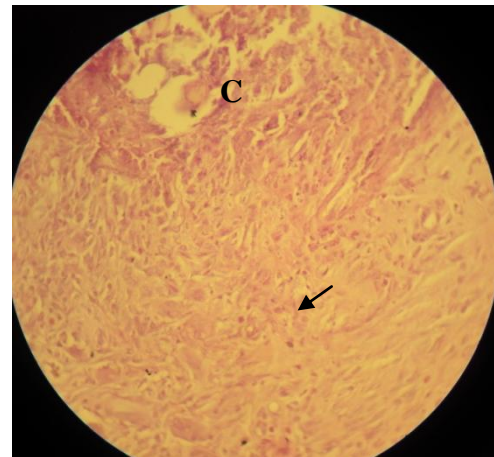
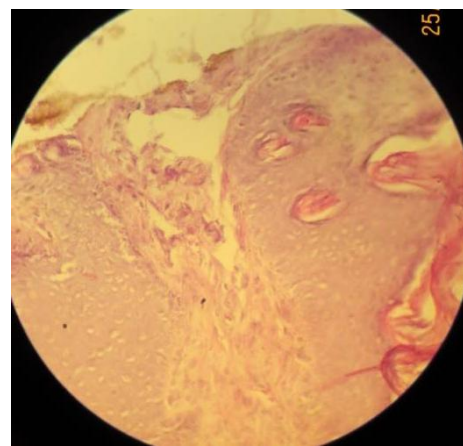


Fig .4 : control wound after 3rd days post wounding shows blood clot ( C ), bundles of collagen ( arrow ), inflammatory cells infiltration. 400 X , H& S stain .



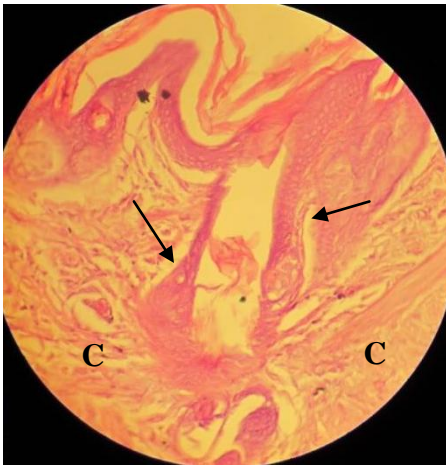


Fig .5 : treated wound after 14<sup>th</sup> days post wounding shows epithelial cells remodeling (arrow) ,and collagen bundles (C) . 400 X , H & S stains.

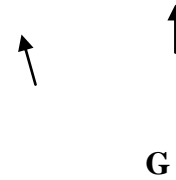


Fig. 6: control wound after 14<sup>th</sup> days post wounding shows granulation tissues ( G ), and vacuolated skin cells ( arrow ). 400 X , H & S stains.

## 2. Macroscopic Appearance

[ Fig.7 ] show the wound on the day 0 .The treated wound show more contraction and appeared smaller ( left wound ) than control wound ( right wound) into [ Fig. 8]. The control wound on the right show scar formation ,while on the left the treated wound more healed and shallow wound after 7<sup>th</sup> days post wounded as in [ fig.9] . The control wound on the right show scar formation ,while on the left the treated wound more healed and no scar formation after 14<sup>th</sup> days post wounded as in [ fig. 0].

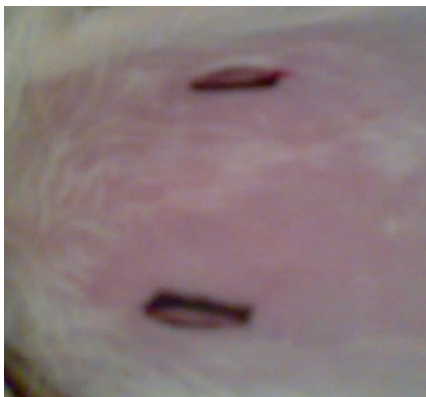

Fig 7 : show the right wound as a control and the left one as a treated wound on day 0 .

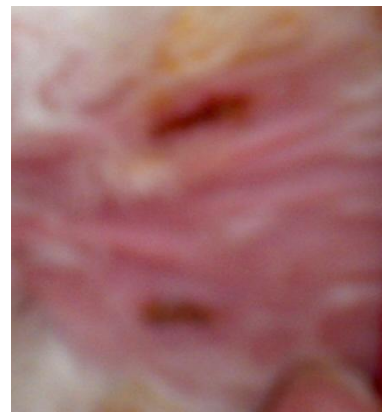

Fig 8 : show the treated wound was more smaller and healed into the left than control one on the right on the 3<sup>rd</sup> days .



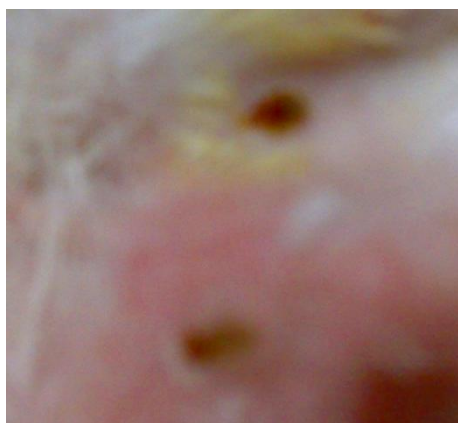


Fig 9: show the control wound on the right show scar formation ,while on the left the treated wound more healed and shallow wound after 7<sup>th</sup> days post wounded .

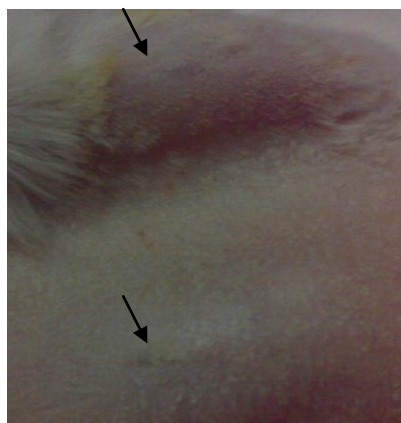

Fig 10 : show the control wound on the right show scar formation ,while on the left the treated wound more healed and no scar formation after 14<sup>th</sup> days post wounded .

## DISCUSSION

Research is now verifying what tropical populations have long known: Coconut oil applied to your skin can help your skin become radiant and healthy. Coconut Oil Central claims that coconut oil, which is rich in medium-chain triglycerides, is a small enough molecule to pass into your skin and nourish it from the inside. Also, the composition of your own sebum, which is the skin oil your body produces to protect your skin from the elements, is also rich in medium-chain triglycerides, meaning this is your own body's preferred protective layer [ 18 ].

On our study the healing more fast after uses of coconut oil ointment and more collagen bundles compared with control because of VCO-treated wounds healed much faster, as indicated by a decreased time of complete epithelization and higher levels of various skin components. Pepsin-soluble collagen showed a significant increase in VCO- treated wounds, indicating a higher collagen cross-linking. Glycohydrolase activities were also found to be increased due to a higher turnover of collagen [ 19, 12 ] . Coconut oil owes much of its wound-healing greatness to a unique and phenomenal type of fat molecules called medium chain fatty acids (MCFA)/.Cellular activity is regulated by the metabolism. A high metabolic rate \*accelerates\* cellular activity which includes healing damaged tissues. MCFAs give a quick source of energy to your cells, \*boosting\* their metabolic level and enhancing your body's capacity to heal itself [20] .

## تأثير مستخلص جوز الهند الزيتي على التئام الجروح كاملة الطبقات في اناث الارانب

بتول سالم حمزة

فرع الأمراض وأمراض الدواجن، كلية الطب البيطري، جامعة البصرة، البصرة، العراق

### الخلاصة

تم استخدام ( 12 ) أرنب من إناث الأرانب قسمت هذه الحيوانات الى ثلاث مجاميع كل مجموعته تحتوي ( 4 ) ارناب لدراسة خواص التئام الجروح عند استخدام مرهم المستخلص. استخدم نوع واحد من الجروح ( الجروح كاملة الطبقات ) في ( 12 ) من اناث الارانب عند وضع مرهم مستخلص جوز الهند الزيتي بتركيز 5 ملغم في هذه الدراسة .

كشف الفحص المرضي النسيجي خلال اليوم الثالث من اجراء الجروح في الجروح المعالجة ، القليل من منطقة النزف ووجود خلايا التهابية العديد منها ، حزم الكولاجين ، مع وجود خلايا البلازما باعداد كثيرة والقليل من خلايا العدلة مع وجود تورم غيمي في خلايا الجلد ، ووجود نزف في منطقة الادمة ، مقارنة مع جروح السيطرة التي اظهرت وجود المرحلة الاولى للالتئام ( وجود منطقة النزف والاحتقان ) ، ارتشاح الخلايا الالتهابية باعداد قليلة ( العدلة ) ، وجود الياف الكولاجين ، وخلايا الجلد ( البلازما ) .

بينما بعد مرور 7 ايام اظهرت الجروح المعالجة اختفاء منطقة النزف ، وجود الخلايا الالتهابية خاصة الخلايا الكبيرة وخلايا البلازما ، واختفاء الخلايا العدلة ، مع وجود حزم الكولاجين بكثرة مقارنة مع جروح السيطرة التي اظهرت وجود جلطة دم في منطقة النزف ، والنسيج الحبيبي وكذلك نمو طبقات الجلد ، وجود اوعية دموية جديدة ، حزم من الكولاجين ، تحوصل خلايا الجلد ، وجود خلايا طلائية ، وخلايا البلازما ، والخلايا الكبيرة ، وخلايا العدلة .

بعد مرور 14 يوم من الجروح اظهرت الجروح المعالجة بقايا نسيج حبيبي والكثير من حزم الكولاجين مع اعادة بناء للخلايا الطلائية كاملة او طبقة الخلايا الطلائية ، ووجود الخلايا الكبيرة في المنطقة اما جروح السيطرة فقد كانت هناك القليل من منطقة النزف وتكون الطبقة المتقرنة مع امتصاص للنسيج الحبيبي وتحوصل الخلايا الجلدية مع وجود القليل من الخلايا الكبيرة في حواف الجرح . الهدف من البحث لدراسة تأثير مستخلص جوز الهند الزيتي على التئام الجروح وتم العمل في فرع الامراض زامراض الدواجن / كلية الطب البيطري .

### REFERENCES

1. G., Boyd ; M. ,Butcher ; and A. ,Kingsley.( 2004 ). Prevention of non-healing wounds through the prediction of chronicity. J. Wound Care .13 ( 7 ) :265 – 6 .
- 2 Fray, M.J.; Dickinson, R.P.; Huggins, J.P.; and Occleston ,N.L .( 2003 ) . A potent, selective inhibitor of matrix metalloproteinase-3 for the topical treatment of chronic dermal ulcers. J Med Chem . 46: 3514–3525.
3. Mast, B.A.: The skin; in Cohen, I.K.; Diegelmann , R.F.; and Lindblad ,W.J. (eds). ( 1992 ) : Wound Healing. Biochemical and Clinical Aspects. Philadelphi

WB Saunders, pp 344–355

4. Percival, M. (1997 ) : Nutritional support for connective tissue repair and wound healing. Clin Nutr Insights; 6: 1–4.
5. Evans, P. (1980 ) Fundamentals of wound healing. Physiotherapy; 20: 256–259.
6. Clark, RAF (1996 ) Wound repair overview and general consideration; in Clark , RAF (ed): The Molecular and Cellular Biology of Wound Repair. New York, Plenum, , pp 3–50.
7. Greiling, D.; and Clark ,R.A. (1997 ) Fibronectin provides a conduit for fibroblast transmigration from collagenous stroma into fibrin clot provisional matrix. J Cell Sci; 110: 861.
8. Toole, B.P. (1991 ) : Proteoglycan and hyaluron in morphogenesis and differentiation; in Hay ED (ed): Cell Biology of Extracellular Matrix. New York, Plenum, pp 305–341.
9. Chithra P, Sajithlal GB, Chandrakasan G (1998 ) The influence of *Aloe vera* on collagen characteristic in healing dermal wounds in rats. Mol Cell Biochem; 181: 71–76.
10. Cotran ,R.S.; Kumar ,V.; and Robbins, S.L. (eds) (1989 ). Robbins Pathologic Basis of Disease. Philadelphia, WB Saunders, , pp 76–86.
11. S., Karger ; and AG, Base. (2010 ). Effect of Topical Application of Virgin Coconut Oil on Skin Components and Antioxidant Status during Dermal Wound Healing in Young Rats. Skin Pharmacol Physiol . 23 : 290-297
- 12 . Sanford, Pinna .( 2011 ) VIRGIN COCONUT OIL AND WOUND HEALING. Skin Pharmacol Physiol. . Department of Biochemistry, University of Kerala, Thiruvananthapuram, India.
13. Maissam , Hassan Ali . ( 2007 ). The effect of alcoholic extract of coconut *cocos nucifera* fruits on some reproductive aspects of male Albino mice . Thesis
- 14 . Al-Ruba'ee, M.A. (2005). Study on the effect of *Loranthus europeus* L. seed on pyogenic inflammation and skin wound healing in rabbits. M.Sc. Thesis, College of Veterinary Medicine, University of Basrah, Iraq.
- 15 . Methaq, A.A.; Marium, A.K.; and Zaniab, W.K. (2007). Study the effect of *Aloe vera* oil extract on excisional wound healing in females rabbits. Journal of Basrah of Veterinary Research. 6(1).



- 16 . Tina, Boyle. ( 2010 ). Uses of Coconut Oil on Skin. Amy Neuzil, N.D.41: 242.
17. Baker, F.J.; and Silverton, R.E. (1976). Medical laboratory technology. 5<sup>th</sup> Edition, Butter Worthy.
18. Nevin , KG ; and Rajamohan, T.( 2010 ). Effect of topical application of virgin coconut oil on skin components and antioxidant status during dermal Can J . Physiol . Pharmacol. . 87(8): 610-6 .
- 19 . [www.cosmeticdoctalk.com](http://www.cosmeticdoctalk.com)
20. Gethin, G.T.; Cowman, S.; and Conroy, R.M. (2008) !e impact of manuka honey dressings on the surface of chronic wounds. Int Wound J 5:185-94