

## Comparative morphometric study of shank bone in the tom (*Meleagris gallopavo*) and local cock (*Gallus banikaval*)

S. Al-Sadi

Department of Anatomy, College Veterinary Medicine, University of Mosul, Mosul, Iraq

(Received May 29, 2011; Accepted April 1, 2012)

### Abstract

The study was carried out on 20 legs of ten adult clinically and healthy local and Tom were obtained from Mosul local market, were divided into three groups; the first and second groups were subjected to gross feature regarding to shape, position, relationship of tibiotarsal and fibula in both birds also the length and diameters of shank bone while third group study morphological of muscles, blood and nerve supply of leg. The purpose of this study, this part of the limb is popularly known as the (drum stick), the bird in lowering its body flexes knee and hock joints and this passively tenses these tendons of leg which clamp the digits about the perch, and that is the much longer than the femur and, in spite of importance study to parameters of leg are more economic to choose breed of fertilization depend on the measurement, the outcome of this investigation may served as a guide for successful study of domestic birds in Iraq. The results include in both birds, the leg is consist of tibia fuses with tarsal element, forming tibiotarsus and fibula articulates with the femur that in contrast to mammals. In Tom the tibia has two cnemial crest in proximal extremity and the distal extremity has tendinal groove, but in local cock it has one cnemial crest of proximal extremity, and it has two tendinal groove in the distal extremity, while hock joint in the Tom and local cock is an intertarsal joint that unites the tibiotarsus with the tarsometatarsus but the stiff joint is similar to that seen in mammals. The mean length of tibiotarsal in Tom  $17.99 \pm 0.44$  cm and the mean length of tibiotarsal in local coke  $11.74 \pm 0.31$  cm, the mean diameter of tibiotarsal in Tom  $3.02 \pm 0.0021$  cm proximal part,  $2.21 \pm 0.005$  cm middle part,  $1.94 \pm 0.0021$  cm distal part, but the mean diameter of tibiotarsal in local coke  $2.86 \pm 0.048$  cm proximal part,  $2.02 \pm 0.067$  cm middle part,  $1.51 \pm 0.0022$  cm distal part. While the mean length of fibula in Tom  $11.62 \pm 0.21$  cm and the mean length of fibula in local coke  $7.27 \pm 0.32$  cm, the mean diameter of fibula in Tom  $1.51 \pm 0.0021$  cm proximal part,  $0.81 \pm 0.0033$  cm middle part, and  $0.33 \pm 0.0043$  cm the distal part, also the mean diameter of fibula in local coke  $1.12 \pm 0.0025$  cm proximal part,  $0.51 \pm 0.007$  cm middle part, and  $0.23 \pm 0.0054$  cm distal part. Tendon of muscles of shank bone in Tom generally ossification but remain that tendon in local cock. Also cranialis tibialis muscle has two head, femoral head is usually smaller than the tibial head and gastrocnemius muscles is composed of three part into two birds which passes through the planter aspect of the tarsometatarsal joint, as soon as flexor digitorum muscle of both species can be grouped into three morphological level (superficial intermediate and deep), the muscles in turkey are very clearly distinguished are read deep color than it is rose color in local cock, blood, nerve supply and venous drainages of the shank bone in both birds by cranial tibial artery is passage with cranial tibial vein and common fibular nerve.

**Keywords:** shank bone. Tom; *Meleagris gallopavo*; local cock; *Gallus banikaval*.

Available online at <http://www.vetmedmosul.org/ijvs>

### دراسة تشريحية قياسية مقارنة للساق في الديك الرومي والديك المحلي

سمية الساعدي

فرع التشريح، كلية الطب البيطري، جامعة الموصل، الموصل، العراق

الخلاصة

اجري البحث على ٢٠ ساق جمعت من عشرة ديوك عراقي ورومي اخذت من السوق المحلية لمدينة الموصل وقسمت عينات البحث

الى ثلاثة مجاميع: درست المجموعة الاولى والثانية شكل وموقع وارتباطات عظم القصبية والشظية في كلا الطيرين و درست قياسات عظم الساق (القصبية والشظية) للديك الرومي والعراقي والمجموعة الثالثة درست شكل وموقع وارتباط عضلات الساق مع بعضها وكذلك المدد الدموي والعصبي والتصرف الوريدي للعضلات. والهدف من الدراسة حيث يعد الساق عمود الادارة الرئيسي الرابط بين الفخذ والكاحل ويسمى عظم الساق (عصا النقر على الطبل) ومن العظام المهمة التي تكون الهيكل الطرفي في الدواجن وان اصل اهمية الدراسة القياسية لعظم الساق له علاقة مباشرة بالانتاج حيث تنتخب الاجناس الجيدة في التلقيح على اساس هذه القياسات وان عظم الساق اطول عظم في القائمة الحوضية لكلا الطيرين. وتعد دراسته دليل للدراسات اللاحقة حول الطيور المحلية في العراق. وبينت نتائج البحث ماييلي: ان عظم الساق للديك الرومي اطول واعرض واكثر استقامة مما هو عليه في الديك المحلي ويتكون عظم الساق من القصبية التي تندمج مع الرسغ لتكون العظم اللارسغي القصبي وعظم الشظية الذي يتم فصل مع الفخذ في كلا الطيرين وهذا غير موجود في اللبائن ولعظم الساق عند الديك الرومي حيدتين قصبتين في الطرف الداني وميزاب وترتي في الطرف القاصي بينما عند الديك المحلي له حيد قصبي وميزابين وترتين وان كلا الطيرين لهما مفصل ركبة يتكون من الاتحاد القصبي الرسغي والرسغي المشطي ولكن مفصل الفخذ في الطيرين مشابه لما هو عليه في اللبائن. وان معدل طول القصبية في الديك الرومي يصل  $17.99 \pm 0.44$  سم وفي الديك المحلي يصل  $11.74 \pm 0.31$  سم ومعدل قطرها في الديك الرومي عند الجزء الداني  $3.02 \pm 0.0021$  سم وعند الجزء الاوسط  $2.21 \pm 0.005$  سم وعند الجزء القاصي يصل  $1.94 \pm 0.0021$  سم اما معدل قطرها في الديك المحلي عند الجزء الداني يصل  $2.86 \pm 0.048$  سم وعند الجزء الاوسط يصل  $2.02 \pm 0.067$  سم وعند الجزء القاصي يصل  $1.51 \pm 0.0022$  سم بينما معدل طول الشظية في الديك الرومي يصل  $11.62 \pm 0.21$  سم وعند الديك المحلي يصل  $7.27 \pm 0.32$  سم اما معدل قطرها في الديك الرومي عند الجزء الداني يصل  $1.51 \pm 0.0021$  سم وعند الجزء الاوسط يصل  $0.81 \pm 0.0033$  سم وعند الجزء القاصي يصل  $0.33 \pm 0.0043$  سم بينما معدل قطرها في الديك المحلي عند الجزء الداني يصل  $1.12 \pm 0.0025$  سم وعند الجزء الاوسط يصل  $0.51 \pm 0.007$  سم وعند الجزء القاصي يصل  $0.23 \pm 0.0054$  سم. وتتعضم اوتار اندغام العضلات في الديك الرومي وتبقى على حالها في الديك المحلي وللعضلة القصبية الامامية راسيين الفخذي عادة اصغر من القصبي وتتكون عضلة بطن الساق من ثلاثة اجزاء وتسير على المفصل الرسغي المشطي وهو مختلف عما موجود في اللبائن وتنقسم العضلات القابضة للاصبع في كلا الطيرين الى ثلاث مستويات تشريحية (سطحية ووسطى وعميقة). وتكون عضلات الديك الرومي مميزة جدا بلونها الاحمر الغامق وتكون وردية اللون في الديك المحلي والتجهز الشرياني والعصبي والتصرف الوريدي للساق عند كلا الطيرين من خلال الشريان القصبي الامامي والعصب الشظوي العام ويسيران مع الوريد القصبي الامامي.

## Introduction

Chicken is primary source of protein, and turkey is special poultry species that deserves it is own approach, and hatching to growing and processing (1,2), the out come of this investigation many served as a quid for successful study of the previous (3,4) but avian leg has received very little attention when compared with other species studies on shank, also Tom and local cock legs provide base support for food in addition birds are different to most of mammals in a number of immediately obvious ways, most of the possible causes of poultry problems causes leg defect (2,5) the leg plays an important role in determination the degree of the movement of the limbs in birds, certain avian tendons are known to mineralize normally in a gender related manner and large amounts of myoglobin and more mitochondria as well as greater vascularity, the red fibers and white (6,7).

The aim of this investigation is to study in detail the different part of the local cock leg and Tom leg.

## Materials and methods

Five healthy adult Tom (meleagris gallopavo) as well as five healthy adult local cock (gallus banikaval) were obtained from Mosul local market, the age of these birds an

average from (2-3) year old with ranging body weight of (2-3) kg were used in order to expose the pelvic limb, feathers of the leg were verified, the specimens were refrigerated, then by dissection the muscles were separated very carefully from each other and cleaned than the specimens were studied anatomically various measurements of shank bone of different part of bone were attempted length of tibiotarsal bone was taken from the distance between the cranial point of the proximal extremities to the caudal point to the distal extremities as well as to the length fibula, the diameter of tibiotarsal bone and fibula it was measured from three level of bones (cranial, middle and caudal) the distance between the transverse line pass on the medial margins to the lateral margins of the bone, the techniques the same as that used by (8) are using digital verner caliper the readings were represented in centimeter these measurements included (Table 1-6) twenty measurement were taken to give full description of the shape of the shank bone.

## Results

The legs variation of shape and sizes in both birds tibiotarsus and fibula in Tom are longer, wider and more striated than in local cock (Fig. 1-3) and (table 1-6). The tibiotarsus characterized by shaft and two extremities, the

lateral part of the upper shaft exhibits a ridge for attachment of the fibula, in Tom the proximal extremity has two cnemial crest, cranial usually larger than caudal crest while in local cock it has one large cranial cnemial crest (Fig. 1, 2) also tibiotarsus is characterized proximally by the cranial auricular area and caudal auricular area. In Tom the distal extremity of the tibiotarsus presents one tendinal groove but two tendinal groove in local cock (Fig. 1, 2) and that bone has prominent condyle for articulation with tarsometatarsus depression for the attachment of the collateral ligament of the tibiotarsus - tarsometatarsus joint, there are present of either side of the distal extremity while some of the proximal tarsal bones fused with the distal end of the tibia.

Table 1: show the length and diameter of tibiotarsal in Tom.

Tom No.	Lengths	Parameters (cm)			
		Diameter			
		Proximal	Middle	Distal	
1	Right tibiotarsal	17.6	3.1	2.3	2.1
	Left tibiotarsal	17.7	3.1	2.2	2.1
2	Right tibiotarsal	17.6	2.9	2.1	1.9
	Left tibiotarsal	17.6	2.8	2.1	1.9
3	Right tibiotarsal	18.2	3.2	2.3	1.9
	Left tibiotarsal	18.1	3.1	2.3	1.8
4	Right tibiotarsal	18.2	3.1	2.1	1.9
	Left tibiotarsal	18.2	3.1	2.2	1.8
5	Right tibiotarsal	18.3	2.9	2.3	2.0
	Left tibiotarsal	18.4	2.9	2.3	2.0

Table 2: show the length and diameter of tibiotarsal in local cock.

Local cock No.	Lengths	Parameters (cm)			
		Diameter			
		Proximal	Middle	Distal	
1	Right tibiotarsal	11.8	2.9	2.0	1.6
	Left tibiotarsal	11.8	2.8	2.1	1.5
2	Right tibiotarsal	11.6	2.8	2.0	1.5
	Left tibiotarsal	11.7	2.8	2.1	1.5
3	Right tibiotarsal	11.6	2.9	1.9	1.4
	Left tibiotarsal	11.6	2.9	2.0	1.5
4	Right tibiotarsal	11.8	2.8	2.0	1.5
	Left tibiotarsal	11.8	2.9	2.0	1.5
5	Right tibiotarsal	11.9	2.9	2.0	1.5
	Left tibiotarsal	11.8	2.9	2.1	1.6

The fibula is reduced long bone in Tom and local cock. It has two extremities and shaft, the proximal extremity is enlarged part of the fibula, that extremity articulates with the lateral facet of tibiotarsus. But in two birds the distal extremity is fused with tibiotarsus, and the shaft has two

surface cranial and caudal, in addition two border medial and lateral (Fig. 3).

Muscles of the curs (shank) divide into the craniolateral and caudomedial.

**Fibularis longus**

The origins mainly fleshy, but often having small aponeurotic connection with end of the tibiotarsus proximally insertion to the tibial cartilage, schematics (1,2).

Table 3: show the length and diameter of fibula in Tom.

Tom No.	Lengths	Parameters (cm)			
		Diameter			
		Proximal	Middle	Distal	
1	Right fibula	11.7	1.5	0.8	0.4
	Left fibula	11.6	1.5	0.8	0.3
2	Right fibula	11.5	1.4	0.9	0.4
	Left fibula	11.6	1.5	0.8	0.3
3	Right fibula	11.5	1.6	0.8	0.3
	Left fibula	11.6	1.5	0.7	0.3
4	Right fibula	11.7	1.6	0.8	0.4
	Left fibula	11.7	1.5	0.9	0.3
5	Right fibula	11.7	1.5	0.8	0.3
	Left fibula	11.6	1.5	0.8	0.3

Table 4: show the length and diameter of fibula in local cock.

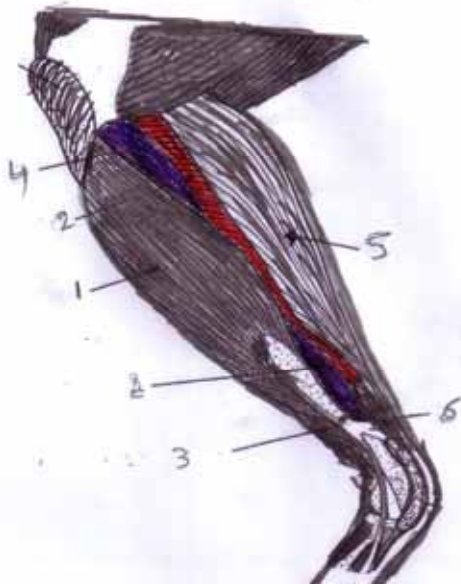
Local cock No.	Lengths	Parameters (cm)			
		Diameter			
		Proximal	Middle	Distal	
1	Right fibula	7.3	1.1	0.5	0.1
	Left fibula	7.2	1.2	0.4	0.2
2	Right fibula	7.1	1.0	0.5	0.1
	Left fibula	7.2	1.1	0.6	0.2
3	Right fibula	7.3	1.2	0.5	0.1
	Left fibula	7.3	1.2	0.5	0.2
4	Right fibula	7.4	1.1	0.6	0.1
	Left fibula	7.3	1.0	0.5	0.1
5	Right fibula	7.3	1.2	0.5	0.2
	Left fibula	7.3	1.2	0.5	0.1

Table 5: show the mean ± ES of length and diameter of tibiotarsal in Tom and local cock.

tibiotarsal in	Lengths	Parameters (cm)		
		Diameter		
		Proximal	Middle	Distal
Tom	17.99±	3.02±	2.21±	1.94±
	0.44	0.021	0.005	0.0021
Local cock	11.74±	2.86±	2.02±	1.51±
	0.31	0.045	0.0067	0.0022

Table 6: show the mean  $\pm$  ES of length and diameter of Fibula in Tom and local cock.

Fibula in	Parameters (cm)			
	Lengths	Diameter		
		Proximal	Middle	Distal
Tom	11.62 $\pm$ 0.21	1.51 $\pm$ 0.008	0.81 $\pm$ 0.0033	0.33 $\pm$ 0.0043
Local cock	7.27 $\pm$ 0.32	1.12 $\pm$ 0.0052	0.51 $\pm$ 0.007	0.23 $\pm$ 0.0054



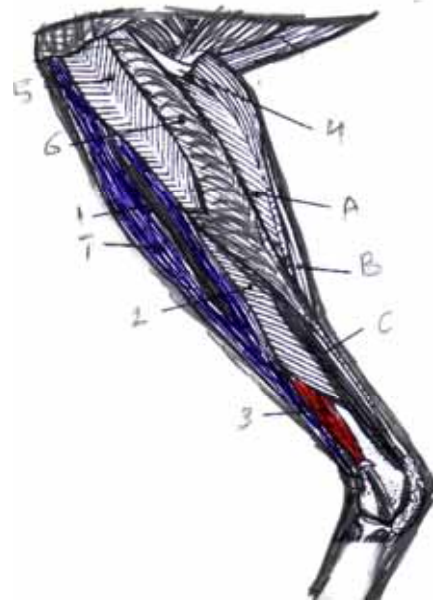
Schematic 1: Showing superficial muscles of the left leg in Tom 1-fibularis longus 2-tibialis cranialis 3-fibularis brevis 4-external digitorum longus 5-gastrocnemius 6-flexor digitorum longus.

**Fibularis brevis**

Usually smaller and shorter muscle in local cock while larger muscle in turkey, origin mainly aponeurotic from the lateral surface of the tibia distal to the fibular crest insertion proximal to the lateral condyle of the tibiotarsus. (Fig. 4), schematics (1,2).

**Tibialis cranialis**

It is located on the cranial surface of the tibia and deep to the fibularis longus it is readily separated into two heads femoral and tibial (Fig. 4,5) femoral head, is usually some smaller than the tibial head, origin femoral head by a tendon from the condyle of femur, tibial head fleshy to partially aponeurotic from the cnemial crests, the two muscular bellies fuse distally to form a single strong tendon in the tendinal groove of the tibiotarsus.



Schematic 2: Showing second and third layers muscles of the left leg in local cock 1 – tibial and femoral head, 2-fibularis longus 3-fibularis brevis 4- plantaris A,B,C- pars externa, media and interna 5- extensor digitorum longus 6-flexor digitorum longus.

**Extensor digitorum longus**

Is located deep to the cranialis tibialis origin usually from the shaft of tibia and deep to the origin of the tibial head of the tibialis cranialis, insertion by the tendon passes beneath the common retinaculum which retains the tendon of the tibialis cranialis (Fig. 5,6).

**Gastrocnemius muscle**

Is the largest and strongest of the crural muscles and it consist of three heads (external, internal and middle) usually the external and internal heads are larger than middle head (Fig. 7,8) origin, the external head (pars externa) by aponeurotic connections with the lateral femoral arm of the popliteal, the middle head (pars media) mostly fleshy from the medial aspect of the popliteal area, the internal head (pars interna) mainly fleshy from the cnemial crest and head of tibia insertion by common tendon contain sheath like aponeurotic, in turkey it form more or less separate tendon and becomes ossified as along bony ridge forming of a fibro- osseous compartment sheath for the flexor tendon of the toes (Fig. 6)

**Plantaris**

The muscle is generally small in both birds origin, from the proximal extremity of tibiotarsus, insertion through fascia along the deep surface of the internal head of gastrocnemius.

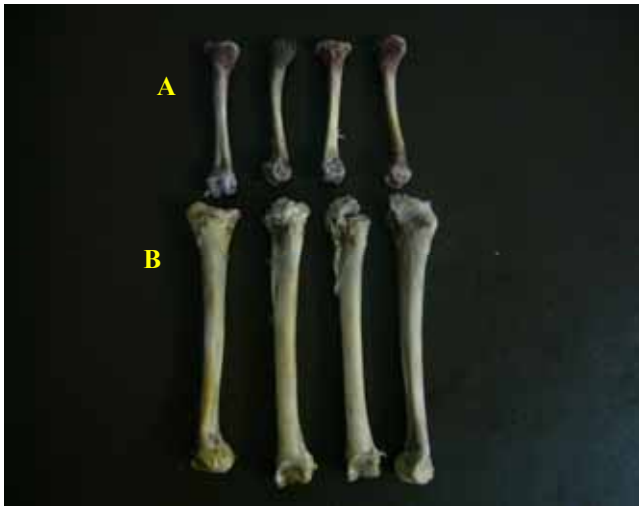

Fig. 1: The tibiotarsal bone of A- local cock and B- In Tom showing cranial and caudal view.

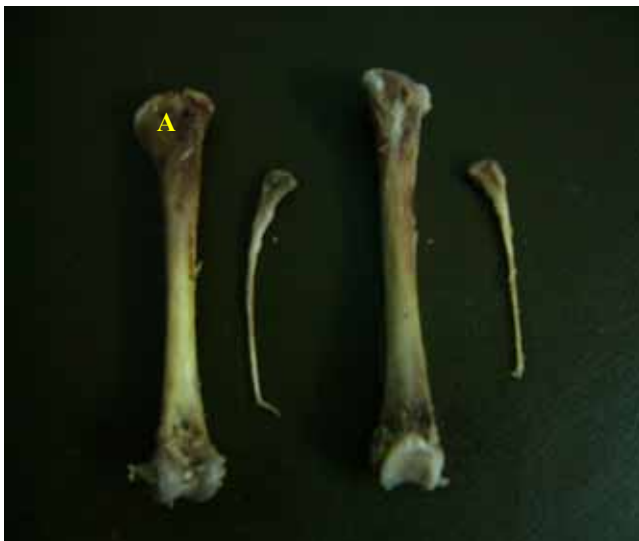

Fig. 2: The tibiotarsal and fibula of Tom showing cranial and caudal view of tibia and fibula (A) cranial cnemial crest in proximal extremity.

**Caudomedial muscle of the shank bone**

**The digital flexor muscle.** It can be grouped into three morphological units based on their respective levels of insertion, superficial digit flexors (flexor perforates digit 11,111 and 1v) intermediate digit flexor (flexor perforates digit 11,111) and deep flexors (flexor digitorum longus) in Tom and local cock (Fig. 7,8).

**Superficial digital flexor muscle** (flexor perforates digit 11,111 and 1v), each of three muscles typically has a lateral and medial head (Fig. 7,8) arise from the caudal surface of the tibiatarus and proximal extremity of fibula,

intermediate digital flexor (flexor perforates digit 11,111) origin of one or two aponeurotic from the caudal cnemial crest in Tom and local cock, deep digital flexor (flexor digitorum longus) originated by two or three bellies in both Tom and local cock from the caudal surface of tibia tarsus and Most of the digital flexor muscles arise by extensive aponeurotic interconnections with each other (Fig. 8,9) and all the insertion tendon of digital flexor muscle from the tibial cartilage bundle of three tendons is exposed the broad and more deeply situated tendon of the of the flexor perforates 111 forms a sheath around the flexor perforates 1v on the lateral side and flexor perforates 111 on the medial side.

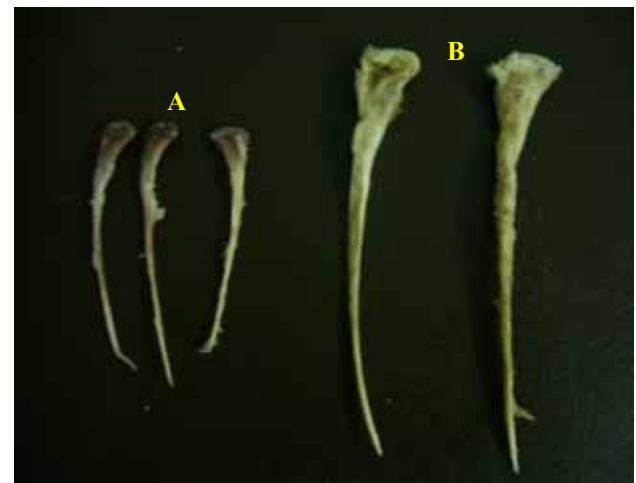

Fig. 3: A- fibula in local cock and B- In Tom showing the cranial and caudal view.

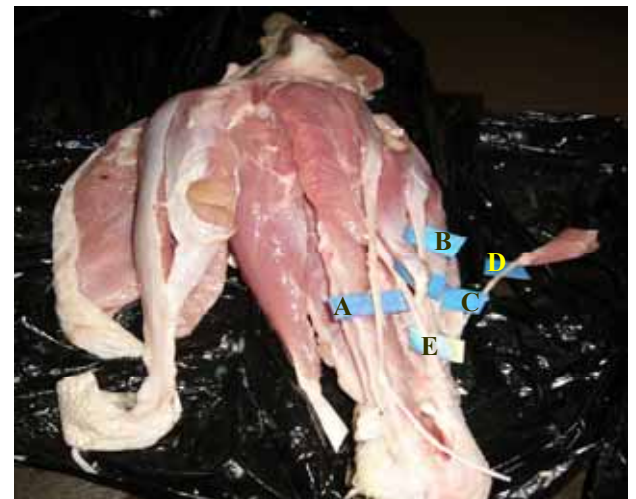

Fig. 4: lateral view of left leg showing superficial muscle of Tom A- Fibularis longus. B- Fibularis brevis. C-Cranialis tibialis. D-Femoral head. E-Tibial head.

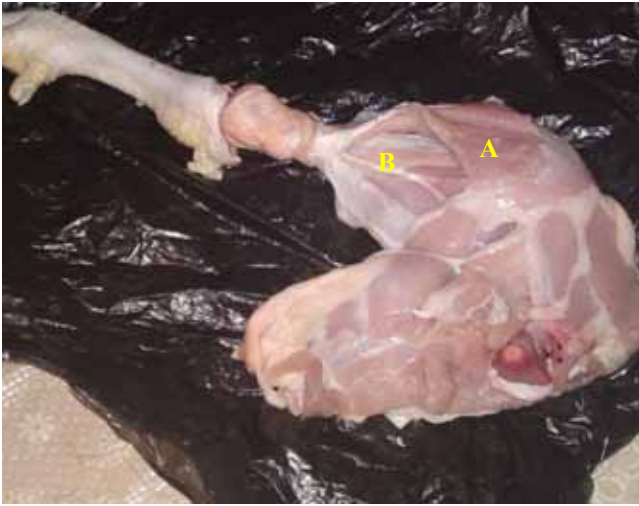

Fig. 5: left leg of local cock showing A- The first and B- Second layer of muscles.

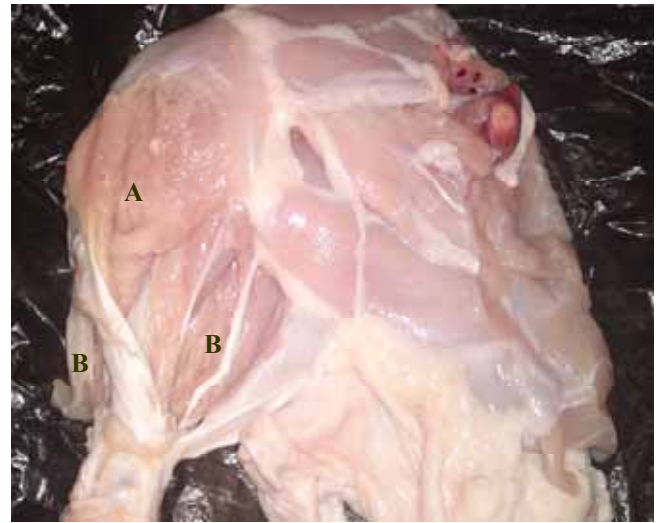


Fig. 7: The right leg of local cock showing third layer of muscles: A- three parts of gastrocnemius muscle and B- three parts of digit flexor muscle.

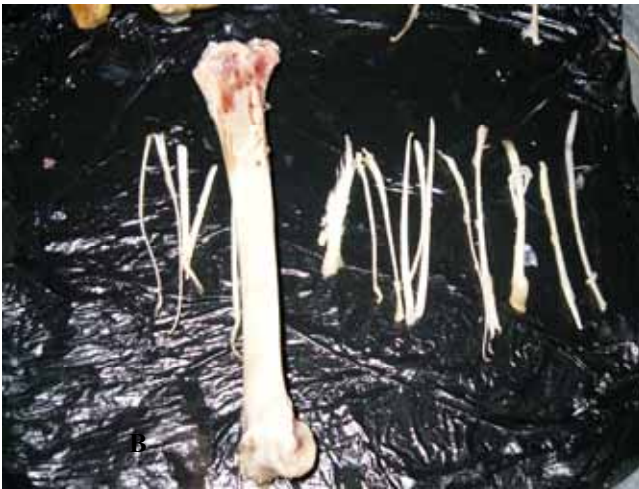

Fig. 6: shows the insertion ossify tendon of gastrocnemius and external digitorum longus muscle in shank bone of Tom after boiling of muscle.

**Popliteus.** Deep small muscle origin from caudal surface of tibia and inserts in the cranial surface of fibula (Fig. 9).

**Blood supply to the shank bone in Tom and local cock.**

At the distal region of femur the ischiatic artery becomes the popliteal artery releases the medial tibial artery enters medial head of the gastrocnemius then curves distally in the muscle to the mid-leg level, accompanies the popliteal vein and the medial tibial nerve reaching the interosseous plane between the proximal tibia and fibula (Fig. 9,10) the popliteal artery turns courses distally in the limb and divided into cranial and caudal tibia arteries, also is distributed to the deeper level of the flexor compartment of the leg and distally part the tarsometatarsal joint.

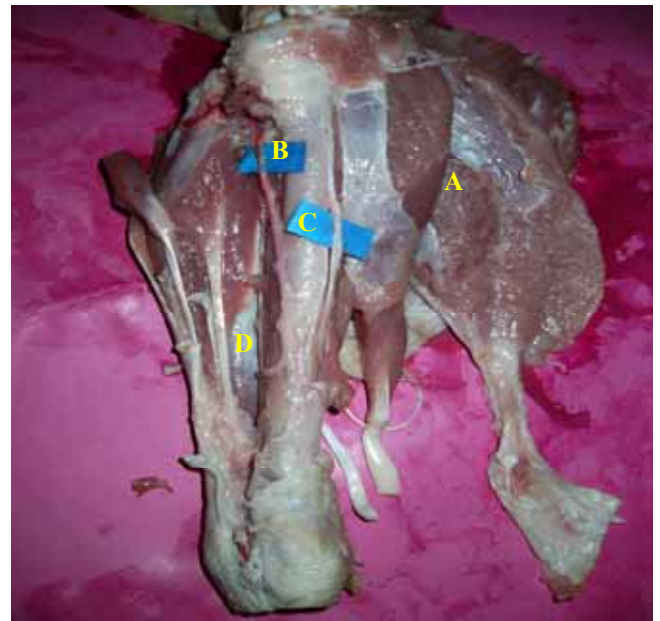

Fig. 8: the left leg of Tom showing third layer of muscles: A- three parts of gastrocnemius muscle, B- Cranial tibial artery C - Common fibular nerve and D- three parts of digit flexor muscle.

**Innervations of the shank in Tom and local cock.**

Nerves supply of shank are tibial nerve is larger division of the ischiatic nerve, it supply most of the flexor muscles of shank is divided into medial tibial and lateral tibial nerves, medial tibia] nerve continues with the popliteal artery in

proximal region of extensor and flexor muscle of the shank bone they are supplied by fibular nerves is divided into three nerves, superficial nerve gives muscular rami to the fibularis longus and fibularis brevis and metatarsal cutaneous rami, deep fibular nerve passes under the tibialis cranialis gives muscular ramus to the flexor digitorum and is divided into digital nerve, common fibular nerve, crosses lateral to the shaft of fibula, related to the fibular vessels gives.

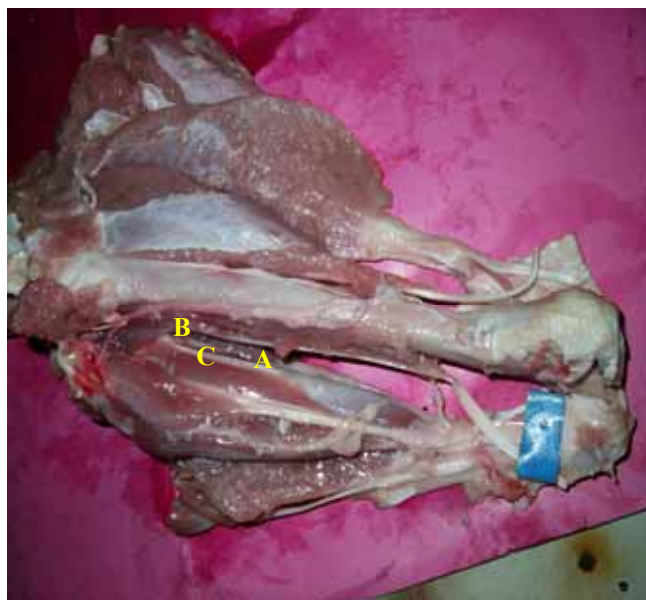

Fig. 9: the right leg of Tom showing fourth layer of muscles: A- plantaris muscle, B- three parts of digit flexor muscle and C- popliteus.

### Discussion

The legs variation of shape and sizes in both birds tibiotarsus and fibula in Tom are longer, wider and more striated than in local cock were not reported by any of the above mentioned authors in any of the birds due to bipeds and man, has a specific longer and wider bones for the leg these characteristic measurements are attributed to compression of the body weight and the demands of the erect posture (9).

Shank bone consists of tibiotarsal and fibula, our results for both species were in agreement with (6) while some of the proximal tarsal bones are fused with the distal end of tibia to increase in length and the whole skeletal.

The fibula is reduced long bone in Tom and local cock. It has two extremities and shaft, (6) report that the fibula in Tom and local cock showed the typical avian condition of having greatly reduced fibula, is greater size and extends, the present study demonstrated that there were hock joint in

Tom and local cock that unites the tibiotarsal with the tarsometatarsus which also included the fused metatarsals second, third and fourth many workers' obtain this result because differential growth in birds (7).

Tendon of limb muscles in Tom is ossification because these tendons have unique properties as well as several features common to calcifying cartilage and bone in large birds (10). In Tom the dark and red muscles are very clearly distinguished because contain larger amount of myoglobin, and more heavily vascularized (10).

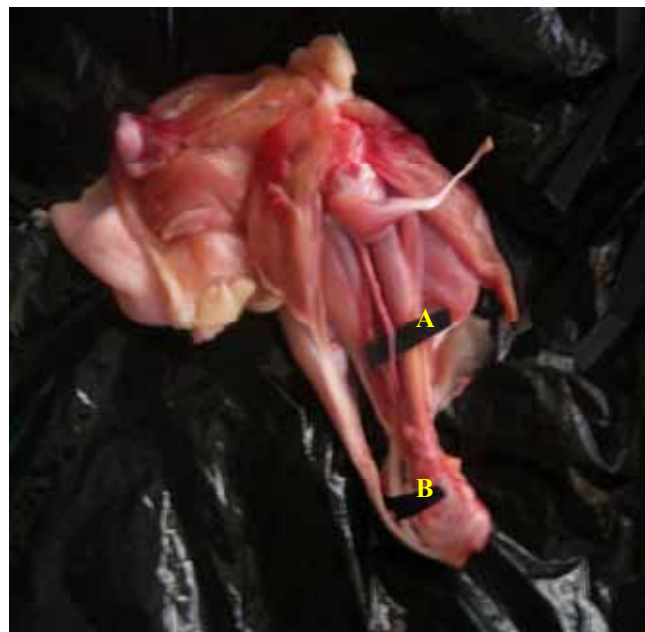


Fig. 10: the left leg of local cock showing: A- Cranial tibial artery B- Common fibular nerve. Muscular branches to the both heads of the tibialis cranialis and extensor digitorum longus.

In our results show the gastrocnemius muscle was largest and has three heads in Tom and in local cock because gastrocnemius are sufficiently well developed in the gallinaceous birds to be however the relative development of each of them may show some variation in birds generally often more or less correlated with the relative length of the leg is strongest and largest of crural muscles (11,12).

The present results were the tibialis cranialis muscles consist of two heads and location directly under the fibularis longus in Tom and local but in mammals this muscle small and it has one head, our results agree with (6) fibularis longus muscles showed considerable variation in its relative development in birds. It may extend over most of the crus concealing the tibialis cranialis, as in the turkey, or it may be somewhat reduced in size and not concealing that muscle as (in local breed, there is very little variation in this

muscle among birds except for the length of the fleshy belly, the present study showed that flexor digital muscle has three level superficial, intermediat and deep, the result agreement with (6) most birds have three heads of origin, or fourth head.

According to the fibularis brevis in our result that muscles smaller and shorter is relatively larger and long muscle in some birds e. g vultures, falcons and parrots, the muscles is absent or reduced in some species of bird, lucluding stroks and falmingoes (6).

## References

1. Gineke M. Certified production of commercial turkey. *World poultry Magazine on production processing and marketing*. 2010;40(26):4.
2. French N. Managing turkey poultry quality in the hatchery. *World poultry Magazine on production processing and marketing Turkey special 10*. 2008;11(24):7.
3. Johnson P. Effect of the unilateral weight bearing on pelvic limb development in broiler vascular studies. *Res Vet Sci*. 1988;44(2):164.
4. Getty R. *The anatomy of the domestic animals*. volume 1. W.B. Saunders comp.,UK. London. 1975. p.35-37.
5. Dyce KM, Sack WO, Wensing CJG. *Textbook of veterinary anatomy*. 3ed. Ed. Sunders. Philadelphia. London. 2002. p.779 -780
6. Vander B J. *Avian mycology*.in Sisson and Grossman.*The anatomy of domestic animals* Rev by Getty. R.W.B. Saunders comp. Philadelphia USA. 1975. p.1837- 1839.
7. Oliver U. Vascular mineral spatial correlation in the calcifying turkey leg tendon. *Connect Tissue Res*. 2002;43(4):595-605.
8. Saleh MN, Mohamed MA, Galal AT. Parametric studies on the hip bone of some mammals. *Assiut Vet Med J*. 1986;17(34):67.
9. Arsenault Al. Crystal collagen relation ships in calcified turkey leg tendon s visualized by selected area dark field electron microscopy. *JAVA*. 2003;3(50):161.
10. Vukovic S. Development of glycogen body in Turkey (*Meleagvis gallopavo*) embryo. *Vet Skiarhv*. 2005;75(2):101.
11. Dickson JG. *The wild Turkey biology and arrangement*. published by stack pole books in mechanic Sbury.. 2003. p.412 -413.
12. Riddell A. *Histology and physiology of the chicken*. Contact Morse. Elu Sub Mitho Web. 2005;(1):5.