

## CASE REPORT

**Emphysematous Pyelonephritis****Hayder Mahdi AL-Ardi****BACKGROUND:**

Emphysematous pyelonephritis is a life threatening necrotizing infection of the kidney characterized by accumulation of gas in the renal parenchyma as well as within the surrounding tissues<sup>(1,2)</sup>. The common presentations are fever (56%), vomiting (16%), abdominal pain (7%), shock (16%) and confusion (24%)<sup>(1)</sup>. The pathogenesis is poorly understood, the condition usually occurs in diabetic patients. Although glucose fermentation may be a factor, the explanation does not account for the rarity of emphysematous pyelonephritis despite the high frequency of gram-negative UTI in diabetic patients, nor does it explain the rare occurrence of the condition in nondiabetic patients. In addition to diabetes, many patients have urinary tract obstruction associated with urinary calculi or papillary necrosis and significant renal functional impairment.<sup>(3)</sup>

**CASE REPORT:**

A 43 year old women presented to emergency room with complaints of pain right side upper abdomen and fever and chills for previous 5 days .The pain limited to the right side of the abdomen with no radiation .Associated symptoms include nausea ,vomiting and abdominal distension .There no lower urinary tract symptoms.Past medical history include tablet uncontrolled diabetes mellitus with no insulin therapy.on examination patient was febrile ,pulse rate of 120 per minute ,blood pressure of 110/70 mm of mercury and respiratory rate of 29 per minute .chest and heart examination were normal .there were no meningeal signs or focal neurological deficit.

Investigations revealed haemoglobin of 8.9g/dL, total leucocyte count of  $15.5 \times 10^3/\text{mL}$  with neutrophil predominant. Blood urea was 95 mg/dl and creatinine of 206 mg/dl.serum glucose was elevated (394 mg/dl).Potassium was 5.5 mmol/dL,serum Na 129 mmol/l .Urinalysis showed pus cells packed field and glycosuria and

was positive for ketones. Urine and blood culture was negative .Abdominal X-ray done in the hospital showed distorted outline of the right kidney with air in the perirenal region and intraparenchymal air (Figure 1) as well as dilated small bowel. These findings are consistent with emphysematous pyelonephritis and probable paralytic ileus due to peritonitis. Unenhanced CT-scan of the abdomen confirmed the abdominal X-ray findings of emphysematous pyelonephritis (Figure 2).abdominal Ultrasonogram demonstrated a strong focal echoes suggesting intraparenchymal gas.

The patient was hydrated and I.V antibiotic(meropenem+metronidazole) was administered .other measures include initiation of insulin injections.she was transfused with packed cells,fresh frozen plasma.she was monitored closely in the intensive care unit and urgent right nephrectomy was done for uncontrolled severe sepsis (Figure 3).Following the operation the patient was admitted to the intensive care unit for intensive monitoring and blood glucose control.Her renal function tests improved to BUN 34 mg/dl and creatinine 1.5 mg/dl .She was discharged in good health 2 weeks later.

**DISCUSSION:**

Emphysematous pyelonephritis should be suspected in every diabetic patient presenting with acute pyelonephritis .Ultrasonography should be done as screening investigation and if there is hyperechoic focus within the kidney ,a non contrast CT scan is recommended. CT is the imaging procedure of choice in defining the extent of the emphysematous process and guiding management<sup>(4)</sup>. Excretory urography is rarely of value in emphysematous pyelonephritis because the affected kidney usually is nonfunctioning or poorly functioning. Because of the significant risk of contrast nephropathy in critically ill, dehydrated diabetic patients with abnormal renal function, retrograde pyelography rather than excretory urography is advisable to demonstrate obstruction. Obstruction is demonstrated in approximately 25% of the cases<sup>(3)</sup>.

Emphysematous pyelonephritis occurs in 90% of

Department of Urology, Medical College , Kufa University, Najaf, Iraq .

## EMPHYSEMATOUS PYELONEPHRITIS

cases in diabetic patients and E.coli is the most common organism <sup>(5)</sup>. Other bacteria include Klebsilla pneumoniae, Proteus mirabilis, Pseudomonas aeruginosa, Aerobacter aerogens and Citrobacter. Rarely yeast such as Candida albican or Cryptococcus neoformans may be implicated <sup>(6)</sup>.

Emphysematous pyelonephritis is a surgical emergency. Most patients are septic, and fluid resuscitation and broad-spectrum antimicrobial therapy are essential. If the kidney is functioning, medical therapy can be considered <sup>(7,8)</sup>. Nephrectomy is recommended for patients who do not improve after a few days of therapy. If the affected kidney is nonfunctioning and not obstructed, nephrectomy should be performed

because medical treatment alone is usually lethal. If a kidney is obstructed, catheter drainage must be instituted <sup>(3)</sup>.

Nephrectomy was the gold standard of treatment previously but percutaneous drainage has gained popularity in the recent years with a few successful case reports and clinical review <sup>(9)</sup>. Chen *et al* reported 20 of 25 (80%) patients successfully treated with antibiotic and percutaneous drainage <sup>(9)</sup>.

Emphysematous pyelonephritis is a condition which carries major morbidity and significant mortality. Rapid and thorough assessment, prompt diagnosis and appropriate aggressive treatment is likely to reduce mortality in these life-threatening case.

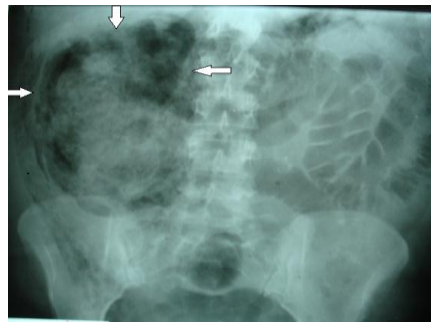


Figure 1: Abdominal X-ray right kidney with air in the perirenal region and intraparenchymal air.

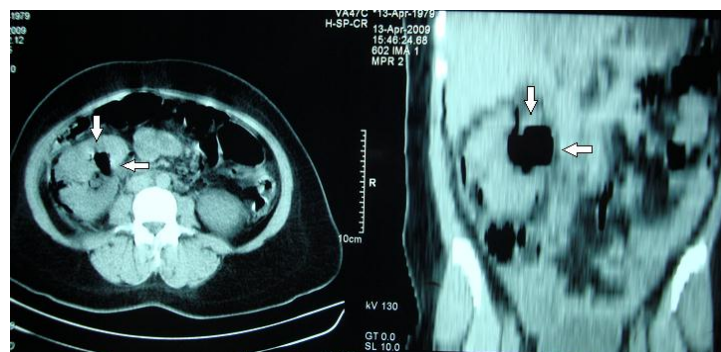

Figure 2: CT scan showing a moderate hydronephrosis, with gas in a dilated pelvicalyceal system.

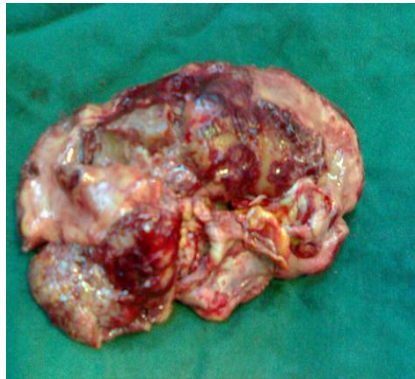

Figure 3: The kidney grossly necrotic seen after nephrectomy.

### CONCLUSION:

Emphysematous pyelonephritis should be excluded in a diabetes patient presented as pyelonephritis. Antibiotic and percutaneous drainage or nephrectomy is management of choice.

### REFERENCES:

1. Michaeli J, Mogle P, Perlberg S, Heiman S, Caine M. Emphysematous pyelonephritis. *J Urology* 1984;131:203-8.
2. Pontin AR, Barnes RD, Joffe J and Kahn D: Emphysematous pyelonephritis in diabetic patients. *Br J Urol* 1995;75:71.
3. Walsh, c; Retik, B; Vaughan, E and Wein, J..*Campbell's Urology*(9th edition), infection and inflammation. USA . 2009;8:s271-73.
4. Baumgarten and Baumgartner, 1997. Baumgarten DA, Baumgartner BR: Imaging and radiologic management of upper urinary tract infections. *Urol Clin North Am* 1997;24:545-69.
5. Pagnoux C, Cazaala J.B., Mejean A., Haas C., Brochen J., Biotard C. Timsit J., Emphysematous pyelonephritis in diabetics, *Rev Med Interne.*, 1997;18:888-92.
6. M. Mallet, D.C. Knockaert, R.H. Oyen & H.P. Van Poppel, Emphysematous pyelonephritis: no longer a surgical disease? *European Journal of Emergency Medicine*, 2002;9:266-69.
7. Wan et al., 1996. Wan YL, Lee TY, Bullard MJ, et al: Acute gas-producing bacterial renal infection: Correlation between imaging findings and clinical outcome. *Radiology* 1996 ;198:433-38.
8. Best et al., 1999. Best CD, Terris MK, Tacker JR, et al: Clinical and radiological findings in patients with gas forming renal abscess treated conservatively. *J Urol* 1999;162:1273-76.
9. Ovid & Chen, Emphysematous pyelonephritis, *J Vasc Interv Radiol*, 1997;8: 909.