

Evaluation of Functional Outcome after Open Reduction and Internal Fixation of Capitellar Fracture with K. Wires

Adnan Husain Hnoosh

ABSTRACT :

BACKGROUND :

Isolated capitellar fractures are uncommon. Authors continue to differ about the preferred method of treatments and its results on the post operative outcome.

OBJECTIVE:

Of This study: Is to evaluate the clinical and functional out come of operatively treated capitellar fracture with K.Wire , and furthermore to define the impact of fracture type on the out come.

PATIENTS AND METHOD:

A retrospective study carried out on 15 patients Sustained closed capitellar fracture , 11 females , 4 males. The main age (16 – 58 years). the Operative treatment performed at a mean of 10 days, by open reduction through relatively limited lateral approach and internal fixation with k. wires. The evaluation of the functional outcome was by clinical and radiographic examination . The range of motion (ROM) by using of Mayo Elbow Performance Index (MEPI), and The American Shoulder and Elbow Surgeons (ASES) scales , and self assessment questionnaires form.

RESULTS:

Eight patients type I , one type II , four type III , two type IV ,and three patients had ipsilateral radial head fracture,. two in association with type III , and one with type IV. All fractures healed , with no significant clinical instability or weakness. The mean ulno-humeral motion (UHM) was (95°-132°) . All patients had full forearm rotation, average flexion contracture was 15° (range (8°-35°). (P=0.05). The mean (MEPI) was (90±10) points, with seven excellent results and six good , and the mean (ASES) was 36±3 (30 to 40 points) in seven patients. Ipsilateral radial head fracture had no significant effect on the functional outcome.

CONCLUSION:

Good to excellent outcome with functional ulnohumeral motion (UHM) can be achieved following open reduction and minimal fixation with k. wires in the treatment of capitellar fractures.

KEY WORDS: capitellar fractures , k.wires fixation , MEPI , ASES

INTRODUCTION:

Isolated coronal shear fracture of the capitellum is relatively rare , accounting for 1% of all elbow fractures and 6% of distal humeral fractures ⁽¹⁾.

It represents a significant partial articular injury especially when the injury extends medially to involve the trochlea , or when it occurs in association with ipsilateral radial head fracture. The injury is a result of low energy fall when direct axial compression transmitted to the capitellum by the radial head , or alternatively during spontaneous reduction of a postero-lateral elbow subluxation.

However the complex nature of the injury is not fully appreciated , there are several classification systems of capitellar fracture , Ring et al⁽²⁾ identified 5 articular segments injury pattern , Bryan and Morrey⁽³⁾ classified capitellar fracture as type (I) is a shear fracture in the coronal plane involving most of the capitellum , little or non of the trochlea , type (II) fractures involve subchondral bone , type (III) is a comminuted or compression fracture of Kocher Lorenz, type (IV) is a coronal shear fracture extended medially to involve most of the trochlea , this type described by McKnee et al ⁽⁴⁾ as Double –arc sign Fig (1).

College of Medicine. Baghdad University.
Dept. of Surg.

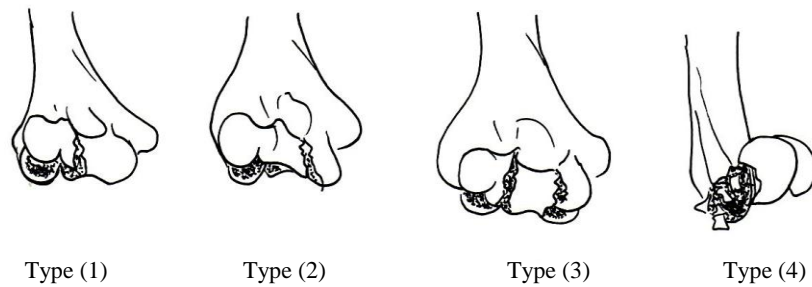


Fig 1: Classification of capitellar fractures (Bryan and Morrey) ⁽³⁾

PATIENTS AND METHODS:

Between January 2007 and March 2011 , 15 patients who have sustained isolated capitellar fracture presented to AL-Haryry Hospital for surgical specialties, Medical City Teaching hospital-baghdad , they were diagnosed and treated operatively within 2 weeks after injury (range 0-14 days) , with mean of 6 days. They were eleven females and four males , their age ranged from 16 year to 58 years with 6 patients younger than 30 years. The right arm was dominant in 12 patients , the left in three.

The fracture type was determined by antero-posterior view , and lateral/or oblique radiograph or intraoperatively . Computed tomography scanning was used in five cases only, any associated injuries e.g radial head fracture , was recorded in the data . Nine patients were available for clinical and radiographic evaluation at a minimum of one year postoperatively (mean duration of follow up (12-38 months). four patients were followed for 36 months post-operatively . Three patients were lost to follow 18 months after surgery . The operative technique was through a lateral approach, through an incision centered over the lateral condyle of a pronated forearm. The common extensor origin conjunction with the anterior capsule were elevated , anteriorly , distally the Kocher ⁽⁵⁾ interval was identified and connected to the proximal exposure , the lateral aspect of the triceps was elevated when a postero-medial comminution was present (in two patients with type IV fracture subgroup .. the fracture was reduced in its place , while the elbow in semiflexion, stabilization achieved percutaneously with two k. wires introduced by posterior to anterior direction to the capitellum all through to the center of the radial head then to the diaphysis for a variable distance ,

unreconstructable fragment or fragments < 20% of the articular surface of the radial head excision was performed ⁽⁶⁾. (in two patients,)

Complete plaster cast applied on a thick pad of cotton wool (to avoid minor movement threatened break of the wires) , the elbow was put at approximately at 90° flexion ,Neither olecranon osteotomy , fixed angle plating , nor bone grating was not used in any case.

Post-Operative follow up was by One week interval visits. On the third week the P.O.P was removed together with the k. wires , back slab splint applied for another 10-14 days before removal and active, and active assisted range of motion started.

Clinical examination for evaluation of R.O.M including the arc of flexion –extension measured by handheld goniometer , and stability evaluated by history and provocative physical examination manouvre for valgus and varus.

Serial Antero-posterior and lateral radiography were done for fracture union, osteonecrosis , heterotopic ossification or osteoarthritis.

Evaluation at the last visit with the use of [A] American ⁽⁷⁾ shoulder and elbow surgeons (ASES) assessment form , which consists of (a) patient's self-assessment section scale of satisfaction, ranging from 0 (not at all satisfied) to 10 very satisfied, through 10 questions related the patients daily activities . 4 points for each (maximum 40) points , and (b) physical examination section of 4 parts : motion , stability , muscle, strength and physical findings (tenderness , pain , crepitus) and [B] The Mayo Elbow Performance Index (MEPI) which is based on 100 points scale of 4 subscales , 50 points for the pain relief , 25 points for functions:

OPEN REDUCTION CAPITELLAR FRACTURE

(grooming 5 , feeding 5 , personal hygien 5 , putting on shirt and shoes 5+5 (10) , 20 point for motion , 10 for stability , the excellent result ≥ 90 , the good 75-89 points.) . fair 60-74 points. poor < 60 points.

The ulno-humeral flexion extension (contracture and the net ulno-humeral arc) recorded at each visit, These expressed by mean values, and p-value in the final results .

RESULTS:

Eight patients with type I , one type II , four type III and two type IV capitellar fracture (McKee)⁽⁴⁾ were identified , according to Bryan and Morrey classification system, all were closed fractures. One patient had concomitant ipsilateral colles fracture, and one patient had cut flexor tendon of Ring finger. Type III fracture in one patient was associated with elbow dislocation and the lateral collateral ligament found avulsed with a linear bone from the lateral condyle (reattached by supplementary k.wire).

The mean union time was 10 weeks (8-12 week) . The average arc of (ulno-humeral motion) was 120° (range 90° - 135°) , and average of flexion of 125° (range 95 - 140°). The contracture average was 15° (range 8° - 35°) eleven patients achieved functional arc of U.H.M 116° (20 - 135°) .10 patients had no pain , and four had mild and moderate pain in one.

The overall ASES function score was 34 ± 3 (range 29-40 points) satisfaction score was 8 ± 2 points (range 8 to10 points) . Regarding The MEPI score the mean was 90 ± 10 points (range 80-100 points), All patients returned to their pre-injury occupation. Table (1) illustrate the arc of UHM and the flexion extension range and the net UHM. While table (2) showed the ASES & MEPI according to fracture subgroup. And Table(3) show the physical out com results

three patients had ipsilateral radial head fracture , two patient in type III and one with type IV. Cupsequent surgical procedure required in one patient was excision of radialhead for loss of function due to R.O.M. of less than 30° – 130° . R.O.M. in the other two patients were acceptable two the patients , 20° - 125° .

Table 1: The functional out come in relation to the fracture subgroup . Type I and III +IV ASES

Type	No.	ASES		MEPI points	Extension	Flexion	Net Ulnohumeral arc
		Function	Satisfaction				
Type I	8	36	8	94	8	127°	135°
Type III +IV	6	33	7	89	18	107°	122°
		0.8	0.49	0.73	0.04	0.01	

Table 2: Functional out come according to MEPI score in all fracture types

Rating	TYPE I No. 8	Type II No. 1	Type III No. 4	Type IV No. 2	P value
Excellent	5		2	0	0.8
good	2	1	1	2	
fair	1		1	0	
poor	0		0	0	

Table 3: Mean values of physical outcomes of all types MEPI (Points).

Pain	Motion	Stability	Function	Total (outcome)
36	18	9	23	90
Extension				10(3 to 40)
Flexion				130° (102 to 40)
Net ulno humeral arc				122° (70-142) ^o
ASES	Function			35 ± 3 (27 to 38)
	Satisfaction			8 ± 2 (4 to 10)

DISCUSSION:

Over the past three decades' literatures reveals that authors continue to differ on the preferred method of treatment of capitellar fracture with opinions varying among reduction by close manipulation, to surgical excision of the capitellum or to open reduction and internal fixation. Further more of the various fixative devices which had been used, e.g cancellous lag screws, cannulated variable-pitch headless compression screws, Herberts' screw or by k. wires of the smooth or the threaded type. Each mode of treatment has its proponents and opponents. In this relatively small cohort analysis and evaluation a uniform relatively limited lateral approach was used which did not necessitate extensive soft tissues dissection in order to avoid post operative scarring and heterotopic ossification. The exposure is merely to visualize the passage of the k. wire through the elbow joint. Stable fixation could be achieved by this method as MEPI scores and ASES index showed the results which was far exceeded the result of Ruschmann et al⁽⁶⁾ who followed extensile lateral approach with elevation of common extensor and pronator tendons in order to insert headless screws from anterior to posterior direction.

The overall R.O.M results and the elbow specific outcome compared favorably with Doornberg et al⁽⁸⁾ and by far exceeded the results of Statmatas et al⁽⁹⁾.

The mean UHM arc of 116° and a mean MEPI score of 90 points corresponded with a series of (17)patients by Dubberley et al⁽¹⁰⁾, who used cancellous lag screws inserted from posterior to anterior direction with flexion contracture in his series (40°-22°).

Ring et al⁽²⁾ reported an arc of 119° and a mean MEPI of 91° points, a good to excellent result in 16 of 21 patients a figure highly compared to ours which was excellent to good result in 11 of 15 patients. However he included fractures extended to the medial condyle, Ring type⁽²⁾ IV which has been regarded by Dubberley et al Norris et al⁽¹⁰⁾ and us as a lower humeral fracture rather than isolated shear capitellar fracture, in addition both performed olecranon osteotomy in all type IV fracture cases. Ring⁽²⁾ et al did not stratify their results or complications according to fracture subgroup as in this series.

The average arc of UHM of type IV in this cohort was 100° and the MEPI score was 90 points a result correspond favorably with Rushelsman et

al⁽⁶⁾ Whose score was below 90 and an arc of UHM of the same subgroup at 89 points.

Goodman and Choucka⁽¹¹⁾ reported MEPI score of 84 points for 8 patients, and a mean contracture of 18° in type (IV) while the mean in this series was 15°, The significant loss of terminal extension in type IV is due to a posterior commotion, trochlear extension and impaction, this finding was found in all other studies (Grantham⁽¹²⁾, and Stamatis et al⁽⁹⁾). However an added factor to this loss is the extended operative dissection (Ruschelsmann et al⁽⁶⁾) in order to create a space for antero-posterior insertion of screws while k.wire doesn't necessitate that extent of dissection.

The functional outcome of elbows (three patients) associated with radial head fractures did not significantly alter the result when a good result in all those three patients achieved, Dubberley⁽¹⁰⁾. Arrived at the same Conclusion, However he reported excellent elbow function in three patients with radial head fractures too. We confess that results of a small number of patients with radial head fracture can not draw a firm conclusion about the impact, a larger series needed to reveal significant data.

The number of fifteen patients reported in this cohort is regarded a considerable size, compared to a series of Ring et al⁽²⁾ MacDermid et al⁽¹³⁾ Mighell et al⁽¹⁴⁾.

Recently Doornberg et al⁽⁸⁾ demonstrate that short term functional outcome following distal humeral fracture endured after a mean duration of follow up of 19 years, furthermore, Sano et al⁽¹⁵⁾ noted that functional outcome and perceived disability were predicted more on pain than on functional impairment, and did not correlate with radiographic signs of arthrosis, delay of operative treatment after injury up to 20 days had no evidence to induce osteonecrosis in capitellar fracture. (Elkowitz et al⁽¹⁾, Mahirogullari et al⁽¹⁶⁾, Sano⁽¹⁵⁾).

Computed scanning have been utilized only in five cases, in order to verify the exact type of fracture subgroup.

There were no cases with clinically important heterotopic ossification, and no pharmacological prophylaxis used after internal fixation (advocated by Stamatis et al⁽⁹⁾ and Sano et al⁽¹⁵⁾).

CONCLUSION:

Excellent to good outcome with functional ulno-humeral motion can be achieved by open

OPEN REDUCTION CAPITELLAR FRACTURE

reduction and internal fixation of closed isolated capitellar fracture by k.wires , with less complications (e.g flexion contracture , osteonecrosis) and less additional surgeries needed post operatively.

REFERENCES:

1. Elkowitz SJ , Polatsch DB , Egol KA , Kummer FJ , Koval KJ : Capitellums fractures a biomechanical evaluation of three fixation methods , J orthop Trauma 2002;16:503-6
2. Ring D , Jupiter JB , Gulottal L : articular fracture of the distal part of the humerus J , Bone joint surg. Am 2003 ;85: 232-38
3. Bryan RS , Morrey BF , Fractures of the distal humerus. In : Morrey BF , editor. The elbow and its disorders. Philadelphia : WB sounders 1985: 325-33.
4. McKee MD , Jupiter JB , Bamberger HB , Coronal shear fractures of the distal end of the humerus , J Bone joint surg Am 1996;78:49-54.
5. Kocher T; operations at the elbow. In: Kocher T, editor : stiles HJ, Paul CB, Translators; textbook of Operative sergery 3rd ed. London; Adam and Charles Black. 1911:313 – 18.
6. Ruchelsman DE , Nirmal C , Tejwani , Kenneth A , et al . Open reduction and internal fixation of capitellar fractures with headless screws , J Bone Joint Surg. Am , 2008 ;90:1321-29.
7. King GJ , Richards RR , Zuckerman JD , Blasier R , Dillman C , Freedman RJ : A standardized method for assessment of elbow function , Research Committee , American shoulder and elbow surgeons , J Shoulder elbow surg. 1999;8: 351-54.
8. Doornberg JN , Van Duijn PJ , Linzel D , Ring DC : Surgical treatment of intra-articular fractures of the distal part of the humerus , Functional out come after twelve to thirty years , J Bone Joint Surg Am 2007; 89:1524-32.
9. Stamatis E , Paxino O , The treatment and functional out come of type IV coronal shear fractures of distal humerus : a retrospective view of five cases , J orthop Trauma 2003;17: 279 – 84.
10. Dubberley JH , Faber KJ , Macdermid JC , Pattreson SD , King GJ : Out come after open reduction and internal fixation of capitellar and trochlear fractures . J Bone Joint Surg. Am 2006 , 88. 46-54.
11. Goodman HJ , Choueka : Complex coronal shear fractures of distal humerus , Bull Hosp. Jt Dis 2005; 62 : 85-89.
12. Grantham SA , Norris TR , Bush DC , Isolated fracture of humeral capitellum , Clin Orthop Relat . Res 1981:161 262-9
13. MacDermid JC , Roth JH , Richards RS , Pain and disability report in the year following a distal radius fracture . A cohort study . BMC Musculoskeletal disord. 2003;4:24.
14. Mighell MA. Harkins D, Klein D. Schneider S, Frankle M, Technique for internal fixation of capitallum and lateral trochlea fractures. J orthop Trauma, 2006; 20: 699 – 704.
15. Sano S , Rokkakut , Saito S , Tokunaga S , Abe Y , Moriya H. Herbert screw fixation of capitellar fractures , J shoulder elbow surg. 2005; 14: 307-11.
16. Mahirogullari M , Kiral A , Solak Oglu C , Pehlivan O: Akmaz I , Rodop O , Treatment of fracture of the humeral capitellum using Herbert screws . J Hand surg (Br) 2006 ;31: 320-25.