

Histological and Biochemical study on effect of dried fruit extract of *S. nigrum* on Hepatopathy induced by CCL4.

Wafeeq N.H. *, Maha k.I. **, Abdulah H.L. **

* Community Health , Technical Institute of Basrah , Foundation of technical Education

** Biology Department , Collage of Science , University of Basrah

Abstract

The results of the present study evaluate the efficiency of dried fruits extract on hepatic damage induced by CCL4. The histopathological changes were less obvious in livers related to rats in (G111) which treated with the extract and then with CCL4 comparative to histological exam of livers related to rats in (G11) treated with only CCL4 and control animals (G1) .

In this study we assessed some of hepatic enzymes levels such as GOT,GPT , ALP and total bilirubin in blood serum .All enzymes showed high significant reduce ($p<0.01$)in animals treated with the extract compared to that in animals treated with CCL4 alone and with controls .

The results also described the histopathological changes including damage ,necrosis of hepatic cells and central vein congestion in addition to bile ducts hyperplasia in rats livers in (G11) compared with animals in (G1) and (G111) .

The rats treated with CCL4 resulted in enlargement of livers while the animals treated with extract showed livers normal with size similar to that in control group .

Introduction

The herbs play a vital role in the management of various liver disorders .In the absence of a reliable liver protective drugs in the modern medicine ,a number of medical preparation in a yurvedh are recommenoted for the treatment of liver disorders(Chartterjee,2000) .

Solanum nigrum (Family : Solanaceae) is a shrub found through India ,it is traditionally used for inflammation ,diuretic and liver disorders(Nadkarni ,1995) . It is also used in treatment as antihypertension ,antispasmodic and anticancer factor specially with digestive and urinary system carcinoma (Friedman *et al.*,2003).

S.nigrum contain many essential reactive compounds like glycosidal alkaloids and steroidal alkaloids (Iamb & Buck, 1989). The toxicity effects of *S. nigrum* related to Solanine and Solasodine alkaloids in addition to its content of nitrate and nitrogen with high rate more than 2.5% (Neilson, 1974).

Mather *et al.*, (1987) studied the treatment ability found in most plants extracts including *S. nigrum* and called Liv.(25) on liver damage and blood sugar lowering which caused by beryllium nitrate. The effect of three types extracted from *S.nigrum* fruits and their ability on healing peptic ulcer induced by aspirin in laboratory rats were described by Jahnu & Devi (2006).

Freidman (2003) identify the effect of steroidal glycoalkaloids on laboratory mice infected with hepatomegaly.

Alcoholic extract of *S.nigrum* play an important role as antioxidant factor in experimental rats infected with carcinoma induced by N-diethyl nitrosamine through its action as inhibitor to tumour growth factor (Shahjahan *et al.*, 2005).

Ethanollic extract from *S. nigrum* dried fruits have an action to reduce the cholesterol level in rabbits and this give an indicator to use these fruits in treatment of disease caused by increase fatty level in blood like arteriosclerosis (Odetola *et al.*, 2004).

Materials and Methods

1. Plant material

The fruits of *S. nigrum* were collected, washed and cut in to small pieces, dried and powdered according to (Raju *et al.*, 2003). 20 gm from coarse powder was taken and mixed with 400 ml of 95% v/v ethanol, then subjected to continuous hot extraction in a Soxhlet for 24 hours. The ethanol was removed by the rotary evaporate system. These extract were suspended with gum acacia to study the effect of this material on liver damage induced by CCL4 in experimental rats.

2. Animals

Eighteen male albino rats of *Rattus norvigicus* weighting (120-130) gm were procured from animal house of Biology department – Science collage. The animals were housed in plastic cages maintained in controlled temperature (20 -25) and light cycle (12 h light and 12 h dark). They were feed on commercial diet and water ad libitum during experiment period (Al.fartosi, 2004).

The selected animals were divided into three groups of (6 rats) on each and were treated as follows :-

G1 : Animals were consider as control group inoculated (0.2ml) of 5% gum acacia daily for (7days).

G11 : Animals inoculated with (0.2ml) of gum acacia only.

G 111: animals inoculated with ethanolic extract of *S.nigrum* dried fruits at adose (250

mg/kg) of body weight suspended with (0.2ml) of 5% gum acacia daily for (7 days). At seventh day carbon tetrachloride (1.25ml/kg) peritoneally was administered (30 min) after the last dose to all rats except rats in (G1). After (36 h) all animals were sacrificed under chloroform anesthesia, then the blood was collected in sterile centrifuge tube and allowed to clot. Serum was separated by centrifuging and used for the estimation of serum enzymes like GOT, GPT by using the transaminase kit and ALP by using phosphatase Kit in addition to total bilirubin content with photometric test.

After the animals were sacrificed, the abdomen was cut open and the livers removed, the morphological changes like size and colour were observed, all livers fixed with formalin (10%) and were processed for paraffin embedding, five micron section of livers, stained with haematoxyline-eosin were examined with light microscopy to study the histopathological changes (Luna, 1968).

Results

1-Biochemical estimations

The biochemical parameters results showed variation in all enzymes concentration levels (GOT, GPT, ALP) and total bilirubin content

in all rats treated with CCL4 compared with control rats (Table -1).

The enzymes levels didn't show any significant differences ($p < 0.01$) in (G1) rats before and after inoculation with gum acacia while high significant difference ($p < 0.01$) in blood enzymes levels and total bilirubin observed in rats related to (G11).

A significant ($p < 0.01$) reduction was observed in GOT, GPT, ALP and total bilirubin content in the group treated with ethanolic extract of dried fruits of *S. nigrum* (G111) comparison to group (G1) and (G11) (Table -1).

2—Effect of *S. nigrum* extraction and CCL4 on livers weight

All the livers related to animals in group (G11) which treated with gum acacia and then CCL4 appeared enlargement that were pale reddish brown in colour and showed high significant difference ($p < 0.01$) in their weight compare to control animals (Table 2). The group (G111) which treated with ethanol extract of *S. nigrum* showed livers size which was similar to control group and the livers with dark-red colour. However a significant ($p < 0.01$) restoration in their weight found in this group treated with extract (Table -2).

Table (1) Effect of *S.nigrum* extract on some biochemical parameter

Biochemical parameters				Test time	Group
Total bill (mg%) mean ±SD	ALP(kau/ml) mean ±SD	GPT (u/ml) mean ±SD	GOT (u/ml) mean ±SD		
0.606± 0.075	11.967± 0.128	24.700± 0.774	2.200±0.073	Before	G1 (control treated with gum acacia)
0.620± 0.073	12.467± 0.334	25.217± 0.651	2.501±0.201	After	
0.626± 0.066	11.967± 0.102	23.967± 0.771	2.38±0.121	Before	G11 treated with gum acacia then CCL4
1.050 **± 0.084	20.817 **± 0.542	36.688 **± 2.337	5.150 **± 0.150	After	
0.6833± 0.060	11.700± 0.204	24.283± 0.454	2.183±0.047	Before	G111 treated with dried fruits and gum acacia then CCL4
0.8333± 0.033	16.817 *± 0.912	28.890 *± 0.364	3.825 *± 0.395	After	

**High significant difference on (P<0.01) in (R.L.S.D) test

*low significant difference on (P<0.01) in (R.L.S.D) test

Table (2) Effect of dried fruits extracts on rats livers weight (gm)

G111 treated with dried fruits extract suspended with gum acacia and then with CCL4)	G11 treated with gum acacia and then with CCL4	(G1)(control)treated with gum acacia only
4.725±0.212	6.450±* 0.381	3.966±0.064

*High significant difference on (P<0.01) test

3-Histopathological study

The histopathological changes in experimental rats caused by CCL4 induced liver damage and effect of ethanol extract of

S.nigrum dried fruits were resulted in this study .

Histopathological examination of the livers related to animals treated with gum acacia didn't show any changes and the hepatocytes

appear normal size with central one or two nuclei ,the cells arranged in hepatic cords concentrically around central vein and these cords separated by vascular spaces called the hepatic sinusoids (Fig . 1) .

The livers of CCL4 –treated rats revealed severe pathological changes ,they showed central vein congestion ,dense an inflammatory cells proliferation specially around the bile ducts and prenerotic changes

at some places distant from the central vein (Fig – 2) ,in addition hehatocytes hypertrophy with vacuolated cytoplasm and hemorrhage also observed (Fig – 3) .

Light microscopic examination of sections from rats treated with extract suspended with gum acacia then CCL4 showed significant regeneration ,minor inflammatory cells around central vein with kupffer cells through sinusoides (Fig -4) .

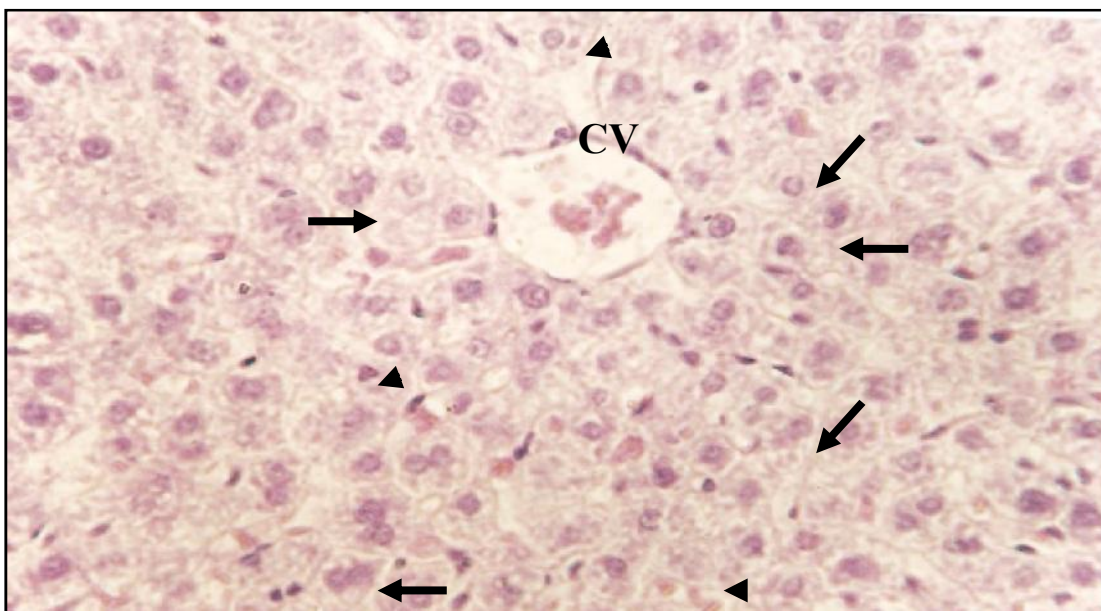


Fig. (1) Liver of control rats showing the central vien (CV) Hepatocytes (—▶) and sinusoids (▶) (500X H&E)

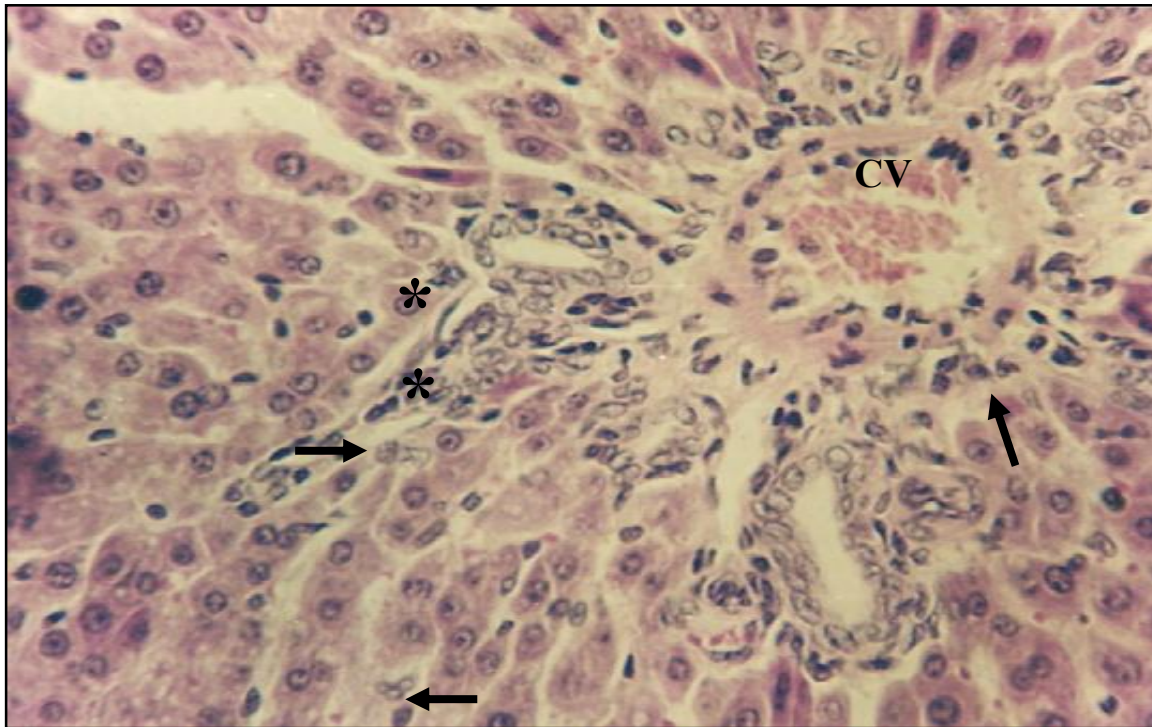


Fig (2) Section in liver of rats treated with gum acacia then with CCL4 Showing congestion in central vein (CV) ,infiltration of an inflammatory cells (→) and bile ducts hyperplasia (*)(500x H & E)

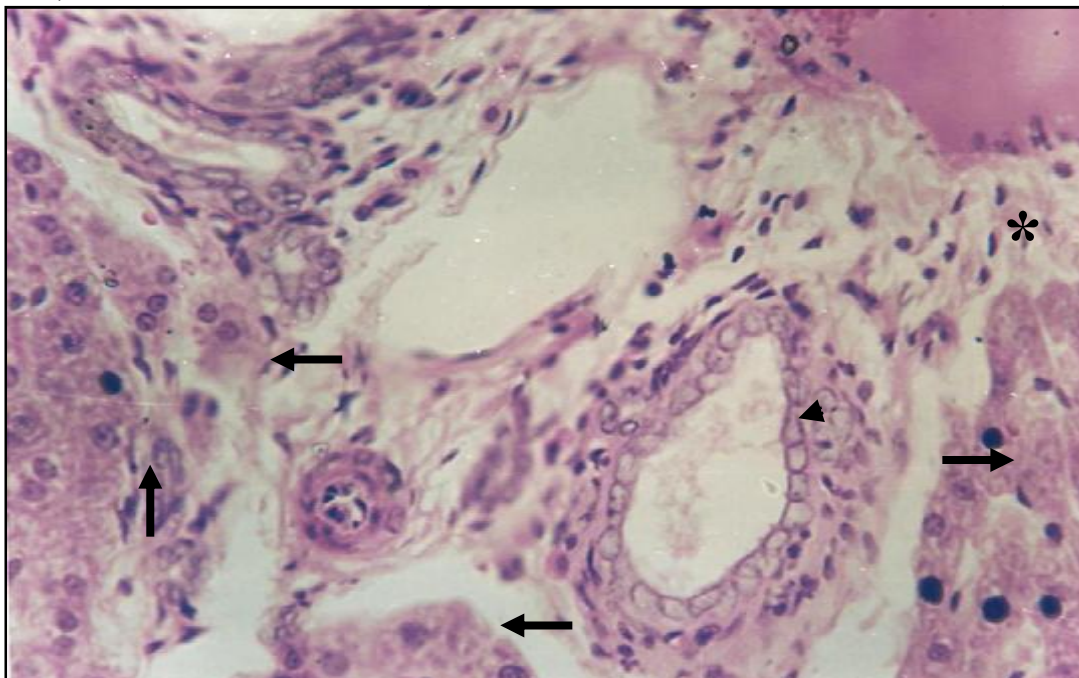


Fig.(3) Section in liver of treated rats showing complete degeneration of hepatocyte (→) bile ducts hyperplasia (▲) and proliferation of inflammatory cells (*) 500x H&E)H & E 500x(

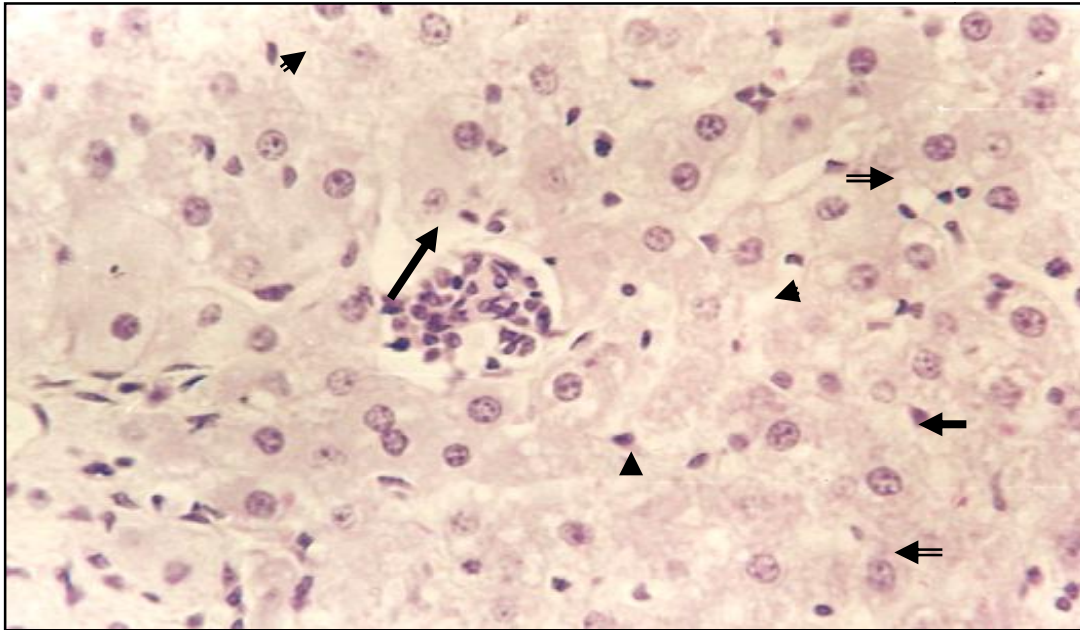


Fig.(4) Photomicrograph of liver related to rats treated with the extracts and then CCL4 showing few inflammatory cells (), partial degeneration of hepatocytes () and kupper cells (▶).
500X .H & E)(

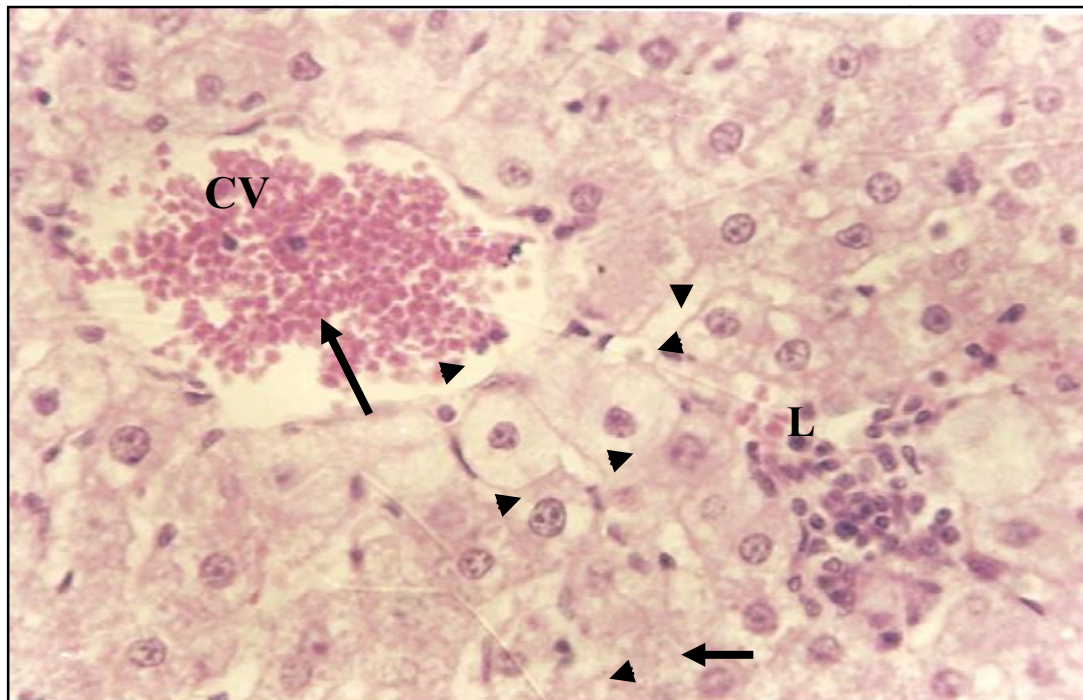


Fig. (5) Section in liver of rats treated with gum accacia and then CCl4 illustrate hemorrhage in central vein (CV) ,hepatocytes hypertrophy with cytoplasm degeneration(▶) and infiltration of inflammatory cells (L). (500X .H&E)

Discussion

The present study focus on the liver damage induced by CCL4 and the efficacy of *S.nigrum* dried fruits extracts as hepatoprotective material .

1- Effect of dried fruits extract on biochemical parameters

The present study showed that some of liver enzymes like (GOT ,GPT ,ALP) in addition to total bilirubin content were significantly higher ($p<0.01$)in (G11)animals compared with control (G1) ,while the enzymes concentration showed significantly decrease in (G111) animals.

The variation in these enzymes concentration and total bilirubin content in (G111) animals which treated with CCL4 may be caused by the ability of this compound to induced hepatic cells degeneration ,damage of supplied blood vessels and then disturbed the metabolic activity of liver .

The study agreed with Anderson (1980) who identified the important of liver in synthesis and storage of glycogen ,lipids and some vitamins ,also the liver role in synthesis of plasma proteins and its main organ with detoxification activity for many drugs and plant extractions .

Our finding identified that the enzymes concentration was significantly decreased in G11 animals which treated with dried fruits extraction and this may be related to unknown

cellular mechanical protection for hepatic cells and then restored normal structure compare with liver of animals treated with CCL4 , This finding agreed with Raju *et al.*, (2003) who confirmed the role of *S.nigrum* dried fruits extract on some liver enzymes levels .

Venkumar & bathes (2000) confirmed that ethanolic extract from *Curculigo orchiods* rhizomes has an effect on reduced liver enzymes levels in animals infected with damage .

Our observation showed significant increase ($p<0.01$)in livers weight of animals in group G11 also these livers looks enlargement and pale colour comparative with livers in G1 and G111 animals which didn't showed any significant difference .

The study in agreement with Raju *et al.*,(2003) who related the main cause in hepatomegaly and colour change to CCL4 while the animals treated with dried fruits extract restored to normal structure similar to that in normal rats . This suggest the maintenance of structural features of hepatocytes or regeneration of damage cells by the effect of extract .

On the light of histologic observation the CCL4 was hepatotoxic caused liver damage and liver section of rats treated with it showed necrosis ,hyperplasia in bile ducts walls and dense infiltration of inflammatory cells while the rats treated with the extract and then CCL4 showed evident of protection as formation of normal hepatic cords and

absence of necrosis and other histopathological changes .

These results agreed with Lindberg *et al* (1997)who indicated that the damage cells release some compound like prostoglandine (E1) which have chemotactic ability to an inflammatory cells .

Macsween &whaley (1997) confirmed that the neutrophils cells migrate to damage tissues and secrete more chemicals mediators to attract another cells to the area in addition to release protein caused by cells degeneration Raju *et al.*,(2003) established the toxic effect of CCL4 which induced experimentally liver damage due to free radical formation which caused lipid peroxidation of cellular membrane leading to hepatocytes necrosis and then dysfunction which improved by significant increase ($p<0.01$) in some enzymes level , also bile ducts hyperplasia which lead to variation in blood serum total biliruin content .The efficacy of dried fruits extract as hepatoprotective material against CCL4 induced liver damage was improved and further study recommended to identify the cellular mechanisms that may be involved .

References

Al-Fartosi, K.K. (2004). Physiological studies of the effects of benzene in laboratory mice and human, ph.D. thesis , college of Education University of Basrah.

Anderson, J.R. (1980). Muir's text Book of pathology 11th ed. Edwaed Aronold. Norwich.

Anthony, H.R. (1976). Chemical microbiology. An introduction to microbial physiology. 3rd ed. Butterworth, Ltd., London.

Chatterjee T.K.(2000) .Medical plants with hepatoprotective properties in herbal options , Books and Allied (p) Ltd ,calcutta ,3rd ed ., p.135.

Friedman, M. ; Henika, P. and mackey, B. (2003) . Effect of feeding Solasodine and Tomatodine to non-pregnant and pregnant mice. . Food and chem. Toxicol. 41: 61-71.

Lamba , S .S .and Buck , K . Y . (1989) .Estimation of glycoalkaloids as solasodine in *Salonum torvum* (solanaceae) indigenous to Jamaica . Phyton . 49 , 35-39.

Lindberg, R. ; Johansen, M.V. ; Montrad, J. ; Christensen, N. and Nansen, P. (1997). Experimental *Schistosoma bovis* infection in goats. The inflammatory response in small intestine and liver in various phase of infection and reinfection. J. Parasitol., 83: 454-459.

Luna, L. (1968). Manual of histological staining methods of Armed forces institute of pathology 3rd ed. McGraw-Hill Book company, New York, London.

- Macsween, R. and Whaley, K. (1997). Muir's text book of pathology 13rd ed. Edward Arnold, London. 1245pp.
- Mathur, S. ; O, P. and R, M. (1987). Effect of liv.52 on blood sugar in beryllium nitrate-exposed Rat. Current science. (7): 322 .
- Nadkarni K.M. (1995) .Indian Material Medica ,popular prakashan Pvt Ltd ., Bombay ,3rd ed ., pp.574 -575.
- Neilson, F.J. (1974). Nitrate/Nitrite poisoning of stock, N.Z.J. Agric., 128: 43.
- Odetola, A.A. ; Iranloyle, Y.O. and Akinloyle, O. (2004). Hypolipidaemic potentials of *Solanum melongena* and *Solanum gilo* on Hypercholesterolemia Rabbits. Pakis. J. Nutri. 3(3): 180-187.
- Raju, K. ; Anbuganpathi, G. ; Gokulakrishnan, V. ; Raj Kapoor, B. ; Jayakar, B. and Manian, S. (2003). Effect of dried fruits of *Solanum nigrum* linn. against CCl₄-induced hepatic damage in rats. Biol. Pharm. Bull. 26(11): 1618-1619.
- Shahjahan, M. ; Vani, G. and Shyamaladevi, C.S. (2005). Effect of *Solanum trilobatum* on the antioxidant status during diethyl nitrosamine induced and Phenobarbital promoted hepatocarcinogenesis in rats. Chem. Bio. Int. 156: 133-123.
- Venukumar, M.R. and Latha, M.S. (2003). Antioxidant activity of *Curculigo orchioides* in carbonyl tetrachloride induced hepatopathy in rats. Ind. J. of clin. Biochem. 17(2): 80-87.

دراسة نسجية وكيميائية حيوية حول تأثير مستخلص الثمار الجافة في نبات عنب الذيب S.solanum على تلف الكبد المستحث بال CCL4 .

وفيق ناصر حسن * ومها خليل إبراهيم ** وعبد الله حمد لفته **

*قسم صحة المجتمع، المعهد التقني في البصرة، هيئة التعليم التقني

** قسم علوم الحياة، كلية العلوم، جامعة البصرة

المستخلص

أكدت نتائج الدراسة الحالية الفعالية الأيجابية لمستخلص الثمار الجافة على تلف الكبد المستحث بواسطة رابع كلوريد الكربون (CCL4)، كانت التغيرات النسجية أقل وضوحاً في أكباد الجرذان ضمن المجموعة (G111) التي عوملت بالمستخلص ومن ثم بالمركب CCL4 مقارنة مع الفحص النسجي لأكباد الجرذان ضمن المجموعة (G11) التي عوملت بال CCL4 فقط ومع حيوانات السيطرة ضمن المجموعة (G1) .
تم في هذه الدراسة قياس مستوى بعض أنزيمات الكبد مثل ال GOT وال GPT وال ALP فضلاً عن محتوى البليروبين الكلي في مصل الدم . أظهرت جميع الأنزيمات انخفاضاً معنوياً عند مستوى احتمالية ($P < 0.01$) في الحيوانات المعاملة بالمستخلص مقارنة مع تلك المعاملة بال CCL4 فقط وحيوانات السيطرة .
أوضحت نتائج التغيرات النسجية التي تضمنت التلف النسيجي والنخر للخلايا الكبدية واحتقان الأوردة المركزية فضلاً عن فرط التنسج للأفنية الصفراوية في أكباد جرذان المجموعة (G11) مقارنة مع الحيوانات في المجموعتين (G1) و (G11) .
أظهرت الجرذان التي عوملت بال CCL4 وبالنتيجة أكباداً كبيرة الحجم بينما تلك التي عوملت بالمستخلص كانت أكبادها اعتيادية مع حجم طبيعي مشابه لأكباد الحيوانات ضمن مجموعة السيطرة .