

## **HISTOLOGICAL STUDY ON THE SYSTEMIC INFECTION OF THE FUNGUS *CLADOSPORIUM* SP. TO SOME ORGANS IN BALB/C MICE**

Adel J. Hussein\*, Basil A. Abbas\*\*

\*Department of Anatomy, College of Veterinary Medicine, University of Basrah,  
Basrah, Iraq.

\*\*Department of Microbiology, College of Veterinary Medicine, University of Basrah,  
Basrah, Iraq.

(Received 17 January 2005, Accepted 6 June 2005)

**Keywords:** Cladosporium, Mycelia, Necrosis.

### **ABSTRACT**

Balb/c mice were used for investigating the ability of the fungus *Cladosporium* sp. To infect the animal organs. Livers and kidneys of the animals were fixed and histopathologically examined after injecting the animal with fungal spores. The study showed that the fungus *Cladosporium* sp. is able to infect the animal organs. Fungal mycelia was observed among tissue cells in addition to many histological changes such as cell degeneration, necrosis, congestion and bleeding.

### **INTRODUCTION**

Fungi have been reported to cause several human diseases (1-7). *Aspergillus* spp. reported to infect lungs causing a disease called Aspergillosis (2). In chronic herpetic involvement of central nervous system (CNS), *Cladosporiosis* is considered as a lesion resulting from a immunosuppression (3). *Cladosporium* also reported to cause many fungal diseases. For example, *C. oxysporum* have been isolated from biopsy of papulo-nodular lesions of leg (4). *C. bantianum* has been found to cause meningitis in adults and children (5). *C. cladosporoides* causes opportunistic infections involving skin in immunocompromised patients (6). Infection with *Cladosporium* have been also reported in patients after transplantation (7).

The present study aims to investigate the ability of this fungus to infect kidney and liver tissues of the animals.

### **MATERIALS AND METHODS**

**Animals:** Eight Balb/c mice (male) with 2 months age and weight ranged between 25-80 gms were used for lab. experiment.

**Fungus:** Clinical isolate of the fungus *Cladosporium* sp. were obtained from fungal laboratory of College of Science . Basrah University. The fungus grew on PDA medium and incubated at 30°C for 2 weeks. Fungal spore suspension was made in normal saline and arranged to 10<sup>30</sup> spore / ml.

**Injection:** 1/2 ml of the above suspension was used to inject 6 animals in peritoneum. The rest of animals were injected with 1/2 ml normal saline as control.

**Histology:** After one month of post injection, animals were killed. Animal organs (livers and kidneys) were fixed in 10% formalin for 24hrs. For block preparation, paraffin wax method was applied according to Drury *et al.*, (8), followed by sectioning with 5µm cutter. Slides were stained with hematoxylin-eosin for histopathological study. Other slides stained with P.A.S. for fungal examination.

## RESULTS

Histological study of the infected animal organs showed that the fungus *Cladosporium* sp. was able to infect these organs systemically. Fungal mycelia were appeared in liver and kidney tissues. Many histological changes have been observed in studied organs by the fungal infection (Fig 1).

Response to the infection and cell degeneration was seen in kidney tissues in addition to heavy bleeding (Fig 1 & 2). More over renal tubules necrosis was also observed in kidney tissues (Fig 3).

Liver tissues showed less changes in comparison to the renal tissues. Blood vessels congestion and bleeding in different locations of liver (Fig 4). Granuloma was appear in liver tissues in addition to cell degeneration and blood coagulation. Many white blood cells were aggregate in blood vessels (Plate 5).

## DISCUSSION

In the present study, the animal tissues were infected by the fungal mycelia indicating the ability of the fungus *Cladosporium* to infect the animal systemically. Following the injection of the animal with 10<sup>15</sup> spores, the fungal threads were appeared in the tissues. The histological study of the tissues showed that the fungus inducing many histological changes in studied organs, such as infection, blood vessels congestion, bleeding and white blood cell aggregation. This results is agreed with the previous studies on filamentous fungi ( 9 , 11 ). Liver and Kidney necrosis was observed in the infected tissues. This may be happened due to the enzymatic activity of the fungus ( 10 ). The renal

tubules necrosis was observed also in this study and this in line with the previous study on the fungus *A. fumigatus* ( 11 ). Aggregation of white blood cells also seen in infected areas. This may be as a result of presence of fungal spores which act as foreign bodies.

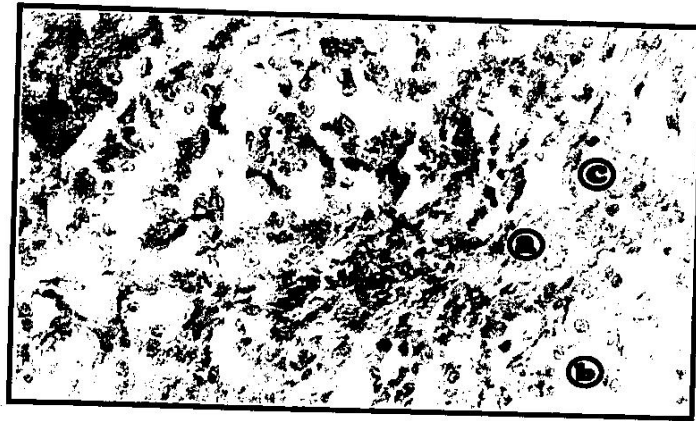

Fig. (1): T.S in Kidney of Mice infected with *Cladosporium* sp. showing: bleeding(a); renal tubules degeneration (b); Fungal mycelia (c). H&E satin (330X)

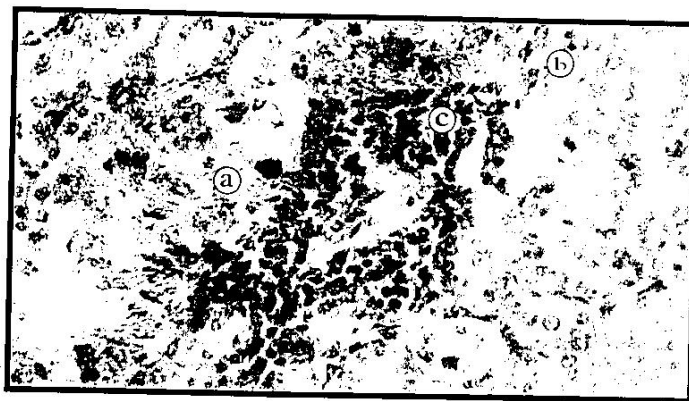

Fig. (2): T.S in Kidney of Mice infected with *Cladosporium* sp. showing: heavy bleeding (a); necrosis (b) and cell congestion (c). H&E satin (330X)

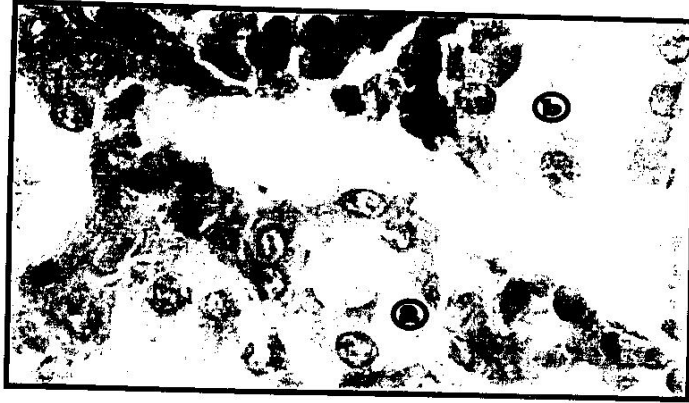

Fig. (3): T.S in Kidney of Mice infected with Cladosporium sp. showing: renal tubules necrosis (a); cell degeneration (b). H&E satin (396X)

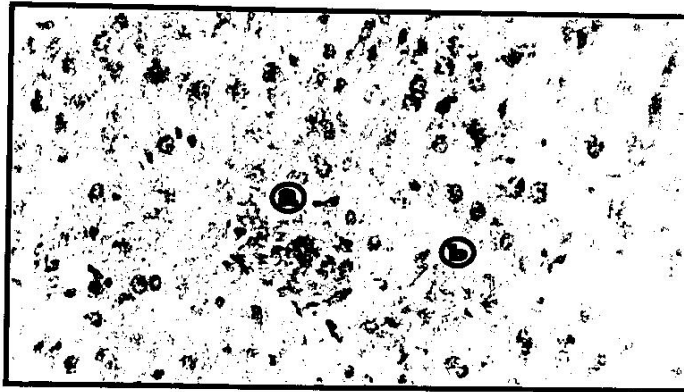


Fig. (4): T.S in liver of Mice infected with Cladosporium Sp. showing: Blood vessels congestion (a); bleeding (b). H&E satin (330X)




Fig. (5): T.S in Kidney of Mice infected with Cladosporium sp. showing: cell necrosis (a); granuloma (b) and blood coagulation (c). H&E satin (330X)

## دراسة نسيجية حول الاصابات الجهازية للفطر كلادوسبوريوم لبعض اعضاء الفئران المختبرية

عادل جبار حسين\* ياسل عبد الزهرة عباس\*\*

\*فرع التشريخ، كلية الطب البيطري، جامعة البصرة، البصرة، العراق.

\*\*فرع الاحياء المجهرية، كلية الطب البيطري، جامعة البصرة، البصرة، العراق.

### الخلاصة

تم استخدام الفئران المختبرية Balb/c لدراسة قابلية الفطر كلادوسبوريوم على احداث الاصابة الجهازية لبعض اعضاء الحيوانات المختبرية. حققت الحيوانات تحت الجلد بمعلق لابواغ الفطر، ثم عزل الكبد والكلى للحيوانات نسيجياً. اظهرت الدراسة بان الفطر كلادوسبوريوم لديه القدرة على اصابة هذه الاعضاء حيث شوهد وجود الخيوط الفطرية بين الالامجة اضافة الى احداث العديد من التغيرات النسيجية مثل تحلل الخلايا والتفخر واحتقان الاوعية الدموية والنزف.

### REFERENCES

1. Rippon, J.W., Larson, R.A., Rosenthal, D-M. and Clayman, J. (1988). Disseminated cutaneous and peritoneal hyalohyphomycosis caused by *Fusarium* species. Three cases and review of literature. *Mycopathol.* 101: 105-11.
2. Weinberger, M. and Elattor, I. (1999). Patterns of infection with patients with a plastic anemia and emergence of *Aspergillus* a major cause of death. *Medicine*, 71:24-34.
3. Nedz'ved', M.K., Fridman, M.V. (2001). *Cladosporiosis* in chronic herpetic encephalomyelitis. *Arkh Patol.* 63(1):38-40.
4. Romano, C, Bilenchi, R., Alessandrini, C. and Miracco, C. (1999). Case report. Cutaneous phaeohyphomycosis caused by *Cladosporium oxysporum*. *Mycoses*, 42(1-2):111-5.
5. Banerjee, T.K., Patwari, A.K., Dutta, R., Anand, V.K. and Chabra, A. (2002). *Cladosporium bantianum* meningitis in a neonate. *Indian J. Pediatr.* 69(8):721-3.
6. Moore J.E, Xu J, Millar, B.C, Elshibly, S. (2002). Edible dates (*Phoenix dactylifera*), a potential source of *Cladosporium cladosporioides* and *Sporobolomyces roseus*: implications for public health. *Mycopathologia*, 154(1):25-8.
7. Safdar, A., Singhal, S. and Mehta, J. (2004). Clinical significance of non-Candida fungal blood isolation in patients undergoing high-risk allogeneic hematopoietic stem cell transplantation (1993-2001). *Cancer*, (11): 2456 – 2461.
8. Drury, R.A.B. and Wallington, E.A. (1967). *Carlittons histological technique*. 4<sup>th</sup>. Ed. Oxford Univ. Press. New York. Toronto. p: 140.

9. Anderson, J.R. (1980). Muic's textbook of pathology, 11<sup>th</sup> ed. Edward Arnold, Norwich, U.K.
10. Richardson, M.D. (1998). *Aspergillus* and *Penicillium* species. Chapter 16. pp.281-312. In Medical mycology, Vol. 4. L. Ajello & R.J. Hay (eds.) Topley & Wilson's microbiology and microbial infection. 9<sup>th</sup> ed., Arnold, London, U.K.
١١. المنصوري؛ حنان عبدا لرضا (١٩٩٩). دراسة نسيجية للفئران المصابة بالفطر *Aspergillus fumigatus* المعزول من سائل الاكياس المائية للأبقار والأغنام. رسالة ماجستير؛ كلية العلوم؛ جامعة البصرة؛ (٨٢) صفحہ.