

STUDY THE EFFECTS OF DRENCHING OF ETHANOLIC EXTRACT OF *TARAXACUM OFFICINALE* LEAVES AND ATROVASTATIN ON SERUM ENZYMATIC ACTIVITY ;CHOLESTEROL LEVEL; REPRODUCTIVE EFFICIENCY AND ON THE STRUCTURAL CHARACTERISTICS OF PITUITARY-THYROID-OVARIAN-UTERINE AXIS OF LOCAL ADULT CHOLECYSTOCTOMISED FEMALE RABBITS

Abdul-Razzak N. Khudayer, Al-Saeed, M.H., Nawras A. Alwan
Hanan A. Salman

Department of physiology and pharmacology, College of Veterinary Medicine, University of Basrah, Iraq

(Received 24 May 2006, Accepted 18 July 2006)

Key words: Uterine, Enzymes, Extracts

ABSTRACT

This work had been done on twenty four healthy adult local female rabbits of mean body weight of 2 kgm and mean age of 5 months were randomly allocated into four groups of six animals each; all groups were fed during the period of experiment on a diet contained 0.5 % cholesterol and 14% coconut oil. The first group was regarded as control and received 3ml of physiological saline orally for a month. The second group was drenched ethanolic extract of *Taraxacum officinale* (500 mg/kg/day) for one month; the third group first subjected to cholecystectomy (removal of gall bladder) then drenched 500 mg/kg/day ethanolic extract of *T. officinale* for month also. The fourth group was treated with atrovastatin (0.4 mg/kg/day) for one month also. Those females were joined with males after treatment for a week to study the effect on fertility and reproductive capacity and on fetal growth. Blood samples were taken from all groups at the end of the treatment to know the effect on serum cholesterol and on enzymatic activity then after killing the animals the following organs were taken for histological study.

They are pituitary and thyroid glands; ovaries and uterin from each animal of each group. The following results were obtained:-

1. The ethanolic extract of *Taraxacum officinale* caused highly significant increase ($p < 0.01$) in SGOT.
2. Atrovastatin caused significant increase ($p < 0.05$) in SGOT.
3. Drenching *T. officinale* extract didnot cause any significant change in SGOT of cholecystoatomised female rabbits.
4. The ethanolic extract of *T. officinale* and atrovastatin had caused significant decrease ($p < 0.05$) of SGPT in intact female rabbits but caused highly significant decrease ($p < 0.01$) in SGPT of cholecystoatomised female rabbits.

5. The prolonged drenching of *T.officinale* had stopped fertility and had a contraceptive effect but atrovastatin had slightly decreases fertility rate.
6. The ethanolic extract had also significant decrease on reproductive organs weight but atrovastatin had not.
7. Prolonged drenching of *T.officinale* showed clear histological changes on all organs of the axis studied which were pituitary, thyroid, ovary and uterus of intact and cholecystomised female rabbits but atrovastatin had little histological changes as compared with control.

INTRODUCTION

Taraxacum officinale Liun belong to the family Asteraceae (compositae) (1). It has been used thousands of years ago as food preservatives, as well as a protective and curative remedy for numerous disorders (2). The herb is widely grown in different parts of the world such as Asia, Europe, America, Australia and New Zealand (3). Its common name is "Dandelion" or "lion's tooth" (4).

Phytochemical studies on *Taraxacum officinale* revealed the presence of resin, essential oil (1), pectose enzyme, fatty acids including melissic and β -hydroxyphenyl acetic acid; alkaloids; sitosterol; stigmasterol; saponin; taxasterol; homotaraxsterol; inulin; levulin; sugar and wax (5).

Dandelion leaves are high in vitamins A,B,C,D,Iron, silicon, zinc, manganese, magnesium, phosphorous, calcium and potassium (2).

In the traditional system of medicine, it is recommended in a wide range of ailments including infections (both fungal and bacterial) (6). In rheumatism (7). Gastro-intestinal problems like dyspepsia, flatulence, loss of appetite (8). It has also been used as diuretic stimulant. It was also used as laxative; antiarthritic; against eczema and in liver disorders (8). Dandelion's bitter compounds increase the gall bladder's production of bile. This improves the liver function and body's metabolism of fat. The popularity of the plant was highly enhanced by ideological belief in the herb as a cure for multiple diseases. In fact, this plant had occupied special place for its wide range of medicinal value in the Islamic civilization, due to the saying of the Holy prophet, Mohammed (peace be upon him) that the plant is full of medicinal values (9). It gained immense popularity.

Consequently, dandelion has been extensively studied particularly in the Islamic world, which justifies its broad traditional therapeutic values. It was found to have antimicrobial (6), hypoglycemic (10), antiinflammatory and renal productive properties (8).

Statins:-

Statin therapy had shown significant reduce of the risk of coronary heart disease in the populations with progressively lower degrees of overall risk (11). Statins interfere with the rate limiting steps in cholesterol biosynthesis and consistently reduced plasma low density lipoproteins (LDL) cholesterol (12) eg.: fluvastatin lovastatin and atorvastatin(13).

This study aimed to study the cholesterol inhibitory effect of *Taraxacum officinale* compared by adrug (atorvastatin) and also to find their effect on serum enzymes and to explore their effect on reproductive efficiency and on structural characteristics of pituitary-thyroid-ovarian-uterine axis of cholecystotomized adult local female rabbit compared with intact adult female rabbits.

MATERIALS AND METHOD

Preparation of ethanolic herbal extract: The ethanolic extract of *Taraxacum officinale* leaves was prepared taking 50 g of dried leaves which were obtained from local garden at Basrah, powdered and combined with 500 ml of ethanol, this combination was concentrated below 50 °C under reduced pressure in arotavapour to get the ethanolic extract (14).

Experimental animals:

Twenty four healthy adult local female rabbits of mean body weight of 2 kg and mean age of 5 months were housed in an individual cages in a room with constant humidity and temperature about (22±2°C) under 12 hourse light to dark cycle and fed for one week on standard diet and tap water *ad libitum*. All animals received human care according to criteria found in "Guide for care and use of laboratory animals". After one week the animals were randomly divided into four groups , six animals for each group. All animal groups were fed the same diet supplemented by 100 gm of diet for each animal for a month contained 0.5% cholesterol and 14% coconut oil after that the animals given the treatments either *Taraxacum officinale* extract or atorvastatin according to its group.

The first group was regarded as control which were received 3ml of physiological saline orally for each animal by gastric tube daily for one month. The second group was drenched ethanolic extract of *Taraxacum officinale* leaves (500mg /kg/day) for one month dissolved in 3ml of physiological saline. The third group first subjected to cholecystectomy (removal of gall bladder) then after healing from the surgery animals of this group also drenched 500mg/kg/day of ethanolic extract of *Taraxacum officinale* daily for one month dissolved in 3ml of physiological saline. The fourth group was treated with atorvastatin (0.4 mg/kg/day) for each animal dissolved in 3ml of physiological saline for one month also.

For fertility activity female rabbits caged for 7 days with males of proven fertility in a percentage of 2:1. their vaginal smears were examined each morning of the period of joining and day of presence of spermatozoa was regarded as day 1 of pregnancy as described by (14). Mated female rabbits were randomly distributed into various groups and treated orally with the tested extract for 30 days post coitus.

Effect on foetal growth:In this part of the experiment the mated females which regarded as pregants were treated by the extract and atrovastatin along the thirty days of pregnancy and after delivery each foetus was examined for any external abnormalities; they were also weighted individually.

Effect on serum cholesterol and enzymatic activity:-

At the end of the treatment of all groups; blood samples for plasma cholesterol and enzymatic activity such as GOT and GPT determination. Those blood samples were collected after twelve hourse fasting by heating puncture by steralized syringes with needles and collected in centrifuge tubes to get the serum needed for analysis.

After that female animals of each treated group and controls were killed by slautering and organs of the study were selected and isolated to get their weights after that they kept in 70% formaline for fixation to be ready for histological studies and examination and their results were compared with those of the control group. The organs subjected to histological technique in this study were pituitary glands; thyroid glands; ovaries and uterine. After dehydration the samples were cut by arotary microtome and stained with hematoxylin and eosin for microscopic examination.

Statistical analysis:

Obtained data were presented as means \pm S.D and the original data were analysed by one way analysis of varians ((ANOVA)) test.

Cholecystectomy: Preparation of animals to the operation include clipping and shaving of thje abdominal region, then followed by intramuscular injection of 10mg/kg body weight acepromazin maleate to sedate the animal. Then the animal was anaesthetized by intramuscular injection of ketamine hydrochloride (10mg/kg. B.w.) and zylazine (5mg/kg B.w.). The animal interred into surgical anaesthesia for 30-45 minutes (Markus, 1988).

The anaesthetized animals were lied and casted on its back. An incision was made in linea alba. After that gall bladder has been exposed, the peritoneum was splited and the gall bladder is freed by blunt dissection. Two forceps were applied to the duct of the gall bladder, the pedicle is served between them. Aligature was placed arround the duct beneath

the first forceps and a second ligature was done in front of the second forceps. Haemorrhage from exposed liver surface can be controlled by pressure with gauze sponge (Archibald, 1974).

RESULTS

A. Effect on serum enzymatic activity and cholesterol:

The influence of prolonged oral administration of ethanolic extract of *Taraxacum officinale* and atorvastatin on the enzymatic activity and cholesterol level are demonstrated in table (1). The results showed that the ethanolic extract of the plant used caused highly significant increase ($p < 0.01$) in serum glutamic oxaloacetic transaminase (SGOT) and also atorvastatin did not alter the activity of (SGOT) and caused significant increase of this enzyme but at 0.05 level ($p < 0.05$) but drenching the extract did not cause any significant change of this enzyme in cholecystotomised rabbits.

Exactly contrary effect of the extract on transaminase (SGPT) when the ethanolic extract caused significant decrease ($p < 0.05$) of the (SGPT) enzyme in the intact rabbit and caused highly significant decrease ($p < 0.01$) in cholecystotomised rabbit. Also atorvastatin had caused the same significant decrease in the enzyme level of intact rabbits. Also results in table (1) showed that drenching ethanolic extract of *Taraxacum officinale* caused highly significant decrease in cholesterol level of intact rabbits ($p < 0.01$) more than the decrease occurred in cholecystotomised rabbits. But atorvastatin caused no significant decrease in cholesterol level of intact rabbits.

Table 1: Effect of prolonged oral administration (30 days) of ethanolic extract and atorvastatin on some enzymatic activity and cholesterol in intact and cholecystotomised rabbits.

Treatment groups	SGOT	SGPT	cholesterol
Control (normal saline) to intact animals	12±5.62	18.16±3.67	384±0.81
500 mg/kg/day of <i>Taraxacum officinale</i> to intact animals	51.33±14.44**	15.33±3.40 *	199.9±0.69**
0.4 mg/kg/day atorvastatin to intact animals	16.66±6.88*	9.10±3.57**	358.51±3.88
500 mg/kg/day of ethanolic extract of <i>T. officinale</i> to cholecystotomized animals	12.33±3.81	9.33±3.32**	300±3.60*

B-Effect of prolong drenching of ethanolic extract of *Taraxacum officiale* on reproductive efficiency of female rabbits.

The influence of prolong oral administration of ethanolic extract of *Taraxacum officiale* and atrovastatin on reproductive efficiency are demonstrated in table (2) results showed that groups drenching *Taraxacum officiale* ethanolic extract of both normal and cholecystectomised female rabbits there was inhibition in their reproductive efficiency when showed (0%) fertility rate of both groups while fertility rate was (83.3%) in group treated with atrovastatin. Also there was no effect neither on gestation period nor on the fetal growth and formation.

Table 2: Effect of prolonged oral administration (30 days) of ethanolic extract and atrovastatin on some reproductive parameters

Treatment groups	No. of new borns	Weight of new borns	Mal formation	Mortality rate	No. of pregnant females	Fertility rate
Control (normal saline) to intact animals	4.33 ± 0.5	23.83 ± 1.16	0	0	6	10%
500 mg/kg/day of <i>Taraxacum officiale</i> to intact animals	0	0	0	0	0	0%
0.4 mg/kg/day atrovastatin to intact animals	3.16 ± 0.75	22.71	0	0	5	83.3%
500 mg/kg/day of ethanolic extract of <i>T. officinale</i> to cholecystectomized animals	0	0	0	0	0	0%

c- Effect on weights of ovaries and uterine of treated female rabbits.

The influence of prolonged oral administration of ethanolic extract of *Taraxacum officinale* and atrovastatin on weights of ovaries and uterine are demonstrated in table (3).

The results showed that the ethanolic extract had high significant decrease ($p < 0.01$) on weights of ovaries and uterine of normal and cholecystectomised rabbits in table (3). But atrovastatin had no such significant decrease on weights of both ovaries and uterine of intact female rabbits.

Table3: Effect of prolonged oral administration (30 days) of ethanolic extract of *Taraxacum officinale* and atrovastatin on ovaries and uterine weights of intact and cholecystoatomised female rabbits.

Treatment groups	Weight of left ovary (gm)	Weight of right ovary (gm)	Weight of uterus (gm)
Control (normal saline) to intact animals	0.095 ± 0.005	0.11 ± 0.02	6.50 ± 0.60
500 mg/kg/day of <i>Taraxacum officinale</i> to intact animals	0.070** ± 0.005	0.075** ± 0.008	1.46** ± 0.11
0.4 mg/kg/day atrovastatin to intact animals	0.085 ± 0.005	0.070** ± 0.005	0
500 mg/kg/day of ethanolic extract of <i>T. officinale</i> to cholecystoatomized animals	0	0	0

** = (p<0.01)

D- Histological changes produced by treatmental doses of *Taraxacum officinale* ethanolic extract and atrovastatin:

1. **Effect on pituitary gland:** Figure (1) showed normal tissue of pituitary gland of control group represented by numerous sinusoidal capillaries which are seen in pars anterior as well as normal groups of chromophobe cells and normal capsule. There are predominance of acidophilic and basophilic cells; nearly the same structures found in group treated with atrovastatin figure (3), but groups received the extract of *Taraxacum officinale* either intact (figure 2) or cholecystoatomised (figure 4) showed several histological changes such as decreased number of chromophobs with less number of sinusoidal capillaries in addition to presence of empty spaces between the tissue structures; those changes may lead to pituitary insufficiency caused by hypopituitarism.

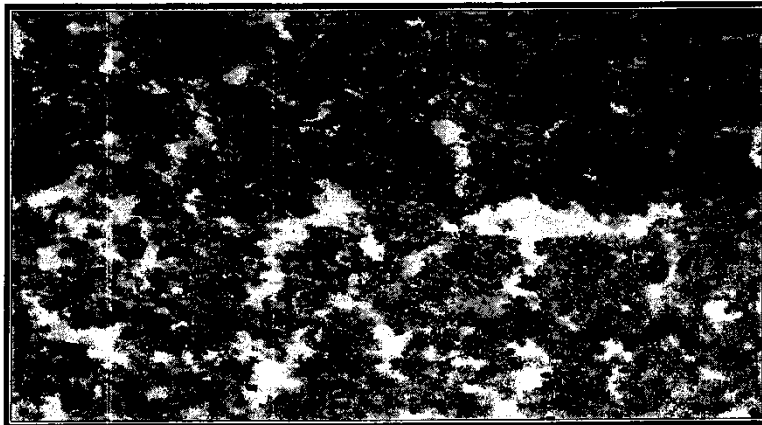

Fig 1: Section of pituitary gland of control group (normal tissue) (40X) H& E. stain.




Fig 2: Section of pituitary gland of group drenched ethanolic extract of *T. officinale* for 30 days (there are 1- decreased number of chromophobes 2- less number of sinusoidal capillaries 3- presence of empty spaces between tissue structures. (40X) H& E stain.



Figure3 : Section of pituitary gland of group treated with atrovastatin for 30 days the structures resembles that of control group.




Figure 4: Section of pituitary gland from cholecystectomised group treated with *T. officinalis* for 30 days shows the following changes:

- 1-decreased number of chromophobs
- 2-less number of sinusoidal capillaries
- 3-presence of empty spaces between tissue structures (40X) H& E stain

2-Effect on thyroid gland:

Figure (5) showed a section of thyroid gland of the control group which showed a large number with simple columnar or cuboidal epithelium. These follicles are filled with colloid which takes the acidophilic stain.

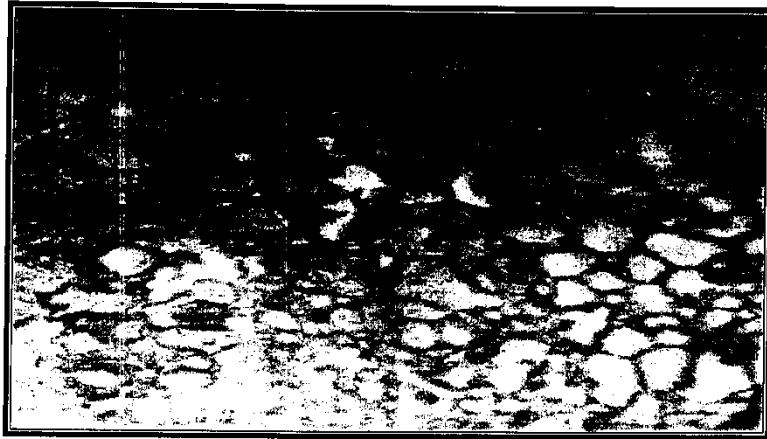

Figure 5: Section of the thyroid gland of the control group showing: Large number of the thyroid follicles (40X) H&E stain.

But in groups received *T. officinale* ethanolic extract for 30 days either intact animals or cholecystotomised we show absence of normal follicular architecture with no clear follicular lumen and presence of fibrous tissue in between the damaged follicles.



Figure 6: Section of the thyroid gland of the group drunched *T. officinale* (40X) H&E stain.




Figure 7: Section of thyroid from cholecystectomised group drenched 500 mg/kg/day *T. officinale* for 30 days shows 1- presence of little number of follicles not clearly filled with colloid of acidophilic stain 2- presence of fibrous tissue. (40X) H&E stain.




Figure 8: Section of thyroid gland of intact animal group treated with 0.4 mg/kg/day atorvastatin for 30 days shows: 1- different sizes of thyroid follicles 2-clear interfollicular septa 3-presence of fibrous tissue. (40X) H&E stain.

3- Effect on the ovary:

The histological section of the control group showed in figure (9). It shows a normal surface or germinal epithelium covering the surface; there is a thin zone of collagenous connective tissue. There are numerous follicles of various stages of development are

embedded in the stroma of the cortex; the most numerous are the primary follicles found in the peripheral zone of the cortex just under the tunica albuginea, the largest of the follicles is almost the mature one.



Figure 9: section of ovary of a control group. (40X) H&E stain.

Figure (10) shows a section of ovary from group treated with 500mg/kg/day of *Taraxacum officinale* ethanolic extract, this section shows thickening of surface epithelium (germinal epithelium) and adestruction in tunica albuginea, there are no primary follicles and there are many secondary follicles undergoing degeneration also there is destruction and disturbances in ovarian stroma. There is no thecalutin tissue.




Figure 10: section of ovary of group treated with *T. officinale* extract. (40X) H&E stain.

Section of cholecystotomised group given *T. officinale* extract showed in figure (11). It is clear that there is necrosis in many areas of the ovary and there is atresia of ovarian follicle.




Figure 11: section of ovary of cholecystotomised group treated with *T. officinale* extract. (40X) H&E stain.

The intact group received atrovastatin drug showed increased number of primary as seen in the section of figure (12).



Figure 12: section of ovary of intact group treated with atrovastatin (40X) H&E stain.

4- Effect on the uterus:

Figure (13) shows the normal structure of the uterus of the control group, revealed normal uterine layers and mucosa as well as normal muscular fibers in addition to the normal uterine glands in the superficial portion of the endometrium.



Figure 13: section of normal uterus from the control group.

While figure (14) shows a hypoplasia of the muscular layer as compared with the above control group, as well as there is atrophy of uterine glands.



Figure 14: section of uterus of group drenched *T. officinal*

While changes in figure (15) of uterus of cholecystotomised female rabbits treated with 500 mg/kg/day of *T. officinal* showed some destructive changes in the muscular

layers of the uterus more than that found in intact females drenched the extract as well as disappearance of uterine glands.



Figure 15: shows a section of uterus of cholecystotomised group drenched *T. officinal* extract.

Changes in uterine structure of group treated with atrovastatin are shown in figure (16) when we notice a disturbance in the columnar epithelium of the endometrium; disturbance of muscular fibers of lamina properia increased number of fibroblast and fibrous tissue instade of interglandular lamina properia also absence of uterine glands is abundant.



Figure 16: section of intact female rabbit of group treated with atrovastatin.

DISCUSSION

Enzymatic activity and cholesterol:

The obtained results denoted that ethanolic extract of studied plant and atrovastatin significantly increased activity ($p<0.01$) of serum glutamic-oxaloacetic transaminase (SGOT) and significantly decreased activity ($p<0.01$) of glutamic- pyruvic transaminase (SGPT) of intact female rabbits but the ethanolic extract of *T. officinal* didnot increased (SGOT) but significantly decreased (SGPT) of cholecystoctomised female rabbits; these effects may be attributed to the influence of the extract and drug on the liver and heart. These effects on enzymatic activity may be related to the alkaloid and saponin containt of the used plant (*T. officinal*) which may affect liver and heart, so they may caused the changes in the enzymatic activity found in this study. These results are in agreement with findings of (15) when found that thymus capitatus affect the enzymatic activity due to their containt of alkaloids and saponin. In the respect of ethanolic extract of *T. officinal* reduction of plasma cholesterol level no reports or scientific articles mentioned such effects on cholesterol or lipid metabolism. This effect may be attributed to the chemical componants of the studied plant which may conjugated with bile acids in the intestine which can inhibit the action of bile acids with fat containt of the food leading to increase the excretion of those bile acids with west products and thus stimulated the conversion of cholesterol to bile acids in the liver; these findings is generally agreed with previous studies on another plants such as (*Allium sativum*) (16,17 and 18). Those authors had suggested the inhibitory effects of garlic on plasma total cholesterol which may be due to an inhibitory effect of this plant on cholesterol synthesis Van Dam *et al.* (2002) mentioned that atrovastatin inhibit the rate-limiting step of cholesterol synthesis which create atranisent decrease in intracellular cholesterol and increase the synthesis of cell surface LDL receptors. Atrovastatin affect the 3-hydroxy-3-methyl glutaryl-COA (HMG-COA) reductase inhibitor and it is very effective as monotherapy in lowering cholesterol (19).

Effect on fertility and reproductive efficiency:

The obtained results denoted that ethanolic extract of *T. officinal* to cholecystoctomised female rabbits lead to loss their fertility due to their effects on pituitary gland and thyroid glands which reflects the effects on ovaries and uteri of treated female rabbits because all these organs are in the same axis. Those results were observed through gross and micro scopic (histopathological lesions and changes) in the organs of the studied axis which clearly noticed in figures 1-16; those results and changes certainly leads to disturbances in gonadotropins from pituitary (LH and FSH) which in turn lead to disturb hormones of estrogen and progesterone secreted from affected ovaries resulting in clear changes in the

uterus shown in figures illustrated in the results; those changes resulted in a 100% loss of fertility of those treated females compared with the controls. Several authors mentioned that athanolic extract of *T. officinal* contain phenoles; alkaloids and saponin and those contain may affect the reproductive efficiency. These results are in agreement with that of (20) when found that phenole compound in gossypol acetic acid had number of effects on reproductive physiology of mammals and affecting fertility and sterility of both male and female due to exerting toxic effects on early formed embryos as well as its spermicidal effects. These results are agreed with those found by (21) that alkaloids had a contraceptive effects in females and causes abortion and toxicity to embryos.

دراسة تأثير تجريع الخلاصة الكحولية لأوراق نبات الهندباء البرية و عقار الانورفاستاتين على نشاط أنزيمات وكولسترول مصل الدم والكفاءة التناسلية وعلى الصفة التركيبية لمحور النخامية. الدرقية. المبيض ورحم إناث الأرانب البالغة المزالة المرارة

عبدلرزاق نعيم خضير منى حميد محمود نورس عبدالاله علوان حنان علي سلمان
فرع الفسلجة ، كلية الطب البيطري ، جامعة البصرة، البصرة ، جمهورية العراق.

الخلاصة

تم إجراء هذه الدراسة على أربع وعشرين أنثى أرنب محلية بالغة سليمة بدنياً بمعدل وزن ٢ كغم لكل منها ومعدل عمر خمسة أشهر، وزعت عشوائياً إلى أربعة مجموعات كل مجموعة احتوت على ستة إناث. غذيت جميع المجموعات طيلة فترة التجربة على علفه احتوت على ٠,٥ % كولسترول و ١٤% زيت جوز الهند. اعتبرت المجموعة الأولى كمجموعة سيطرة أو مقارنة وجرعت ٣ مللترات من المحلول الملحي الطبيعي لمدة شهر وجرعت المجموعة الثانية الخلاصة الكحولية لأوراق نبات الهندباء البرية بواقع ٥٠٠ ملغم/كغم/باليوم لمدة شهر كامل أما المجموعة الثالثة فقد أزيلت المرارة من جميع حيواناتها بعملية جراحية وبعد شفاؤها تم تجريعها ٥٠٠ ملغم/كغم/يوم من الخلاصة الكحولية لأوراق الهندباء البرية لمدة شهر أيضاً. أما المجموعة الرابعة فجرعت ٠,٤ ملغم/كغم/يوم من عقار الانورفاستاتين لمدة شهر أيضاً. وضعت جميع إناث التجربة في الأسبوع الأخير منها مع ذكور خصبة لغرض دراسة تأثير المعاملات المختلفة على الخصوبة والكفاءة التناسلية لإناث أرانب التجربة وكذلك تأثيرها على نمو الأجنة. أخذت نماذج دم من جميع إناث التجربة في نهاية فترة التجريع لمعرفة التأثيرات على مستوى كولسترول مصل الدم ونشاط أنزيمات المصل ثم بعد قتل الحيوانات تم اخذ الأعضاء التالية لغرض

- اجراء الدراسة النسيجية للصفة التركيبية لها وهي الغدة النخامية-الغدة الدرقية- المبيض والرحم من جميع حيوانات التجربة.
- وقد تم الحصول على النتائج التالية:
1. ان الخلاصة الكحولية لاوراق نبات الهندباء البرية كان لها تأثير عالي المعنوية ($p < 0.01$) في زيادة انزيم SGOT .
 2. اثر إعطاء عقار الاتروفاستاتين على زيادة انزيم SGOT بصورة معنوية ($p < 0.01$).
 3. ان تجريع الخلاصة الايثانولية لاوراق نبات الهندباء البرية لم تسبب أي تغير معنوي بانزيم SGOT في اناث الارانب المزالة المرارة.
 4. ان تجريع الخلاصة الايثانولية لاوراق نبات الهندباء البرية وكذلك عقار الاتروفاستاتين قد سببا نقصاً معنوياً ($p < 0.05$) لانزيم SGPT في الحيوانات الغير مزالة المرارة لكنهما سببا نقصاً عالي المعنوية ($p < 0.01$) في انزيم SGPT لاناث الارانب المزالة المرارة.
 5. ان التجريع الطويل الامد للمستخلص الايثانولي لاوراق نبات الهندباء البرية قد ادى الى توقف خصوبة اناث الارانب وكان تأثيره كمانع للحمل. ولكن تجريع عقار الاتروفاستاتين كان له تاثير مخفض نسبياً لمعدل الخصوبة.
 6. لقد سبب تجريع المستخلص الايثانولي لاوراق نبات الهندباء البرية نقصاً معنوياً في اوزان اجهزة تكاثر اناث الارانب بينما تجريع عقار الاتروفاستاتين لم يسبب ذلك.
 7. ان التجريع الطويل الامد للمستخلص الايثانولي لاوراق نبات الهندباء البرية لاناث الارانب قد سبب تغيرات واضحة في التراكيب النسيجية لجميع الاعضاء المدروسة وهي محور النخامية-الدرقية- المبيض والرحم للاناث السليمة والمزالة المرارة على حد سواء ولكن تجريع الاتروفاستاتين كان له تاثير قليل على الصفة التركيبية النسيجية للاعضاء المدروسة مقارنة باعضاء السيطرة.

REFERENCES

- 1- Simon, J.E.(1990). Essential oil and culinary herbs. P.P: 472-483. In: Janick, J. And Simon, J.E. (1993).(eds). New crops. John Wiley & Sons, Inc.
- 2- Akeel, M. (1996). Teb Al-emam Ali. 1st edition, Dar Al-Mahaga "El-bedaa" for press, Burit, Lebanon, P.P:100-105. (in Arabic).
- 3- Al-Rawi, A. and Chakravarty, H.L.(1964). Medicinal plants of Iraq. Ministry of Agriculture, Baghdad, Iraq.

- 4- Saad, S.I. (1975). Classification of flowering plants. 2nd edition. The General Egyptian Book Co. Alexandria.
- 5- Nassimy, M.N. (1984). The prophetic Medicine " Al Teb Al-Nabawy and moder medicine, vol. III, 1st edition. The United Comp. For dist. Damascus, Syria.
- 6- Cowan, M.M. (1999). Plant products as antimicrobial agents. Clinical Microbiology Reviews, P.P:564-582.
- 7- Rawaiha, A. (1978). Herbs therapy. 5th ed., Dar Al-Kalam for press, Burit, Lebanon. (in Arabic).
- 8- Al- Maiyah, A.A. (2001). Moder plant taxanomy. 1st ed. Central for press, University of Basrah-University of Taz. (in Arabic).
- 9- Al-Bukhari, A. (1976). " Collection of authentic prophetic saying, Division 71 (the book of Medicine). Chapter 7" published by Hill Yayinlari, Ankara, Turkey, 2nd edition.
- 10- Brinker, F. (1998). Herb contraindications and drug interaction. . 2nd sandy, OR: Eclectic Institute Inc.
- 11- Plutzky, J. And Ridker, P.M. (2001). Statin of stroke circulation. 103: 348-350.
- 12- Davignon, J.; Montigny, M. And Dufour, R. (1992). HMG-CoA reductase inhibitors: a look back and a look a head.
- 13- Stone, N.J. (1996). Lipid management: Current diet and drug treatment. Am.J. Med., 101: 40S-48S.
- 14- Harborne, J.B. (1984). Phytochemical methods. Chapman and Hall, London, O.K., P.P.:566-568.
- 15- Kandil, O.; Radwan, N.M.; Hassan, A.B.; El-Banna, H.A. and AZIZA, N.M. (1993). Toxicity of some plants. Vet.Med.J. Giza, vol. 14, No.2:9-14.
- 16- Gebhart, R. (1993). Multiple inhibitory effect of garlic biosynthesis in hepatocytes. Lipids, 28:613-619.
- 17- Al-kakey, I.S. (1999). Effect of some hypoglycemic plants on lipid peroxidation, glutathione content and certain biochemical aspect in normal and alloxan diabetic male rabbits. Ph.D. Thesis. College of Science. University of Mousl.
- 18- Yeh, Y.Y. and Liu, L. (2001). Cholesterol- lowering effect of garlic extracts and organosulfur compounds: Human and animal studies. J.Nutr., 131:989S-993S.
- 19- Van Dam, M.; Zwart, M.; Beer, F.; Smelt, A.H.M.; Prins, M.H.; Trip, M.D.; Havekes, L.M.; Lansberg, P.J. and Kastelein, J.J.P. (2002). Longterm efficacy and safety of atrovastatin in the treatment of sever type III and combined dyslipidemia. Heart, 8:234-238.

- 20- Montomat, L.A.; Fag, C.A. and Petra, O.M. (1982). Effect of cotton extract on sperm morphology. *Andrologia*, 52:101-105.