

## Co-Expression of Intestinal Lymphocyte Subpopulations in Ulcerative Colitis: An Analysis by Dual-Immunofluorescence Technique

Haider F. Ghazi

*Department of Microbiology /College of Medicine / Al-Nahrain University*

### Abstract

**Background:** Fluoresceins labelled monoclonal antibodies against cell surface antigens are able directly to examine the expression of multiple antigens on the surface of lymphoid cells in Ulcerative colitis lesions.

**Materials and methods:** Using dual-immunofluorescence for investigated the coexpression of (CD3-CD19 and CD4-CD8) antigens on infiltrated lymphocytes of 47 patients with ulcerative colitis and 10 subjects from control group. Total and differential T cells as well as plasma cell counts were recorded in all tissue samples. Non parametric Kruskal-Wallis test was used to compare the median cell counts among different study groups.

**Results:** T lymphocyte, T-cell subtype and plasma cell in UC were high with highly statistical significant difference when compared with those in normal control subjects T cell UC (301.39) Controls (35.48), T-helper 2 UC (228.41) Controls (24.75), T-helper 1 UC (54.21) Controls (13.45) and plasma cell UC (45.46) Controls (12.94). Recorded values of were different and increased according to modified Geboes histological grades of disease activity T lymphocytes ( $r=0.944$ ) followed by T helper 2 subtype ( $r=0.821$ ), T helper 1 ( $r=0.653$ ) and B lymphocyte ( $r=0.237$ ).

**Conclusions:** The increased number of lymphocyte subsets was found in the UC lesions and correlated with different histological grades of disease activity.

**Key words:** Ulcerative colitis, disease activity and lymphocytes.

### الخلاصة

**الخلفية:** الفلورسئين المرتبط بالأجسام المضادة أحادية سلاطة ضدَّ مُسْتَضَدَّاتِ الخلية السطحيّة قادرة مباشرة لفحص تعبير المُسْتَضَدَّاتِ المتعدّدة على سطح الخلايا للمفاوية في آفات التهاب القولون التقرحيّة. **المواد وطرق العمل:** استخدم التصبيغ المناعي الانزيمي المتألق الثنائي للتصنيف المظهري للخلايا اللمفية المخترقه (CD3- CD19) و (CD4-CD8) في 47 مريض مصاب بالتهاب القولون التقرحي و 10 اشخاص من مجموعة السيطرة. العد الكلي والتفريقي للخلايا التائية ومعها خلايا البلازما قد ثبت لكل العينات النسيجية. الاختبار الغير رقمي Kruskal-Wallis قد استخدم لمقارنه الوسيط الرقمي للنتائج بين مجاميع الدراسة المختلفة.

**النتائج:** الخلايا اللمفية التائية، انواع الخلايا التائية وخلايا البلازما في التهاب القولون التقرحي كانت عالية وبفرق احصائي عالي عندما قورنت بأولئك في مجموعة السيطرة الطبيعية تي خلية المرضى (301.39) سيطرة (35.48)، الخلايا المساعد 2 المرضى (228.41) سيطرة (24.75)، تي مساعد 1 المرضى (54.21) سيطرة (13.45) و خلية بلازما المرضى (45.46) سيطرة (12.94). القيم المسجلة كانت مختلفة ومتزايدة طبقاً للدرجات المُعدّلة Geboes histological لنشاط المرض الخلايا اللمفية التائية ( $r=0.944$ ) تلت من قبل الخلايا لاتائية المساعدة من النوع الثاني ( $r=0.821$ )، الخلايا التائية من النوع الاول ( $r=0.653$ ) و خلايا البلازما اللمفية ( $r=0.237$ ).

**الاستنتاجات:** العدد المتزايد لأنواع الخلايا اللمفية الفرعية وجد في افات التهاب القولون التقرحي وربط بالدرجات الباثولوجية المختلفة من نشاط مرض. **كلمات مفتاحية:** التهاب القولون التقرحي، فعالية المرض و خلايا لمفية.

## Introduction

Ulcerative colitis (UC) is an inflammatory disease of the rectal and colonic mucosa and seems to result from a complex series of interactions between susceptibility genes, the environment and the immune system<sup>(1, 2)</sup>. The total numbers of infiltrating subpopulations of lymphocytes are increased, not normally present in the lamina propria of the intestine<sup>(3,4)</sup> indicating ongoing recruitment to the inflamed bowel, bearing in mind their function, lymphocytes may contribute to intestinal damage<sup>(5)</sup>. It appears as though the T-cell response to the antigens is not T-helper (Th) 1 dominant as in the case of Crohn's disease but rather is either Th2 [interleukin (IL)-4, IL-13] or is mediated by specialized cells such as natural killer (NK) T cells (IL-13). Lamina propria T cells from ulcerative colitis patients produce significantly greater amounts of IL-13<sup>(6)</sup>.

The histological examination of routinely processed colonic sections indicates alterations in intensity and composition of the lamina propria infiltrate, which allow a distinction among different disease activity patterns. Over the years, several microscopic scores for the assessment of disease activity in UC have been developed, generally for study purposes<sup>(7,8)</sup>, it could be used to document disease evolution, or to assess clinical efficacy in therapeutic trials and prediction of relapse<sup>(9, 10)</sup>.

So, by application of our simple basic immunological knowledge through examination of lymphocyte subpopulations in tissue biopsies by a sensitive and specific assay (dual immunofluorescence cellular staining)

could open a way toward proper assessment of in the degree of bowel inflammation. This study was designed to determine the significance and prognostic value of various infiltrating lymphocytes in ulcerative colitis.

## Materials and Methods

### Samples

Forty seven archived paraffin-embedded blocks of UC patients samples diagnosed at the Gastro Intestinal Tract and Liver Disease Hospital-Baghdad to have ulcerative colitis were included in this study. Patient's characteristics are presented in Table 1.

Haematoxylin and Eosin stained sections were examined by the same senior pathologist to confirm the diagnosis and assign the grade of activity of inflammation based on simplification of the activity scale proposed by Geboes et al., 2000 as follows:

### *Immunoreagents and immunocyto-chemical procedures*

Thin paraffin-embedded sections (4 µm thick) of UC and resection margin tissue section were mounted on poly-L-lysine-coated (positively charged) slides for the immunocytological characterization in these tissue sections.

Lymphocyte subpopulations were identified by two sets of dual staining monoclonal antibodies labeled with FITC and RPE as ordered as (anti-CD3, anti-CD19 and anti-CD4, anti-CD8) respectively.

### *Direct dual – Immunofluorescence procedure:*

1. Dewaxing and rehydration: paraffin embedded sections were placed

inside a hot air oven at 65°C overnight, then dipped in xylene and ethanol containing jars in the following order:

- a. Xylene for 5 minutes.
- b. Fresh xylene for 5 minutes.
- c. Absolute ethanol for 5 minutes.
- d. Ethanol (95%) for 5 minutes.
- e. Ethanol (70%) for 5 minutes.
- f. Ethanol (50%) for 5 minutes.
- g. Distilled water for 5 minutes.
2. For blocking the non-specific binding sites, 100 µl of a protein-blocking reagent was placed onto the section and incubated for 10 minutes in a humid chamber at room temperature. Then slides were drained and blotted gently.
3. 50 µl of diluted primary antibody was placed onto the section and incubated for 1 hour at 37°C in a humid chamber. After incubation, the slides were drained and blotted gently.
4. Slides were dehydrated by dipping in ascending concentration of ethanol and xylene containing jars in the following order:
  - h. Ethanol (50%) for 5 minutes.
  - i. Ethanol (70%) for 5 minutes.
  - j. Ethanol (95%) for 5 minutes.
  - k. Absolute ethanol for 5 minutes.
  - l. Fresh xylene for 5 minutes.
5. A drop of mounting medium (DPX) was placed onto the xylene-wet section then quickly covered with a cover slip.

6. Slides were examined under fluorescent microscope at X400 magnification.

#### Statistical analysis:

Data were recorded as median values and non parametric Kruskal-Wallis test for one way ANOVA was used to compare the median cell counts among different study groups and p-value <0.05 was considered significant.

## Results

All cases were investigated for determining CD3/CD19 and CD4/CD8 expression based on dual immunofluorescence staining technique and recorded as total number of T CD3+, T-helper 1 cells (CD8+), T-helper 2 cells (CD4+) and plasma cells (CD19).

In table 1, the result showed that the mucosa in UC colon tissue was characterized by a 8.5 fold increase in lymphocytes compared with normal colon. For all lymphocytic infiltrates there were highly statistical significant difference between UC patients and control T cell (CD3+)UC (301.39) Controls (35.48), T-helper 2 (CD4+) UC (228.41) Controls (24.75), T-helper 1 (CD8+)UC (54.21) Controls (13.45) and plasma cell (CD19+) UC (45.46) Controls (12.94), reflecting the inflammatory status of colonic mucosa (figure 1).

Table 1. Result of comparison for total T cells and different subsets of T cells between UC lesions and control.

	T cell (CD3 <sup>+</sup> )	B cell (CD19 <sup>+</sup> )	T-helper 2 (CD4 <sup>+</sup> )	T-helper 1 (CD <sup>+</sup> )
UC (47)	301.39 (86.39%)	45.46 (13.11%)	228.41 (75.79%)	54.21 (17.99%)
Controls (10)	35.48 (73.28%)	12.94 (26.72%)	24.75 (69.76%)	13.45 (37.91%)
UC : Controls	8.5:1	3.5:1	9.23:1	4.03:1
UC versus	≤0.001**	≤0.001**	≤0.001**	≤0.003*

\* = statistical significant difference.

\*\* = highly statistical significant difference.

According to histological grading, our records were classified and compared in Table-2. The results showed that there were highly statistical significant differences for all cell types reflecting the constituents of inflammatory cells in the colonic mucosa in relation to the grade of disease activity. This inclination was further explained in figure 2 and correlation coefficient between lymphocyte subsets and histological grade shown in the legend of figure 1. The highest association found with T lymphocytes ( $r=0.944$ ) followed by T helper 2 subtype ( $r=0.821$ ), T helper 1 ( $r=0.653$ ) and B lymphocyte ( $r=0.237$ ).

## Discussion

The immunophenotyping of cellular subsets seen in Ulcerative colitis tissue biopsies forms the basis of understanding the cellular immune response in various disease activity patterns. In UC disease there is infiltration of the mucosa with lymphocytes, both T cells and B cells<sup>(11, 12)</sup>.

As shown in this study, however, the proportions of T lymphocyte subsets, as defined by monoclonal antibodies, do not differ, either in the epithelium or in the lamina propria, from those seen in normal colonic mucosa. This is true both in ulcerative colitis and in Crohn's disease, regardless of disease activity or mode of treatment. These mucosal populations are also similar to those seen in normal small intestine this findings indicate that the pathogenesis of inflammatory bowel disease does not depend upon an imbalance of the immunoregulatory T cells defined by the monoclonal antibodies used in this study. They also suggest that the

reduction in the number of circulating T lymphocytes seen in patients with inflammatory bowel disease, without alteration in the proportions of T cell subset<sup>(13)</sup> may well be because of sequestration into involved mucosa. This emphasises the need to study events in the mucosa rather than those in the peripheral blood.

The total number of cells of the inflammatory infiltrate was more than the total number of cells that were stained with dual monoclonal antibodies (immunofluorescence). This indicates that there may be other cells that form part of a chronic inflammatory infiltrate including the fibroblasts, histiocytes, macrophages and dendritic cells<sup>(14)</sup>. The inflammatory cellular infiltrate in active lesions contained a large number of CD3 + cells but a low CD4+ and CD8+ cell count. By comparing the immunophenotype of different disease activity lesions of UC, we were mostly able to confirm the previous reports of other researchers that the bulk of the inflammatory infiltrate is made up of T cells<sup>(15, 16, 17)</sup>. The predominant cells in the inflammatory infiltrate are CD3+ cells and less CD19 B cells, and a small percentage of CD4+, CD8+ cells. Also a large percentage of cells were seen in the infiltrate, which were CD3+, CD4- and CD8-, these were presumed to be gamma delta cells.

UC is also characterized by a special distribution of inflammation and architectural distortion with increasing intensity from the proximal towards the distal colon. Regarding T cells, total numbers of T cells are increased in tissue samples<sup>(14)</sup> while the ratio of CD4+ to CD8+ cells is unchanged in patients with ulcerative colitis<sup>(15)</sup>.

Table 2. Result of comparison for total T cells and different subsets of T cells among different study groups of UC lesions.

	T cell (CD3 <sup>+</sup> )	B cell (CD19 <sup>+</sup> )	T-helper 2 (CD4 <sup>+</sup> )	T-helper 1 (CD8 <sup>+</sup> )
Grade 1 (7)	175.39	27.11	138.11	46.11
Grade 2 (6)	240	35.5	205	39.5
Grade 3 (9)	268.5	41.83	204.33	35.33
Grade 4 (8)	298.22	34.5	190.4	22.9
Grade 5 (8)	358.83	62.33	256.67	71.17
Grade 6 (9)	466.83	51.17	305.17	62
Among grades	≤0.001**	≤0.001**	≤0.001**	≤0.001**

\* = statistical significant difference.

\*\* = highly statistical significant difference

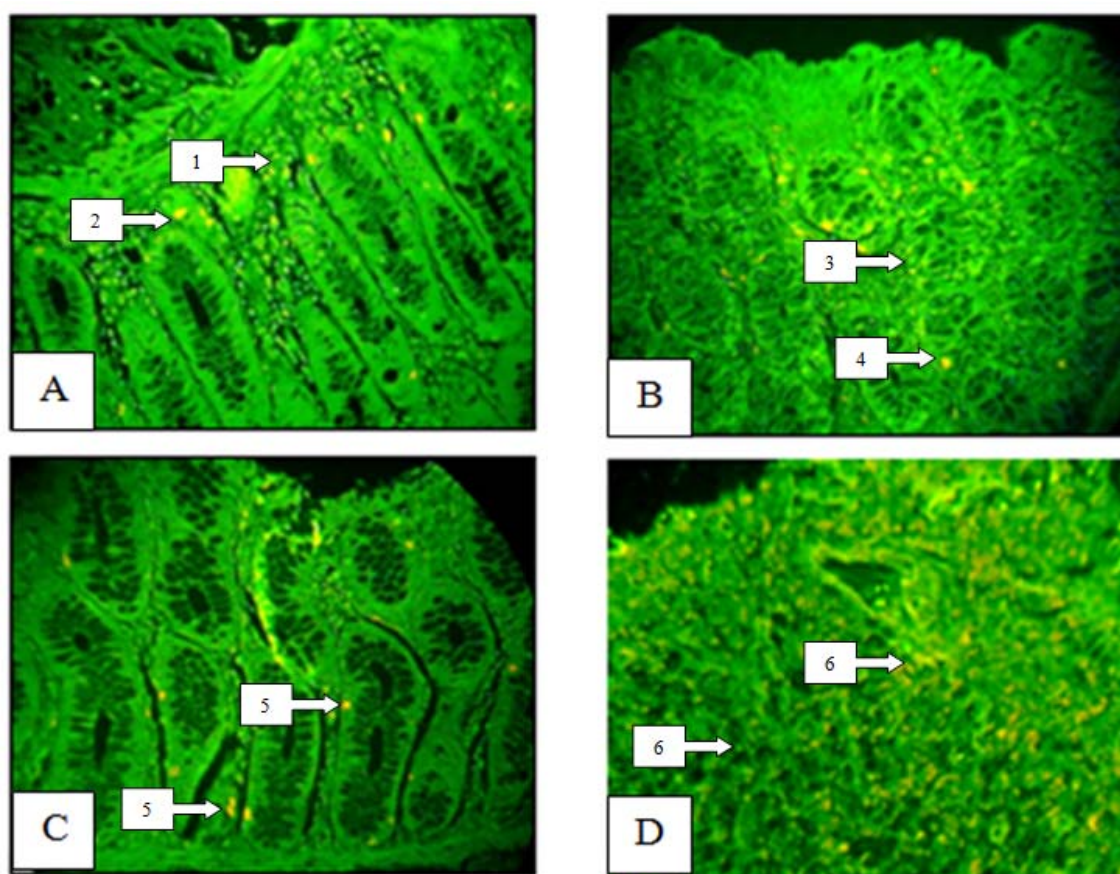


Figure 1. Dual immunofluorescence (A, B, C and D) staining of ulcerative colitis lesions (X400). Colon stained with Anti (CD3-CD19) antibodies. (A) Stained cells can be seen in aggregates near the muscularis mucosa and extended through lamina propria showing several T-cells (CD3+ve) (1) and fewer plasma cells (CD19+ve) at the crypts base near the muscularis (basal plasmocytosis) (2) (grade III). (B) T-helper 2 (CD4+ve) (3) extensively infiltrated through lamina propria and fewer T-helper 1 (CD8+ve) transmucosal infiltration seen in this section (4) (grade II). (C) Both T-cells and plasma cell were distributed in the lamina propria, note that plasma cells in the base of mucosa and between crypts (5) (grade II). (D) Extensive random infiltration of both helper-1 and helper-2 cells among destroyed crypts (6) (grade VI).

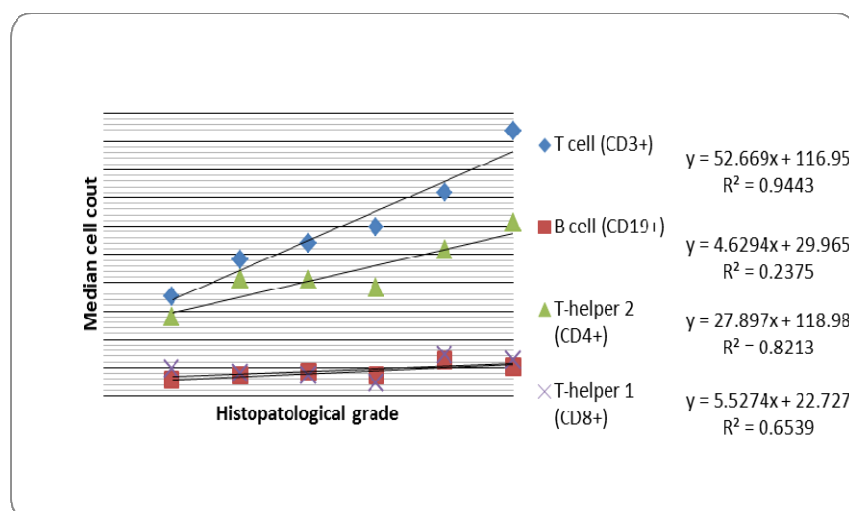


Figure 2. Scatter blot showing the distribution of cellular phenotype in correlation with histopathological grade.

Inflammation is characterized by increased intensity of the lamina propria cellular infiltrate with alterations of the composition and changes in distribution<sup>(18)</sup>. The normal lamina propria infiltrate is located in the upper part of the mucosa and this pattern persists in infectious colitis. In UC, the infiltrate is more extensive and extends diffusely towards the deeper part (transmucosal) with accumulation of plasma cells near the mucosal base, in-between the crypt base and the muscularis mucosa (basal plasmacytosis), is common. Focal or diffuse basal plasmacytosis (combined with crypt distortion) is a strong predictor for the diagnosis of chronic idiopathic inflammatory bowel disease (IBD) and occurs in over 70% of the patients<sup>(15)</sup>.

1. Increasing attention is being paid to the role of mucosal, rather than circulating, lymphocyte subpopulations in the pathogenesis of intestinal diseases such as inflammatory bowel disease. Study of tissue sections enables analysis of cell populations and their interactions *in situ*, as well as examination of the local microenvironment. Only such a combined fluorescence labeling will increase our understanding of the role

of the intestinal immune system in health and disease.

## References

- Zhang, S. Zhao, X. and Zhang, D. Cellular and Molecular Immunopathogenesis of Ulcerative Colitis. Cellular & Molecular Immunology. 2006; 3: 35- 40.
- Shih DQ, and Targan SR. Immunopathogenesis of inflammatory bowel disease. World J Gastroenterol 2008; 14: 390-400.
- Macdonald TT, Monteleone G, Pender SLF. Recent developments in the immunology of inflammatory bowel disease. Scand J Immunol. 2000; 51:2-9.
- Campieri M, Gionchetti P. Bacteria as the cause of ulcerative colitis. Gut. 2001; 48:132-135.
- Schultsz C, Van Den Berg FM, Ten Kate FW, Tytgat GN, Dankert J. The intestinal mucus layer from patients with inflammatory bowel disease harbors high numbers of bacteria compared with controls. Gastroenterology. 1999; 117:1089-1097.
- Targan SR and Karp LC. Defects in mucosal immunity leading to ulcerative colitis. Immunological Reviews 2005, 206:296-305.
- Powell-Tuck J, Day D W, Buckell N A *et al.* Correlation between defined sigmoidoscopic appearances and other measurements of disease activity in ulcerative colitis. *Dig Dis Sci* 1982; 27: 533–537.

9. Florèn C H, Benoni C, Willén R. Histologic and colonoscopic assessment of disease extension in ulcerative colitis. *Scand J Gastroenterol* 1987; 22: 459–462.
10. Geboes K, Riddell R, Öst Å et al. A reproducible grading scale for histological assessment of inflammation in ulcerative colitis. *Gut* 2000; 47: 404–409.
11. Riley S A, Mani V, Goodman M J et al. Microscopic activity in ulcerative colitis: what does it mean? *Gut* 1991; 32: 174–178.
12. Strickland RG, Husby G, Black WC, Williams RC Jr. Peripheral blood and intestinal lymphocyte subpopulations in Crohn's disease. *Gut* 1975; 16: 847-53.
13. Meuwissen SGM, Feltkamp-Vroom TM, Brutel de la Riviere A, Von Dem Borne AEG, Tytgat GN. Analysis of the lympho-plasmacytic infiltrate in Crohn's disease with special reference to identification of lymphocyte-subpopulations. *Gut* 1976; 17: 770-80.
14. Selby WS, Jewell DP. T lymphocyte subsets in inflammatory bowel disease: peripheral blood. *Gut* 1983; 24: 106-13.
15. Hirata I, Berrebi G, Austin LL, Keren DF, Dobbins WO 3rd. Immunohistological characterization of intraepithelial and lamina propria lymphocytes in control ileum and colon and in inflammatory bowel disease. *Dig Dis Sci* 1986; 31:593-603.
16. Weldon MJ, Lowe C, Joseph AE. Review article: quantitative leucocyte scanning in the assessment of inflammatory bowel disease activity and its response to therapy. *Aliment Pharmacol Ther. Apr* 1996; 10:123-32.
17. Froelich JW, Swanson D. Imaging of inflammatory processes with labeled cells. *Semin Nucl Med. Apr* 1984; 14(2): 128-40.
18. Fuss IJ, Heller F, Boirivant M, Leon F, Yoshida M, Fichtner- Feigl S, et.al. Non-classical CD1d-restricted NK T cells that produce IL-13 characterize an atypical Th2 response in ulcerative colitis. *J Clin Invest* 2004; 113: 1490-1497.
19. Strober W, James SP. The immunologic basis of inflammatory bowel disease. *J Clin Immunol* 1986; 6: 415-432