

Pathological and Biochemical Study on The Albino Rat Treated With *Curcuma Longa* Induced Atherosclerosis By H₂O₂

E. R. AL-Kennany

Department of Pathology
College of Veterinary Medicine
University of Mosul

O. H. Aziz

Department of Veterinary Public Health
College of Veterinary Medicine
University of Dohuk

Received
16 / 04 / 2009

Accepted
22 / 04 / 2009

(H₂O₂)

Albino

%

(GSH)

(MDA)

(VSMC)

ABSTRACT

This study was conducted to determine the effect of *curcuma longa* (*C-longa*) as antioxidant and antiatherogenic in male rats after treated with 0.5% hydrogen peroxide (H₂O₂) in order to induce atherosclerosis. Oxidative stress has been investigated via estimation of Malondialdehyde (MDA) and Glutathione (GSH) in aorta and liver tissues as indirect lipid peroxidation index. The results elucidate significant elevation in GSH concentration parallel significant reduction in MDA concentration in aorta and liver tissues as well as increase in HDL-C and decrease in LDL-C in serum of male rats treated with *C-longa* and H₂O₂. Histological findings resulted in less improvement in

histological picture, reduction in lipid vacuoles in both internal and medial layers associated with proliferation of vascular smooth muscle cells (VSMC) but it not reach to normal tissue.

INTRODUCTION

Curcuma longa (*C-longa*), a perennial herb, is a member of the Zingiberaceae (ginger) family. The plant grows to a height of three to five feet. It has oblong, pointed leaves and bears funnel shaped yellow flowers (1). *C-longa* are constituent from turmeric which are the flavonoid curcumin and volatile oils including turmorone, atlantone, and zingiberone, other constituent include sugars, proteins, and resins. Cucumin is a major compound in *C-longa* being responsible for its biological actions (2).

Water and fats-soluble extracts of turmeric and its curcumin components exhibit strong antioxidant activity comparable to vitamin E and C (3). Also cucumin is capable of scavenging oxygen free radicals such as superoxide anions and hydroxyl free radicals and potent inhibitors of lipid peroxidation (4). (5) Illustrated that curcumin have ability to induced resistance to oxidative damage. Some others showed inhibitory effect of cucumin to platelet aggregation (antithromboic action) (6, 7). The aim of this study was carried out to observe the effect of *C-longa* as antioxidant experimentally in rat.

MATERIAL AND METHODS

Animals

Thirty two male albino rats weighting between 300-325 gm of 2-3 month age were used. The rats housed in hanging cages and maintained under laboratory controlled of temperature (25 ± 2) and light (14 hour light and 10 hour dark), pelleted food and tap water were given *ad libitum*.

Experimental design

Animals were divided into four groups each of 6-8 rats. Group I: received regular rat diet and maintained as a control group; Group II: rats subjected to experimentally induced oxidative stress by the ad libitum supply of drinking water contains 0.5 % H_2O_2 (V/V) (Degussa AG merl Rheinfelden, Belgium) was prepared daily over entire 60 days period of the experiment (30 days), after the end of 30 days of H_2O_2 treated five animals were selected randomly to serve as the *curcuma longa* treated group, Group III: animals of this group received *C-longa* extract for 15 days, which prepared according to (8); Group IV: received only regular rat diet and subjected *C-longa* of eat diet was prepared daily.

Samples collection

At the end of the experiment period, rats were bled and plasma samples were analyzed after collection of blood samples after an overnight fast for 12-14h. and analysis performed in fresh heparin-treated plasma, the lipid

parameters; TC, TG, HDL-C, VLAL-C, were determined by using colorimetric assay kits (Bicon, Diagnostic Gmbh, Burbach, Germany), whereas LDL-C was calculated according to (9) :

$$\text{LDL-C} = \text{TC} - (\text{HDL-C}) - \text{TG}/5$$

Histology

Pieces of aorta and liver tissue were removed for estimation of MDA by thiobarbituric acid (TBA) test as previously described by (10). GSH concentration of aorta and liver was measured according to (11). For histological study, rats killed by anesthesia, aorta were dissected from the arch to the bifurcation, rinsed with isotonic saline and opened along the intercostals and stained with suden for detection of fatty streak. After fixation of aorta and liver, tissue blocks were routinely embedded in paraffin, and 5-6 μ sections were cut. Histological sections were stained with haematoxyline and eosin (H&E) (12).

Statistical analysis:

All data were analyzed by-one-way analysis of variance ANOVA, the specific group differences were determined using Tukey's test. The accepted level of significant was $P < 0.05$ (13).

RESULT

Chemical assay

Table 1, showed that 0.5 % of H_2O_2 in drinking water significantly increase TC, TG, LDL-C, VLDL-C, and atherogenic index, while HDL-C revealed decreased significantly when compared with untreated control rats. In male rats subjected to H_2O_2 and *C-longa*, the lipid profiles indicated decrease of TC, TG, LDL-C, and VLDL-C in these groups, the level of LDL-C increase significantly (6.77 ± 0.32).

In group treated with *C-longa*, the picture of lipid profiles illustrated an increase of TG (61.93 ± 0.21), and HDL-C (68.61 ± 0.05) with concomitant decrease in TC, LDL-C when compare with control value (Table 1).

Tissue (aorta and liver) TBA reactive substance were significantly increase in male rats after 30 days of H_2O_2 treatment as compare with control group (Table 2). The greatest decrease in MDA content was seen in aorta and liver in rat treated with *C-longa*. *C-longa* supplementation in diet resulted a significant reduction of lipid peroxidation produced, induced by H_2O_2 normalized the MDA value. Table 2 also showed tissue (aorta and liver) GSH content after 45 days of H_2O_2 treatment; they were significant reduction as compare with control value, *C-longa* supplementation kept the aortic GSH within the normal value. It induced a significant decrease in aorta and liver GSH in rat-treated with H_2O_2 0.5%.

Cross pathological change

Fatty streak of initial aorta was seen in rats treated with H_2O_2 after 30 days. This fatty streak was detected only after gross suden staining.

Microscopical changes

Aorta- aortic lesions were seen in rats with H₂O₂ for 30 days characterized by presence of fatty streak, intimal thickening due to presence of lipid vacuole, foam cells, collagen, elastin fragmentation and spindle-shaped cells, as well as, degeneration of vascular smooth muscle cells (VSMC) in intimal and medial layer (Fig 1). In control and *C-longa* treated, rats aorta revealed no pathological changes, while in treated with H₂O₂ and *C-longa*, showed proliferation of VSMCs in media toward the intima, degeneration of some VSMCs, small lipid vacuoles and numbers foam cells in addition to proliferation of fibroblast (Figs 2, 3).

Liver- there were no pathological lesion in rats of control group, liver of group H₂O₂ and H₂O₂ with *C-longa* revealed fatty changes, congestion of blood vessels, some hepatic cells showed coagulation necrosis and cell swelling as well as infiltration of mononucleus inflammatory cells (lymphocytes) (fig 4). While in group treated with *C-longa* showed cell swelling and congestion of blood vessels (sinusoid) associated with infiltration of mononuclear inflammatory cells (fig 5).

Table 1: Level of lipid profile in serum of male rats treated with *C-longa* and 0.5 % H₂O₂ with *C-longa*.

Groups	Parameters					
	TC mg/dl	TG mg/dl	HDL-C mg/dl	LDL-C mg/dl	VLDL-C mg/dl	Atherogenic index
Control	90.60 ± 0.52	62.59 ± 0.32	70.55 ± 0.21	8.50 ± 0.43	12.59 ± 0.26	1.28 ± 0.55
H ₂ O ₂	195.86 ± 2.5	91.81 ± 0.21	44.61 ± 0.53	11.88 ± 0.25	10.36 ± 0.51	4.39 ± 0.04
<i>C-longa</i>	86.68 ± 0.41	60.59 ± 1.21	75.52 ± 2.1	9.88 ± 0.03	12.19 ± 0.21	1.14 ± 0.87
H ₂ O ₂ + <i>C-longa</i>	96.66 ± 0.03	61.93 ± 0.21	68.61 ± 0.05	6.77 ± 0.32	12.38 ± 0.11	14.40 ± 0.08

Value is expressed as means ± SD of 6-8 rats/ group

Means with same superscript in the same column are not significantly different from others (P<0.05)

Table 2: Level of MDA and GSH in aorta and liver of male rats treated with H₂O₂, *C-longa*, and H₂O₂ with *C-longa* comparison with control.

Groups	MDA nmol/g wet tissue		GSH mmol/l	
	Aorta	Liver	Aorta	Liver
Control	443.6 ± 6.33	506.42 ± 15.13	2.33 ± 0.21	2.05 ± 0.3
H ₂ O ₂	598.12 ± 13.6	715.41 ± 13.72	1.02 ± 0.12	1.32 ± 0.06
<i>C-longa</i>	215.05 ± 8.63	498.41 ± 7.66	2.84 ± 2.23	2.2 ± 0.5
H ₂ O ₂ + <i>C-longa</i>	430.21 ± 11.21	686.60 ± 8.19	2.12 ± 0.53	1.95 ± 0.03

Value is expressed as means ± SD of 6-8 rats/ group at (P<0.05)

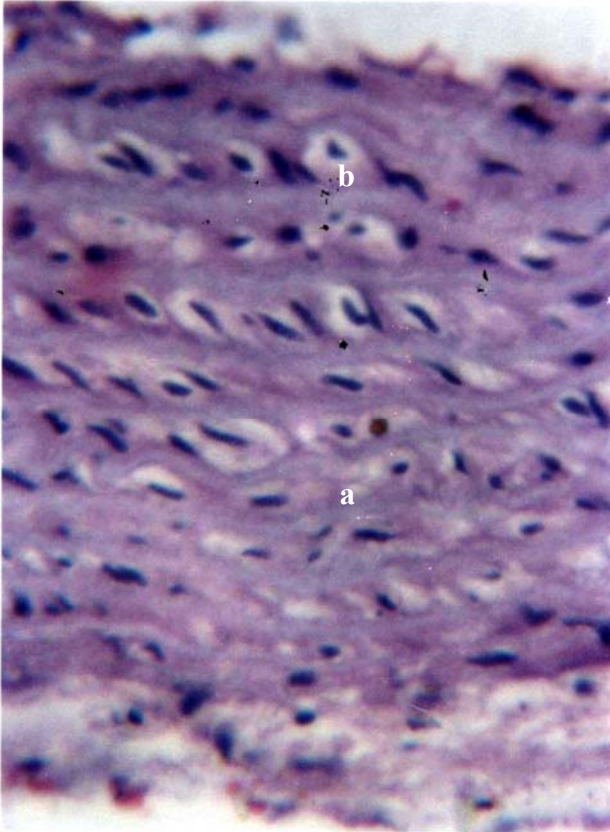


Fig 1: Photomicrograph of rat aorta treated with 0.5 % H₂O₂ revealed presence of lipid vacuole of (a) foam cells in intima and medial layers H & E 400 X.

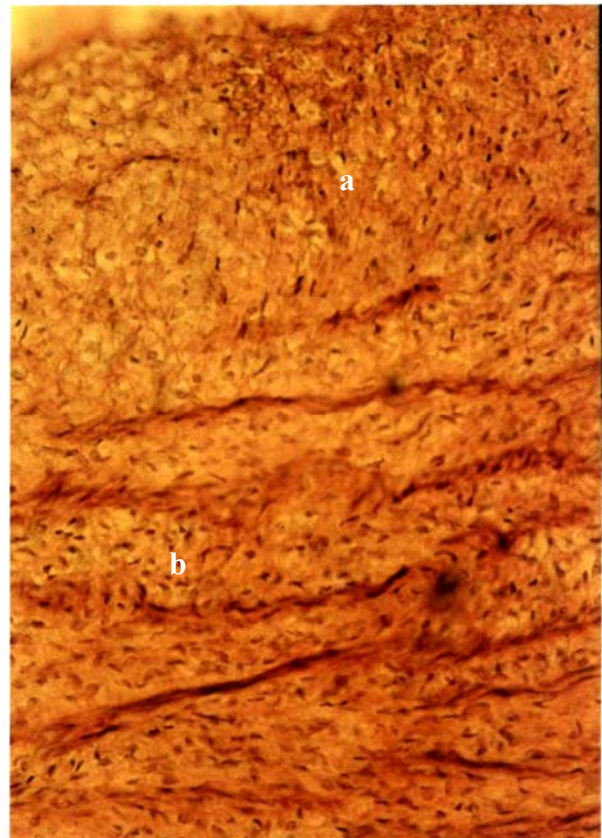


Fig 2: Photomicrograph of rat aorta treated with 0.5 % H₂O₂ with *C-longa*, showed thickening in wall due to presence of lipid vacuole and foam cells (a) associated with proliferation in VSMC (b) H & E 1000 X.

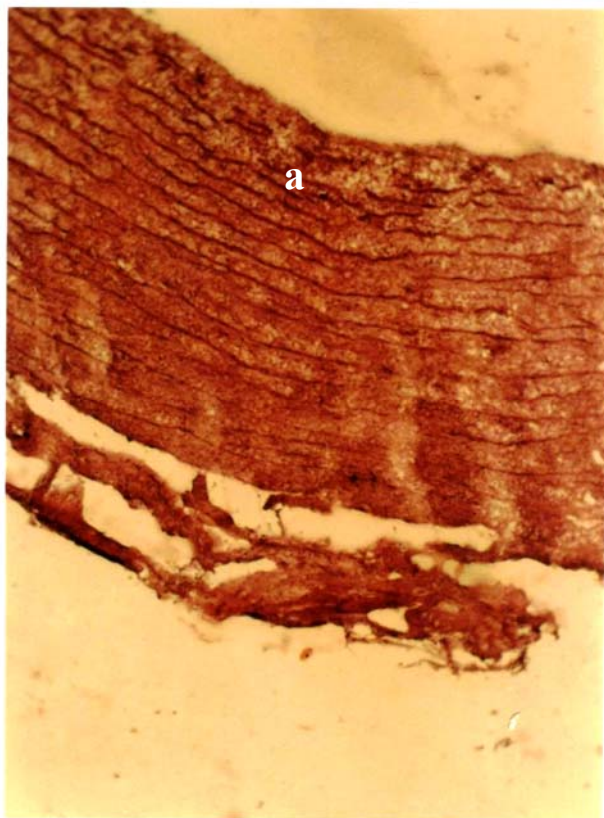
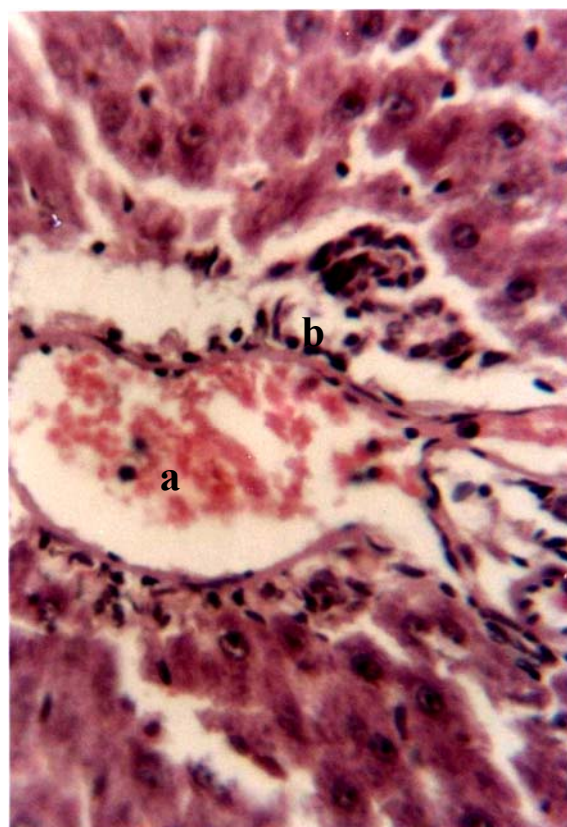


Fig 3: Photomicrograph of rat aorta treated with 0.5 % H₂O₂ with *C-longa*, showed proliferation of VSMC in media toward intima (a) H & E 400 X.

Fig 4: Photomicrograph of rat liver treated with 0.5 % H₂O₂ showed congestion of blood vessels (a) and infiltration of mononucleus inflammatory cells H & E 400 X.



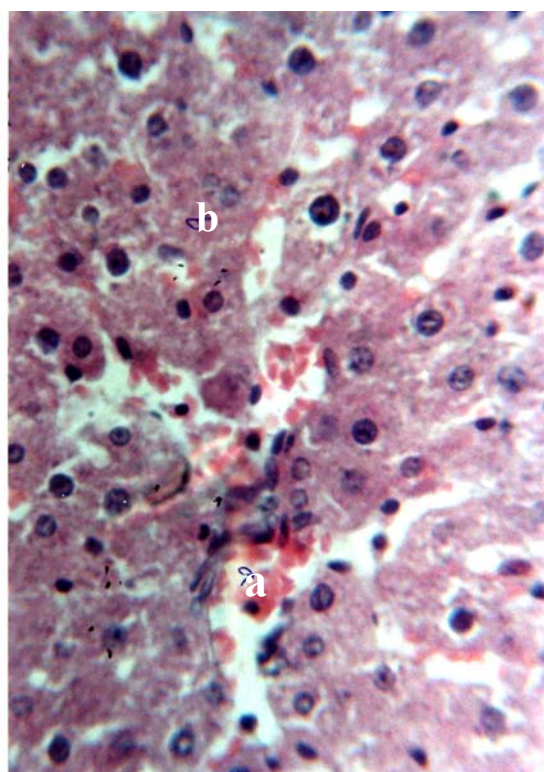


Fig 5: Photomicrograph of rat liver treated with 0.5 % H₂O₂ with *C-longa* showed congestion of sinusoid (a) and infiltration of mononuclear inflammatory cells (b) H &E 400 X.

DISCUSSION

This study demonstrate clear elevation of TC, TG, LDL-C, VLDL-C, and atherogenic index of male rats treated with 0.5% H₂O₂ for 30 days suggesting that these changes reflect susceptibility of these tissues to experimentally induced atherosclerosis by oxidation stress that closely resemble those found in human, chicken and rats (14,15). Result of this study illustrated that administration of H₂O₂ induced atherosclerosis in aorta on high microscope, is similar with that report previously in aorta of chicken, rabbit and rat (16,15).

C-longa used in this study to test its effect as antioxidant against H₂O₂- induced oxidative stress, the results of treated with *C-longa* that provided in diet excreted a significantly ameliorating effect on lipid peroxidation and antioxidant status cause decrease in level of TC, TG, LDL-C, VLDL-C, and atherogenic index as well as decrease in concentration of MDA aorta and liver tissues associated with increase level of HDL-C in serum and GSH of aorta and liver tissues. Our study suggest that curcum is capable of scavenging oxygen free radical such as H₂O₂, superoxide anions and hydroxyl group, which are important for the initiation of lipid peroxidation, as well as, Curcuminoids has a potent inhibitors of lipid peroxidation (4). However *C-longa* reduced the tendency of LDL-C oxidize and enhance cellular antioxidant enzyme activity or antioxidant defense (17).

The protective effect of *C-longa* against H₂O₂ induced atherosclerosis may be due to its ability to induce metabolic activity of cell in the tissue as well as the synergistic activity with vitamin E, which have ability of Curcuminoids to induce releasing of vitamin E from adipose tissue that present in the body (18).

Our study found that oral administration of 0.5 % H₂O₂ for 30 days in male rats induces lipid peroxidation concomitant with aortic lesions. *C-longa* as antioxidant effectively inhibited the H₂O₂ induced changes except the histological one, therefore, the use of *C-longa* as antiatherogenic effect in male rats illustrated less histological effect on aortic lesion via less reduction in lipid vacuole.

REFERENCES

- 1) Dobelis TN. Magic and Medicine of plants. Ed. Readers Digest Association, Inc. Pleasantville, NY.324-326 (1986).
- 2) Araujo CAC. and Leon II. Mem. Inst. Oswaldo Cruz.; 96:723-728 (2001).
- 3) Toda SL. Chem. Pharm Bull.; 33:1725-1728 (1985).
- 4) Roa CV. Cancer Res; 55: 259 (1993).
- 5) Mortellin R., Foresti R., Bssi R. and Green CJ. Radic. Biol. Med; 28: 1303-1312 (2000).
- 6) Shah BH., Nawaz Z., Pertani SA., Rommi A., Mahmood H. and Saeed SA. Biochem. Pharmacol; 58: 1167-1172 (1995).
- 7) Srivastava KC., Bordia A. and Verma SK. Prostaglandins leukot Essent fatty Acids; 52:223-227 (1995).
- 8) Alkennany ER., Al-Alaf ES. and Maraa EB. J Al-Qadisiya Vet Sci; 6:95-102 (2007).
- 9) Morita TA., Oh-Hashi K., Takei M., Ikai S., Kasaoka S. and KiriyaawaC. J. Nutr., 127: 470-477 (1997).
- 10) Gilbert SD.and Both EF. Anal Biochem ; 137:282-286 (1980).
- 11) Moron MS., Depirre JW. and Mennerv IK. Bioch Biophys Acta Stemp; 582: 67-78 (1979).
- 12) Luna LG. Manual of histological staining methods of the armed forces institute of pathology 3rd edit. McGraw Hill Book Co. 3, 34-36 (1986).
- 13) Bruning JL, Kintz BL. Computational Handbook of Statistics. 2^{ed} ed. Scott Foresman and Co. Glenveiw. Illionois. U.S.A. 1977: 75-80, 102-138.
- 14) Sayer J. and Timmis A. Circulation; 94:1-8 (1996).
- 15) Alkennany ER. and Al-kafaf AI. Iraq J Vet Sci; 20: 139-151 (2006).
- 16) Alkennany ER. and Alalaf ES.. Iraq J Vet Sci; (2005).
- 17) Venkatesan N., Punithavathi V. and Chandrakasan G. Life Sci; 61: 51-58 (1997).
- 18) Hunge HC., Jan TR. and Yeh SF. Eur. J. Pharmacol; 221: 381-384 (1992).