

Uterus didelphys in a buffalo heifer: a case report

O. I. Azawi, A. J. Ali, U. T. Noaman and E. H. Lazim

Department of Veterinary Surgery and Obstetrics, College of Veterinary Medicine, University of Mosul, Mosul, Iraq

(Received March 25, 2007; Accepted January 27, 2008)

Keywords: Buffalo cow, Genital system, Uterus didelphys.

Available online at <http://www.vetmedmosul.org/ijvs>

عق رحم مزدوج في عجلة جاموس: تقرير حالة

أسامة إبراهيم عزوي، علي جدعان علي، عدي طلعت نعمان وإيمان حياوي لازم

فرع الجراحة البيطرية وعلم تناسل الحيوان، كلية الطب البيطري، جامعة الموصل، الموصل، العراق

الخلاصة

يعد عق الرحم المزدوج من التشوهات الخلقية في الحيوانات أحادية الولادة. تم تشخيص الحالة في عجلة جاموس خلال جمع عينات للأعضاء التناسلية من مجزرة الموصل. تعد هذه الحالة لعنق الرحم المزدوج الأولى التي يتم تسجيلها في الجاموس.

Uterus didelphys or true double cervix is a congenital anatomical defect of the female genital tract of monotocous species, including cattle and humans (1). The defect is characterized by presence of completely separated cervixes, each one leading to a separate uterine horn. The condition has been attributed to failure of fusion of the caudal portions of the paramesonephric ducts during embryonic development, resulting in a double cervix or a divided uterine funds (2). These cases could conceive normally, but may show dystocia due to a fetal limb entering each cervical canal (3). Case reports of uterus didelphys in cows are sporadic (4,5).

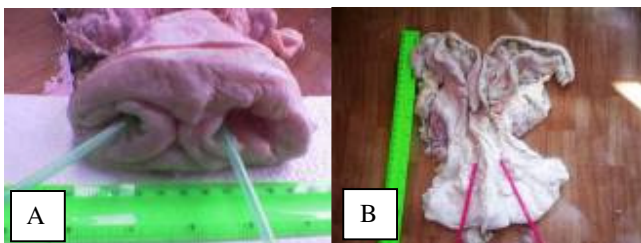


Fig 1: A- Buffalo heifer reproductive tract showing two cervical canals, B- two cervical canals leading to separate uterine horns.

In the present case and during routine collection of reproductive tracts from Mosul abattoir a uterus didelphys was diagnosed through the post mortem examination of the reproductive tract of a buffalo heifer. Macroscopically, the genital tract had two cervical canals without any connections between them; they were separately opened into separated uterine horns (Figure 1). This is the first record of such a case in buffalo cows.

References

1. Kennedy PC, Miller NB. The female genital system. In: Pathology of domestic animals Jubb KVF, Kennedy PC, Palmer N, eds. 3rd Ed. Vol. 3. San Diego: Academic Press, 1993:355.
2. Roberts SJ. Hereditary or congenital anatomic defects of the reproductive tract. In: Veterinary obstetrics and genital diseases (Theriogenology). 3rd Ed Woodstock: SJ Roberts, 1986:520-533.
3. Arthur GH, Noakes DE, Pearson H. Infertility in the cow: General considerations, anatomical, functional and management causes. In: Veterinary reproduction and obstetrics (Theriogenology). Arthur GH, Noakes DE, Pearson H, eds. 6th Ed., London: Bailliere Tindall, 1992:346-347.
4. Fathalla M. Pregnancy in a cow with uterus didelphys. Aust Vet J, 2000; 78: 616.
5. Hatipoglu F, Ortatlati M, Kiran MM, Erer H, Ciftci MK. An abattoir study of genital pathology in cows: II. Uterus, cervix and vagina. Revue Med Vet, 2002; 153: 93-100.