

## A comparative study for lung biopsy in dogs

O. H. Al-Hyani

Department of Surgery and Theriogenology, College of Veterinary Medicine, University of Mosul, Mosul, Iraq

(Received April 9, 2009; Accepted April 15, 2010)

### Abstract

This study was conducted to compare two techniques for obtaining lung biopsy in dogs. Twelve adult dogs from both sexes were used in this study. The animals were divided into two groups, each group contained six dogs. In both groups, the animals were applied under right thoracotomy for lung biopsy collection from the middle lobe. In group one the lung biopsy was obtained by removal of a piece of lung tissue with a scalpel and the cut edge was sutured by two rows of continuous horizontal matters and simple continuous patterns where as in group two the biopsy was collected using a therom-cautery device and the cut edge was left without suturing.

Gross and histopathological changes were examined on postoperative days 15 and 30. The gross pathological changes in group one after 15 day revealed presence of severe adhesions between the cutting site and pleura where as the adhesion was less after 30 postoperative day. The pulmonary tissue at site of biopsy collection relatively became hard especially near the suture line. Group two showed no adhesion on postoperative day 15 but the adhesion appeared on postoperative day 30 between the sites of cauterization with the other lung lobes which varied from simple to moderate adhesion while the lung tissue at cauterization site had approximately the same consistency of normal lung tissues. The histopathological changes in group one was characterized by formation of inflammatory nodules and high infiltration of inflammatory cells particularly polymorphonuclear cells with presence of pulmonary hemorrhage and edema in the cutting site. Group two showed lesser histopathological changes and they were associated with lesser mononuclear inflammatory cells where as hemorrhage and edema were not developed on the cutting site. In conclusion, the use of thermo-cautery device to obtain the lung biopsy is simple, fast, less invasive and more aseptic than use the cutting and suturing method.

**Keywords:** Thoracotomy; Lung; Biopsy; Dog.

Available online at <http://www.vetmedmosul.org/ijvs>

### دراسة مقارنة للخزعة الرئوية في الكلاب

أسامة حازم الحياني

فرع الجراحة وعلم تناسل الحيوان، كلية الطب البيطري، جامعة الموصل، الموصل، العراق

### الخلاصة

صممت هذه الدراسة للمقارنة بين طريقتين لأخذ الخزعة الرئوية في الكلاب حيث تم استخدام اثني عشر كلبا بالغا ومن مختلف الجنسين وقسمت الحيوانات إلى مجموعتين، كل مجموعة ضمت ستة كلاب وخضعت الحيوانات في كلتا المجموعتين لعملية فتح القفص الصدري ومن الجهة اليمنى وذلك لأخذ الخزعة الرئوية من الفص الرئوي الأوسط، ففي المجموعة الأولى تم أخذ الخزعة الرئوية من خلال إزالة جزء من نسيج الرئة بواسطة المشرط الجراحي ثم خياطة منطقة القطع باستخدام تقنيتين من الخياطة أما في المجموعة الثانية فاستخدم لأخذ الخزعة الرئوية أداة الكاوية الحرارية وبدون خياطة منطقة القطع بخيط جراحي. درست كل من التغيرات العيانية والنسجية المرضية لمنطقة أخذ الخزعة للفترات 15 و 30 يوما بعد إجراء العملية، ففي المجموعة الأولى أوضحت التغيرات العيانية بعد خمسة عشر يوما وجود التصاقات شديدة بين منطقة القطع وغشاء الجنب ولكن الالتصاقات قلت بشكل ملحوظ بعد ثلاثين يوما وأصبح النسيج الرئوي في منطقة أخذ الخزعة الرئوية تقريبا صلدا خصوصا قرب منطقة الخيط الجراحي أما في

المجموعة الثانية وبعد خمسة عشر يوما من إجراء العملية فلم يشاهد حدوث أي التصاقات إلا بعد ثلاثين يوما حيث كانت الالتصاقات ما بين منطقة الكي وفصوص رئوية أخرى وبشدة تراوحت من الدرجة البسيطة إلى المتوسطة وتميز النسيج الرئوي في منطقة الكي بأنه أصبح مشابها تقريبا لطبيعة النسيج الرئوي الطبيعي. في حين بينت التغيرات النسيجية المرضية للمجموعة الأولى تكون عقد التهابية وارتشاح كبير للخلايا الالتهابية خصوصا الخلايا متعددة النوى مع وجود خبز ونزف رئوي في منطقة القطع عكس المجموعة الثانية التي لم يشاهد فيها تغيرات نسيجية مرضية شديدة سوى ارتشاح قليل للخلايا الالتهابية وحيدة النواة بالإضافة إلى عدم تكون خبز ونزف رئوي بمنطقة القطع. بالاستنتاج نجد أن استخدام أداة الكاوية الحرارية لأخذ الخزعة الرئوية تميزت بالسهولة والسرعة وقل تلوثا وتأثيرا مقارنة مع استخدام طريقة القطع والخياطة.

## **Introduction**

A lung biopsy can be defined as a collection of a small piece of lung tissue by different approaches for diagnosis of different lung diseases like tumors and certain infections (1,2). Lung tissue is composed from vascular network to carry blood and bronchial structure that carry air to oxygenation the blood. Resection this type of tissue poses two problems to a surgeon; achieving homeostasis of vascular tissue and achieving pneumostasis of bronchial structure, additionally since these problems usually involve lung tissue that is frequently diseased. The diseased lung is often over distended or inflamed then resulting in fragile, friable tissue. Consequently variety of techniques are available to surgeons as means of controlling homeostasis and pneumostasis in lung tissue which include suturing, application of clips, radio frequency energy or other energy applications. The post operative air leaks is the most frequent complication after lung surgery regardless of whether an operation is performed by thoracotomy or by use of endoscopic techniques (3). Therefore the surgeon should reduce air leaks by careful suturing, stapling or electrocautery as well as by using other different methods for seal the lung such as using fibrin glue (4-7).

The diagnosis of pulmonary disease in dogs is very challenging so the lung biopsy is used for diagnosis and treatment of such lung diseases (8). Biopsy of the pulmonary parenchyma remains the technique of choice when diagnosis is absolutely required (9). Lung biopsies can be done by 4 ways either by: 1) bronchoscope biopsy, 2) needle biopsy, 3) thoracoscopic surgery, 4) open chest biopsy (2,10,11). Others depend on diagnosis of lung disease through cytological and histological evaluation of diseased tissue which usually reveals a definite diagnosis. The cytological evaluation for samples can be obtained through transtracheal washes, bronchial brushing, bronchoalveolar lavage, transthoracic lung aspiration and transthoracic needle biopsy where as for histologic evaluation may be obtained via either atransbronchiolar approach or lateral thoracotomy (12). Lung biopsy is contraindicated in cases that suffer from a bleeding disorder or abnormal blood clotting because of low platelet counts, or prolonged prothrombin time (PT) or partial

thromboplastin time (PTT). In addition, lung biopsies should not be performed if other tests indicate the patient has enlarged alveoli associated with emphysema, pulmonary hypertension, or enlargement of the right ventricle of the heart. Like other surgical operation, lung biopsy procedure can cause some postoperative complication such as hemorrhage, infection, pneumonia and pneumothorax, but in patients which had some pulmonary defects and undergoing open biopsy procedures, the risk of these complications is higher (2). The thermo cautery device used in this study was recently manufactured in the Department of Surgery and Theriogenology, College of Veterinary Medicine, University of Mosul by Aziz et al. (13) and its was used successfully in many surgical operations such as partial splenectomy in dogs and ovarioectomy in equidea (14,15).

The aim of this study was to collect lung biopsy through lateral thoracotomy approach as well as comparing the gross and histoathological changes between incision and suturing versus cauterization for obtaining the lung tissue biopsy.

## **Materials and Methods**

Twelve adult dogs from both sexes were used. The animals were divided into two groups of six dogs each. In group one the biopsy was obtained by excision and suturing where as in group two the biopsy was collected by using a thermo-cautery device. In both groups, right thoracotomy approach was used for biopsy collection. All the operations where performed under general anesthesia using atropine sulfate at dose (0.1 mg /kg, I.M.) as a premedication followed by administration of combination of xylazine and ketamine (2 mg / kg + 10 mg / kg, I.M., respectively). The animals where connected with the positive pressure ventilation machine for maintenance of the respiration during the thoracotomy. The right site of the thoracic cavity was prepared for aseptic surgery and skin incision was induced along the 6<sup>th</sup> rib, then the latissimus dorsi was incised over the rib. The serratus ventralis and external abdominal oblique muscles were located and retracted to expose the rib. The periosteum on the lateral surface of the rib was incised and reflected, and then the rib was resected

at the costochondral junction. The periosteum of the inner surface of the rib and pleura was incised as stump incision during the expiratory pause and extended with scissors. The middle lobe was selected for biopsy collection. In group one, a crushing forceps was applied at a distance of 5 to 8 cm from the edge of the middle lobe then continuous horizontal matters suture was placed proximal to the forceps. The lung tissue was excised just between the suture lines and forceps and leaving a margin of tissue 2 to 3 mm distal to the suture. The cut edge was closed by using a simple continuous patterns, where as in group two, thoracotomy was performed as in group one, but the biopsy collection was accomplished by using a thermo cautery device after placing the crushing clamps instead of cutting and suturing method. The thermo cautery device was placed proximal to the crushing clamps, firstly an intermitted electrical current was applied to produce a cauterization and coagulation zone around the crushed area to reduce hemorrhage, and then continued electrical current was applied for excision of the biopsy. In both groups, the site of tissue excision was checked for post operative leakage or bleeding then a chest tube was applied to reduce the rate of post operative pneumothorax. Thoracotomy incision was closed by closing of pleura and periosteum with lock stitch followed by suturing of the muscles by simple continuous pattern using cat gut suture and finally the skin was closed by horizontal interrupted pattern using silk. All the animals were administered after operation with a systemic injection of penicillin streptomycin (0.1 ml / kg) daily for 5 days and treated the wound daily with antiseptic spray.

The gross and histopathological changes of the site of biopsy collection were examined on postoperative days 15 and 30.

## Results

### Gross pathological changes

Group one, after 15 day, showed severe adhesion between the sites of biopsy collection with pleura. This adhesion was markedly decreased after 30 postoperative days. In group two, there was no adhesion formation on postoperative day 15, but mild to moderate degree of adhesion was developed between the site of the biopsy with the caudal lobe on postoperative day 30 (Figures 1-4). Both groups showed complete bridging to the edges of the incision on postoperative day 30. By finger palpation on the site of biopsy collection hard nodules was felt at the site of suturing in group one especially after 15 day where as in group two the site of biopsy had normal texture of the lung tissue. Both groups show no leakage from the site of the biopsy collection.

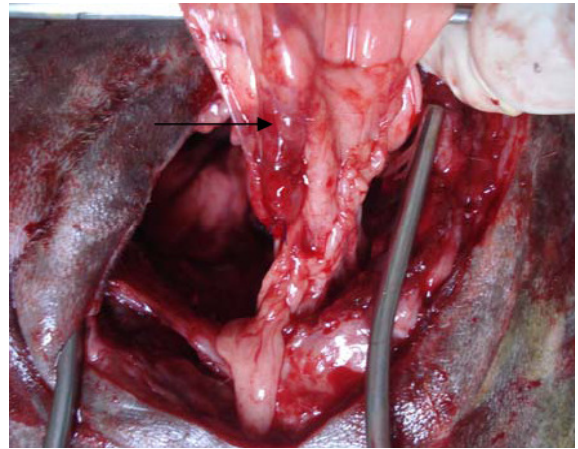


Figure 1: site of biopsy on postoperative day 15 in group one.

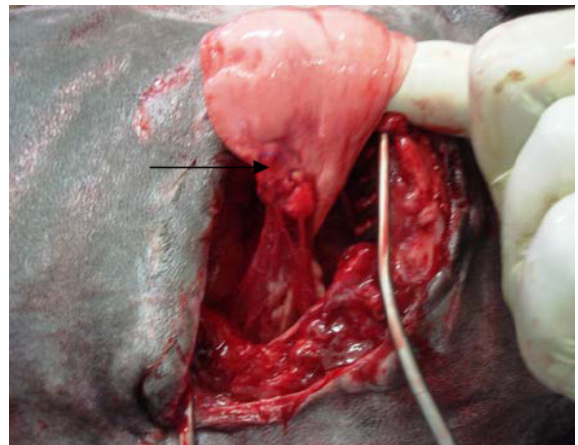


Figure 2: site of biopsy on postoperative day 30 in group one.

### Histopathological changes

Animals in group one after 15 postoperative days showed presence of adhesion formation between pleura and lung tissue with inflammatory nodules around the line of the incision. Near the suture material there was proliferation of fibroblast, collagen fiber with newly formed capillaries. Hemorrhage, edema, and emphysema were associated with proliferation of pneumocyte type II and little area of atelectasis, Also other sections showed infiltration of polymorphonuclear inflammatory cells (Figures 5, 6), where as after 30 postoperative day there were presence network of fibrin, newly capillaries and collagen fiber, Hemorrhage, atelectasis, interstitial emphysema and infiltration of mononuclear inflammatory cells (Figures 7, 8). In general, disorientation of lung tissue structure with rearrangement of bronchioles was seen.

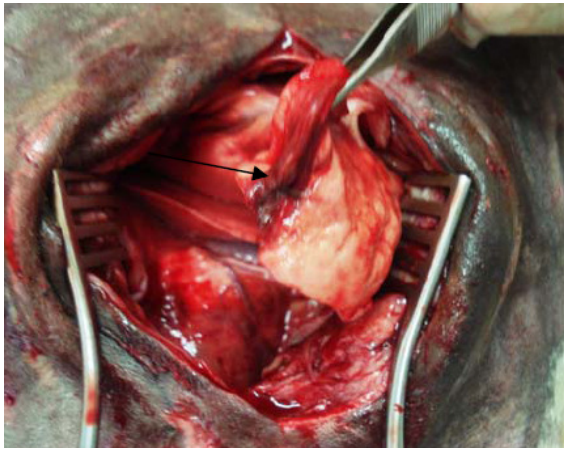


Figure 3: site of biopsy on postoperative day 15 in group two.

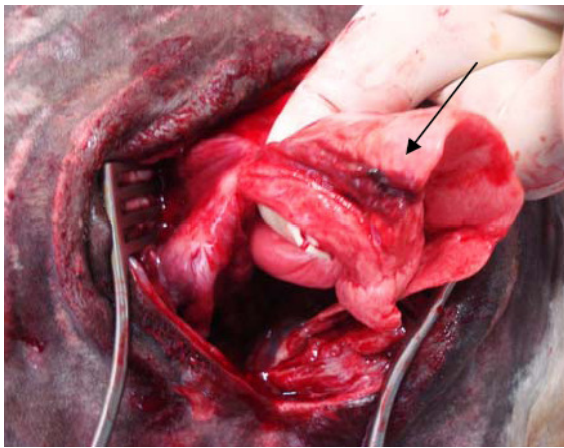


Figure 4: site of biopsy on postoperative day 30 in group two.

In group two after 15 postoperative days, newly granulation tissue appeared with infiltration of mononuclear inflammatory cells. The capillary bed was congested; proliferation in pneumocyte and the wall of the blood vessels was thickened with hyalinization and vacuolation especially near the area of cautery. The changes included area of atelectasis and thickening in the wall of the alveoli with the presence of serous exudates within the lumen. Other sections showed hyperplasia and squamous metaplasia of the epithelium of mucosa of bronchioles and the lumen contained serous exudates (Figures 9, 10). After 30 postoperative days there was granulation tissue with infiltration of little of mononuclear inflammatory cells. The septa of the lung between the lobules suffered from thickening and proliferation. The wall of alveoli was distracted without presence of serous exudates within the

lumen. Also, some area of alveolar atelectasis showed the presence variable size of vacuoles in tissue. The epithelium of mucosa of bronchioles showed squamous metaplasia (Figure 11).

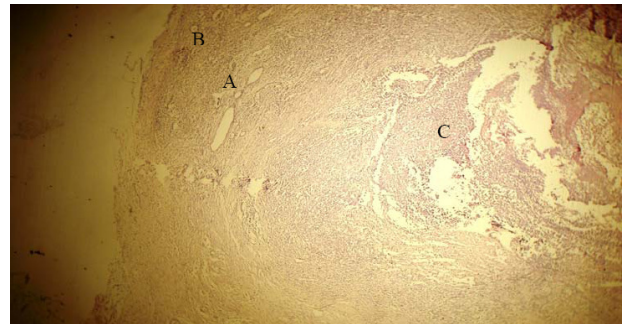


Figure 5: Photomicrograph of lung tissue in a dog on postoperative day 15 in group one showed granulation tissue formation (collagen fiber and fibroblast) (A), hemorrhage (B) and inflammatory nodules (C) (H&E 35X).

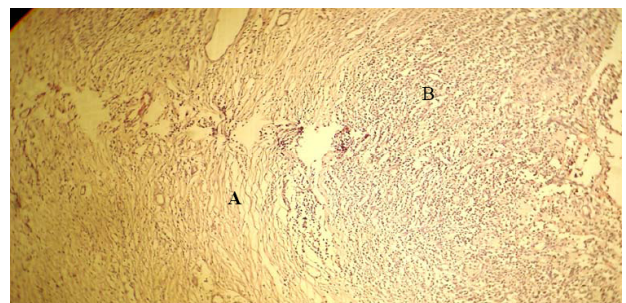


Figure 6: Photomicrograph of lung tissue in a dog on postoperative day 15 in group one showed area of atelectasis (A), infiltration of polymorphonuclear inflammatory cells (B) (H&E 90X).

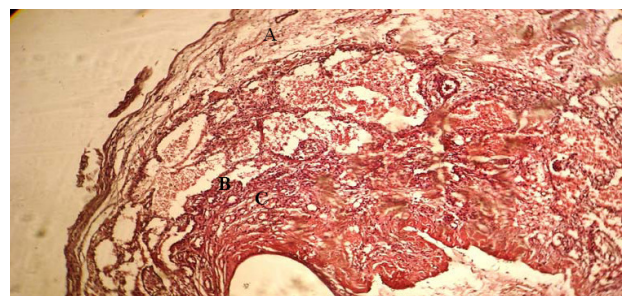


Figure 7: Photomicrograph of lung tissue in a dog on postoperative day 30 in group one showing the presence of fibrin (A), newly capillaries (B) and collagen fiber (C) (H&E 90X).

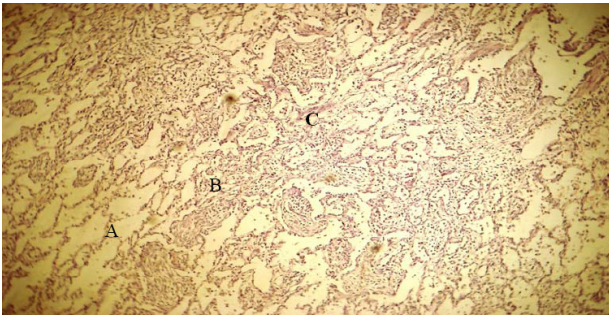


Figure 8: Photomicrograph of lung tissue in a dog on postoperative day 30 in group one showed interstitial emphysema (A), atelectasis (B), and infiltration of mononuclear inflammatory cells (C) (H & E 90X).

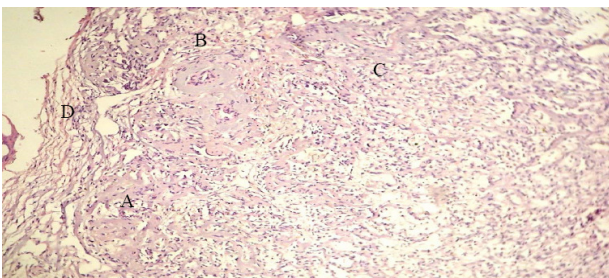


Figure 9: Photomicrograph of lung tissue in a dog on postoperative day 15 in group two showed newly granulation tissue (A), thickening in the wall of congested capillaries (B) and infiltration of mononuclear inflammatory cells (C) with atelectasis (D) (H&E 90X).

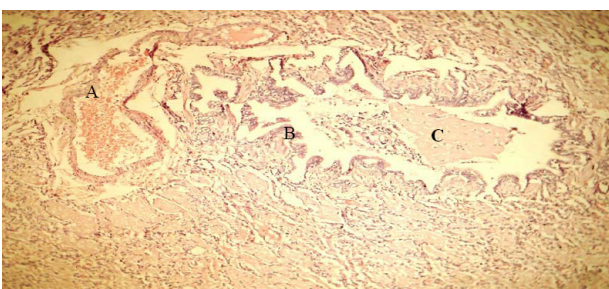

Figure 10: Photomicrograph of lung tissue in a dog on postoperative day 15 in group two showed congestion of the blood vessels (A), hyperplasia and metaplasia of the bronchial epithelial mucosa (B) associated with serous exudates in the lumen of it (C) (H&E 90X).

## Discussion

In this study cutting and suturing method for biopsy collection were associated with severe adhesion between the site of biopsy collection and pleura with hardness of

lung tissue near the suture line. This adhesion may be due to the hemorrhage that is associated with this technique and the damage of the parenchyma of the lung associated with penetration of the suturing needle and suture material that may cause postoperative air leaks that need prolonged chest tube drainage time then increasing of the plural infection (4,7). Histopathologically, there was severe infiltration of inflammatory cells which was decreased after one month; this finding resemble that found by (2) where the severe infiltration of inflammatory cells are commonly associated with the presence of suture materials or due to pneumonia that commonly follow open chest surgery. This infection can be subsided with systemic antibiotic therapy. Edema and hemorrhage was seen at the site of biopsy in lung tissue in this group. Edema formation may be due to the effect of tissue excision or in association with generalized edema of the lung that developed as a result of tracheal intubations and anesthesia (16-18). Hemorrhage was developed as a result of bleeding associated with incision of the lung tissue or due to damage to the pulmonary capillaries or disruption to the bronchial vessels as a result of tracheal intubations (18).

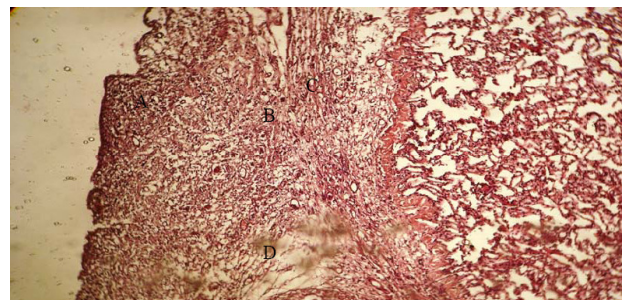


Figure 11: Photomicrograph of lung tissue in a dog on postoperative day 30 in group two showed granulation tissue (A), infiltration of little of mononuclear inflammatory cells (B) thickening and proliferation in the septa between lobules (C) and area of atelectasis (D) (H&E 90X).

In group two, the site of biopsy collection was free from adhesion with the pleura, this may be due to the excellent control of hemorrhage by the using of the thermo cautery device (15,19) when compared with group one. Also the site of biopsy collection had normal consistency resembling to normal lung tissue because this was free from suture material which act as foreign body causing hardening of the site of the incision and enhancing the development of adhesion formation with the pleura as in group one. The infiltration of inflammatory cells was low when compared with group one and this feature may be due to absence of the suture material and the effect of heating that was produced from the thermo cautery which had aseptic action.

The lung tissue at the site of biopsy collection in this group was free from edema and hemorrhage, this effect is an agreement with those found by (15,19-22) who reported that heat produced from lasers, ultrasounds coagulating device, radiofrequency radio energy, electrocautery device and thermocautery device cause coagulation of the blood vessels that prevent bleeding, Additionally the heat produced by the thermo cautery causes vaporization of the tissue fluid and rupture of cells as well as the appearance the vaculation in tissue which may lead to the disappearance of edema (13,23,24).

In both groups, atelectasis was formed and this could be due to pneumothorax that is associated with the thoracotomy (2,25). The atelectasis can be also developed due to obstruction of air passage (bronchus or bronchioles) or by pressure on the outside of the lung (26). In group one, the hole that was made by the biopsy needle may cause lung collapse due to the air leaks (12), where as in group two the atelectasis was more severe at the site of biopsy than in group one and this is may be due to the effect of heating and the pressure produced by heating wire on the tissue during biopsy collection.

## References

1. Lee JA. Incision for lung biopsy. www. Veri Med Health Care Network. 2006.
2. Maria G, Essig MS. Lung biopsy. www.GIGNA. 2007.
3. Porte HL, Jany T, Akkad R, Conti M, Gillet PA, Gurdar A, Wurtz AJ. Randomized common alveolar air leaks after lobectomy. *Ann Thorac Surg.* 2001;71:1618-1622.
4. Macchiarini P, Wain J, Almy S, Darteville P. Experimental and clinical evaluation of air leaks in thoracic operation. *J Thorac Cardio Vasc Surg.* 1999;17:751-758.
5. Anegg U, Rychlik R, Juttner FS. Do the benefits of shorter hospital stay associated with the fleece-bound sealing outweigh the cost of the materials. *Euro Asso of Cardio- Thoracic Sur.* 2007;7:292-296.
6. Westerdahl E, Lindmark B, Eriksson T, Friberg O, Hedenstierna G, Tenling A. Deep-breathing exercises reduce atelectasis and improve pulmonary function after coronary artery bypass surgery. *Chest.* 2005;128:3482-3488.
7. Ayed AK, Raghunathan R. Thoracoscopy versus open lung biopsy in the diagnosis of interstitial lung disease, a randomized controlled trial. *JR Coll Surg Edinb.* 2000;45(3):159-163.
8. Pramatinai CH, Brahmasa A, Chuthatop S, Borkawan P, Komin K. Thoracoscopic – guided lung biopsy in dogs. *TJVM.* 2003;36(4):33-40.
9. Bauer TG. Lung biopsy. *Vet Clin North Am Small Anima Pract.* 2000; 30(60):1207-25.
10. Hider E, Murat S, Okan S and Onder S. Importance of lung biopsy in patients suspected interstitial lung disease. *Eur J Med.* 2007;4(1):16-18.
11. Soh LH, Chian CF, Yan HC, Perng WC. Role of lung biopsy in patients with diffuse lung infiltrates and acute respiratory failure. *J Formos Med Assoc.* 2005;104(1):17-21.
12. Faunt KK, Jones BD, Turk JR, Cohnl A, Dodam JP. Evaluation of biopsy specimens obtained during thoracoscopy from lungs of clinical normal dogs. *Am J Vet Res.* 1998;59:1499-1502.
13. Aziz DM, Al Badrany MS, Taha MB. Laproscopic ovarioectomy in standing donkeys by using a new instrument. *Anim Reprod Scien.* 2008 ;107:107-114.
14. Al heani WA. Laproscopic partial splenectomy in dogs. MSc. Thesis, College of Veterinary Medicine, University of Mosul, Mosul, Iraq, 2007.
15. Alanaz MTH. Comparative study of different methods of laparoscopic ovarioectomy in equidae. MSc. Thesis, College of Veterinary Medicine, University of Mosul, Mosul, Iraq. 2007.
16. Takroui M, Baaj J. Bilateral negative airway pressure pulmonary edema: case report. *Middle East J Anaesthesiol.* 2005;18(3):631-638.
17. Koop KH. Post obstructive pulmonary edema as a complication of endotracheal tube obstruction. *Anaesthesiol Intensivmed Notfallmed Schmerzther.* 2000;35(1):721-4.
18. Sownam Y, Gareral D. Pulmonary hemorrhage in association with negative edema in an intubated patient. *Acta Anaesthes Scand.* 2001;45(7):911-913.
19. Hendrickson DA. Electrocautery as an adjunct to minimally invasive procedures. www. ivis.org. 2006.
20. Palmer SE. Used lasers in laparoscopic surgery. In: Fischer AJ, equine diagnostic and surgical laparoscopy. W.B. Saunders Company, Philadelphia, USA. 2002 ; PP:83- 90.
21. Hendrickson DA. Laparoscopic ovarioectomy in horses. www. dvmnews magazine com. 2005.
22. Cuschieri A. Technology of minimal access surgery. www. bmj.com. 1999.
23. Chung YH, Ilu H, Lin AS, Lin MC. Bronchoscopy electrocautery for palliation of post – anastomosis tracheal stricture in a patient with complete tracheal transection following blunt chest trauma. *Chang Gung Med J.* 2005;28(10):742-749.
24. Fischer AT. Electro surgery in laproscopy. In: fischer A.T. Equine surgical and diagnostic laproscopy. W.B.Saunders Company, Philadelphia, USA. 2002; pp:79-82.
25. Bashir MS, Gomen PN. Mucus metaplasia of pleura. *J Clin Pathol.* 1992; 45:1030–1031.
26. Askam FB, McCann BG, Knhn C. Reactive eosinophilic pleuritis: a lesion to be distinguished from pulmonary granuloma. *Arch Pathol Lab Med.* 1977;101:187-191.