

Histopathology of virulent Newcastle disease virus in immune broiler chickens treated with IMBO®

O. G. Mohammadamin and T. S. Qubih

Department of Pathology and Poultry diseases, College of Veterinary Medicine, University of Mosul, Mosul, Iraq

(Received September 9, 2009; Accepted April 15, 2010)

Abstract

The effect of feed additive IMBO was investigated on histopathology of Newcastle disease virus in broiler chickens. Result of this study showed no differences in histological changes of virulent Newcastle disease virus in vaccinated chickens treated with IMBO compared with non-treated chickens.

Keywords: IMBO; Histopathology; Humoral immunity; Newcastle disease vaccine.

Available online at <http://www.vetmedmosul.org/ijvs>

التغيرات النسجية المرضية لفيروس مرض نيوكاسل الضارى في فروج اللحم الممنع والمعالج بالايبدو®

اميد جرجيس محمد امين و طارق سالم قبع

فرع الأمراض وأمراض الدواجن، كلية الطب البيطري، جامعة الموصل، الموصل، العراق

الخلاصة

اجريت هذه الدراسة للبحث عن تأثير الإضافة العلفية الايبدو على التغيرات النسجية المرضية لفيروس مرض نيوكاسل الضارى في دجاج فروج اللحم. اظهرت الدراسة عدم وجود اختلاف في التغيرات النسجية المرضية لفايروس مرض نيوكاسل الضارى في الدجاج الملقح المعالج بالايبدو مقارنة بالدجاج غير المعالج.

Part of the MSc thesis submitted by the first Author to the College of Veterinary Medicine, University of Mosul.

Introduction

Newcastle disease virus (NDV), is a member of the genus Avulavirus within the Paramyxoviridae family (1). It causes a highly contagious and fatal disease for, commercial broiler chickens and wild bird species. Infected birds show gastrointestinal, respiratory and nervous signs, with mortality up to 100%, depending upon pathotype of the virus (2,3). Histologic changes following virulent NDV infection include, depletion of lymphoid tissues and necrosis in various visceral organs (4). Histopathology of NDV varies and can be affected by strain of the virus and host species, the method of infection, host immune status and virus dose (5). Probiotics are defined as direct feed

microbials or microbial cell preparations with a beneficial effect on the health and well-being of the host (6). Probiotic represents one of the natural substances that influence adaptive immune responses by activating the innate immune system (7), and enhancing the systemic antibody response to some antigens in chickens (8).

Recently, the beneficial effect of Biomin®C-X (*Enterococcus faecium* + prebiotic+cell wall extract) on humoral immunity to Newcastle disease vaccine of commercial broilers was studied (9). In addition (10) found that giving *Enterococcus faecium* in the feed had insignificant effect on Newcastle antibodies test on day 37 of the rearing period and showed on day 57 as well. An experiment was conducted to investigate the effect of

Biomin®IMBO(Biomin G.T.I. GmbH., Ember AG-Austria; containing *Enterococcus faecium* 5×10^{11} cfu /kg, prebiotic, cell wall and algae extracts) on histopathology of different tissues of vaccinated broiler chickens exposed to virulent NDV.

Materials and Methods

Commercial day-old Hubbard-Flex broiler chicks were procured from a local supplier. Birds were reared in cages in separate rooms at the animal house, College of Veterinary Medicine, University of Mosul and fed ad libitum with a Hubbard-Flex recommended diet. Ambient temperature, lighting, ventilation and other environmental conditions fully met the requirements for management of Hubbard-Flex birds.

IMBO®

(Biomin G.T.I. GmbH., Ember AG-Austria, contains *Enterococcus faecium* 5×10^{11} cfu / kg, prebiotic, cell wall and algae extracts. IMBO was added to the feed free from antibiotics as recommended by the manufacturer and administered till one day before challenge.

Experimental design

One day-old Hubbard-Flex broiler chicks were randomly divided into 4 groups (30 birds/group). Group 1 was the negative control(not-challenged) and Group 2 was the positive control (challenge), Group 3 (vaccination+ challenge), and Group 4 (IMBO+vaccination+challenge).

Vaccination

Groups G3 and G4 were vaccinated with enterotropic strain (Cevac®Vitapest L) at day 7 and LaSota (Cevac® NEW L) at 21 day of age, individually by oral route, using 1 ml syringe and injected with 0.1 ml of killed ND vaccine (Cevac®Broiler NDK) at seven days of age.

Challenge virus

At 39 day of age, chickens were intramuscularly inoculated with virulent field NDV strain (obtained from the Microbiology department, College of Veterinary Medicine, Mosul University). The virus titer was determined to be $1 \times 10^{6.5}$ EID₅₀ / 0.1ml.

Histopathology

Three chickens from each group were examined microscopically at 3 and 7 days post virulent NDV inoculation. Tissue samples from bursa of Fabricius, thymus, spleen, proventriculus, duodenum, and cecal tonsils from chickens were removed. The organs were fixed in 10% neutral buffered formalin (100 ml formalin (40%), 4 g sodium phosphate monobasic, 6.5 g sodium phosphate dibasic and 900 ml D.W) and processed for paraffin embedding according to (11). The histopathological

sections (4-6 μ m) were stained with haematoxylin and eosin. The slides were coded and examined with light microscope.

Serological Tests

Blood samples were taken from chicken groups before and after challenge. Antibodies to NDV were quantified by hemagglutination inhibition test (HI) using the diluted serum-constant virus procedure according to (12).

Results

Histopathological Changes

Bursa of Fabricius

Bursal sections from negative control G1 did not reveal any histological changes. On day three post-challenge, sections from challenged groups; G2, G3 (Figure 1a) and G4 revealed reduction in size in bursal follicles, lymphocyte depletion in bursal follicles, formation of intrafollicular glandular structures with enormous proliferation of fibrous connective tissue in interfollicular space. Bursal lesions were more severe in G2 (positive control) compared with G3 and G4 groups. At seven days post-challenge, sections of bursa from groups G2, G3, and G4 revealed changes similar to those observed in 3 days post challenge.

Thymus

On day three post-challenge, tissue sections from all challenged groups except G1 showed histopathological changes. In G3 and G4 there was lymphocyte depletion in cortex and medulla. Also, thymic sections from G2 (Figure 1c) group revealed total depletion and disappearance of lymphocytes in cortex and medulla with only islands of lymphocytes remained in cortex. On day seven post-challenge, sections of thymus from groups G2, G3, and G4 revealed changes similar to those observed in 3 days post challenge.

Spleen

On day three post challenge, sections from G2, G3 (Figure 1b), and G4 groups revealed histopathologic changes irrespective of IMBO supplementation when compared with G1. Lymphocyte depletion in splenic lymphoid follicles was the most prominent lesion found, the lymphocyte depletion was characterized by fewer lymphocytes than normal. Furthermore, splenic sections from G2 group revealed total depletion and disappearance of lymphocytes in periarteriolar area. The splenic sections from G4 group which was submitted to dietary IMBO also revealed histopathologic changes similar in severity of group G3 (no IMBO supplementation). On day seven post-challenge, sections of groups G2, G3 and G4 revealed changes similar to those observed in 3 days post challenge.

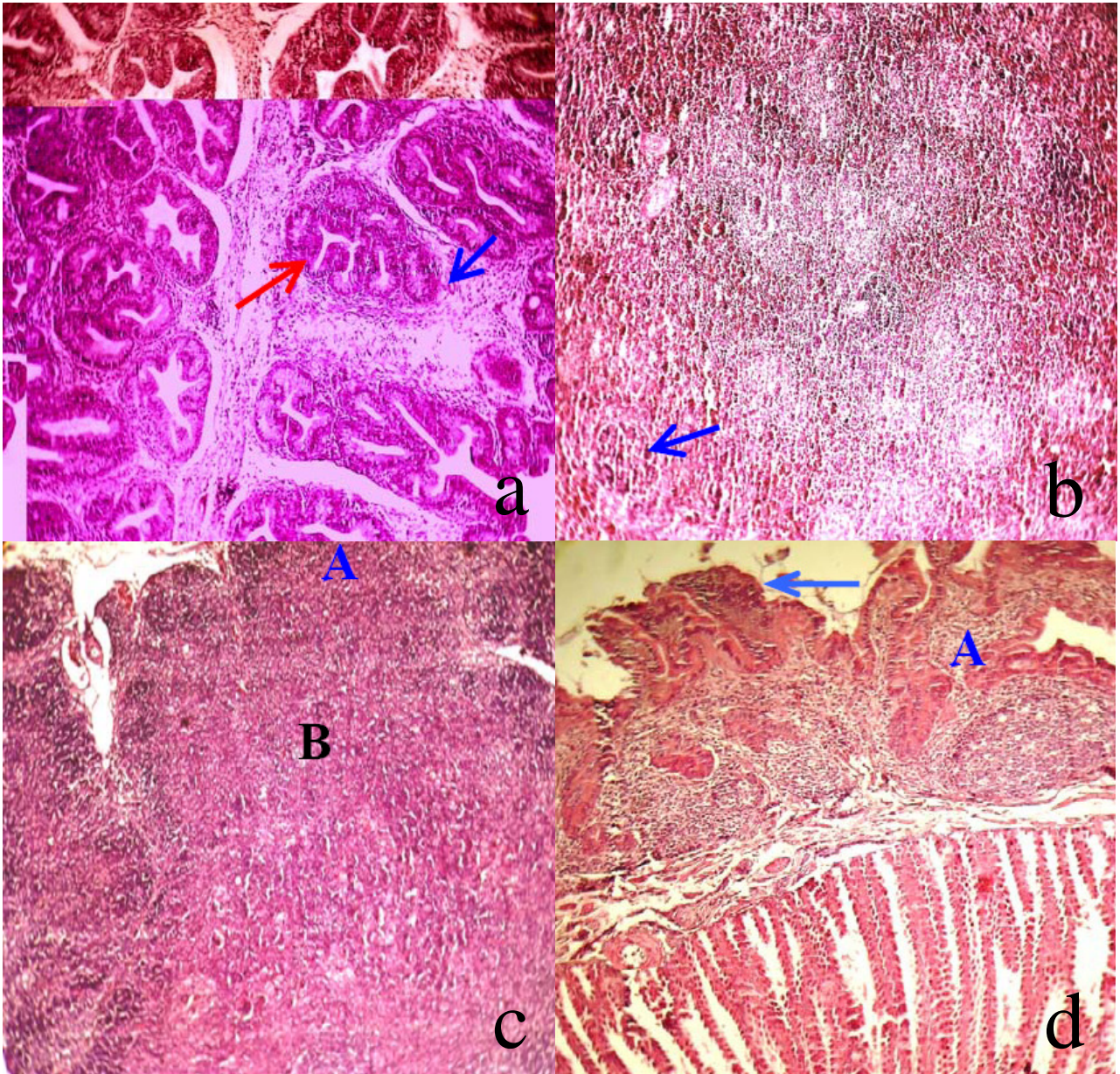


Figure 1: (a) A section of the bursa of Fabricius from G3 group 7 days post-challenge. Severe glandular transformation of lymphoid follicles (Red arrow) and thickening of interfollicular connective tissue(Blue arrow) could be noted. H&E. (90×).(b) A section of spleen from G3 group at 3 days post challenge.Lymphoid depletion(Blue arrows) could be seen. H&E. (90×).(c) A section from the thymus from G2 group at 3 days post-challenge. Severe lymphocyte depletion both in cortex(A) and Medulla(B) could be seen H&E(90×).(d) A section of proventriculus from G4 group at 3 days post-challenge. Shortening of villi(Blue arrow) and infiltration of lymphocytes in mucosa(A) could be seen. H&E.(90×).

Proventriculus

On day three post-challenge, proventricular sections from G2, G3 and G4 (Figure1d) groups mainly showed lymphocytic infiltration in lymphoid tissue, shortening of proventricular papillae and diffused infiltration of

lymphocytes in mucosa (Fig. 1) compared to the control group. On day seven post-challenge, proventricular sections from all groups revealed lymphocytic infiltration in lymphoid follicles and shortening of proventricular papillae.

Intestine

On day three post-challenge, sections from duodenum in G2, G3 and G4 groups revealed thickening and fusion of villi in comparison to G1 group. On day seven post-challenge, histopathological lesions in all groups revealed changes similar to those observed in 3 days post challenge.

Cecal tonsils

On day three post-challenge, microscopical sections from G2, G3 and G4 groups revealed lymphocyte infiltration in lamina propria as well as infiltration of lymphocytes between mucosal glands compared to G1 group. On day seven post-challenge, sections of cecal tonsils from groups G2, G3 and G4 groups revealed changes similar to those observed in 3 days post challenge.

Serology

The means of HI antibody titer (log₂) before challenge of G1, G2, G3 and G4 were 0, 0, 5.3 and 7.2, respectively. The post-challenge values were 0, not done, 10.17 and 10.5, respectively (Table1).

Table 1: Geometric mean HI antibody titer (log₂) in chickens with or without IMBO supplementation, before and after challenge with NDV.

Groups	Days After challenge		
	Before challenge	7	14
G1	0 ^{A,c}	0 ^A	0 ^A
G2	0 ^A	No	No
G3	5.333±0.42 ^B	10.17±0.48 ^B	9.667±0.56 ^B
G4	7.167±0.31 ^C	10.5±0.43 ^B	10.833±0.54 ^B

(G1) No IMBO, no vaccine and no challenge (referred to as negative control). Challenged groups: (G2) No IMBO + No vaccine (G3) No IMBO + vaccine and (G4) IMBO + vaccine, A–C Means within a column lacking a common superscript differ (P < 0.05), Values of HI titre ± SE, No: not done

Discussion

Under conditions of this study, histopathological changes occurred in all challenged groups irrespective of IMBO supplementation, which agreed with (13). The histopathology of the organs following NDV infection varies with the clinical signs and gross lesions and was greatly affected by the strain of the virus and host immunity. Despite vaccination, solid immunity does not develop against NDV. Vaccination prevents disease, but not infection. When vaccinated birds challenged with virulent ND viruses, replication and shedding of the virus occur.

The tissue sections from bursa of Fabricius, thymus, spleen, proventriculus, duodenum and cecal tonsils at 3 and 7 days post-challenge, revealed histopathological changes and were mainly characterized by lymphocytes depletion in all challenged groups. The depletion of lymphocytes is a common feature of virulent NDV strains (14,15). The histopathological changes were more prominent in G2 (positive control) group compared with G3 and G4 groups. The absence of antibody in G2 group increased pathogenicity of challenge virus, hence increased severity of histopathological changes (5). When treated with IMBO, vaccinated birds showed significantly greater antibody response to ND vaccine than that of the vaccinated birds not treated by IMBO, but it did not modify the tissue changes when exposed to challenge with virulent NDV. Histopathological changes did not differ in IMBO and non IMBO treated G4 and G3 groups. (9) also reported that feeding chickens Biomin®C-X enhanced humoral immunity to NDV, but did not ameliorate histopathological lesions in chickens challenged with virulent *Salmonella enteritidis* compared to control.

In the present study, although IMBO enhanced humoral immunity, but did not ameliorate histological changes induced by virulent NDV.

Acknowledgments

The researcher is grateful to the College of Veterinary Medicine, Department of Pathology and Poultry diseases for facilities provided.

References

1. Mayo M A. A summary of taxonomic changes recently approved by ICTV. Arch Virol.2002;147:1655-1663.
2. Alexander DJ. Newcastle disease virus and other avian paramyxoviruses, In: Swayne DE, Glisson JR, Jackwood MW, Pearson JE and Reed WM (Eds.). Laboratory Manual for the Isolation and Identification of Avian Pathogens, 4th ed. American Association of Avian Pathologists, Kennett Square; 1998. pp:156-163.
3. Alexander D J. Newcastle disease. Br Poult Sci.2001;42:5-22
4. Alexander DJ. Newcastle disease and other Paramyxoviridae infections. In: Calnek BW, Barnes HJ, Beard CW and McDougald L, Saif YM, (Ed.), Diseases of poultry, 10th ed., Iowa State University Press, Ames, Iowa; 1997. pp:541-570.
5. Alexander D J. Newcastle disease, other avian paramyxoviruses, and pneumovirus infections, In: Saif YM, Barnes HJ, Glisson IR, Fadly AM, McDougald JR and Swayne DE (Ed.). Disease of Poultry, 11th ed. Iowa State University Press, Ames;2003. pp: 63-92.
6. Nemcová R. Criteria for selection of lactobacilli for probiotic use. Vet Med.1997; 42:19-27.
7. Maldonado Galdeano C, Perdigo G. The probiotic bacterium *Lactobacillus casei* induces activation of the gut mucosal immune system through innate immunity. Clin Vaccine Immunol.2006;13:219-226.
8. Haghghi H R, Gong J, Gyles C L, Hayes M A, Sanei B, Parviz P, Gisavi H, Chambers J R, Sharif S H. Modulation of antibody-mediated immune response by probiotics in chickens. Clin Diagn Lab Immunol.2005;12:1387-1392.

9. Al-Dalo NR. Effects of probiotics on some aspects of pathology and productivity of chicken broilers. [Ph.D. Thesis]. College of Veterinary Medicine, University of Mosul. Mosul. Iraq; 2007.
10. Emad J K, Amjad H E. Study of some impact of *Enterococcus faecium* as probiotic on chick 2-Newcastle disease antibody and white blood cells. *Iraqi Journal Vet Med.*2007;31(1):78-86
11. Kiernan JA. *Histochemical and Histochemical Methods*. 3rd. ed. Butterworth / Heinemann, Oxford;1999. pp:109-113 and 200-210.
12. Mayo M A. Virus taxonomy-Houston. *Arch Virol.*2002;147:1071-1076.
13. Hamid H, Campbell RSF, Lamichhan C. The pathology of infection of chickens with the lentogenic V4 of NDV. *Avian pathol.*1990;19:687-696.
14. Brown C, King DJ, Seal B. Pathogenesis of Newcastle disease in chickens experimentally infected with viruses of different virulence. *Vet Pathol.*1999; 36:125-132.
15. Koppers GD, King D J, Seal B S, Brown CC. Pathogenesis of chicken-passaged Newcastle disease viruses isolated from chickens and wild and exotic birds. *Avian Dis.*2003;47:319-329.