
BASCOM'S OPERATION FOR CHRONIC PILONIDAL SINUS.

Jasim D. Saud* & Mazin A. Abdulla@

*Specialist Surgeon FICS, CABS, @Specialist Surgeon CABS. Department of Surgery, Basrah General Hospital, Basrah, IRAQ.

A wide variety of procedures have been described for the management of pilonidal sinus, none of which, judged by the yardsticks of disability period, complete healing and recurrence of disease, are perfect¹. Prolong disability period and complete healing of these procedures made the Karydakis, Bascom, and Lord to describe slightly different simple procedures resulting in minimal disability, good long term control and rapid return to normal activity^{2,3,4}. Bascom's procedure attacks the source of disease but does not create large unhealing wound. It is simple for out patient or day- case use and patients can return to work the following day^{5,6}. In Bascom operation incision in the midline should be avoided whenever possible. The force and condition that created the pilonidal problem will tend to disrupt a suture line. Thus, when entering the abscess cavity, one or more incision should be placed laterally away from midline¹.

Correspondence to:

Dr. Jasim D. Saud
Department of surgery, Basrah General Hospital
Basrah - Iraq

Preoperative preparation:

Informed consent was taken, shaving of area done one hour before operation.

Anesthesia

We used general endotracheal anesthesia although if available a mixture of lignocain 1%, Bupivacaine hydrochloride 0.5% with adrenaline 1:200,000 and normal saline a total 30-60 ml is adequate and provides prolonged local anesthesia.

Position: positioning the patient on the operative table in prone position with two pillows or sandbag below the buttock and chest. The separated buttocks are pulled in opposite direction with adhesive dressing to help identify all pits. Magnification and good lighting are of value.

Procedure: After cleaning of skin with 10% povidone iodine solution drapping the area. Using the tip of number 15 blade midline pits were excised, removing a minimal amount of tissue "the size of a grain of rice" "Fig. 1". Pits are excised individually as far as

feasible, these wounds extend into the abscess cavity which was then drained laterally to the most convenient side of midline by parallel incision which made 2.5 cm lateral to midline "Fig. 2". The incision is made long enough to see inside the entire cavity quite clearly. Incision length adds nothing to disability and does not delay healing. Using currette to remove granulation tissue, hair and debris "Fig. 3". Then a fibrous and fatty flap lifted deep to the midline pits,

this was achieved by incising the fibrous boundary of abscess cavity into the fat of opposite buttock, thus releasing the midline pits from the post sacral fascia. This flap was sutured to the bridge of skin between the midline pits and the lateral incision, the midline wounds then was closed with subcuticular, non-absorbable suture, Haemostasis secured using monopolar diathermy, lateral incision left open with small wick left inside "Fig. 4".

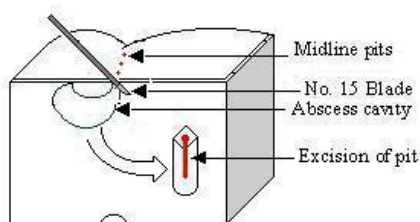


Fig. 1: Excision of midline pits

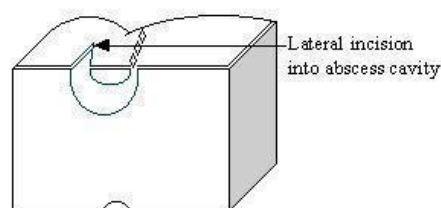


Fig. 2: Lateral drainage of abscess cavity

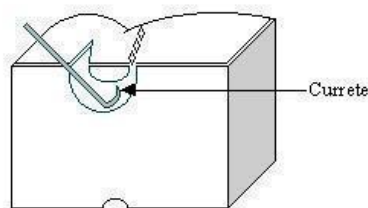


Fig.3: Currette of abscess cavity

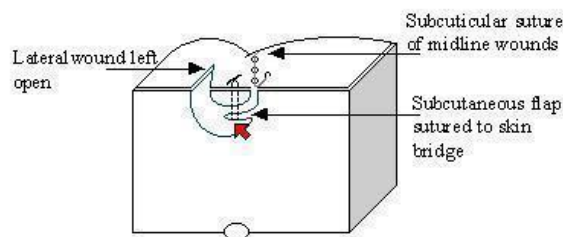


Fig.4: Suturing of subcutaneous flap to skin bridge and subcuticular closure of midline wounds

Post Operative Care: Antibiotic coverage with oral metronidazol 500 mg tid and Cephalosporin 500 mg qid for 3 days. Dressing removed in first postoperative day, patient should be encouraged to wash the wound with soap and water twice daily. Immediate return to normal sitting and activity should be suggested. Dressing to protect clothing by a mini-pad inside the underwear is useful. Sutures are

removed on 7th postoperative day and the patient should be examined every week until solid midline healing. Most patient need only one or two post operative visits.

Acknowledgements

The authors are grateful to Dr. Hashim S. Khayat for help, encouragement and comments.

References

1. Allen- Mersh TG: Pilonidal sinus: Finding the right track for treatment. *BJS* 1990; 77: 123-132.
2. Karydakis GE: New approach to the problem of pilonidal sinus, *Lancet* 2: 1414, 1983.
3. Bascom J: Pilonidal dis-
ease, origin from follicles of hair and result of follicle removal as treatment. *Surgery* 87: 567, 1980.
4. Lord PH. Anorectal problems, aetiology of pilonidal sinus. *Dis Colon Rectum* 1975;18:661.
5. Bascom J: Pilonidal dis-
ease, Long term result of follicle removed, *Dis. Colon Rectum* 1983; 26: 800,.
6. Senapati A, Cripps N.P.J. and Thomopson M.R.: Bascom's operation in the day-surgical management of symptomatic pilonidal sinus, *BJS*, 2000, 87, 1067-1070.