

---

**COMBINED THERAPY IN THE TREATMENT OF  
LARGE AURICULAR KELOID****Zuhair F Fathallah**

MB,ChB, MSc, Assist.Prof. Of Plastic Surgery, Department of Surgery, College of Medicine, University of Basrah, IRAQ.

**Introduction**

tendency to heal with an abnormal scar<sup>7</sup>.

The external ear is most prone to unfavorable wound responses such as keloids<sup>8</sup>. Earlobe keloids are common response to ear piercing, especially in females and darker skin individuals<sup>9</sup>. Keloids on the ears present several therapeutic challenges. They are common after small skin excisions and other procedures, including drainage of auricular hematomas, repair of other auricular traumas or as secondary keloid formation after prior keloid excision. Several treatment modalities are used for keloid such as surgery alone or surgery combined with other measures with varying success rates. Today there is no agreement about which treatment modality will significantly solve the problem<sup>10</sup>.

This paper report a case of a large bilateral post burn ear keloid on the helical rim which was successfully treated with surgery and intra-lesional injection of 5FU and Triamcinolon.

**Case report**

A 25 year old male worker at the domestic gas unit in Basrah Fertilizer Plant. On May11, 2005, he sustained a burn due to explosion of the gas; he had a mix degree burn of the face, ears, both forearms and both legs. After initial first aids, he was transferred to Basrah General Hospital, where he was

**K**eloid and hypertrophic scars are benign growths considered as an aberration of the wound healing process and characterized by an excess of collagen deposits<sup>1</sup>. In such cases, too much collagen is produced and degraded, result in expansion of the scar in all directions and become elevated. Keloids tend to be raised erythematous nodules with pruritus that extend beyond the margins of the original wound and have tendency to recur after excision<sup>2</sup>.

There are many theories about keloid formation, but the etiology is still unknown. Osman et al. claim that an autoimmune response to sebum trapped deep in dermis may lead to keloid formation<sup>3</sup>. A disorder of the hormone that stimulates melanocyte is one of the factors that is accused of causing keloid formation<sup>4</sup>.

The incidence of keloid formation is difficult to assess, varying from 4.5% to 16% in colored. Incidence is higher during times of hyperactivity of the pituitary gland, such as puberty and pregnancy<sup>5,6</sup>. It is more likely to see keloid or hypertrophic scarformation in the second decade of life due to more active fibroblastic phase during wound healing<sup>4</sup>.

Wounds in certain area of the body as presternal and deltoid regions, wounds that cross the skin tension lines, wounds closed under tension, and wounds in thicker skin have a greater

then closed primarily without tension with fine 5/0 PDS. The edge of the wound was infiltrated by 5FU solution peroperatively. Sutures were removed in the seventh postoperative day (Fig 2 & 3).

On Jan 2008, patient starts to feel sense of itching at the site of suturing, which raised the suspicion of recurrence.

One ml of triamcinolone (40 mg/ml) mixed with 1ml of 2% Lidocaine was injected Intralesional in each ear, followed by topical application of Betamethasone ointment for three weeks. The patient was evaluated for objective findings such as raised scar, erythema, pain and pruritus.

Four months later, the area look stable with no recurrence of itching or thickening. The patient didn't show after August 2008.

treated by closed method except the face and ears.

He had good recovery and continues his treatment as outpatient.

Four months later he starts felling itching at the margin of the ear and in the forearm, with time a thickening of the helical rim of both ears developed also in the antihelix and scapha, which later progressed to a hard rubbery keloid. The right ear shows a large size keloid, about 10 cm length and 3 cm in width, which is pedunculated with tilting of the ear due to the heaviness of the mass, but the rest were sessile. The left ear shows two small pedunculated masses at helical rim but the rest were sessile (Fig. 1).

On Nov 15, 2007 operation was done, all the keloid were excised preserving as much healthy skin as possible to avoid grafting of the area. The wound

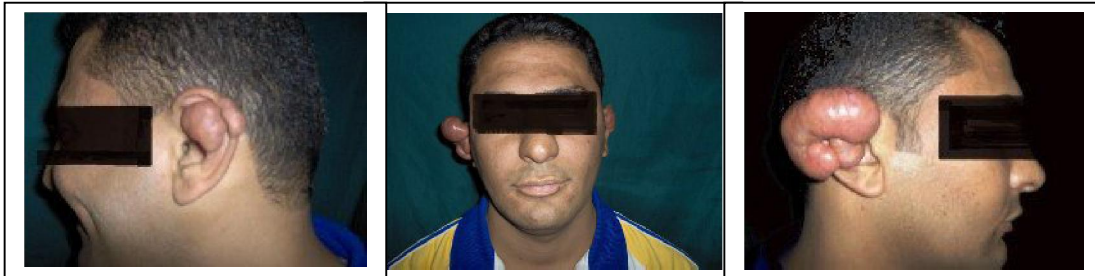

Fig.1: Pre-operative

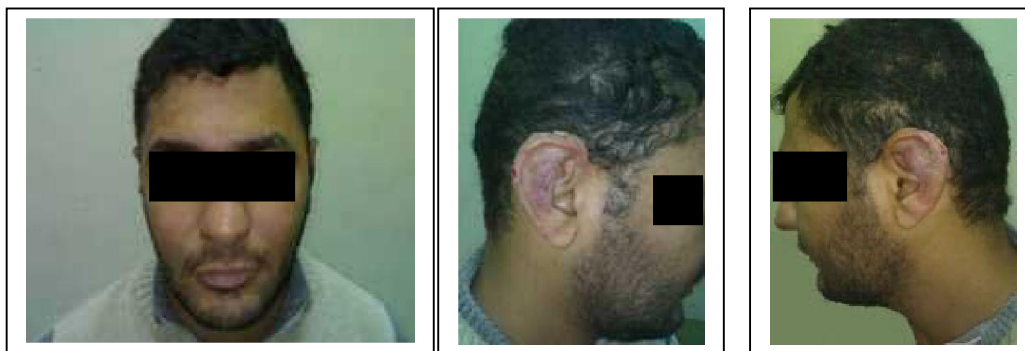
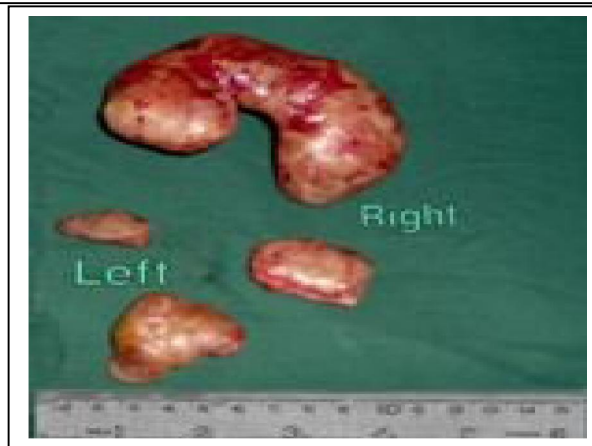
Fig.2: Post-operative

Fig.3: Excised masses.



### Discussion

decreasing the level of collagenase inhibitors, thereby increasing collagen degradation<sup>17</sup>. The preferred drug is triamcinolone acetonide with dose of 20–40 mg/ml<sup>18</sup>. Success rates increase with combination of two treatment modalities, which is surgery and triamcinolone acetonide injection, but this combination shows great variation in different studies and most of them are not satisfactory<sup>10</sup>.

Silicone gel sheet application is another treatment modality. Many theories have been postulated as to the mechanism of action of pure silicone gel sheets act in reducing keloids. Silicone gel had no effect regarding pressure, change in scar temperature, or oxygen tension within these scars<sup>18,19</sup>. A decrease in evaporative water loss, up to one-half of that of normal skin was seen, with the stratum corneum providing the fluid reservoir.

The silicone gel sheet is impermeable to water and has been described as acting like stratum corneum, decreasing any of the associated hyperemia and fibrosis, and thus leading to the flattening of the raised scar<sup>20</sup>. In the literature, silicone gel sheet is usually used directly on keloids without any combined other therapeutic agent. When silicone gel sheet is used alone, at least two to three months, should be allowed in order to obtain results<sup>21</sup>, which is a disadvantage for this treatment modality.

There is a role of hypoxia in hypertrophic scars and keloids. In scars treated with compression by the time oxygen tension

Management of earlobe keloids is still controversial. Many different treatment modalities have been employed; however, no single approach has been completely successful<sup>11</sup>.

Surgical excision of keloids without adjuvant therapy has a high recurrence rate of 55%<sup>12</sup> therefore, combination of surgery and adjuvant therapy is recommended<sup>13</sup>. Lee et al. advocate a new surgical technique for the treatment of keloid with surgery but without adjuvant therapy called it “keloid core extirpation”. They found this technique to be excellent in preventing keloid recurrence<sup>14</sup>. However, this technique produces less aesthetically acceptable results.

Radiation therapy is another therapeutic procedure, often combined with surgery. Wagner et al. reported 82.4% recurrence free response rate in male and 71.8% in female by radiation combination therapy<sup>15</sup>, no correlation was found between success rates or recurrence rates and total doses, but the response to this combined treatment is different according to the site. In head and neck its nearly 100%, in contrast to the chest which is 51% and post burn keloids had a poorer outcome than keloids developing surgical intervention and trauma. Cohen and McCoy strongly recommended that treatment with radiotherapy should be used only for keloids in the elderly and when all other methods have failed<sup>16</sup>.

Intralesional injection of corticosteroids is one of the basis of keloid treatment. It is believed that corticosteroids acts by

patient. Akoz T et al<sup>4</sup> in their series of 9 patients with ear lobe keloids, use to excised the keloid then followed by Triamcinolon actonide two weeks later, but he used silicon gel covered ear rings with one recurrence rate. In this patient no pressure was applied because of the site of the keloid over the helical rim. Sand M, et al<sup>24</sup> combined surgical excision of the keloid with designed silicon pressure splint, it was done for one patient followed later by triamcinolon injection with good result. Yenchae MW & Oberman JP<sup>11</sup> Also found that combination of different treatment modalities gives a better outcome. They used combination of compression, laser and serial steroid therapy. In conclusion, the treatment of auricular keloid is a difficult task, which needs a combined therapy of different measures, followed by careful and frequent visit of the patients to the outpatient for early detection of recurrence.

becomes normal. The mechanical pressure changes the capillary permeability during early phase of wound healing causing shortening in scar formation time. Other studies, reported that there is an increase in collagenase activity because of pressure. Long term (4–12 months) pressure treatment has been successful in preventing abnormal scar formation after burns<sup>4,22,23</sup>, due to reorientation of the collagen fibers to become parallel to the skin surface, and mature by pressure. Pressure also decreases chondroitin sulphate levels which accompany abnormal scar formation and increases hyaluronic acid levels up to normal<sup>18</sup>. The most important disadvantage of pressure therapy is that it requires a long interval of application. If the pressure is ended prematurely, lesions may recur.

Surgical excision combined with peroperative injection (infiltration) of 5FU into the wound was performed on this

## References

1. Cohen IK, Keisser HR, Sjoerdsma A: Collagen synthesis in human keloid and hypertrophic scar. *Surg Forum* 22:488, 1971.
2. Peacock EE, Jr, Madden JW, Trier WC: Biological basis for the treatment of keloids and hypertrophic scars. *South Med J* 63:755, 1970.
3. Osman AA, Gumma KA, Satir AA: Highlights on the etiology of keloids. *Int Surg* 63:33, 1978.
4. Akoz T, Gideroglu K, Akan M: Combination of different techniques for the treatment of earlobe \ keloid. *Asthetic Plast Surg*. 2002 May-June; 26(3): 184-188.
5. Cosman B, Crikelair GF, Ju DM, et al.: The surgical treatment of keloids. *Plast Reconstr Surg* 27:335, 1961.
6. Olluwansmi JO: Keloids in the African. *Clin Plast Surg* 1:179, 1974.
7. Crockett DJ: Regional keloid susceptibility. *Br J Plast Surg* 17:245, 1964.
8. Furnas DW: Complications of surgery of the external ear. *Clin Plast Surg* 17:305, 1990.
9. Salasche SJ, Grabski WJ: Keloids of the earlobe: A surgical technique. *J Dermatol Surg Oncol* 9:552, 1983.
10. Lawrence WT: In search of the optimal treatment of keloids: Report of series and a review of literature. *Ann Plast Surg* 27:164, 1991.
11. Oberman Jp, Yenchae MW: Combined therapy in the treatment of auricular keloids. *Ear Nose Throat J*, 2006 Feb; 85(2): 96- 67.
11. Yenchae MW, Oberman JP: Ear Nose Throat J. 12. Cosman B, Wolff M: Correlation of keloid recurrence with completeness of local excision. A negative report. *Plast Reconstr Surg* 50:163, 1972.
13. Murray JC: Keloids and hypertrophic scars. *Clin Dermatol* 12:27, 1994.
14. Lee Y, Minn KW, Baek RM, Hong JJ: A new surgical treatment of keloid: Keloid core excision. *Ann Plast Surg* 46:135, 2001.
15. Wagner W, Alfrink M, Micke O, et al.: Results of prophylactic irradiation in patients with resected keloid. *Acta Oncologica* 39:217, 2000.
16. Cohen IK, McCoy BJ: The biology and control of surface over healing. *World J Surg* 4:289, 1980.
17. Cohen IK, Diegelmann RF: The biology of keloids and hypertrophic scars and the influence of corticosteroids. *Clin Plast Surg* 4:297, 1977.
18. Quinn KG, Evans JH, Courtney JM, Gaylor JDS, Reid WH: Nonpressure treatment of hypertrophic scars. *Burns* 12:102, 1985.
19. Quinn KG: Silicone gel in scar treatment. *Burns* 13:33, 1987 29. Rudolf R: Wide spread scars, hypertrophic scars and keloids. *Clin Plast Surg* 14:253, 1987.
20. Davey RB: The use of silicone gel and silastic foam in burn scar management—how does it work? Presented at the 7th Congress of The International Society of Burn Injuries, Melbourne, Australia, February 1986.
21. Ohmori S: Effectiveness of silastic sheet coverage in the treatment of scar keloid (hypertrophic scar). *Aesth Plast Surg* 12:95, 1988.
22. Berry RB, Tan OT, Cooke ED, et al.: Transcutaneous oxygen tension as an index of maturity in hypertrophic scars treated by compression. *Br J Plast Surg* 38:163, 1985.
23. Brent B: The role of pressure therapy in management of earlobe keloids: Preliminary report of controlled study. *Ann Plast Surg* 1:579, 1978.
24. Sand M, Sand D, Boorboor P, Mann B, Altmeyer P, Hoffmann K: Combination of surgical excision and custom designed silicon pressure splint therapy for keloids on the helical rim. *Head & Face Medicine* 2007, 3: 14doi: 10.1186/1746- 160X-3-4.

**FOREQUARTER AMPUTATION FOR RECURRENT  
EWING'S SARCOMA OF THE HUMERUS (CASE REPORT)****Jasim Hasan Amarah**

MB,ChB, FICMS, Orthopaedic Surgeon, Samawa-General Hospital, IRAQ

**Abstract**

A 27 year old male, known case of Ewing's Sarcoma of the right lower third humerus since July 2002, he was treated by combined therapy. After 3 years, he presented with pain, pathological fracture of the upper end of the right humerus and soft tissue mass around the right shoulder. Forequarter Amputation was done to him in October 2005. The presentation and management of this patient is discussed.

**Introduction**

Forequarter amputation consists of removal of the entire upper extremity and scapula girdle in the interval between the scapula and the thoracic wall. Usually it is indicated for malignant tumours which are preformed either through anterior (Berger) or posterior (little wood) approach<sup>1</sup>. In recent years, emphasis on surgical resection in the treatment of Ewing's Sarcoma has increased; studies have demonstration reduced rates of local recurrences in surgically treated compared to radiation treated tumors. In addition to reducing the incidence of local recurrences, surgery appears to have an advantage over radiation therapy in term of long disease-free survival<sup>1,2-5</sup>.

**Case History**

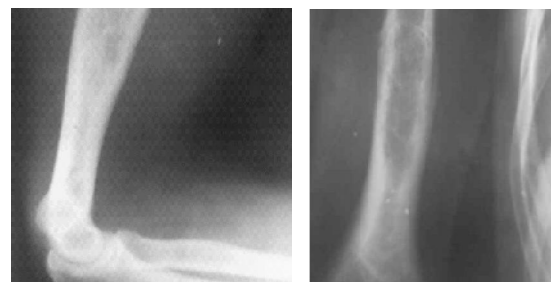
A 27 years old man from Samawa city was referred to our orthopaedic Outpatient Department on July 1<sup>st</sup> 2002 from rheumatologist. He has history of 3 months duration of pain and swelling of the right Lower end of arm. Pain worse at night and was associated with fever. Patient gives no history of trauma and he received treatment but with no

benefit. Initial examination showed diffuse swelling above the right elbow, no redness, the area was hot and tender. Movement in joints of the right upper limb was normal, peripheral pulses and sensation were intact.

Investigations; Blood tests were all normal a part from slightly raised ESR (28 mm/1hr).

**Radiological examination:**

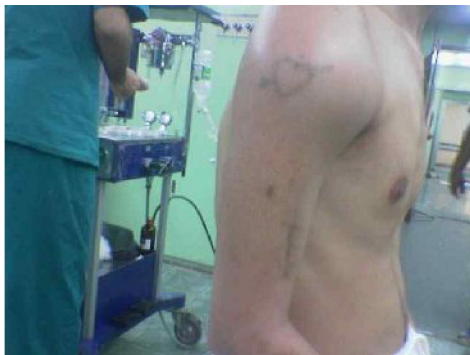Plain radiography of the right humerus and elbow showed peri-osteal reaction with loss of cortico-medullary junction at the middle and lower third of the humerus (fig.1). Chest x-ray was normal.

**Fig. 1**

Ultrasonography: Abdominal sonography was normal.

Histological examination: Biopsy was taken from affected area, the histopathological studies showed malignant round cell tumor with intervening connective tissue septa involving mainly the soft tissue and the muscle with focal area of bone involvement, a picture of Ewing's Sarcoma.

Post operatively patient was referred to oncology center in Baghdad (2002 to Aug. 2003), he received chemotherapy and radiotherapy. After that we lost till October, 9<sup>th</sup> 2005 when he consulted me again. At that time, patient had swelling of the right shoulder, pain and pathological fracture of the upper end humerus (fig.2), so he was admitted to the hospital.



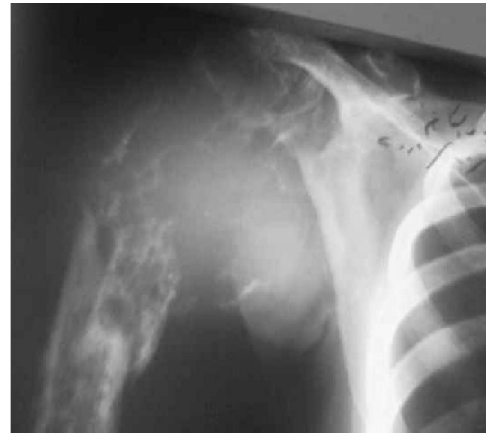
**Fig. 2**

Investigations:

Blood tests were normal apart from slightly raised ESR (30 mm/1hr) and marked high Lactate dehydrogenase (300 u/L).

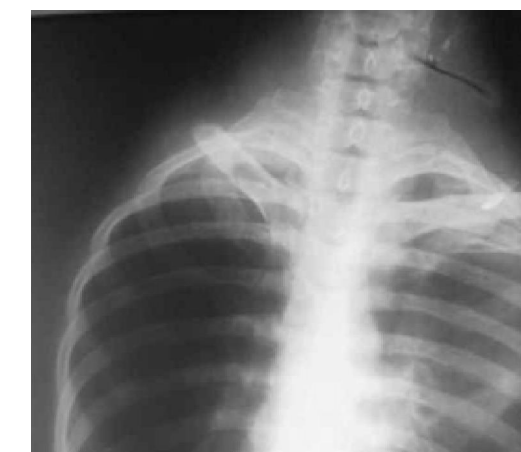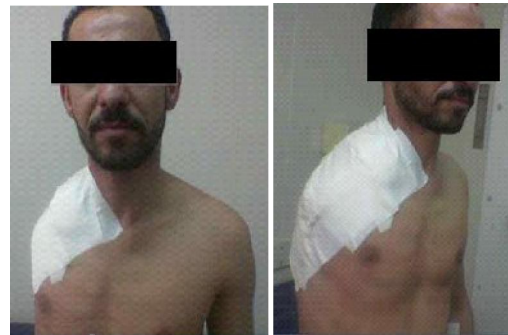Radiological examination:

Plain radiography of the right Shoulder (fig.3) showed soft tissue swelling with pathological fracture of upper end humerus and complete bone resorption. Chest x-ray was normal and abdominal sonography was also normal.



**Fig. 3**

On October, 19<sup>th</sup> 2005 and after wide discussion with the patient and his family we preformed forequarter amputation through anterior (Berger) approach. (Fig.4). Biopsy was taken and proved to be Ewing's sarcoma. The patient still alive till now, But he refused our advice about oncologist opinion post operatively.



**Fig. 4**

## Discussion

Ewing's sarcoma occurs most frequently in male in the second decade of life and presented usually with pain or mass or both. Fever, malaise, and other constitutional signs are not unusual. Radio-graphically; Ewing's sarcoma is lytic with permeative bone destruction, reactive subperiosteal reaction and large circumferential soft tissue mass. Biopsy is necessary to establish the diagnosis<sup>3</sup>

Treatment consists of chemotherapy, surgery and radiotherapy. However, as patients survive longer because of chemotherapeutic prevention of metastasis, local recurrences are being reported more frequently.

Some, advice amputation when the lesion is large in the presence of pathological fractures and in young children with distal lower extremity lesions.

Important prognostic factors are tumor stage, site (worst in the spine and pelvis), size of the tumor at presentation (Patient with tumors > 100 cm<sup>3</sup> have a worse prognosis than patients with tumor with smaller size), and lactate dehydrogenase (LDH) level (elevated LDH is associated with worse outcomes)<sup>4,5</sup>. Overall, the survival rate in patients with Ewing's sarcoma who receive combined treatment is 60%<sup>6</sup>.

In the case presented, forequarter amputation was selected for these reasons:

1. Presence of pathological fracture with complete bone resorption.
2. Large soft tissue mass around the shoulder.
3. Clinical suspicion of post radiation malignant transformation.
4. Lack of facilities to perform limb salvage or reconstruction.

## References

1. Campbell's operative orthopaedics. Volume one 11<sup>th</sup> edition 2008.
2. Ozaki T, Hillmann A, Hoffmann C, et al: significance of surgical margin on the prognosis of patient(s) with Ewing's Sarcoma. A report the cooperative Ewing's Sarcoma study cancer 1996;78: 892.
3. Apley's system of orthopaedics and fractures.2001
4. Bacci G, Ferrari S, Bertoni F, et al. Prognostic factors in non-metastatic Ewing's Sarcoma of bone treated with adjuvant chemotherapy; analysis of 359 patients at the Istituto orthopaedic Rizzoli-J.Clino oncol. Jan.2000; 18(1) 4-11.
5. Orthopaedic Knowledge Update- 6.1999
6. Orthopaedic Knowledge Update- 7.2002

**ACUTE ERYTHRO-LEUKEMIA (DI GUGLIELMO SYNDROME) IN A YOUNG ADULT IN BASRAH CITY****Zuhair Al-Barazanchi\* & Thya Al-Saadi#.**

\*MB,ChB, MSc(Hematol), Consultant Hematologist, Basrah General Hospital, [barazanchi\\_57@yahoo.com](mailto:barazanchi_57@yahoo.com). #SHO, Department of Internal Medicine, Basrah General Hospital, IRAQ.

**Introduction**

Giovanni Di Guglielmo first described erythroleukemia, a leukemia composed of purely erythrocytic precursors in 1926, and the disorder is often still referred to as acute Di Guglielmo syndrome. It is classified as an M6 subtype of acute myelogenous leukemia (AML) in the French-American-British (FAB) classification system based on morphologic and cytochemical criteria<sup>1a</sup>. Acute erythroleukemia accounts for 3-5% of all de novo AMLs and 20-30% of secondary leukemias. It is very rare in children. The incidence of erythroleukemia increases in people older than 50 years<sup>2</sup> Mazzella et al (2000) described 2 peaks, one in the seventh decade of life and a second, smaller peak in the fourth decade of life. Although rare in children, M6 AML has been reported in children from the newborn period through age 7 years.<sup>3</sup> Clinically, upon presentation, signs and symptoms of erythroleukemia are usually nonspecific and result from decreased hematopoiesis from the replacement of bone marrow by leukemic cells. This results in anemia, thrombocytopenia, and leukopenia. Patients rarely present with symptoms lasting longer than 6 months, and they are usually diagnosed within 1-3 months after the onset of symptoms. The most common presenting symptoms are as follows: fatigue or malaise, minimal-to-modest weight

loss, easy bruising, fever, bone or abdominal pain, dyspnea, meningeal signs and symptoms (very rare, only if leukemic involvement of CNS is present), diffuse joint pain (nonspecific in one third of patients).<sup>4</sup>

Physical signs include: pallor, hemorrhages, ecchymoses or petechiae, gum bleeding, epistaxis, retinal hemorrhage, fever and infection: Common sites include the respiratory tract, urinary tract, sinuses, perirectal area, and skin. hepatosplenomegaly (<25% cases)lymphadenopathy<sup>5</sup>. It can be primary or secondary. De novo (primary) cases have no identifiable risk factors. The most common predisposing factors in secondary acute erythroleukemia are as follows: myelodysplastic syndrome (MDS), ionizing radiation, thorotrast, a radiographic contrast medium used in the 1940s, is associated with increased risk of erythroleukemia (latent period of 10-30 years after exposure), prior chemotherapy, such as with alkylating agents. Rare cases of familial erythroleukemia (autosomal dominant with variable penetrance) have been described, which manifest in the sixth decade of life.<sup>6</sup>

It had been classified, using both peripheral blood smear & bone marrow aspirate smears and touch preparations from biopsy, stained with Wright-Giemsa and other histochemical stains and according to the FAB classification as acute myeloid leukemia(AML), M6 subtype<sup>1</sup>.



Peripheral blood smear: Findings may vary and include blasts (may not be present in as many as 50% of cases), macrocytosis, nucleated erythrocytes, schistocytes, and thrombocytopenia.

FAB criteria require <sup>1</sup> a 50% or more erythroid component in all nucleated cells and <sup>2</sup> at least one of the following: 30% or more nonerythroid blasts, excluding erythroblasts, or less than 30% blasts in all nucleated cells. Nonerythroid blast cells are blast I (ie, myeloblast with no cytoplasmic granules, distinct nucleoli) or blast II (ie, granules, centrally placed nucleus) and monoblast.<sup>1</sup> But nowadays, and using the WHO classification, it had been categorized with the group: acute myeloid leukemia, not otherwise categorized. The World Health Organization (WHO) proposed a new subclassification that recognizes 2 subtypes of acute erythroid leukemia:

M6a erythroleukemia is 50% or more erythroid precursors in the nucleated cells population and 20% or more nonerythroid elements (ie, myeloblasts I, myeloblasts II, monoblasts), and M6b, a pure erythroid leukemia, the erythroid component seems to be singularly involved. The erythroid component is 80% or more of bone marrow. The myeloblast count is usually less than 30%, and distinguishing the myeloblasts from primitive erythroblasts is difficult. For this reason, Auer rods are never observed in this subtype. Periodic acid-Schiff (PAS) stain findings are usually positive in erythroblasts and abnormal erythroid precursors and negative in normal erythroid precursors of all stages of maturation.<sup>7-9</sup> However, a third subset, M6c had been characterized by the mixed, (myeloblast- and proerythroblast-rich mixed variant with M6C with >30% myeloblasts and >30% proerythroblasts)<sup>10</sup>.

It should be differentiated from acute Lymphoblastic Leukemia, acute, acute

myelogenous Leukemia(M2 subtype), myelodysplastic syndrome, pernicious anemia, and besides, some cases of erythropoietin therapy (which may induce increased erythroblasts in bone marrow and, in some situations, may complicate the interpretation of bone marrow morphology)<sup>11</sup>

Lactate dehydrogenase (LDH) and uric acid elevated levels may be present. Rheumatoid factor, antinuclear antibody, Coombs test, and immunoglobulins should be evaluated. Autoantibodies and hypergammaglobulinemia have been reported in patients with erythroleukemia who have joint or bone pain. Vitamin B-12 and folate levels should be measured because severe pernicious anemia sometimes mimics acute erythroleukemia. Using flow cytometry, the leukemic cells often express both erythroid and myeloid markers. They are often positive for myeloid markers, such as CD117, CD13, CD33, and MOP, while the expression of HLA-DR and CD34 is often decreased or absent. The megakaryocytes antigens CD41 and CD61 can be positive in some cases.

Erythroid markers such as glycophorin A and transferrin receptor (CD71 and CD45) may be increased, but they are negative in many patients with erythroleukemia. Therefore, while the expression of glycophorin A and/or transferrin receptor may be helpful, the absence of erythroid antigens does not exclude erythroleukemia. The assessment of chromosomal abnormalities in patients with erythroleukemia is critical in the diagnosis and prognosis of disease. Multiple chromosomal abnormalities have been described, but none of them is specific for M6 AML.

Results from many studies demonstrate that certain chromosomal abnormalities are associated with different prognoses in all AMLs, including acute

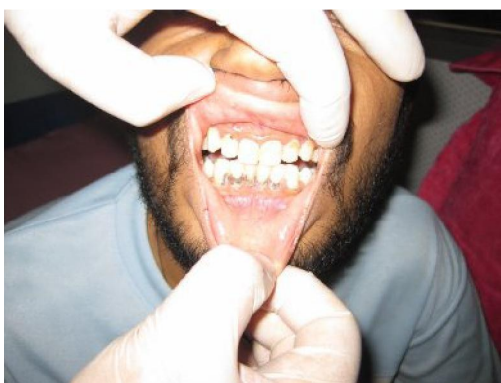erythroleukemia, as follows: Prognosis is favorable with t(8;21), inv16/t(16;16), and +14. Prognosis is unfavorable with -5/5q, -7/7q-, inv3, 11q, 17p, del20q, +13, t(9;22), or more than 2 cytogenetic abnormalities.

Prognosis is intermediate with normal karyotype and all other cytogenetic abnormalities<sup>12-14</sup>. It's a rare and heterogeneous disease with a poor prognosis<sup>10</sup>.

#### CASE DESCRIPTION

A young adult male, 29 yrs old, from Basra City presented with fever of 2 months duration with night sweating, progressive pallor, generalized weakness & exertional dyspnea. The condition did progress rapidly during the last 10 days with bone pains, blurring of vision, multiple ecchymotic patches all over the body, pyrexia, bleeding hypertrophied gums (figure 1) & bleeding from the nose.

Fig.1



On examination, the patient was extremely pale, with multiple bruises & ecchymotic spots all over the body. He was feverish, yet he was conscious. He had bilateral leg edema, gum hyperplasia. He had generalized lymphadenopathy & hepatosplenomegaly (Fig.2).

His chest X-ray showed a pleural effusion.

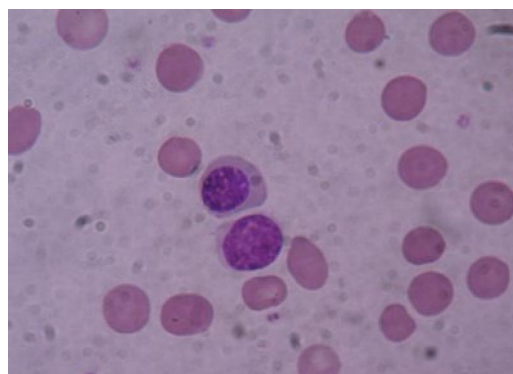
His complete blood count showed a hemoglobin concentration of 42 g/L, HCT 0.12, total WBCs  $14.3 \times 10^9/L$ , platelets  $3.0 \times 10^9/L$ , ESR 125 mm/1<sup>st</sup>

hr. Peripheral blood film shows a leuco-erythroblastic blood picture with

Fig.2

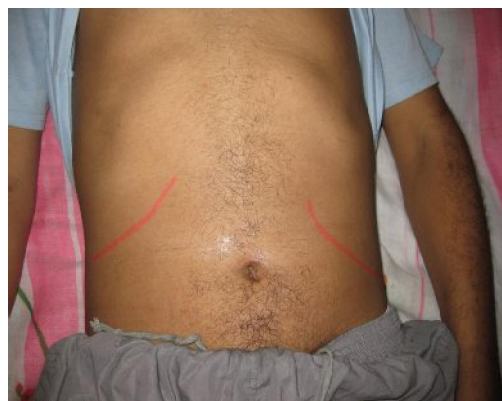

Fig.3



abnormal nasty malignant mononuclear cells of both erythroid & myeloid origin seen (Figure-3).

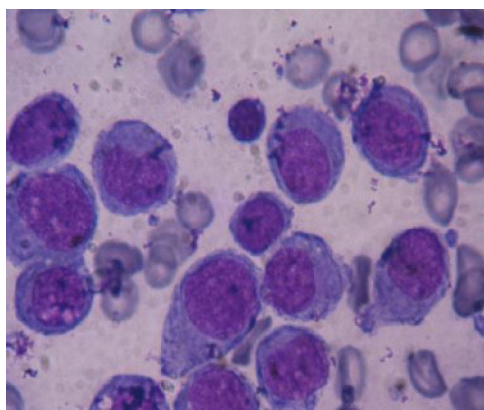
He was blood group O Rh(D) positive, Direct & indirect Coombs, tests were both negative, C-reactive protein was positive in dilution of 192 IU/L. His pleural fluid LDH was 324 IU/L, sugar 11.4 mmol/L, proteins 101 g/L, Gram stain was negative, Zeihl Nelsen stain for Acid fast bacilli was negative too.

Bone marrow aspirate & trephine biopsy were done to the patient using Salah BM aspiration needle & Jamshidi trephine biopsy needle, from right posterior iliac crest. Marrow aspirate was extremely hypercellular with almost total suppression of all normal cellular marrow elements with replacement by a mixed malignant population of cells, both of erythroid & myeloid components constituting >90%

of TMNCs. Erythroid blasts showed an abnormal morphology with binuclearity, abnormal mitosis & gigantism in many, constituting, collectively > 50 % of TMNCs. The diagnosis was proven to be of acute erythroleukemia Di Guglielmo syndrome (Fig.4,5&6).

Bone marrow trephine biopsy showed an extremely hypercellular marrow with almost total suppression of normal

Fig.4



cellular elements by malignant erythroid & myeloid precursors with open chromatin, vesicular nuclei & frequent mitoses ( Fig.6).

Fig.5

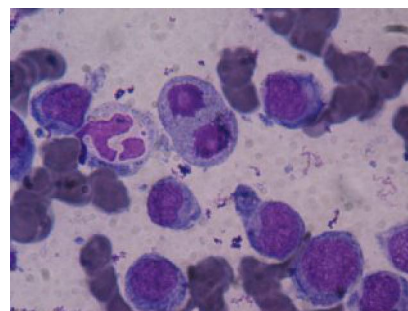
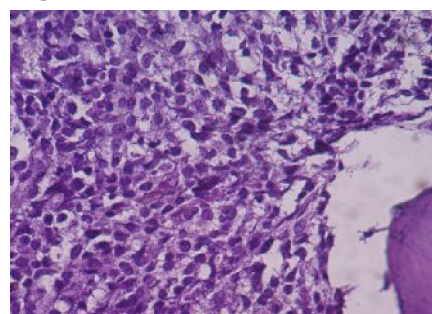


Fig.6



## References

- 1a. Mazzella FM; Schumacher HR. Acute Erythroleukemia, M6b. Archives of Pathology and Laboratory Medicine: 2000, Vol. 124, No. 2, pp. 330-331.
1. Bennett JM, Catovsky D, Daniel MT, et al. Proposed revised criteria for the classification of acute myeloid leukemia. A report of the French-American-British Cooperative Group. Ann Intern Med. Oct 1985;103(4):620-5. [Medline]
2. Beata Holkova, Kenichi Takeshita, Erythroleukemia: <http://www.medscape.com/article/199965-overview>, Updated: Jul 18, 2006
3. Mazzella FM, Alvares C, Kowal-Vern A, Schumacher HR. The acute erythroleukemias. Clin Lab Med. Mar 2000;20(1):119-37. [Medline].
4. Peterson BA, Levine EG. Uncommon subtypes of acute nonlymphocytic leukemia: clinical features & management of FAB M5, M6 and M7. Semin Oncol, 1987;14(4):425-434
5. Hetzel P, Gee TS. A new observation in the clinical spectrum of erythroleukemia. Am J Med, 1978;64:765-772
6. Mazzella FM, Kowal-Vern A, Shrit MA, et al. Acute erythroleukemia: evaluation of 48 cases with reference to classification, cell proliferation, cytogenetics, and prognosis. Am J Clin Pathol. Nov 1998;110(5):590-8. [Medline]
7. Vardiman J. Proposed WHO Classification of Neoplastic Diseases of Hematopoietic and Lymphoid Tissues (Acute Leukemias and Myeloid Disorders). Am J Surg Path. 1997;21:114-21
8. Greer JP, Baer MR, Kinney MC. Acute myeloid leukemia in adults: in Wintrobe, Clinical Hematology, 11<sup>th</sup> Ed, 2004, Ch 79, pp 2097-2142
9. Harris NL, Jaffe ES, Diebold J, et al. World Health Organization classification of neoplastic diseases of the hematopoietic and lymphoid tissues: report of the Clinical Advisory Committee meeting-Airlie House, Virginia, November 1997. J Clin Oncol. Dec 1999;17(12):3835-49. [Medline]
10. Kowal-Vern A, Mazzella FM, Cotelingam JD, et al. Diagnosis and characterization of acute erythroleukemia subsets by determining the percentages of myeloblasts and proerythroblasts in 69 cases. Am J Hematol. Sep 2000;65(1):5-13. [Medline]
11. Sultan C, Deregnacourt J, Ko YW, et al. Distribution of 250 cases of acute myeloid leukemia (AML) according to the FAB classification & response to therapy. Br J Haematol, 1081; 47: 545-551
12. Cuneo A, Van Orshoven A, Michaux JL, et al. Morphologic, immunologic and cytogenetic studies in erythroleukaemia: evidence for multilineage involvement and identification of two distinct cytogenetic-clinicopathological types. Br J Haematol. Jul 1990;75(3):346-54. [Medline].
13. Leith CP, Kopecky KJ, Godwin J, et al. Acute myeloid leukemia in the elderly: assessment of multidrug resistance (MDR1) and cytogenetics distinguishes biologic subgroups with remarkably distinct responses to standard chemotherapy. A Southwest Oncology Group study. Blood. May 1 1997;89(9):3323-9. [Medline].
14. Willman CL. The prognostic significance of the expression and function of multidrug resistance transporter proteins in acute myeloid leukemia: studies of the Southwest Oncology Group Leukemia Research Program. Semin Hematol. Oct 1997;34(4 Suppl 5):25-33. [Medline].
15. Santo FPS, Faderl S\*, Garcia-Manero G, et al. Acute Erythroleukemia: An Analysis of 108 Patients Treated with Cytarabine-Containing Regimens at the M.D. Anderson Cancer Center Saturday, , the 50<sup>th</sup> ASH Annual Meeting & Exposition online program and Abstracts. December 6, 2008, 5:30 PM-7:30 PM

# Basrah Journal of Surgery

Bas J Surg, September, 15, 2009

## Editorial

---

- DO WE NEED CONTINUOUS MEDICAL EDUCATION?.....1  
*Thamer A Hamdan*

## Leading Article

---

- MEDICAL ERRORS AND RESPONSIBILITY OF THE PHYSICIAN.....3  
*Thamer A Hamdan*

## Review Articles

---

- NUTRITION IN GASTROINTESTINAL SURGICAL PATIENTS.....10  
*Majeed H Alwan*
- OPEN ABDOMEN, WHAT IS NEW IN ITS SURGICAL MANAGEMENT? .....16  
*Ghassan A A Nasir*

## Original Articles

---

- IS IT SAFE NOT TO LIGATE THE INFERIOR THYROID ARTERY DURING SUBTOTAL THYROIDECTOMY? ,,.....20  
*Ahmed D Chiad & Mazin H Al-Hawaz*
- THE ROLE OF CONVENTIONAL ULTRASOUND IN THE ASSESSMENT OF THYROID NODULES IN AL-SULAIMANYIA TERRITORY .....34  
*Amer A M Ali, Abdulkadir H Hasan & Tahir A Hawrami*
- Can Cystic Artery Cauterization be safely Practiced in Laparoscopic Cholecystectomy?.....45  
*Falih M Ali, Safwan A Taha & Adnan Y Al-Adab*
- AURICULAR RECONSTRUCTION BY COSTAL CARTILAGE GRAFT IN BASRAH PROVINCE....49  
*Jabir R Hameed*

## Articles

---

- EMERGENCY PERIPARTUM HYSTERECTOMY: EXPERIENCE AT BASRAH MATERNITY AND CHILDREN HOSPITAL.....56  
*Haifa Al-Shaheen*
- NON RADIO OPAQUE FOREIGN BODIES IN ORTHOPAEDIC PRACTICE.....64  
*Jasim Hasan Amarah*
- HEMOSTASIS WITH SURGICEL FOR TONSILLECTOMY: A PILOT STUDY.....69  
*Abdulmohsen E Hussain & Yaseen H Ali*
- INFLUENCE OF BODY MASS INDEX ON THE INCIDENCE OF PRETERM LABOUR.....72  
*Khilud Salim Al-Salami, Zaineb T Alyasin & Ragad Nasir Hussain*
- LAPAROSCOPIC LIVER HYDATID ENDOCYST-ECTOMY (INITIAL EXPERIENCE OF FOURTEEN CASES).....78  
*Abdulhadi M Mohamad, Salim M AL-Bassam & Hamed Boserwel*
- MANUAL PHACOEMULSIFICATION IN BASRAH; THE FIRST SERIES FROM IRAQ.....81  
*Sajid Al-Assady*
- EVALUATION OF THE CLINICOPATHOLOGICAL CHARACTERISTICS OF LABIAL MUCOCELE.....88  
*Ali Darweesh AL Sarraj & Riad G Al-Tae*

## Case Report

---

- COMBINED THERAPY IN THE TREATMENT OF LARGE AURICULAR KELOID.....93  
*Zuhair F Fathallah*
- FOREQUARTER AMPUTATION FOR RECURRENT EWING'S SARCOMA OF THE HUMERUS....97  
*Jasim Hasan Amarah*
- ACUTE ERYTHRO-LEUKEMIA (DI GUGLIELMO SYNDROME) IN A YOUNG ADULT IN BASRAH CITY.....100  
*Zuhair Al-Barazanchi*



رقم الإيداع في دار الكتب والوثائق ببغداد (621) لسنة 1995

!!