

---

## **CAN CYSTIC ARTERY CAUTERIZATION BE SAFELY PRACTICED IN LAPAROSCOPIC CHOLECYSTECTOMY?**

**Falih M Ali<sup>\*</sup>, Safwan A Taha<sup>@</sup> & Adnan Y Al-Adab<sup>#</sup>**

<sup>\*</sup>MB,ChB, Iraqi Board of Surgery Candidate. <sup>@</sup>MB,ChB, CABS, Prof. of Surgery, Dept. of Surgery, Basrah College of Medicine. <sup>#</sup>MB,ChB, FRCS, Assist. Prof. of Surgery, Dept. of Surgery, Basrah College of Medicine, IRAQ.

### **Abstract**

This study aimed to evaluate the safety and efficacy of cystic artery cauterization in laparoscopic cholecystectomy (Lap.Chole.) and to outline possible complications and limitations that might arise from adoption of such approach.

Cauterization of the cystic artery was adopted as the principal mean of securing the cystic artery in the course of standard lap.chole. The technique was applied on 46 cases of laparoscopic cholecystectomy. Patients with adhesions in the triangle of Calot and/or very short cystic arteries were excluded from the study. All patients were followed up for 2-3 weeks.

We didn't get any serious complication in form of: major bile duct injury, right hepatic artery injury, post operative hematoma.

Mean operative time was 35 minutes. Out of the 46 patients who had cystic artery cauterization we had the following complications: one patient developed intra-operative bleeding from the cystic artery in the course of its skeletonization which was controlled by prompt clipping, another patient developed rather severe bleeding from a torn cystic artery and we converted him to open cholecystectomy.

Forty one patients were females (age range 18-48 years) and 5 were males (age range 33-49 years). Complications occurred exclusively in females.

Apart from conversion due to other causes, the incidence rate of conversion due to bleeding from cystic artery during clipping and cauterization was 1.5%, 2% respectively.

---

### **Introduction**

Cholecystectomy was established as the surgical treatment for cholelithiasis in 1882 by Carl John. Open cholecystectomy became the gold standard for treatment of cholelithiasis till the introduction of laparoscopic cholecystectomy in 1980 when a lot of doubts were raised regarding its safety but it was Philip Mouret from France who performed the 1st human laparoscopic cholecystectomy in 1985<sup>1,2</sup>.

Orientation to the anatomy and anatomical variations in the biliary system is very important to be familiar with structures in vicinity of dissection for safe cauterization and/or clipping during lap. chole.

The cystic artery comprises the principal blood supply for gall bladder. It is usually a branch of the right hepatic artery in more than 90% of the cases. Course of the cystic artery may vary, but it is nearly always found in the hepatic cystic triangle; the area bounded by the cystic duct, common hepatic duct and liver margin (triangle of Calot)<sup>3</sup>.

Also the cystic duct has many variations and its union with the common bile duct is surgically important<sup>4</sup>.

There are different methods for controlling cystic artery; the primary method for controlling of cystic artery in laparoscopic cholecystectomy is clipping by using metallic clips<sup>5</sup>, the ligation

system allows safe closure of vessel not exceeding 7mm in diameter. The main advantage of ligasure is to perform laparoscopic cholecystectomy without clips and so reduce clip related complications<sup>6</sup>, recent studies goes with using bipolar coagulation scissor at the same time of tissue dissection with coagulation and division of the artery without changing the instrument, this procedure is safe without after bleeding and less time consuming<sup>7</sup>. Ultrasonic energy has recently been used for surgical coagulation and cutting of cystic artery without post operative bleeding<sup>8</sup>.

### **Patients and methods**

This study was carried out in Al-Sader Teaching Hospital and Al-Mosawi Private Hospital in Basrah, Iraq, from January 2005 to June 2006. It included 46 patients all of whom were diagnosed clinically as symptomatic gall stone disease and were proved by ultrasonic examination. Patients who underwent lap.chole were prepared pre-operatively with general investigations that included Haemoglobin level, fasting blood sugar, renal function tests, liver function tests, bleeding profile, Chest X ray and ECG. All patients were followed up for 2-3 weeks post-operatively by outpatient visits.

A standard technique for laparoscopic cholecystectomy was practiced apart

from cauterization of artery. We however, adopted a 3-port access routinely but required a fourth port in 11 patients due to difficulties during the procedure including gall bladder empyema, severe adhesions and the need for sufficient caudal traction of infundibulum for safe dissection of the triangle of Calot as shown in table I.

During dissection we used the hook electrode. Carefully explore the tissues to the patient's left hand side of the cystic duct. The artery should gradually emerge as the cystic duct did. Once the artery has been identified, dissection was performed towards the gall bladder as dissecting towards the right hepatic artery is more dangerous<sup>9</sup>.

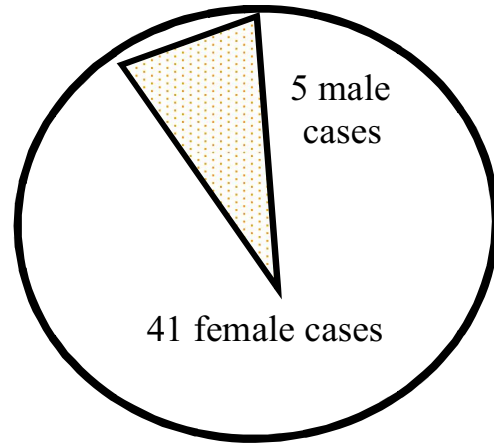
Dissecting was stopped when there was a skeletalised 20mm section of cystic artery or when there is enough space behind the artery for the jaws of the clip applicator (10mm). The hook electrode run up and down behind the cystic artery to make sure that it is completely free. If the length of cleared cystic artery is less than 20mm, dissection was further carried towards the gallbladder to increase the available length of artery. If 10mm of the artery is available, cauterization of cystic artery was practiced by using diathermy coagulation of whole exposed length of the artery with division by the scissor or the hook<sup>9</sup>.

**Table I: Number of ports and indications.**

Total cases	3 ports	4 ports	Indications
46	35 (76%)	11 (23.9%)	1- Severe adhesions. 2- Empyema. 3- Sufficient traction

**Results**

Forty one patients were females (age range 18-48 years) and 5 were males (age range 33-49 years) as demonstrated in table II and fig.1. Complications occurred exclusively in females.



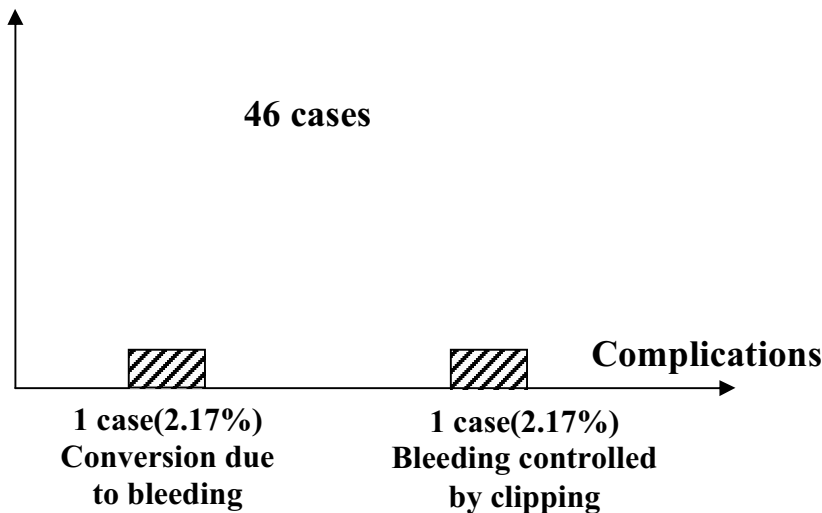
**Fig. 1: Gender distribution.**

**Table II: Age distribution.**

Age	No. Of cases
< 20 years	2 (18 years)
20 – 30 years	4
30 – 40 years	12
40 – 50 years	28
Total	46

From the 46 cases of laparoscopic cholecystectomy, 2 cases developed complications in relation to cystic artery cauterization as shown in fig.2. The mean time needed for lap.chole (measured from the time of introduction of the first ports to skin closure) was 35 minutes (range=25-45 minutes). The

main cause of per-operative bleeding in the course of cystic artery skeletonization was avulsion of the cystic artery. The incidence of conversion in our study was 2.17% while in clipping of cystic artery was 1.5%, so there was no significant difference (p value 0.772).



**Fig. 2: Incidence and types of complications.**

**Discussion**

Biliary diseases constitute a major portion of digestive tract disorder. Among these gall stone disease is the most common biliary pathology. It is

important to have some idea about the individual patient risk when obtaining informed consent. Identifying potential difficulties is especially important in a

teaching hospital when open cholecystectomy has become a rare procedure. The most important step in laparoscopic cholecystectomy is optimal dissection of the triangle of Calot before any clipping and/or division of any structure<sup>5</sup>.

We didn't observe cystic artery anomalies of any sort apart from anomalies related to the cystic duct itself (short and low insertion cystic duct).

During skeletonization of cystic artery there must be acceptable length for cauterization by the hook to get optimal coagulation of the artery and then divided by the hook.

The mean time consumed for cystic artery coagulation is less than that need for clipping and for economic purposes we spare the use of clips and clipper (the mean time in our study was 35 min, while in lap.chol with cystic artery clipping was 50 min ).

In certain situations there was no sufficient place for applying clips due to increase incidence of biliary and hepatic

artery injuries so it's more safe to coagulate the artery.

In comparison to other study of cystic artery cauterization in lap.chole that had been done in France by Ajay Anand, B.S. Pathania and Gurjeet Singh, showing the complication rate during cystic artery cauterization (2.84%) in form of per operative bleeding in 5 cases (three of them controlled by clipping and other end with conversion to open)<sup>4</sup>, while the complication rate in our study was 3.34%) which means that there is little difference between the two studies.

The conversion rate due to bleeding from cystic artery in lap. Chole. in form of clipping is (1.5%) in comparison with (2%) in form of cauterization<sup>9,10</sup>.

We concluded that apart from conversion due to other causes, the incidence rate of conversion due to bleeding from cystic artery during clipping and cauterization was only (1.5%), (2%) respectively so we can apply cystic artery cauterization when there is sufficient length of the artery.

## References

1. Douglas O. Olsen, Historical Overview and Indications for cholecystectomy. In: Bruce V. Macfadyen, Jr., MD, et al., Editors. Laparoscopic surgery of the Abdomen .New York: Springer 2004;10:71
2. Gai H, Thiele H. Sonographische Selektionskriterien für die laparoskopische Cholezystektomie. Chirurg 1992; 63:426– 431.[Medline]
3. John Karani, The Biliary Tract.In: David Sutton MD, FRCP, FRCR. Textbook of Radiology and Imaging.7th ed. Churchill Livingstone: 2003;24:711.
4. Ajay Anand, B.S. Pathania, Gurjeet Singh, Conversion In Laparoscopic Cholecystectomy:An Evaluation Study Vol. 9 No. 4, 2007,pp171-174.
5. Margret &John Hunter, F. Charles Brunicaudi, Shwartzs principles of surgery; 8th edition 2005.
6. A. Shmiyeh, P. schren, L.tulipan, P.vattay, S.bogner, W.wayand, A new bipolar feedback controlled sealing system for closure of the cystic duct and artery, Surg.Endos, 2002 16: 812-813.
7. J.P. Eitenmueller, E. Volckmann, Clinical experience with bipolar multifunctional coagulation scissors in laparoscopic surgery,Surg. Endosc (2008) 22:421–425.
8. Leas ET, Siaas P, , Tsimoviannis EC, Jabarin M, Glantzounis G Stefanaki-Nikou S, Laparoscopic cholecystectomy using ultrasonic activated coagulations shears, Surg. Laparosc. 1998, 8(6);421-4.
9. International Journal of surgery, Basic laparoscopic cholecystectomy ,cystic artery dissection, 18-2-2008.
10. Peters JH, Krailadsiri W, Incarbone R, et al. Reasons for conversion from laparoscopic to open cholecystectomy in an urban teaching hospital. Am J Surg 1994; 168:555 -558[Medline]