

STUDY OF PATHOLOGIC CHANGES IN COLLIBASILOSIS OF MEDITERRANEAN SEAGULL (*Loras melonocephalus*) AT BASRAH PROVINCE

Majeed S. K. ¹, Ali, M. A. ², Shehan, N. A. ², Suzan, A. A. Al-Azizz³

¹55 Desborough Road, Hartford- Huntingdom, Cambridgeshire, PE 29 1 SN, England,

²Department of Anatomy , College of Veterinary medicine,University of Basrah,Basrah,Iraq

³Department of Microbiology, College of Veterinary medicine,University of Basrah,Basrah,Iraq

(Received 16 November 2011,Accepted 14 February 2012)

Keywords; Hepatic granuloma, seagull birds, macrophages.

ABSTRACT

Hepatic granuloma is a chronic inflammatory disease characterized by a granulomatous reaction. A total of (5) seagull birds were collected from different locales at Basrah city under this study with clinical signs anoxia and maciatuion.

The pathological sections showed many changes; presence of scattered granuloma in the parenchyma mostly midzonal and in periportal regions. Those granulomas consist of macrophages with central necrosis, some of those macrophages were with epithelial appearance or what is called epithelioid cells.

In conclusion the hepatic granulomas under this study suspected to be caused by infection with *E. coli*.

INTRODUCTION

Migratory birds can disperse microorganisms across international borders and myriad pathogens harmful to poultry or other vertebrates have been associated with such birds (1, 2). They transmit avian influenza virus (AIV), avian pneumovirus, Newcastle disease virus, duck plague virus, *Chlamydomphila psittaci*, *Campylobacter* and *Salmonella* (1, 3, 4,

5, 2). Migrating birds generally include species that cyclically cross one or more national boundaries and use a variety of habitats including wetlands, marshes and other water bodies (6).

Hepatic granuloma is a chronic inflammatory disease characterized by a chronic inflammatory reaction characterized by granuloma formation or what is called granulomatous reaction with accumulation of macrophages and/or epithelioid cells, which may fuse to form multinucleated giant cells. The hepatic granulomas typically have a surrounding rim of lymphocytes and fibrous tissues. The etiology of some hepatic granulomas in birds is well known. It could be due to bacterial, fungal, protozoal, or helminthic infection (7). The presence of these pathogens in the liver is usually through systemic infections that might preferentially colonize the liver. Persistence of these pathogens infecting the liver can lead to granulomatous inflammation with different gross lesions and histopathologic patterns depending on the causative agent. This review describes the etiology, clinical signs, pathological changes, and diagnosis in a wide variety of diseases associated with hepatic granuloma in birds in which the detection of granulomatous inflammation is an aid in the differential diagnosis(8). (9) confirm that hepatic granuloma which caused by *Escherichia coli* in liver of pheasant.

Granuloma can be present in the liver in a variety of conditions. Although the granuloma themselves rarely cause structural liver damage, it is important to identify the underlying systemic disease since it might have prognostic and therapeutic implications. Careful consideration of associated clinical symptoms and characterization of the appearance and localization of the granuloma within the liver usually leads to a definitive diagnosis (10).

The aim of this study is to study the pathology/ pathogenesis of Colibacillosis and its importance to other species of animals.

MATERIALS AND METHODS

Birds on Study (seagull):

A total of (5) seagull birds were collected from different locales at Basrah city.

Clinical Signs:

The clinical signs in all samples were recorded.

- Processing:

After the birds slaughters, the liver were washed many times in distilled water and then dissected and put in 10% formalin.

For histological section, the procedure by (11) were done, and slides were stained with Haematoxyline and Eosin.

RESULTS

The most clinical signs in all samples was anroxia and maciatiun.

- Macroscopic Examination:

Post mortem findings were mainly in liver, which appeared as whitish grayish scattered nodules of 3-5 mm. up to 1 cm. in diameter.

- Microscopic Examination:

The microscopic findings of liver slides showed presence of scattered granuloma in the parenchyma mostly midzonal and in periportal regions. Those granulomas consist of macrophages and multinucleated giant cells with central necrosis as in (Fig: 1, 2), a dilated portal vein with higher magnification was shown in (Fig. 3).

A periportal granuloma consisting of macrophages and fibrous capsule with central coagrlntive necrosis of cellular debris and necrotic materials were shown in (Fig. 4).

some of those macrophages were with epithelial appearance, therefore, it was consider as epitheloid cells at the periphery there were lymphocytes (Fig: 5, 6).

Most of the above granuloma were enclosed by fibrous capsules.

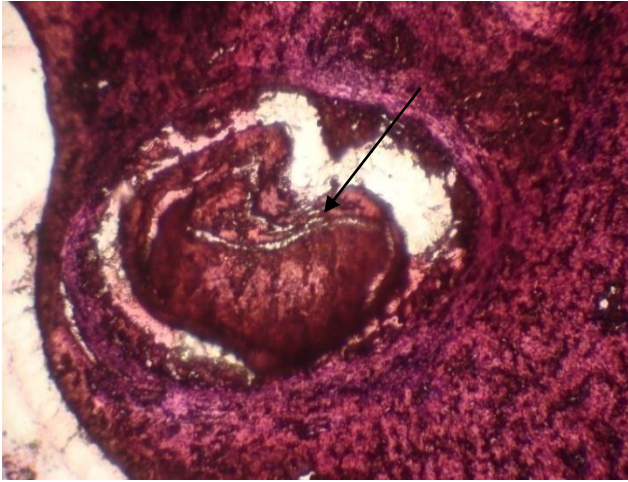

Fig (1): liver of seagull with parenchymal granuloma of macrophages, multinucleate giant cells and fibrous capsule with central necrosis. E & H.. X 10.

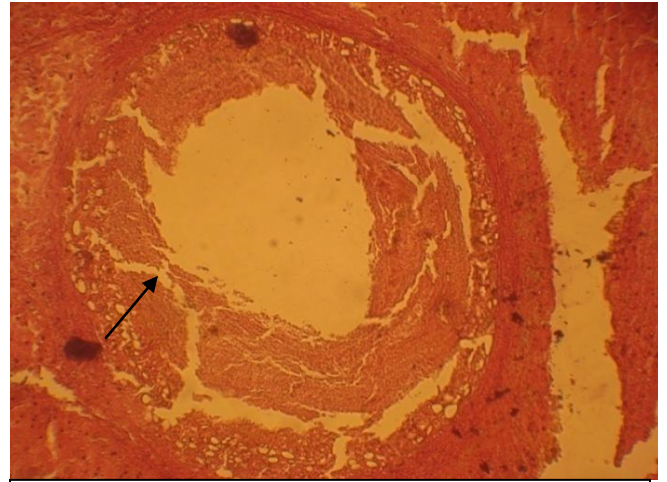


Fig (2): liver of seagull with parenchymal granuloma of macrophages and fibrous capsule with central necrosis. E & H. X 10.

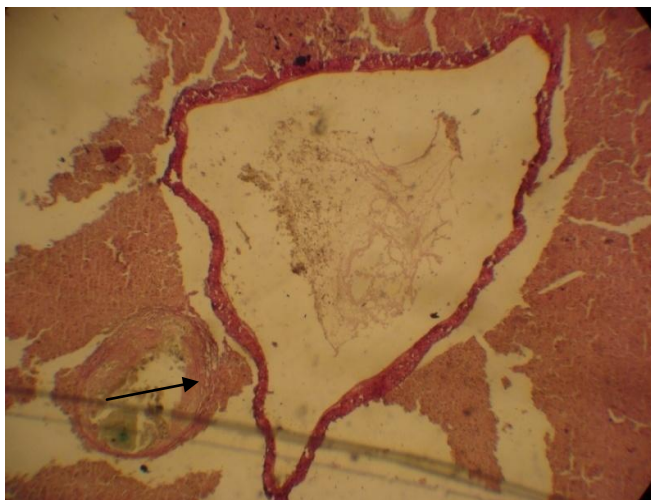


Fig (3): liver of seagull with dilated portal vein with higher magnification. E. & H. X 10.

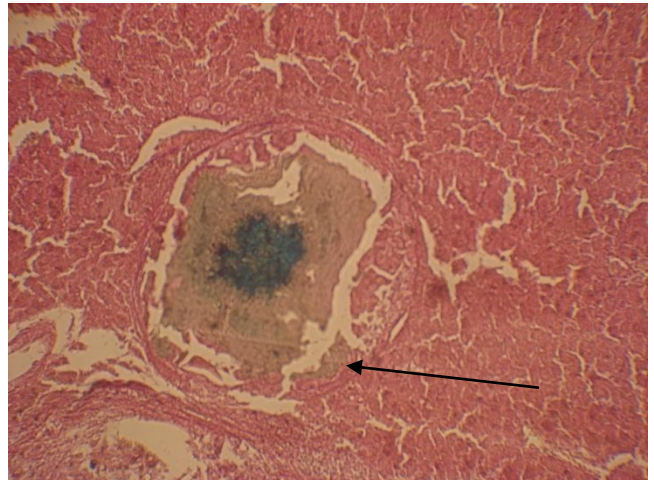


Fig (4): Liver of seagull with periportal granuloma consisting of macrophages and fibrous capsule with central necrosis of cellular debris and necrotic materials. E & H. X 4.

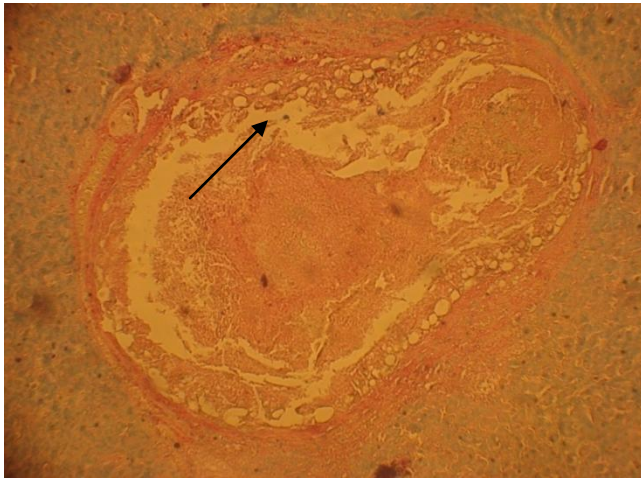


Fig (5): Liver of seagull a granuloma with central necrosis lined by macrophages and multinucleate giant cells enclosed by fibrous capsule infection with Colibacillosis. E. & H. X40.

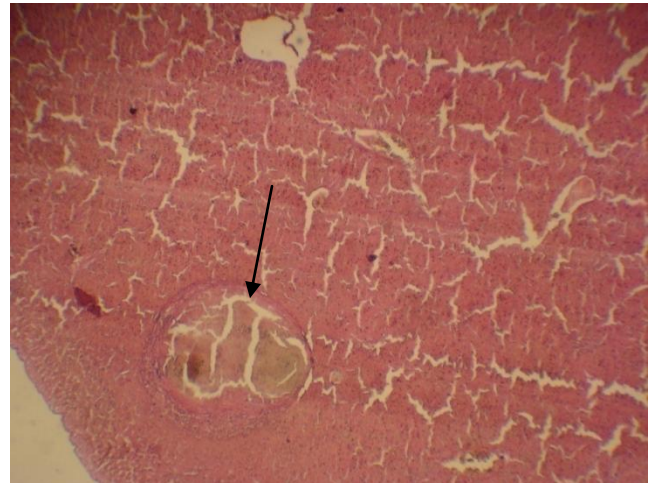


Fig (6): Liver of seagull with two granuloma of macrophages, multinucleate giant cells and fibrous capsule with central necrosis. E. & H. X 10

DISCUSSION

A granuloma is a circumscribed lesion that forms as a result of an chronic inflammatory reaction in body tissues. It is characterized by compact and organized collection of macrophages or epithelioid cells, with a surrounding rim consisting of lymphocytes and fibroblasts. The lesions are distinct from nearby uninvolved tissue, as reported by (12). Early in the development of the granuloma, lesions may appear as punched-out clusters of histiocytes or lymphocytes (8). The granuloma evolve with stimulation of mononuclear cells from a variety of cytokines. Activated macrophages are transformed to resemble epithelial cells (referred to as epithelioid cells), which

The cells within the granuloma are capable of secreting a variety of proteins. As an example, epithelioid cells from patients with sarcoidosis secrete lysozyme, collagenase, and angiotensin converting enzyme (ACE). Elevated serum levels of ACE are characteristic of active sarcoidosis (13).

The histological features of the granulomas and their location may be helpful for narrowing the differential diagnosis. Four histological variants of hepatic granuloma have been recognized, the first two of which are most common in the United States (14).

The above hepatic granulomas suspected to be caused by infection with *E. coli*, which was reported in pheasants by (9).

دراسة التغيرات الامراضية في النوارس المصابة بالكوليباسلوسيز في مدينة البصرة

صالح كاظم مجيد،² محمد عباس علي،³ ناظم عزيز شيحان،⁴ سوزان عبد الجبار عبد العزيز

¹ أستاذ زائر- فرع الامراض وامراض الدواجن،

²، فرع الانسجة والتشريح، كلية الطب البيطري، جامعة البصرة، البصرة، العراق.

³ فرع الاحياء المجهرية، كلية الطب البيطري، جامعة البصرة، البصرة، العراق.

الخلاصة

يعد الورم الحبيبي الكبدى من الامراض الالتهابية المزمنة والتي تكون ضمن التفاعلات الالتهابية. بلغ العدد الكلي للطيور المفحوصة (5) نوارس برية حيث جمعت من مناطق مختلفة من مدينة البصرة مع تسجيل العلامات السريرية المتمثلة بأضطراب تنفسي.

اظهر الفحص النسيجي للمقاطع عدة تغيرات منها وجود ورم حبيبي في المنطقة الحشوية وخاصة الوسطى والمحيطية من الكبد. أن الاورام الحبيبية مكونة من خلايا ملتهمة مع تنخر مركزي، بعض الملتهمات اظهرت تشابه بالخلايا الطلائية.

كأستنتاج نهائي يكون الورم الحبيبي الكبدى المشخص في هذه الدراسة هو بسبب اصابة النوارس بالايشرشيا القولونية.

REFERENCES

- 1- Hubalek, Z. (1994). Pathogenic microorganisms associated with free-living birds: A Rev. Acta Scient. Natural. Brno, 28: 1-74.

- 2- Hubalek, Z. (2004). An annotated checklist of pathogenic micro-organisms associated with migratory birds. *J. Wildlife Dis.*, 40: 639-659.
- 3- Palmgren, H.; Sellin, M.; Bergstrom, S. and Olsen, B. (1997). Enteropathogenic bacteria in migrating birds arriving in Sweden. *Scand. J. Infect. Dis.*, 29: 565- 568.
- 4- Wobeser, G. A. (1997). Avian cholera, In: *Diseases of wild waterfowl*. 2nd Edn., New York, Plenum Press, pp: 57-69.
- 5- Alexander, D. J. (2000). A review of avian influenza in different bird species. *Vet. Microbiol.*, 74: 3-13.
- 6- UNEP (2005). [www.http//colibasillosis in birds](http://colibasillosis in birds).
- 7- Supartik, I. K.; Toussaint, M. J.; Gruys, E. (2006). Avian hepatic granuloma, a review. *Vet. Q.*,28(3):82-89.
- 8- Supartika, I. K. E.; Van der, A. B. J. H. Stroom-Kruyswijk, C. M. J. M.; Toussaint, A, and Gruys, A. D. E. (2007). Necrotizing granulomatous hepatitis in slaughtered broilers.. *Avian Dise.*, 51(2):632-638.
- 9- Majeed, S. K.; Cooper, J. and Al-Daraji, A. M. (1988). Collibacilliosis in Pheasants. *Iraqi Vet. Med. J.*, 2 (24).
- 10- Flamm, S.; Chopra, S. and Bonis, P. A. L. (2011). Hepatic granulomas. Up To Date.
- 11- Luna, A. (1968). *Animal tissues technique*. 3th ed. Black well Publ., Pp: 1270.
- 12- Majeed, S. K. (1972). The paratuberculouse inflammatory process in goat. Ph. D. thesis, Fac. Of Vet. Med., Univ. of Utracht, Holand.
- 13- Ishak, K.G.(1995). Granulomas of the liver. *Adv. Pathol. Lab. Med.*, 8:247.
- 14- Maddrey, W. C. (1989). Granulomas of the liver. In: *Schiff's Diseases of the Liver*, 8th Edition, Schiff, ER, Sorrell, MF, Maddrey, WC (Eds), Lippincott-Raven, Philadelphia Pp:1572.