

MORPHOLOGICAL AND HISTOLOGICAL STUDY FOR THE KIDNEYS OF COOT BIRD (*Fulica atra*)

Abbas Lafi Batah

Department of anatomy , college of veterinary medicine, university of Basrah,Basrah,Iraq

(Received 24April 2012,Accepted 3June 2012)

Keywords; kidneys, medulla, tubules

ABSTRACT

Present study were carried out on ten adult males of coot bird, for determinate the histological structure of kidneys. The results were showed that each kidney consisted of three parts, a large cranial (mean of its length $28\pm 0.15\text{mm}$ and its width $13\pm 0.08\text{mm}$), a small caudal (mean of its length $13\pm 0.07\text{mm}$ and its width $4\pm 0.08\text{mm}$) and a middle part (mean of its length $30\pm 0.08\text{mm}$ and its width $7.5\pm 0.10\text{mm}$).

Histological results were showed that the kidneys consisted of cortex and medulla, the cortex made up the majority of the kidney and composed of large and small renal corpuscles, each renal corpuscle consisted of Bowman's capsule and glomerulus. The proximal convoluted tubules were lined by simple cuboidal epithelium. The distal convoluted tubules and collecting tubules were lined by simple cuboidal epithelium. The macula densa was situated at vascular pole of glomerulus in close to distal convoluted tubules.

Medulla of kidney was composed of thin and thick segment of henles loop and collecting ducts and these structures were lined by simple cuboidal epithelium. The collecting ducts continued to form the papillary ducts which lined by simple columnar epithelium.

Key words: kidneys, coot bird, nephrons ,glomerulus ,histological.

INTRODUCTION

Kidneys conserve fluid components necessary to maintain homeostasis while ridding the body of metabolic waste products, as well as excess water and electrolytes, in the form of urine. An understanding of the structure the kidney and especially the

interrelation ship of the renal tubules and renal vasculature, is essential to appreciate the diverse function of kidney (1)

Avian kidneys normally consist of three divisions cranial, middle and caudal lobe, and each lobe consist of smaller lobes (2, 3). The avian kidney is unique in structure among vertebrate kidney in having two types of nephrons those with and without a loop of henle (looped and loopless respectively)(4).the loopless nephrons stay with in the cortex while the looped nephrons extend from the cortex and into discrete medullary areas called medullary cones with each cone, the number of loops of henle decreases as tip of the con is approached (5).The two nephrons also called the cortical (reptilian) type in more numerous and lacks a loop of henle ,it is located in the cortex ,while the other nephrons called medullary (mammalian) type ,it has a loop of henle and it is less numerous ,which extend into medulla(6).

Due to vital function of kidneys so the major aim of this examine to study the histological structure of kidneys in coot bird *fulica atra*

MATERIAL AND METHODS

Ten adult males of coot bird *fulica atra* were collection from local hunters in mayssan province .The birds were transported to the laboratory of anatomical and histological department in college of veterinary medicine .

The birds were killed after anesthesia by intramuscular injection of a mixture of ketamin and diazepam at dose 25 and 5 mg/kg of body weight (7).The simple exploratory laparatomy procedure was done to remove the kidneys from the synsacrum The overall length and width of cranial lobe, middle lobe and caudal lobe were measured by using vernier instruments . The kidneys preserved in 10% buffered neutral formalin ,the kidneys were left in the fixative for 24 hours, the fixed tissues were washed by water and dehydrated in an ascending series of graded concentration of alcohol (70%,80%.90%,100%) with a time interval of 2 hours for each stage then cleared with xylene for about 2 hours ,infiltrated with paraffin wax for 2 hours and embedded in paraffin block, sections of 5 microns thick were then using a microtom ,mounted on glass slides in the presence of egg albumin, then dried at room temperature. They were stained

with hematoxyline and eosin, dehydrated and cover slipped using permount as the mounting medium and viewed under alight microscope (8)

RESULTS AND DISCUSSION

Morphological study

Morphological results showed that the kidneys of coot bird consisted of three parts, a large cranial, a small caudal, and a middle part fig(1). these result was conflicted with(4,9) whom mentioned that the kidneys of quail and sparrows consisted of a large caudal, a small middle and a cranial part. The kidneys extended from the caudal margin of lungs to the caudal end of the synsacrum. The dorsal half of the kidneys laid embedded deeply in the synsacral fossa fig(2) The result is similar to that described in rock, collard dove and owl(10).

Histological study

The result showed that the kidneys consisted of the cortex which made up the majority of the kidney with only a small portion as medulla. The cortex contain the reptilian type of nephrons without loop of henle while the medulla contain the mammalian type of nephrons with loop of henle fig(3,5) this result agreement with(11) who referred that the cortex of kidney in a nectarivorous bird formed 90% of total volume while medulla formed 2% , also conducted with (12) who mentioned that the kidney of mallard duck consist of a very large cortex and relatively small medulla.

The cortical nephrons has smaller renal corpuscles than the medullary nephrons, the large renal corpuscles of medullary nephrons lie close to the medulla, each renal corpuscles consisted of an outer Bowman's capsule separated by Bowman's space from a centrally located glomerulus, the glomeruli consisted of tightly packed central core of mesangial cells fig(3,4) this result similar to (13) whom mentioned that the renal corpuscle in kidney of pekin duck consisted of bowman's capsule and glomerular capillaries were characterized by a large central mass of mesangial cells.

The proximal convoluted tubules were lined by simple low cuboidal epithelium .The distal convoluted tubules were also lined by simple cuboidal epithelium , the lumen of the distal convoluted tubules were more clearly defined fig(3,4) this result was agreement with (10) whom mentioned that proximal and distal convoluted tubules of kidney in rock, collard dove and owl consisted of a cuboidal epithelium and the luminal surface

area of the proximal convoluted tubules enhanced by a thick layer of microvilli forming a brush borders.

The macula densa occurs at the initial part of distal convoluted tubules fig(4) this result similar to (14) whom referred that the macula densa occurs at the point of the initial part of the distal convoluted tubules and were closely situated to the vascular pole of glomerulus in both Rhod Island and white leghorn chicken, also this result agreement with (15) who mentioned that the macula densa in the kidney of domestic fowl and japans quail is attached to the vascular pole of glomerulus at the distal convoluted tubules.

Collecting tubules were occurred in the peripheral part of the cortex ,they lined by pale cells and cuboidal shape and were intermediate in size between the proximal and distal convoluted tubules fig (3) The result similar to (16) who was referred that the collecting tubules in the kidney of starling bird lined by cuboidal cells and connected to collecting duct.

Medullary nephrons tubules were arranged in a sequential manner. Thick and thin segments of henles loop were separated by collecting ducts ,thick segments were restricted to the peripheral of the medullary cones and surrounded by a ring of collecting ducts, the thick and thin segment consisted of simple cuboidal epithelium ,the medullary collecting ducts continued into a distal papillary duct which consisted of a columnar epithelium fig(5) this result agreement with (17) who showed that the avian kidney has a similar parallel arrangement of the loops of henle and collecting ducts in the medullary cones and these structures were lined by cuboidal epithelium.

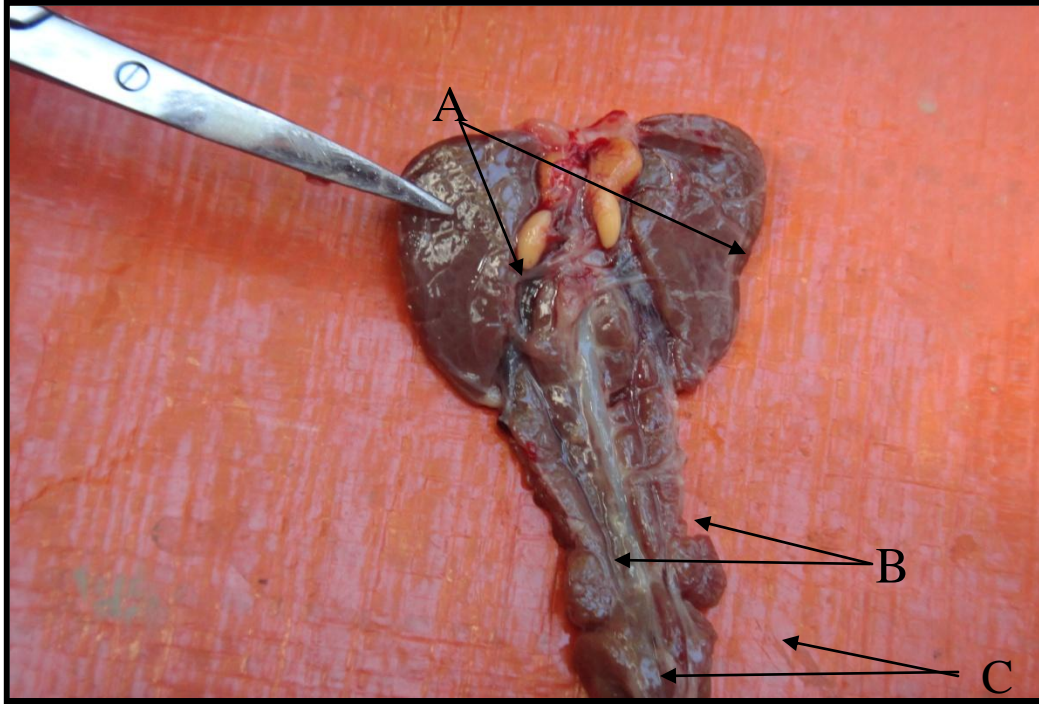
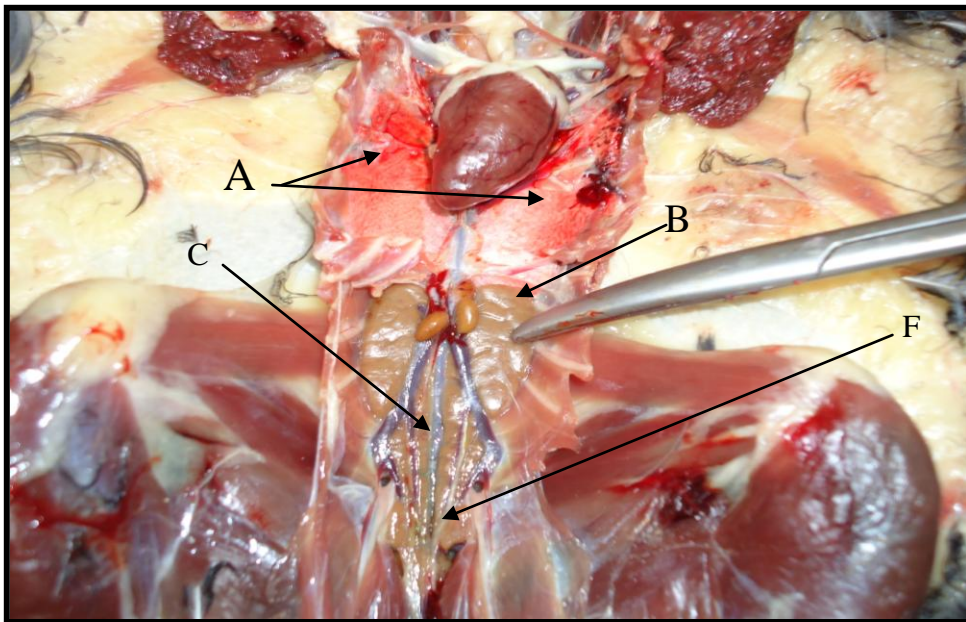
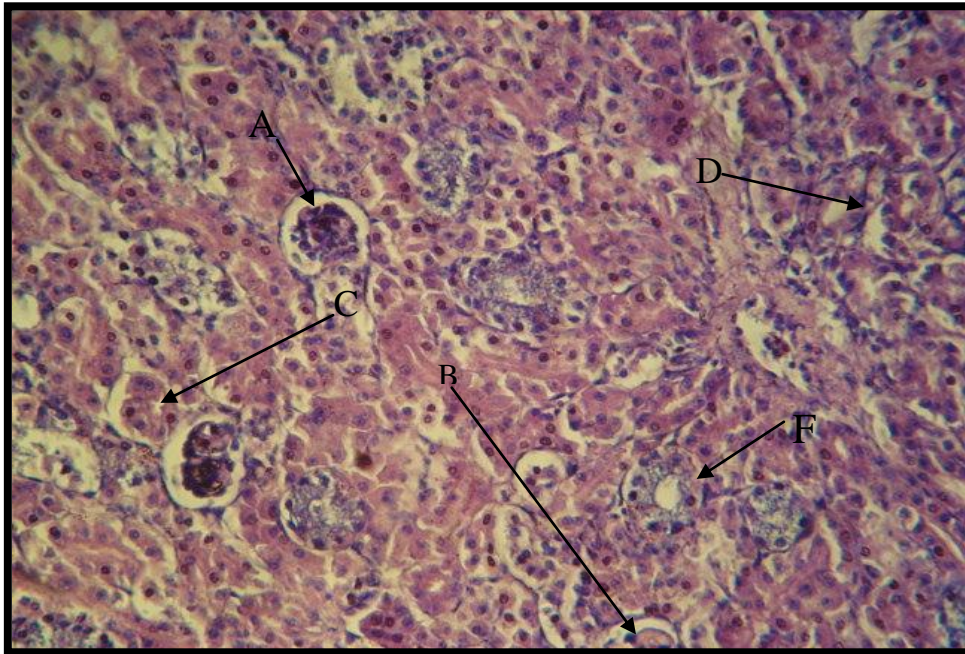
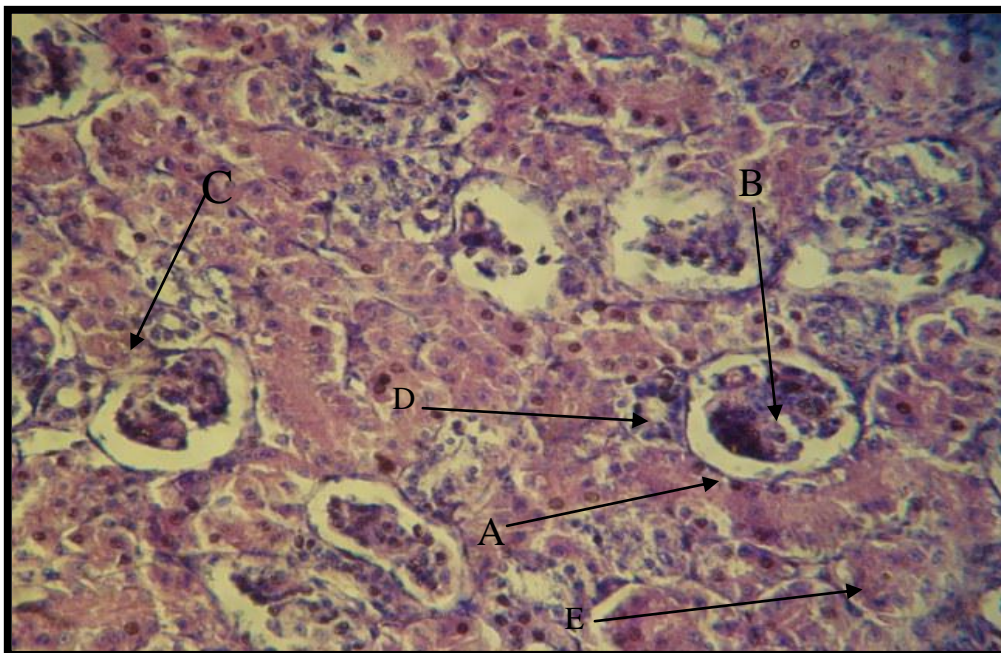


Fig (1) kidney of coot bird. A. cranial part. B. Middle part. C. Caudal part





Fig(3) Transverse section through the cortex showing A-large renal corpuscle B-small renal corpuscle. C- proximal convoluted tubule. D-distal convoluted tubule .F-collecting tubule 400X H & E



Fig(4) section through the cortex showing A-Bowman's capsule .B-glomerulus C-macula densa .D-distal convoluted tubule. E- proximal convoluted tubule 800x H&E

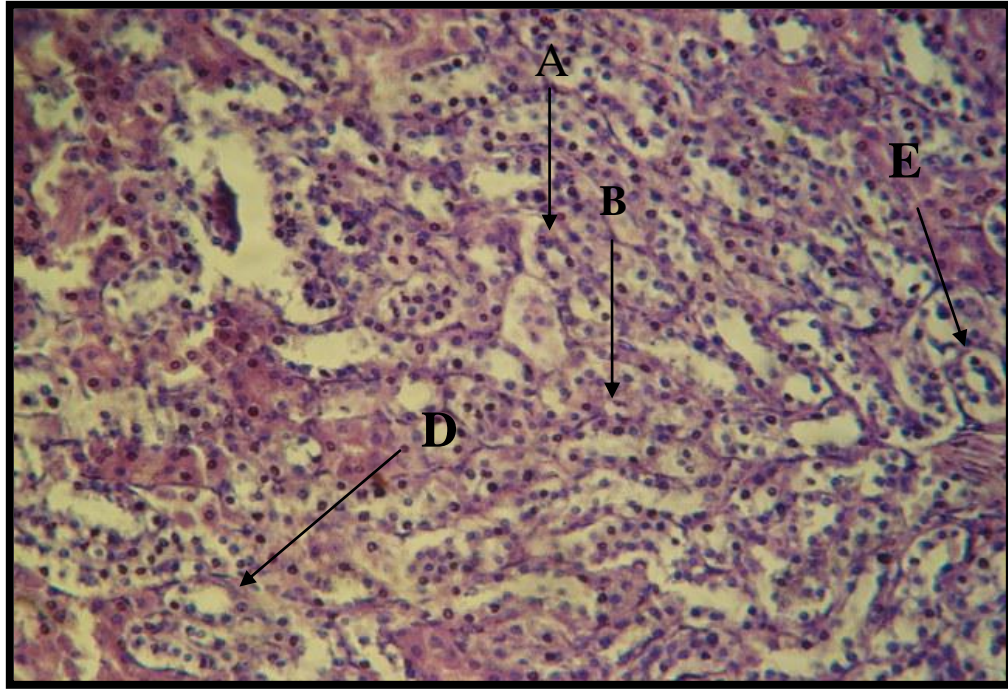


Fig (5) section through medulla, A. Thick segment of henles loop, B. thin segment of henles loop, D. collecting duct, E. papillary duct. 400X H & E

دراسة شكلية و نسيجية للكلى في طائر الغرة

عباس لافي بطاح

فرع التشريح كلية الطب البيطري، جامعة البصرة، البصرة، العراق.

الخلاصة

أجريت الدراسة الحالية على عشر ذكور من طائر الغرة لتحديد التركيب النسيجي للكلى.

أظهرت الدراسة بان كل كلية تتكون من ثلاثة أجزاء، أمامي كبير (معدل طوله 0.15 ± 28 ملم ومعدل عرضه 13 ± 0.08 ملم)، خلفي صغير (معدل طوله 13 ± 0.07 ملم ومعدل عرضه 4 ± 0.8 ملم) وجزء وسطي (معدل طوله 30 ± 0.8 ملم ومعدل عرضه 7.5 ± 0.10 ملم).

أظهرت النتائج النسيجية بان الكلية تتكون من القشرة والللب. تشكل القشرة الجزء الأكبر من الكلية وتتألف من كريات كلوية كبيرة وأخرى صغيرة، كل كرية كلوية تتكون من محفظة بومان والكبيبة. تبطن النبيبات الملتوية الدانية والنبيبات الملتوية القاصية والنبيبات الجامعة بالظهارة المكعبة البسيطة. تقع البقعة الكثيفة عند القطب الوعائي للكبيبة بالقرب من النبيبات الملتوية القاصية.

يتألف للـب الكـلية من القطـع الرقيقـة والسـميكة لعـروة هنـلي والقنـوات الجامـعة، تبطن جميع هذه التراكيب بالظهارة المكعبة البسيطة، تستمر القنوات الجامعة لتكون القنوات الحلمية التي تبطن بالظهارة العمودية البسيطة.

REFERENCES

- 1-Dellman,H.D and Eurell,J.(1998).Text book of veterinary histology. fifth Edition ,lippincott William and Wilkins, Philadelphia pp:213-217.
- 2-Johnson,O.W and Skodhauge,E.(1975).Structure-functural correlations in The kidneys and a observation of colon and cloacal morphology in asturalin birds.j.anat 12o:495-505.
- 3-Richardson,K.C;Wooller,R.D and Casti,G.(1991).The relative size and Asymmetry of kidneys in passerine birds from asturalia and north America .j.anat.175:181-185.
- 4-Braun,E.J and Dartzler,W.H.(1972).functional of mammalian-type and Reptilian-type nephrons in kidneys of desert quail.Am.J.physiol 222:617-629.
- 5-Layton,H.E.(1986).Distribution of henles loops may enhance urine Concentrating ability Biophysiol.J.49:1033-1040.
- 6-Bacha,W,J.and Wood,G.L.M.(1990).Avian urinary system in color atlas of Veterinary histology.William and Wilkins.Waverlly company . Hong Kong.pp:164-174.
- 7-Schindala,M.K(19990,Anesthetic of affect of ketamine ,ketamine with Diazepam chicken .iraqi,vet.J.Sci.12:261-265.
- 8-Luna,L.G.(1968).Manual of histological staining methods of armed force Institute of pathology.third edition.New York,U.S,A.PP:39-110.
- 9-Casotti,G.and Braun,E.J.(2000).Renal Anatomy in Sparrows from Different Enviroments.J.morphol.243:283-291.
- 10-Nabipour,A;Alishah,E.and Asadian,M.(2009).Some histological and Physiological feature of avian kidney.J.Appl.Anim.Res.36:195-198
- 11-Casotti,G; Beuchat,C.A.and Braun,E.J.(1998).Morphology of the kidney

- In a nectarivorous bird the Anna's humming bird *calypte anna*
J.Zool.London.244:175-184.
- 12-Warui,C.N.(1989).Light microscopic of the kidneys of fourteen avian
Species ,J.Anat.162:19-31.
- 13-Susan,M; Snelgrone-Hobson,P.V.V;Rao,p and Bhtnagar,M.K.(1988).
Ultra structural alterations in the kidneys of pekin ducks fed
Methylmercury,can.J,Vet.Res.52:89-98.
- 14-Islam,Kh.N;khan,M.Z.I;Siddiqui,M.S.I;Islam,M.R;Lucky,N.S;Hossain,
M.K and Adhikary,G.N.(2004).The anatomical studies of the
Kidneys of Rode island Red(RIR) and white leghorn(WLH)
Chicken during their post anatal stages of groth and
Development, international.J.Poult,Sci.3(5):369-372
- 15-Ogaw,M.and Sokabe,H.(1971).The macula densa site of avian kidney
Cell and tissue research 12o:29-36
- 16-Nicholson,J,K.(1982).The microanatomy of the distal ,collecting tubules
And collecting ducts of the starling kidney.J.Anat.134:11-29.
- 17-Casotti,G;Lindbery,K.K and Braun,E.S.(2000).Functional morphology of
The avian medullary cone.Amer.J,Physiol.243:283-291.