

## **Histo –pathological changes in the three aquatic birds intestines due to parasitic infestations in the Bahr AL- Najaf depression Iraq**

التغيرات النسجية – المرضية في أمعاء ثلاثة أنواع من الطيور المائية نتيجة أصابتها بالطفيليات في منخفض بحر النجف , العراق

سليم خضير/ماجستير في الطفيليات - كلية العلوم – جامعة الكوفة  
د. هيثم محمد حمادي العوادي أستاذ مساعد- كلية التربية للبنات/جامعة الكوفة  
د. عبد الهادي صلال محمد أستاذ مساعد هيئة التعليم التقني المعهد التقني الطبي/كوفة

### **Abstract:**

The present study carried – out on thirty aquatic birds including *Tringa nebularia* , *larus argentatus* and *phalacrocorax carbo* . Among ten *T nebularia* two aquatic birds were infected with (cestoda) *Anomotaenia microrhyncha* and *Trichocephaloides megalalocephala* And among ten *l argentatus* three aquatic birds were infected with *paricterotaen porosa* while among ten *phalacrocorax carbo* one bird was found to be infected with *haloparaxis crassirostris* the infected birds were observed fibrosis surrounded the worm in the mucosa of small intestine (duodenum) also all infected aquatic birds were revealed the ulceration , destruction degeneration and necrosis in most epithelial lining of the small intestinal villi , beside decreasing in number or some time lost of the goblet cells , also the damage was extended in to intestinal glands , these pathological effects which led to dysfunction of small intestines in the infected birds , and emaciation was appeared on the infected aquatic birds in this present study , also inflammatory cells infiltrate in mucosa and submucosa of infected small intestines .

### **الخلاصة :**

نفذت الدراسة الحالية على ثلاثين طيراً مائياً شملت الطيطوى خضراء الساق *Tringa nebularia* والنورس الفضي *larus argentatus* والغاق *Phalacrocorax carbo* مابين عشرة طيور من الطيطوى خضراء الساق سجلت أصابتهن بالدودة الشريطية *Trichocephaloides megalalocephala* , *Anomotaenia microrhyncha* وهناك ثلاث أصابات بالدودة الشريطية *paricterotaen porosa* من بين عشرة طيور للنورس الفضي *Larus argentatus* بينما سجلت إصابة واحدة بطفيلي *haloparaxis crassirostris* بين عشرة طيور للغاق . أظهرت كافة الطيور المصابة بالطفيليات تليف في مخاطية الأمعاء الدقيقة (الأثني عشر) يحيط بالدودة الشريطية وحدوث تقرح (Alceration) , تحطم (Dystraction) , اضمحلال (Atrophy) , تنخر (Necrosis) , في معظم الخلايا الظهارية المبطننة لزغابات الأمعاء الدقيقة , علاوة على ذلك انخفضت أعداد الخلايا الظهارية المبطننة لزغابات الأمعاء الدقيقة , كما لوحظ انخفاض أعداد الخلايا الكأسية وفقدانها في أحيان أخرى . أدت التأثيرات المرضية الى عطل في وظيفة الأمعاء الدقيقة للطيور المصابة في الدراسة الحالية حيث ظهر الهزال عليها . في حين ارتشحت الخلايا الالتهابية في الطبقة المخاطية وتحت المخاطية للأمعاء الدقيقة المصابة.

### **Introduction**

Like other animals , the aquatic birds are subject to invasion with many parasites which cause considerable damage to their host . the aquatic birds not only compete with fishes in farms or consuming young fishes (Mhaisen and Abus – Eis , 1992) but also birds may act as reservoir hosts to many helminth species which causing serious diseases to poultry . and man zoonosis (Barus et al , 1978) . Recently , AL – Mayah (1990) found *E . tubifex* in *podiceps ruficollis* for the first time in Iraqi birds and he expected that this parasite posses afatal effects on the birds in spite of the importance of birds as very numerous and wide spread group , only few investigations of their parasitic fauna have been under taken in other hand many accounts concerning with the pathogenicity of the birds parasites have been carried out in other parts of the world by Solman (1955) and clark (1978) . such accounts were seems to be limited in Iraq ,

Mustafa (1984) , AL-Mayah et al (1991) and AL-Mayah and Mustata (1994) of some the literatures available on aquatic bird helminth in Iraq during the last nineth years and make it available for investigators interested in this field . the first one which introduced by Awad et al , (1993) consist of the helminth fauna which recorded in the period from 1977 – to 1991 in Basrah avian helminth have been studied by workers in many parts of the world , and published works are too extensive to review here , but helminth funa of birds in center and north of Iraq is still incompletey knows as well as such investigations are limited in Iraq .

The aim of this work is to study the histo – pathological changes on the some aquatic birds caused by Anomotaenia microrhyncha , trchocephaloides megalaloecephala paricterotaen porosa and haplo paraxis crassirostris in the tringa nebularia , larus argentatus and phalacrocorax carbo.

## **Materials And Mathods**

Thirty aquatic birds (tringa nebularia , larus argentatus and phalacrocorax carbo) were collected from Bahr AL- Najaf depression in September till November 2004 . All birds were examined immediately when reach to the anatomy and histology laboratory . The birds were anaesthized with chloroform . The small and large intestines were removed and opened carefully by sissor for determined the parasites . Small pieces of infected small intestines were cut and put in 10% formalin to carried – out fixation for 48 hrs , Dehydration by graduate ethanol alcohol (50% , 70% , 90% , and 100% ) and after that clearing by xylene , then embedding in paraffin to make blocks . histological paraffin blocks were cut by microtome at (six – micrometers) in thickness sections were stained with hematoxylin and eosin and then mounted in canda – balsm Vacca (1985) . parasites were identified according to Soulsby (1968) .

## **Results and discussion:**

The basic structure of the aquatic birds intestines is showing in (fig , 1 , 2 , 3 ) the intestinal mucosa is formed in to large numbers of leaf – shaped villi arranged in a zig-zag pattern the crypts of lieberkuhn , short simple acinous tubular duct , the villi lined by simple columnar epithelium , the muscularis mucosa is so poorly developed being only about the same thickness as the external longitudinal layer in the small intestine , the submucosa is so poorly developed as to be almost non – existent in most of small intestine externally there is alayer of squamous epithelium , under which is athin layer of loose connective tissue – the muscularis consist of longitudinal muscle fibers through out the length of intestine except in the ceca , where there are two layers an outer longitudinal layer and an inner circular or oblique layer of smooth muscle fibers . among ten T nebularia two birds were found infected with cestoda A microrhyncha and cestoda T megalaloecephala (fig.4) , the infected birds were revealed fibrosis surrounded the worm in the mucosa of small intestine , the parasite were seen early in section of the mucosa of the duodenum inducing marked granulomatous , inflammatory alteration which occur due to mechanical effects which lead to massive tissue damage , beside degeneration and necrosis in the simple columnar epithelium a decreasing in goblet cells number and connective tissiue elements which are more abundant around the parasite the parasite was located in fibrous tissue led to marked vasculitis and proliferation of small arteriols and venules also among ten L argentatus three specimens were found to be infected with cestoda paricterotaen porosa the histopathological changes were diagnosed by the examination of infected small intestine (duodenum) which appeared the ulceration of epithelial lining in the villi .

Also inflammatory cells infliterate including lymphocytes , plasma cells , phagocytic cells and esinophils the inflammation was extend in to core of lamina properia in the intestinal villi odema occur in the mucosa and hyperplasia in the intestinal glands , beside the necrosis and degeneration in the most of epithelial cells and the goblet cells were disappeared . While among ten P carbo one bird found infected with haploparaxis crassirostris . (fig 6) showing the sever damage in the epithelium , lost goblet cells , polymorphic nuclear infliterate cells found in the

lamina propria of the villi , also destruction occur in the intestinal glands , these pathological changes which led to impairment in the function of small intestine of the infected bird .

The parasitic infection of the birds depends mainly on parasite types , number , size , organs invaded , time of infection and on age and sex of the host (Wilson , 1967) the pathogenicity of the aquatic bird parasites particularly in Iraq are not well known . many parasites invaded vital organs of their host causing massive alterations in their functions . in addition to their mechanical damages subsequently leading to dysfunction and impaired digestion and then lead to emaciation (AL-Mayah et al 1991) , these results were corresponding to this present study . Also the histopathological effects noticed in this study seems to be similar to that investigated by Wehr (1971) on birds infected by *E. ignotus* . In this study granulomatous tissue contain acentrally located worm portion surrounded by inflammatory cells such as lymphocytes , plasma cells and macrophages with neutrophils and fibroblasts were observed . The migration of the larva and immature parasite of *Contracaecum* spp , causes great mechanical damage to the proventriculus of purple heron (AL-Hadithi and Habash , 1977). On other hand , *Acanthocephalus* induced serious damage to the intestinal wall due to embedding of their protoscolex in the mucosa of the bird which may subsequently induce tissue reaction (Abdullah , 1998) these pathological findings were agreement with this present study . the previous studies revealed the same pathological effects which occurred in present study , these previous studies were carried – out by investigators (AL – Mayah et . al , 1991) they observed destruction of duct epithelium in the proventriculus of *Bubulcus ibis* by *microcotyle* spp .

Petechial hemorrhage , and small nodules were observed on the external surface of small intestine of infected quail birds with mentioned parasites in this present study . these histopathological findings were identical with results recorded in the alimentary canal of *Sturnus vulgaris* .

Due to infection with *Acanthocephala* and *Passerilepis crenata* (Abd al Razak , 1998) while some works (AL-Mayah et . al . , 1994) described the pathological changes in the proventriculus of *Podiceps ruficollis* due to infection with *Eustrongylides tubifex* (nematoda) diotrophidae from Basrah , they found fibrous tubes containing the worms in the proventriculus of the infected birds , the worms were seen clearly in section of proventriculus mucosa initiating marked granulomatous , inflammatory changes and mechanical effect which induced massive tissue destruction , atrophy and hemorrhage which is more severe around the worm the later pathological findings were similar to the pathological changes that appeared in this present study .

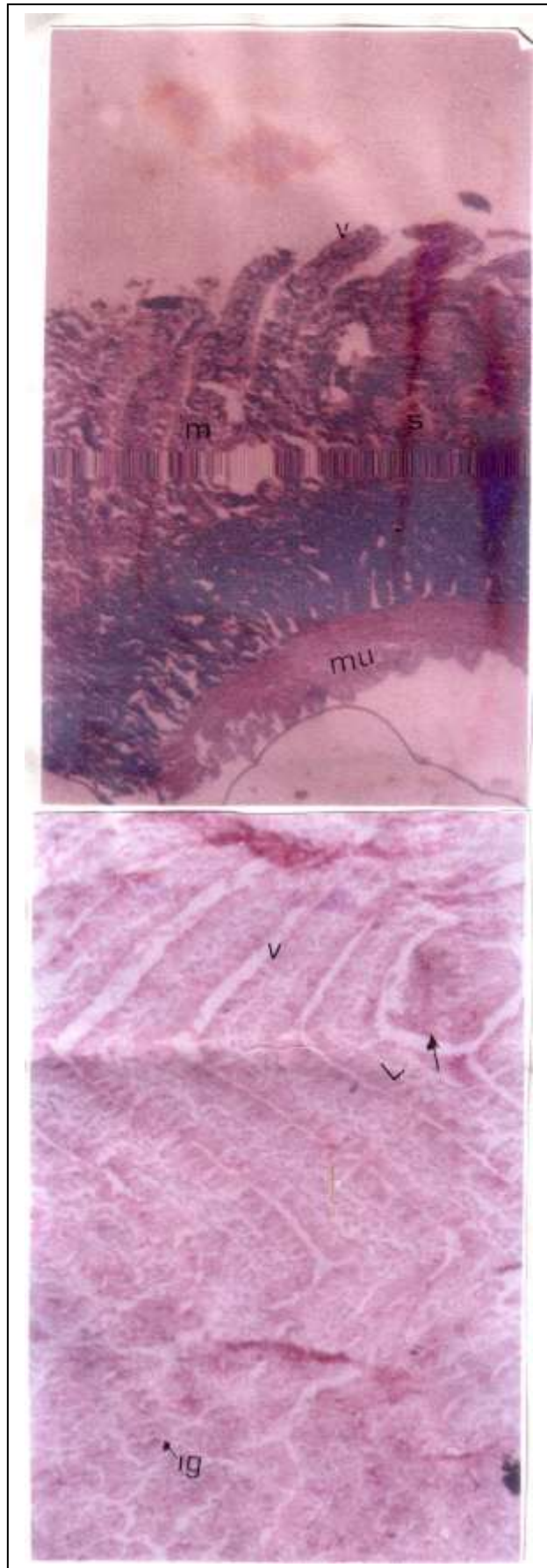


Fig.1: show normal small Intestine (duodenum)of *phalacrocorax carbo* V : villus  
m: mucosa . S : submucosa (intestinal glands)  
mu: muscularis externa Hematxylin and Eosin.250x

Fig2 :reveale infected small Intestine (duodenum) of *Tringa nebularia* with *trichocephaloides megalalocephd* Arrow referred to fibrosis Surrounded the parasite Degeneration and necrosis Observe in the simple Columnar epithelium and Epithelial linings of intestinal Glands. v: villi. Lillamina Properia I.g:intestinal Glands .Hematoxylin and eosin 450x

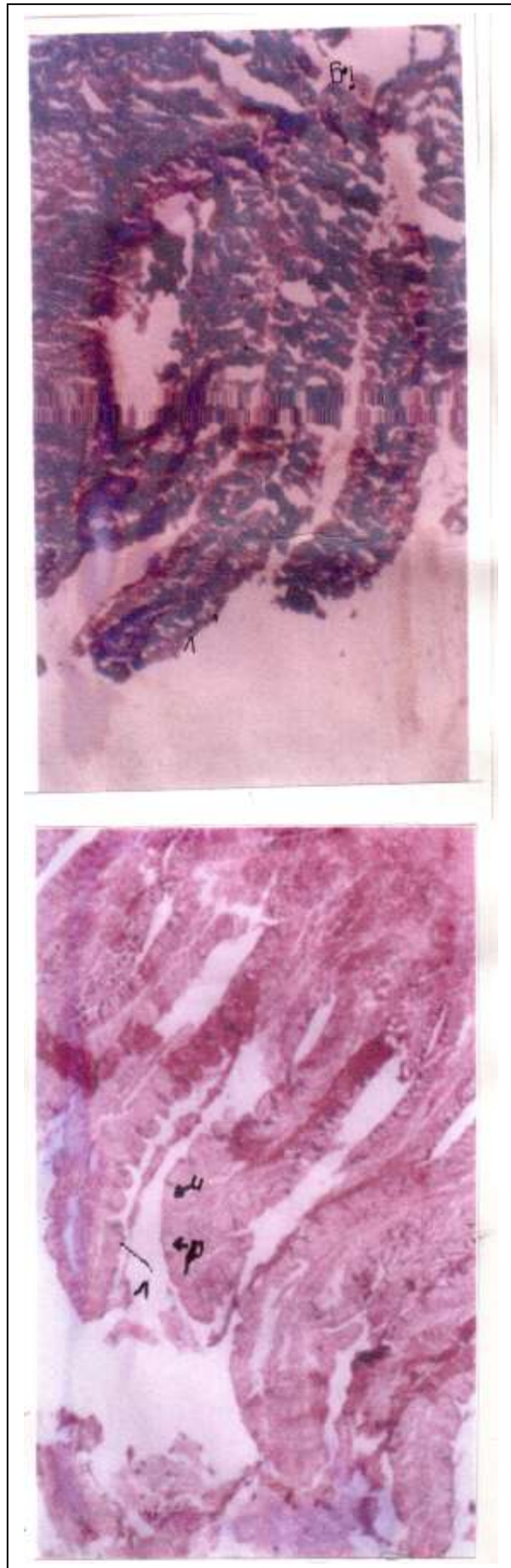


Fig3: show the mucoa ofinfected small intestine (duodenum) with parasite P parosa in the L argentattus the pathologicl changes includes ulceration in epithelial linings of villi and degeneration and necrosis occurs in the simple columnar epithelium which lined the villi as well as decreasing in the goblet cells number . v : villus . hematoxylin and Eosin 450x.

Fig4: revealed the mucosa and submucosa of infected small intestine (duodenum)With parasite haploparaxis Crassirostris in the P carbo show destruction in cellular elements in epithelial linings Of villi and intestinal glands v: villi l.g : Intestinal glands Hematoxylin and Eosin.450x

**References:**

- 1- Abdal – Razak , A.T. (1998) pathological changes in the alimentary canal of sturnus vulgaris L.due to infection with prosthynchus gracile (Acanthocephala) and passerilepis crenata from Basrah , Iraq . Basrah . J. Sci. 14 (1) pp : 1-6 .
- 2- Abdullah , B.H. (1998) A study on parasites of some aquatic birds in Basrah .M.sc.thesis univ Basrah . pp : 118 .
- 3- AL- Hadithi , I.A. and Habash , A.H.(1977) . Observations on nematodes parasite contra caecum sp . of some Iraqi fishes Bull . Basrah nat . Hist , Mus (4) : 17 – 25 .
- 4- AL-Mayah , S.H.(1990) Helminths of some aquatic birds and notes about swimmers itch in Basrah M.Sc.thesis . univ . of Basrah . pp : 103 .
- 5- AL-Mayah , S.H , Mustafa , F.A. and AL-Hadithi , I.A. (1991) the morphology effect of microtetrameres egrete Bubulcusibis (L) in Basrah Iraq .Basrah.J.Agric.(4):297-303
- 6- AL-Mayah , S.H. and Mustafa , F.A.(1994) pathological changes in the proventriculus of podiceps ruticollis due to infection with Eustrongylidae tubife (nitzsch , 1819) from Basrah , Iraq . Basrah . J . of science , B . 12:59 – 62 .
- 7- Awad , A.H, AL-Mayah , S.H. and Abdullah , B.H. (1993) . aquaic birds helminth founa in Basrah province , Iraq : A check – list A – Basrah . J . science , 11(1) : 115-131 .
- 8- Barus , V.I, sergeeva , T . P . , sonin , M.D. and Ryzhikov , K.M. (1978) helminth of fish – eating birds of the palaearctic region I , nematode published by dr.W.Junk , Hague , nether lands , pp : 318 .
- 9- Clark , W.C.(1978). Tetramers tarapungae n . sp Nematoda spiruridae aparasite of thread – biled gull , larus novaehollandiae , scopulinus – newzeal . J. zool ., 50:7-13.
- 10- Mhaisen , F.T. and abul-eis , E . S . (1992) . parasitic helminthes of eight species of aquatic birds in Babylon fish farm , Hilla , Iraq . zoology in the middle east , 7:115-119 .
- 11- Mustafa , F.A. (1984) epidemic study on some cestodes infecting the alimentary canal of pigeons . M.Sc . thesis – univ . of Basrah .
- 12- Solman , K.N. (1955) . observations on some helminth parasites from ducks in southern England . j . heliminth . vol . ix : 12- 26 .
- 13- Soulsby , B.J. (1968) helminthes , arthropods and protozoan of domesticated animals . (6<sup>th</sup> ed . of monnings vet . helminthology and entomology ) . London . Baillae , tindall and cassell ltd . p : 824 .
- 14- Vacca , L.(1985) laboratory manual of histo – chemistry . 1st ed . Ravan press . new york pp:205 .
- 15- Wehr, E.E. (1971) nematodes In davis , J.W. : Anderson , R.C , kastad , L. and trainer , D.O. (eds) . infectious and parasitic disease of wild birds . Iowa state univ . press , Amen , Iowa . p: 185 – 233 .
- 16- Wilson, R.A.(1967) An introduction to Parasitology Edward Arnold, (Publ.),London:59 pp.