

## Relationship between mycotoxicosis and calcium during preproduction period in layers

T. S. Qubih

Department of Pathology and Poultry Diseases, College of Veterinary Medicine, University of Mosul, Mosul, Iraq

(Received March 28, 2011; Accepted June 29, 2011)

### Abstract

This study was conducted to examine field cases of mycotoxicosis (Aflatoxicosis and ochratoxicosis) and their effects on calcium during the preproduction period of ISA brown pullets. Birds were 12-15 weeks of age. The feed was subjected to analysis for mycotoxin and blood samples were laboratory diagnosed for infectious bronchitis and infectious bursal viruses antibody titer and for determination calcium level. Clinical signs of affected birds were rubbery bone, ruffled feather, paleness and high mortality. Necropsy findings of sick birds were characterized by muscle dehydration, enlarged livers yellowish, kidney enlargement and urate deposition. Histopathological features of liver consisted of capsular thickening hepatocellular necrosis, subcapsular infiltration with inflammatory kidneys cells showed swelling of tubular cells, deposition of calcium between kidney tubules with infiltration of inflammatory cells. ELISA test revealed the presence of 800 ppb aflatoxin and 100 ppb ochratoxin. Normal titers of infectious bronchitis virus and infectious bursal diseases antibodies were recorded. Low blood calcium level of 8.2 mg/dl was registered in the tested blood samples.

**Keywords:** Mycotoxicosis; Calcium; Reproduction; Layers.

Available online at <http://www.vetmedmosul.org/ijvs>

## العلاقة بين السموم الفطرية والكالسيوم للدجاج البياض خلال مرحلة ما قبل الانتاج

طارق سالم قبيح

فرع الأمراض وأمراض الدواجن، كلية الطب البيطري، جامعة الموصل، الموصل، العراق

### الخلاصة

أجريت هذه الدراسة لفحص حالات حقلية للعلاقة بين السموم الفطرية (سموم الافلا وسموم الاوكرا) والكالسيوم خلال فترة ما قبل الانتاج لقطيع البياض نوع ايسا البني، عمر ١٢-١٥ أسبوع. تم التحري عن السموم في الاعلاف، و فحصت المضادات الجسمية لمرض التهاب الشعب الهوائية المعدي والتهاب جراب فابريشيا المعدي وكذلك لتقدير مستوى الكالسيوم في الدم. الاعراض السريرية للافراخ المصابة شملت سهولة التواء العظام، نفوش الريش، شحوب وزيادة نسبة الهلاكات. فحص ما بعد الموت للافراخ اظهر انكاز في العضلات، تضخم الكبد واصفراره، تضخم الكلية و ترسب مادة اليوريت. الفحص النسيجي للكبد اظهر وجود نثخن في القشرة مع تنخر خلايا الكبد و ارتشاح للخلايا الالتهابية تحت القشرة اما الفحص النسيجي بخصوص الكلية فلو حظ تورم في الخلايا النبيبات الكلوية مع ترسب أملاح الكالسيوم ما بين الفوصيصات المصاحب لارتشاح الخلايا الالتهابية. اختبار الاليزا كشف عن وجود سموم الافلا ٨٠٠ جزء بالبلليون وسموم الاوكرا ١٠٠ جزء بالبلليون (مستوى المضادات الجسمية لفايروس التهاب الشعب الهوائية المعدي والتهاب جراب فابريشيا المعدي طبيعي). انخفاض مستوى الكالسيوم في الدم ٨,٢ ملغم/١٠٠ مل.

## **Introduction**

Kidney failure (KF) is a symptom of many diseases in chickens such as infectious bronchitis, infectious bursal diseases, mycotoxicosis and some diseases classified under the item of unknown etiology such as cage layer fatigue (1).

Mycotoxicosis has been reported in many countries where intensive poultry production is practiced (2). Mycotoxicosis is an accumulative disease, and its effect appears particularly at rearing period 13-14 weeks of age in layer type chicken (3). At these times, the owners try to increase the quantity of calcium to enhance the production (4).

Mycotoxin causes variety of effects in poultry such as poor growth, decreased efficiency of feed conversion and increased mortality, and (5) liver trouble (6), kidney trouble (7) and undesired reproductive changes (4).

During the period from 2006 till 2009 commercially laying flocks (ISA brown) reared in Nineveh governorate experienced a dramatic increase in mortality of about 100-200 birds per day from flocks of total number 24000 hens per house and last for varying time.

The most prominent clinical signs were restricted to reduction in feed consumption, rubbery bones and drop in egg production. Case of field mycotoxicosis was suspected where it affects calcium metabolism and egg production.

The aim of this study was to identify the lesions resulting from the mycotoxin and its relation to calcium salt.

## **Materials and methods**

A flock of 120000 Commercial laying hens (ISA brown) reared in five houses, aged between 12-15 weeks were followed in this study. These houses located in Nineveh governorate. Birds were reared in battery cages in a well-ventilated house. With temperature of 20°C and a lighting system applied according to the specified guideline.

Feed was offered as recommended by the supplied company program. Water was given according ad lib.

Blood samples from sick birds were collected from wing vein. Serum was collected from clotted blood and stored individually at -20 °C. These samples were subjected to analyze the titers of infectious bronchitis virus and infectious bursal disease, using enzyme linked /sor bent assay (ELISA) technique with a kit from a symbiotic corporation (symbiotic company).

Calcium blood level was determined using a prepared kit offered from Biomeuriux (france) using a wave length of 450 nm.

Representative feed samples (complete mixed feed samples) were analyzed for mycotoxins (Aflatoxin and ochratoxin) using Neogen mycotoxin kits (USA). Analysis was performed by enzyme linked immunosorbent assay

technique (ELISA) with EL<sub>800</sub> reader (USA). Assay was performed by following the instructions of the producer.

Affected Livers and kidneys were collected from necropsied birds and fixed in 10% neutral buffered formalin for 48 hours. They were sectioned in 5m thickness and stained with hematoxylin and eosin stain as reported by (8).

## **Results**

The most prominent signs in the affected birds were rubbery bones, ruffled feather, decrease in feed consumption, decreased egg production (8 %) when production start paleness, recumbence and high mortality.

Necropsy of sick birds showed prominent lesions darkened dehydrated muscles, yellowish discoloration of fatty and creasy, with discrete necrotic foci of enlarged (hepatomegaly) Livers.

Kidneys were swollen, hemorrhaged with distended kidney tubules and accumulated urate (Figure 1).

Aflatoxin and ochratoxin analysis of mix layer feed using ELISA test show high level of aflatoxin (800 ppb) and ochratoxin (100 ppb).

Spectrophotometric analysis of calcium level in blood samples revealed a low calcium concentration of 8.2 mg/dl.

Thickening of liver capsule was evident with atrophied sub capsular paranchymal cells and massive necrotic areas (coagulative necrosis) scattered within areas (Figure 2) inflammatory cells infiltration in the portal area with deposition of acidic material between hepatic cells and around hepatic sinusoids (Figure 3).

Dilation of central vein and sinusoids were also evident (Figure 4).

The histological changes showed nephrosis changes, swelling of renal tubular cells, stenosis of tubular lumen with calcium deposition. Hyperplasia of glomerular tuft, with infiltration of inflammatory cells in the interstitial tissue (Figure 5) also observed.

Some sections showed calcium salt deposition between renal tubules with necrotic changes in renal tissues (Figure 6).

## **Discussion**

Observations on poultry farms showed paleness, ruffled feathers, some recumbency, with high mortality, and rubbery bone. This is due to increased calcium metabolism and reduced calcium deposition in bone; these results are in agreement with (9).

The results of this study in most pullets showed that there were no prominent changes in blood picture of birds investigated.

Blood calcium was in with lower limit of the ordinary range which may cause some lesions in the kidneys this explanation agree with that reported by (10).

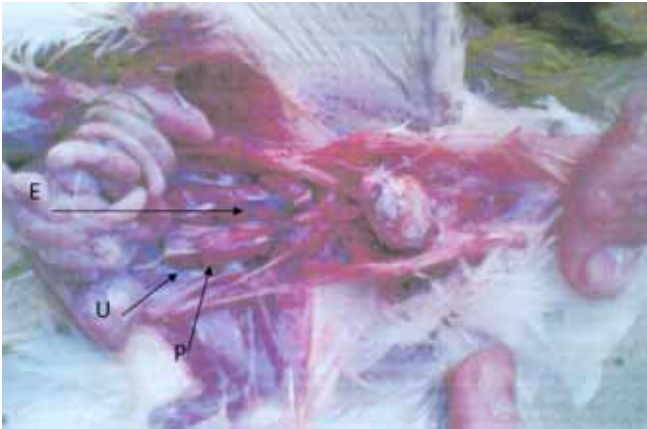


Figure 1: Enlargement of kidney (E) with petechial hemorrhage (P), and urate filled the ureter (U).

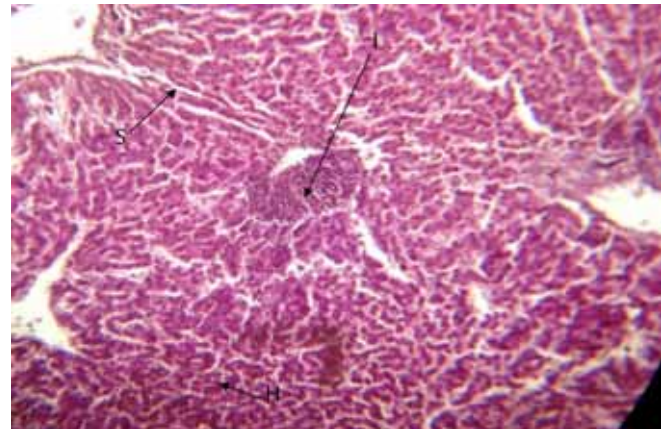


Figure 4: Liver shows focal necrosis of hepatocytes (H) with dilatation of sinusoid (S) with inflammatory cells (I) (H&E 115 X).

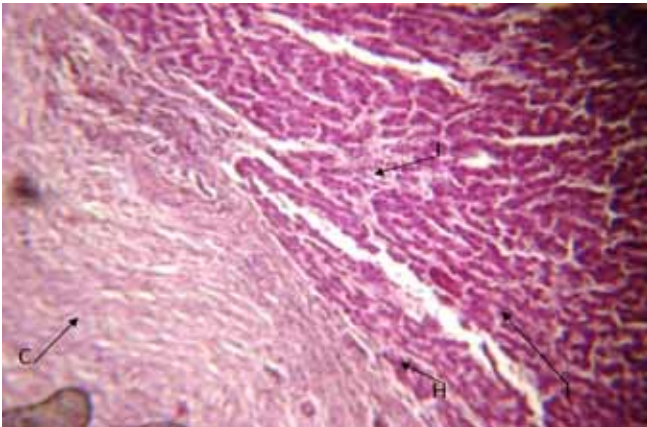


Figure 2: Liver shows thickening of capsules (c) with atrophy of hepatocytes in subcapsular area (H) and inflammatory cells (I) (H&E 145 X).

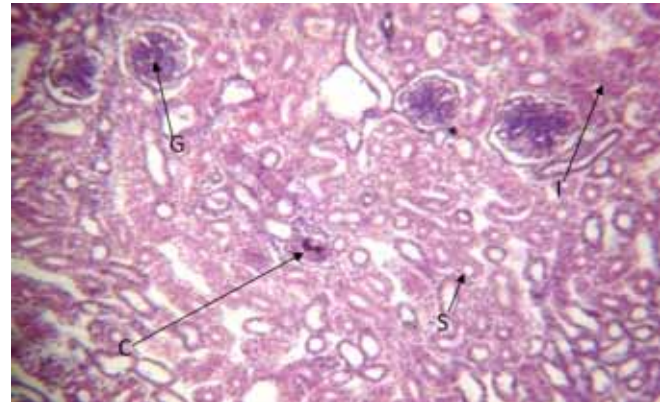


Figure 5: Kidney tissue shows stenosis of lumen of tubules (S), deposition of calcium salt (C) and hyperplasia of glomerular tuft (G) (H&E 165 X).

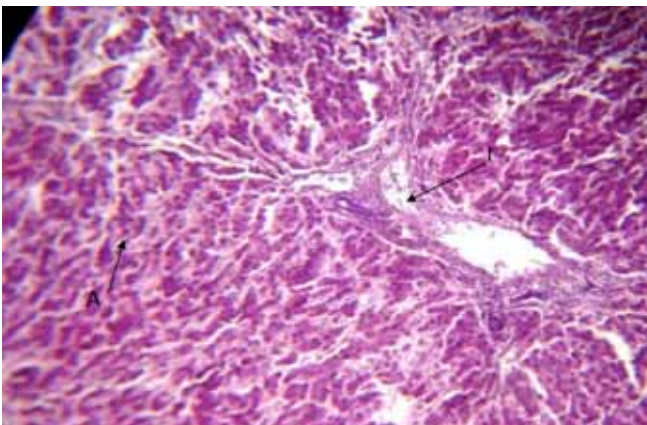


Figure 3: Liver shows deposition of acidic materials between hepatic cells (A) with inflammatory cells in portal area (I) (H&E 145 X).

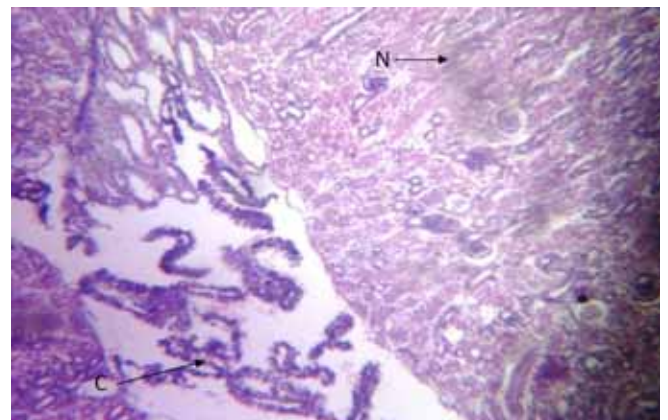


Figure 6: Kidney tissue shows necrosis in renal tissue (N) with deposition of calcium salt (C) (H&E 165 X).

The case might be ascribed to decrease on the level of vitamin D those reduced parathyroid hormone synthesis which lead to a decrease in feedback mechanism of kidneys and intestine to parathyroid hormone and eventually alter the calcium and phosphorus absorption.

It is also known that the low level of vitamin D3 increases the calcium excretion which predispose deposition of calcium in kidney tissue. Which lead to pale and swollen kidney as stated by (11). At the same time level of calcium decrease in plasma causing decreased egg production this is in agreement with (12).

The enlarged liver indicating aflatoxicosis is due to accumulation of lipid, as pointed out by (13) and also in the kidney according to (14).

### **Acknowledgements**

The study was supported by the College of Veterinary Medicine, University of Mosul. The author thanks Dr. A. M. Shareif for his efforts to detect the mycotoxin by ELISA technique.

### **References**

1. Saif AM, Barnes HJ, Glisson JR, FadlyAM, McDougaldLR, Swayne DE. Diseases of poultry 11<sup>th</sup>ed. Iowa State University Press, Ames, Iowa, USA 2003. 1103p.
2. Abdel Hamid AM, Dorra TM. Study on the effect of feeding laying hens on separate mycotoxins (aflatoxin, patulin, or citrinin) contaminated diets on the egg quality and tissue constituents. Archv furtierenahrung. 1990;40:305-316
3. Ortatali M, Ciftci MK, Tuzcu M, Kaya A. The effect of aflatoxin on the reproductive system of roosters. Res Vet Sci. 2002;72:29-36
4. Rama- RAOSV, RajusMVLN, Panda AK, RaddyMR. A practical guide to vitamin D nutrition in poultry. Poul Intern. 2007;46:12-17.
5. Smith JW, HamiltonPB. Aflatoxicosis in broiler chicken. Poul Sci. 1970;49:207-215
6. Jordan FTW, Pattison M. Poultry disease 4<sup>th</sup> ed. Gopsons paper Ltd Nodia, India 1998. 254p.
7. Glahu PP, BearsKW, BottjeWG, Widemman RF, Huff WE, Thomas W. Aflatoxicosis alter avian renal function, calcium and vitamin D metabolism. J Toxicol Environ Health. 1991;34:309-321
8. Luna LG, Manual of histological staining methods of armed forces instant of pathology 3<sup>rd</sup>ed. McGraw. Hill Body Co. New York, USA 1968. 3p.
9. Garlich JD, Turo HT, Hamilton PB. The use of short term feeding of aflatoxin on eggs production and some plasma elements of laying hens. Poul Sci. 1973;52:2206-2211
10. Wolrak A, PearsonAM, Coleman TH, pestka JJ, Chen C. Aflatoxicosis carry over and clearance from tissue of laying hens. Food and Chem. Tox. 1986; 24:37-41
11. Trucksess MW, Stollof L, Young K, Wyatt KD, Milier BL. Aflatoxins B<sub>1</sub> and M<sub>1</sub> in egg and tissue of laying hens consuming aflatoxin-contaminant feed. Poultry Sci. 1983;62:2176-2182.
12. Oguz H, HadimliHH, KurtogluV, EvaganisO. Evaluation of humoral immunity of broiler during chronic aflatoxin (50 and 100 ppb) and clinoptilolite exposure. Rev Med Vet. 2003;38:483-486
13. Ortatatli M, OguzH. Ameliorative effect of dietary clinoptilolite on pathological changes in broiler chickens during aflatoxicosis. Res Vet Sci. 2001;71:59-66.
14. Bilgic HN, YesildereT. Renal lesions on experimental aflatoxicosis in hybro type chicks Vet Fak Derg. 1992;18:102-108.