

# Clinical evaluation of the effect of four flap designs on the post-operative sequel (pain, swelling and trismus) following lower third molar surgery

**Mohammad S Sulieman**  
BDS, MSc (Assist Lect)

**Department of Oral and Maxillofacial Surgery**  
College of Dentistry, University of Mosul

## ABSTRACT

The present study aimed to assess the effect of different flap designs on pain, swelling and trismus following surgical removal of impacted mandibular third molar. The study was carried out in Oral and Maxillofacial Department, Dental Teaching Hospital of Dentistry College, Mosul University.

Sixty patients were included in the research where they were divided into 4 groups, each comprised of 15 patients. In the first group, the impacted teeth were removed using an envelope flap. In the second group, a standard flap was used for the removal of impacted teeth. For the third group, the impacted teeth were removed using modified standard flap. While in the fourth group, S-shaped flap was used. Pain, swelling and trismus were assessed clinically post-operatively at 1 day, 3 days and 7 days intervals. Pain and swelling were evaluated subjectively while trismus was evaluated by measuring the maximum mouth opening ability (in mm) between the right upper and right lower central incisors using a vernier. The results showed no significant effect among the 4 flap designs on post-operative complaints.

It was concluded that the type of incision appears to have no effect on the degree of pain, swelling and trismus following surgical removal of impacted lower third molar.

**Key Words:** Impaction, incisions, flaps in oral surgery, lower wisdom.

Sulieman MS. Clinical evaluation of the effect of four flap designs on the post-operative sequel (pain, swelling and trismus) following lower third molar surgery. *Al-Rafidain Dent J.* 2005; 5(1): 24-32.

**Received:**  
8/9/2004

**Sent to Referees:**  
14/9/2004

**Accepted for Publication:**  
6/11/2004

## INTRODUCTION

Third molar impaction surgery is a common dental procedure that requires a sound understanding of surgical principles and patient management skills,<sup>(1)</sup> and often the removal of impacted lower third molar involves trauma to the soft and hard tissues due to preparation and retraction of a mucoperiosteal flap and the removal of bone, which is frequently followed by oedema of varying degree, pain, trismus<sup>(2, 3)</sup> and at times delayed healing.<sup>(4, 5)</sup>

Overtime, certain standards and expectations have been established as benchmarks for acceptable treatment, whether

third molar surgery is performed by the specialist; those standards are the same, such as timing for surgery, flap design, instrumentation, extent of bone removal, sectioning methods and suturing.<sup>(1)</sup> Some researchers stated that the difficulty of removing an impacted tooth depends on its accessibility. Therefore, to gain access to the area and visualize the overlying bone that must be removed, the surgeon must choose the most appropriate flap design to allow placement and stabilization of retractors and instruments for the removal of an impacted tooth.<sup>(6-8)</sup> However, little attention has been given to the soft tissue that

must be incised and reflected to surgically gain access to the impacted tooth.<sup>(9, 10)</sup>

Over the years, the authors suggested different types of flap design that can be used for the removal of impacted lower third molar,<sup>(1, 8, 11-13)</sup> while only few studies have been carried out to compare the effect of choosing a certain flap design over another on post-operative complaints.<sup>(9, 11)</sup>

In this clinical trial, four commonly used flap designs (envelope, standard, modified standard and S-shape) in lower third molar removal were evaluated clinically.

The aims of the study were to estimate the effect of using different flap designs on the most likely post-operative complaints (pain, swelling and trismus) following lower third molar surgery.

### MATERIALS AND METHODS

Sixty outpatients aged between 17 and 35 years of age who were attending Oral and Maxillofacial Surgery Department, Dental Teaching Hospital of Dentis-

try College, Mosul University who required surgical removal of mesio-angularly impacted mandibular third molar teeth and good oral hygiene were eligible for inclusion in this study. Before participation in this study, full medical histories were obtained from all patients, those with systemic diseases were excluded from the study. Women patients were excluded if they were pregnant or lactating. In addition, any patient who had taken any analgesic or anti-inflammatory agent within 12 hours period before surgery was also excluded from the study. A specific case sheet was designed for each patient (Figure 1).

The patients were randomly enrolled into four treatment groups: Each containing 15 patients (Table 1).

The random allocation of patients to the four treatment groups ensured that patient and treatment variables such as age, sex, operation time and degree of surgical difficulty were uniformly distributed among the treatment groups.

**University of Mosul – College of Dentistry**  
**Department of Oral & Maxillofacial Surgery**  
**Impaction Case Sheet**

Patient's Name: \_\_\_\_\_ Age: \_\_\_\_\_  
 Date: \_\_\_\_\_ Sex: \_\_\_\_\_  
 Occupation: \_\_\_\_\_ Marital Status: \_\_\_\_\_  
 Address (including telephone number): \_\_\_\_\_  
 Chief Complaint: \_\_\_\_\_  
 Medical History: \_\_\_\_\_

Mouth Opening Pre-Operatively: (    ) mm.

Type of Flap: Envelope:( 1 )                      Standard:( 2 )  
                                          Modified Standard:( 3 )                      S-Shape:( 4 )

Severity of Surgical Trauma: Mild:(    ) Moderate:(    ) Severe:(    )

Operation Time: (            ) minutes.

Post-operative Follow-up	Pain				Swelling				Degree of Trismus (Mouth Opening, mm)
	0	1	2	3	0	1	2	3	
1 Day									
3 Days									
7 Days									

Pain: 0: No pain; 1: Mild; 2: Moderate; 3: Severe

Figure (1): Case sheet

Table (1): Sex distribution and mean age of patients in relation to treatment groups

Group	Type of Flap	Sex		Total	Age Range (Years)	Mean Age (Years)
		Male	Female			
I	Envelope	7	8	15	18–34	21
II	Standard	8	7	15	17–36	23
III	Modified Standard	5	10	15	17–35	23
IV	S-Shape	5	10	15	17–35	24

Group I included 15 patients; impacted teeth were removed using envelope flap, where the incision extends from the mesial papilla of mandibular first molar around the necks of the teeth to the distobuccal line angle of the second molar, and then posteriorly to and laterally up the anterior border of the ramus (Figure 2A).<sup>(13)</sup>

In group II, 15 impacted teeth were removed using standard flap, in which the anterior incision curves forwards from the distobuccal corner of the crown of the second molar and ends alongside the mesio-buccal cusp of that tooth. Distally the horizontal incision was extended with the buccal side of the tooth to the external oblique ridge (Figure 2B).<sup>(13)</sup>

Whereas in group III, modified standard flap was used for the removal of 15

impacted teeth. In this type of flap design, the anterior vertical incision is commenced at the distobuccal corner of the crown of the lower first molar and extended forw-ards alongside that tooth. A horizontal incision is made in the buccal gingival cre-vice of the second molar and then the inci-sion is extended along the buccal side of the tooth to the external oblique ridge (Figure 2C).<sup>(13)</sup>

In group IV, an S-shape flap design was used where the incision was made from the retromolar fossa across the external oblique ridge curving down through the attached mucoperiosteum to run along the reflection of the mucous membrane to the anterior border of the first permanent molar (Figure 2D).<sup>(13)</sup>

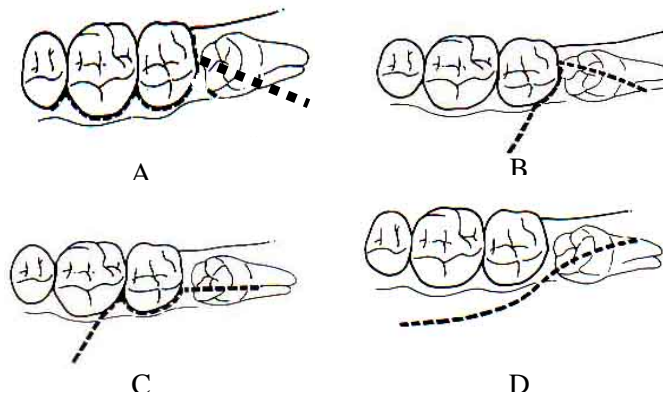


Figure (2): Types of flap<sup>(13)</sup>

A; Envelope; B: Standard; C: Modified standard; D: S-shape

**Surgical Procedure**

All of the operations were performed under local anaesthesia which was obtained by inferior alveolar, lingual and long

buccal nerve block, using 2.2 ml lidocaine with 1:80 000 adrenaline (Septodont, France). A standard surgical technique was used for all patients as described by Killey

et al.<sup>(14)</sup> Following reflection of mucoperiosteal flap, bone removal was done as needed.

The severity of surgical trauma was graded as follows:

- 1) **Mild Trauma:** Only reflection of mucoperiosteal flap and creation of point of application for elevator.
- 2) **Moderate Trauma:** Reflection of mucoperiosteal flap and bone removal by creating gutter on the buccal side of the tooth.
- 3) **Severe Trauma:** Reflection of a mucoperiosteal flap, bone removal from the occlusal, buccal and distal sides, together with sectioning of the tooth.<sup>(2,3)</sup>

After removal of the impacted tooth, the socket was irrigated with 10 ml normal saline (Mosul IV Plant, Iraq) and only one stitch was done just distal to the standing lower second molar and post-operative instructions were given to the patient.<sup>(13)</sup>

All patients were given metronidazole tablets (as antibacterial agent) 400 mg bid and paracetamol tablets (as analgesic) 500 mg qid for 5 days post-operatively.<sup>(10, 15-17)</sup>

#### Assessment of Post-operative Pain

The pain was evaluated subjectively according to the following criteria:<sup>(18)</sup>

**0= No pain.**

**1= Mild pain:** It is easily tolerated.

**2= Moderate pain:** It is causing discomfort, but bearable.

**3= Severe pain:** It is causing discomfort, hardly tolerated and unbearable.

#### Assessment of Post-operative Swelling

The post-operative swelling was assessed subjectively by criteria developed by Sabur<sup>(3)</sup> as follows:

**Grade 0=** No swelling.

**Grade 1=** Oedema that involves the alveolar mucosa buccally and/or lingually (intraorally).

**Grade 2=** Oedema that involves the alveolar mucosa buccally and/or lingually, and involves the cheek (extraorally) to the lower border of the mandible.

**Grade 3=** Oedema that involves the alveolar mucosa buccally and/or lingually, and involves the cheek (extraorally) below the lower border of the mandible.

#### Assessment of Post-operative Trismus

The maximum mouth opening ability measured in millimeters was recorded between right upper and right lower central incisors with the use of a vernier-calibrated sliding caliper.<sup>(19)</sup> Mouth opening was recorded pre-operatively, 1 day, 3 days and again on 7 days post-operatively. Percentage of trismus was calculated according to the following equation:<sup>(20)</sup>

$$\frac{\text{Post-operative mouth opening (mm)}}{\text{Pre-operative mouth opening (mm)}} \times 100\%$$

All patients returned for checkup of pain, swelling and trismus on the first, third and seventh post-operative days.

Statistical analysis of the data in this study included Kolmogorov-Smirnov test<sup>(21)</sup> for the comparison of pain and swelling among the four groups; whereas analysis of variance (ANOVA) was used to compare the results of trismus among the study groups.

## RESULTS

The demographic sex distribution and the mean age of all patients included in the present study were shown in Table (1). Concerning group I, there were 7 male and 8 female patients. The age range was 18-34 years with a mean age 21 years. However, in group II 8 cases male and 7 cases female were found; age range was 17-36 years and a mean age 23 years. Meantime, 5 male patients and 10 female patients included in group III. The age range was 17-35 years and mean age 23 years. Lastly, group IV contained also 5 cases male and 10 cases female, while the age range was 17-35 years and the mean age was 24 years.

Table (2) showed details of impacted teeth removed including surgical trauma and time of operation. Group I included 9 mild cases, 5 moderate and only 1 case was severe. The range of operation time was 10-45 minutes and the mean operation time was 20 minutes. In group II, the majority of cases were moderate (8), and 7 cases were mild; operation time range was 15-35 minutes and mean operation time

was 23 minutes. However, group III included 7 mild cases, 7 moderate and only 1 case recorded severe surgical trauma; range of operation time was 10–35 minutes, while the mean operation time was 22

minutes. Lastly, group IV recorded equal number for mild and moderate cases (7 for each) and 1 severe case was recorded. Range for operation time was 10–40 minutes and mean operation time 23 minutes.

Table (2): Details of operated cases involving surgical trauma and operation time

Group	Severity of Surgical Trauma			Operation Time Range (Minutes)	Mean Operation Time (Minutes)
	Mild	Moderate	Severe		
I	9	5	1	10–45	20
II	7	8	0	15–35	23
III	7	7	1	10–35	22
IV	7	7	1	10–40	23

I: Envelop flap; II: Standard flap; III: Modified standard flap; IV: S-shape flap.

**Pain**

Concerning day 1 interval, the majority of patients suffered from mild to moderate pain, only 2 patients recorded no pain and 4 patients showed severe pain. No statistically significant difference ( $p \leq 0.05$ ) was observed among all treatment groups. The same thing was true for 3 days period, where no significant differences were observed. Only one patient from all groups re-

corded severe pain, whereas 22 patients recorded no pain, 19 patients showed mild pain and 18 patients suffered from moderate pain. Over the next 7 days, the pain levels were dramatically decreased. The majority of patients recorded no pain and only 10 patients stated mild pain (Table 3); but again, no statistically significant differences ( $p \leq 0.05$ ) were observed as shown in Table (4).

Table (3): Patient’s expression of pain for all study groups

Severity of Pain	1 Day					3 Days					7 Days				
	I	II	III	IV	T	I	II	III	IV	T	I	II	III	IV	T
No Pain (0)	1	0	1	0	2	7	4	5	6	22	12	11	13	14	50
Mild Pain (1)	9	6	8	7	30	5	6	5	3	19	3	4	2	1	10
Moderate Pain (2)	4	8	4	8	24	3	5	4	6	18	0	0	0	0	0
Severe Pain (3)	1	1	2	0	4	0	0	1	0	1	0	0	0	0	0

I: Envelop flap; II: Standard flap; III: Modified standard flap; IV: S-shape flap; T: Total.

Table (4): Kolmogrov–Smirnov test regarding pain

Pain	G1	G1	G1	G2	G2	G3
	vs	vs	vs	vs	vs	vs
	G2	G3	G4	G3	G4	G4
After 1 Day	2.139*	0.135*	1.2*	1.2*	0.135*	0.531*
After 3 Days	1.2*	0.539*	1.2*	0.135*	0.531*	0.135*
After 7 Days	0.135*	0.135*	0.531*	0.539*	1.2*	0.131*

G1: Group 1: Envelope type flap  
 G2: Group 2: Standard type flap  
 G3: Group 3: Modified standard type flap  
 G4: Group 4: S-shaped type flap  
 df = 3

\* No significant difference between groups at 0.05 level ( $p > 0.05$ ).

**Swelling**

At one day period, the majority of patients recorded grade 1 swelling. Only one patient from group II had no swelling (grade 0), and another one patient from group III had grade 3 swelling. The remaining patients complained from grade 2.

At the third day, also the highest number of patients showed grade 1 swelling.

However, no patient experienced grade 3; but at day 7, the majority of patients showed no swelling, and only one patient showed grade 2. Meantime, 3 patients belonging to group II and 2 patients from group III suffered from grade 1 swelling (Table 5). Statistical analysis showed no significant differences among treatment groups concerning swelling (Table 6).

Table (5): Results of the swelling for all the groups one day, three days and seven days post-operatively

Grade of Swelling	1 Day					3 Days					7 Days				
	I	II	III	IV	T	I	II	III	IV	T	I	II	III	IV	T
Grade 0	0	1	0	0	1	4	0	1	3	8	15	12	12	15	54
Grade 1	12	6	9	11	38	6	7	7	11	31	0	3	2	0	5
Grade 2	3	8	5	4	20	5	8	7	1	21	0	0	1	0	1
Grade 3	0	0	1	0	1	0	0	0	0	0	0	0	0	0	0

I: Envelop flap; II: Standard flap; III: Modified standard flap; IV: S-shape flap; T: Total.

Table (6): Kolmogrov-Smirnov test regarding swelling

Swelling	G1	G1	G1	G2	G2	G3
	vs	vs	vs	vs	vs	vs
	G2	G3	G4	G3	G4	G4
After 1 Day	3.327*	1.2*	0.135*	0.531*	2.123*	0.531*
After 3 Days	2.139*	1.2*	2.123*	0.135*	6.515*	4.8*
After 7 Days	1.2*	1.2*	0*	0.135*	1.2*	1.2*

G1: Group 1: Envelope type flap  
 G2: Group 2: Standard type flap  
 G3: Group 3: Modified standard type flap  
 G4: Group 4: S-shaped type flap  
 df = 3

\* No significant difference between groups at 0.05 level ( $p > 0.05$ ).

**Trismus**

At one day period, group II patients showed the highest mean (90.233%), while group III showed the least mean (86.100%). However, no significant difference was observed as shown in Table (7).

At 3 days interval, the highest mean was recorded by group IV (91.713%), and the least mean was shown in group III (86.560%). But again, no significant differences

were noted (Table 7). The same thing was true concerning 7 days interval, where significant difference was not found; although group IV recorded the highest mean (99.85%) and group III patients showed the least mean (97.27%). Meantime, the mean for group I was 98.97% and 98.44% for group II as shown in Table (7).

Table (7): Results of trismus

Time Post-operatively	Group I	Group II	Group III	Group IV	F-value	p-value
	Mean ± SD					
1 Day	86.840 ± 8.151	90.233 ± 7.004	86.100 ± 14.711	89.560 ± 8.204	0.61	0.609
3 Days	89.427 ± 8.280	88.647 ± 9.148	86.560 ± 13.749	91.713 ± 5.841	0.72	0.542
7 Days	98.97 ± 2.92	98.44 ± 3.21	97.27 ± 5.64	99.85 ± 0.57	1.38	0.259

Group I: Envelop flap; Group II: Standard flap; Group III: Modified standard flap; Group IV: S-shape flap.

## DISCUSSION

The two main mistakes made by general dentists when removing impacted third molars are inadequate flap design and inadequate bone removal. The flap must be large enough to provide unobstructed visibility to the tooth and encasing bone.<sup>(1, 17)</sup>

According to our knowledge and researches, no previous study had compare between different flap designs and their effect on pain, swelling and trismus. In the present study, four flap designs were assessed clinically on most common post-operative complaints to the patients (pain, swelling and trismus). Statistical analysis revealed no significant difference regarding pain among all treatment groups at 1 day, 3 days and 7 days post-operatively. This was in agreement with the findings of Bracco *et al.*,<sup>(17)</sup> who stated that pain was not generated due to the incision itself (whatever the type of incision) but due to the release of endogenous mediators such as bradykinine, serotonin and certain types of prostaglandin. Beside that raising in tissue tension within the inflamed area is another cause. Also, other researchers<sup>(22-24)</sup> stated that the type of incision had no influence on pain.

In the statistical comparison at day 1, day 3 and day 7 among treatment groups, no significant differences in swelling were noticed. This may be due to the fact that post-operative swelling is mainly due to local oedema caused by accumulation of fluid exudates in the interstitial tissue spaces.<sup>(5)</sup> Also, other researchers<sup>(2, 3, 24-26)</sup> mentioned that the type of incision appear to have no effect on post-operative swelling, and they concluded that the oedema was caused by the reflection of the periosteum and not by making a relaxing incision. Also the damage to the periosteum probably caused more oedema. However, McCagie<sup>(27)</sup> insisted that when some surgeons extend the incision into the sulcus (as in standard, modified and S-shape), although over extension in this area is not likely to encounter major vessels, a venous plexus may be encountered which may give rise to a brisk ooze resulting in more swelling. According to this opinion, the envelope incision will avoid this complication, since its anterior extension being confined to the

gingival trough: The deeper the tooth the further this incision is extended anteriorly, and the papillae seem to heal well, but no one has studied these points in details.<sup>(27)</sup>

The results of trismus showed that the highest degree was recorded in one day period. The extra-pain that had been recorded in this interval is probably responsible for this reflectory trismus.<sup>(19, 28)</sup>

However, Sowray<sup>(29)</sup> wrote that there was a relation between the cheek swelling and trismus. If the patient had a marked swelling of the cheeks, then there was a concomitant degree of trismus, but these results disagree with those of the present study since no massive extra-oral swelling was recorded in all groups in this study. Furthermore, no significant differences were observed among treatment groups at one day period. The same thing was true for 3 days and 7 days intervals. This may be due to the strong inter-relation between post-operative pain and trismus indicating that the pain is the main reason for reduced mouth opening following removal of impacted mandibular third molars.<sup>(29, 30)</sup>

The results of trismus in this study agree with other studies<sup>(19, 28-31)</sup> who concluded that the trismus was reduced as a result of the reduction of pain and swelling at 3 days and 7 days intervals.

## CONCLUSION

The type of incision appeared to have no effect on post-operative complaints following surgical removal of impacted mandibular third molars at these intervals and further investigations are recommended for longer post-operative periods.

## REFERENCES

- 1) Koerner KR. Basic procedures in oral surgery. *Dent Clin North Am.* 1994; 38(2): 255-271.
- 2) Al-Sandook TA, Kaskos HH, Suliman MS. Effectiveness of NSAIDs on post-operative complaints following lower third molar surgery. *Al-Rafidain Dent J.* 2003; 3(2): 116-126.
- 3) Sabur JJ. Clinical evaluation of the dexamethasone and piroxicam for the control of swelling, trismus and pain

- following the removal of impacted lower third molar. MSc thesis. College of Dentistry. University of Baghdad. 1993.
- 4) Ross R, White CP. Evaluation of hydr-ocortisone in prevention of post-operative complaints after oral surgery. *J Oral Surg.* 1985; 16: 220-226.
  - 5) Forsgren H, Heimdahl A, Johansson B, Krekmanov L. Effect of application of cold dressings on post-operative course in oral surgery. *Int J Oral Surg.* 1985; 14: 223-228.
  - 6) Hill CM, Mostafa P, Thomas DW, Newcombe RG, Walker RV. Nerve morbidity following wisdom tooth removal under local and general anaesthesia. *Br J Oral Maxillofac Surg.* 2001; 39: 419-422.
  - 7) Renton T, McGurk M. Evaluation of factors predictive of lingual nerve injury in third molar surgery. *Br J Oral Maxillofac Surg.* 2001; 39: 423-428.
  - 8) Peterson LJ. Contemporary Oral and Maxillofacial Surgery. 2<sup>nd</sup> ed. CV Mosby Co, St Louis. 1993; Pp: 225-260.
  - 9) Wadhvani KK, Garg A. Healing of soft tissue after different types of flap designs used in periapical surgery. *Endodontol.* 2004; 16: 19-22.
  - 10) Sekhar CH, Narayanan V, Baig MF. Role of antimicrobials in third molar surgery: Prospective, double blind, randomized, placebo-controlled clinical study. *Br J Oral Maxillofac Surg.* 2001; 39: 134-137.
  - 11) MacGregor AJ. The Impacted Lower Wisdom Tooth. Oxford University Press, Oxford. 1985; Pp: 65-72.
  - 12) Howe GL, Bastiaan RJ. Minor Oral Surgery. 3<sup>rd</sup> ed. John Wright and Sons, Ltd. Bristol. 1985; Pp: 131-134.
  - 13) Alling CC, Helfrick JF, Alling DA. Impacted Teeth. WB Saunders Co, Philadelphia. 1993; Pp: 167-202.
  - 14) Killey HG, Seward GR, Kay LW. An Outline of Oral Surgery. Part One. Revised Reprint. John Wright and Sons, Ltd. Bristol. 1975; Pp: 25-54.
  - 15) Liloyd CJ, Earl PD. Metronidazole: Two or three times daily- A comparative controlled clinical trial of the efficacy of two different dosing schedules of metronidazole for chemoprophylaxis following third molar surgery. *Br J Oral Maxillofac Surg.* 1994; 32: 165-167.
  - 16) Hamad ShA. Clinical evaluation of topical tetracycline, metronidazole and chlorhexidine for prevention of dry socket following surgical removal of impacted lower third molars. MSc thesis. College of Dentistry. University of Mosul. 1997.
  - 17) Bracco P, Debernardi C, Coscia D, Pasqualini D, Pasqualicchi O, Calabrese N. Efficacy of rofecoxib and nimesulide in controlling post-operative pain in oral surgery: A randomized comparative study. *Curr Med Res Opin.* 2004; 20(1): 107-112.
  - 18) Beirne OR, Camilleri GE. The effect of methyl prednisolone on pain, trismus and swelling after removal of third molars. *Oral Surg Oral Med Oral Pathol.* 1985; 61: 134-139.
  - 19) Van der Westhuijzen AJ, Roelofse JA, Becker PJ. Randomized double blind comparison of tiaprofenic acid and diclofenac sodium after third molar surgery. *Oral Surg Oral Med Oral Pathol.* 1994, 78(5): 557-566.
  - 20) Ten Bosch JJ, Van Gool AV. The interrelation of post-operative complaints after removal of mandibular third molar. *Int J Oral Surg.* 1977; 6: 22-28.
  - 21) Hettmansperger TP, Sheather SJ. Confidence intervals based on interpolated order statistics. *Stat Prob Letters.* 1986; 4(2): 75-79.
  - 22) Troullos ES, Hargreaves KM, Butler DP, Dionne RA. Comparison of non-steroidal anti-inflammatory drugs, ibuprofen and flurbiprofen with methyl prednisolone and placebo for acute pain, swelling and trismus. *J Oral Maxillofac Surg.* 1990; 48: 945.
  - 23) Chang DJ, Fricke JR, Bird SR, Bohidar NR, Dobbins TW, Geba GP. Rofecoxib versus codeine / acetaminophen in post-operative dental pain: A double blind, randomized, placebo and active comparator-controlled clinical trial. *Clin Ther.* 2001; 23: 1446-1455.
  - 24) Chang DJ, Desjardins PJ, Chen E, Polis AB, McAvoy M, Mockoviak SH. Comparison of the analgesic



- efficacy of rofecoxib and enteric coated diclofenac sodium in the treatment of post-operative dental pain: A randomized, placebo-controlled clinical trial. *Clin Ther.* 2002; 24: 490-503.
- 25) Kalamchi S, Hensher R. The management of impacted mandibular third molars. *Dent Update.* 1987; 14: 437-440.
- 26) Kugelberg CE. Periodontal healing two and four years after impacted lower molar surgery. *Int J Oral Maxillo-fac Surg.* 1990; 19: 341.
- 27) McCague J. A standard procedure for the removal of unerupted wisdom teeth. *Dent Prac.* 1957; 7: 150-154.
- 28) Cameron IW. An investigation into some of factors concerned in the surgical removal of the impacted lower wisdom tooth including double blind trial of chymoral. *Br J Oral Surg.* 1980; 18: 112-124.
- 29) Sowray JH. An assessment of the value of lyophilized chymotrypsin in the reduction of post-operative swelling following surgical removal of impacted wisdom teeth. *Br Dent J.* 1961; 21: 130-133.
- 30) Pederson A, Mersk-Moller O. Volumetric determination of extraoral swelling from stereophotographs. *Int J Oral Surg.* 1985; 14: 229-234.
- 31) Osborn TP, Frederickson G, Small IA. A prospective study of complications related to mandibular third molar surgery. *J Oral Maxillofac Surg.* 1985; 43: 767.