

Histological Studies on Pancreatic Tissue in Diabetic Rats by Using Wild Cherry

Yasamin Thamer Qadori

ABSTRACT :

BACKGROUND:

A lot of debate about wild cherry is published especially it's hypoglycemic and antioxidant effects, this study is conducted to see the histological, biochemical and morphometrical changes in rats pancreas.

OBJECTIVE:

Wild cherry possesses a mild stimulatory action on pancreatic islets. Also it can be regarded as protective to islets of Langerhans in diabetic rats.

MATERIAL & METHODS:

Fifteen Rats were employed in this study. they were divided into 3 groups (5 normal controls, 5 given alloxan, 5 Treated with cherry herbs after given alloxan).

RESULTS:

The normal control group resulted , no abnormalities in pancreatic tissue , while the group of alloxan rats showed marked reduction in the diameter of islets of langerhans with necrosis cells, it also showed increase in blood sugar (as compared with the control Group). The wild cherries group showed apparently normal pancreatic tissue and islets of langerhans diameter, also normal blood sugar (as compared with the alloxan group).

CONCLUSION:

Islets cells destruction was evident after alloxan administration, while protection action was prominent after wild cherry in diabetic rats.

KEY WORDS: wild cherry, diabetes mellitus, pancreas.

INTRODUCTION:

The pancreas is a large gland situated near the junction of the stomach and small intestine, it is one of the accessory organs that contribute secretion to the digestive tract .It performs many functions that are important and are interrelated with the activities of many other organs of the endocrine system. In general the pancreas consists of two parts: 1) Exocrine glands which are responsible for enzyme production for digestion, such as chymotrypsin, trypsin and lipases. 2) Endocrine glands which known as the islets of Langerhans which are predominantly made up of beta cells and alpha cells, granules of alpha cell stain red, granules of beta cells are blue by using haematoxylin and eosins (H&E) stain ,Alpha cells tend to be situated more periphery in the islets ⁽¹⁾ . Beta cells lie deeper and have some very important function: It is produce the hormone insulin that controls blood sugar levels. Insulin stimulates skeletal muscle fibers to convert glucose into glycogen and amino acids into protein. And

causes liver cells to convert glucose into glycogen and to prevent conversion of fats and proteins into glucose.

Destruction of beta cells is the main cause of Type 1(insulin dependant diabetes mellitus IDDM). Which causes very little or no insulin circulating in the blood. In Type (2 Non-insulin dependant diabetes mellitus), beta cells undergo a slow degeneration causing insufficient insulin to be produced, and abnormalities in beta cell function and secretion. ^(2,3) . there is insulin resistance where the ability to remove glucose from the blood is reduced by over 80%.

Wild Cherry- *Prunus serotina* have been an item of human food for several thousands of years. As the main ancestor of the cultivated sweet cherry, the Wild cherry is one of the two cherry species which supply most of the world's commercial cultivars of edible cherry (the other is the Sour cherry *Prunus creases*, mainly used for cooking; a few other species have had a very small input) ⁽⁵⁾ . Various cherry cultivars are now grown worldwide wherever the climate is suitable; the number of cultivars is now very large. The species has also escaped from cultivation and become naturalized in some temperate regions, including southwestern Canada,

Department of Anatomy College of Medicine
/University of Baghdad.

Japan, New Zealand, and the northeast and northwest of the United States.⁽⁴⁾

According to a study funded by the Cherry Marketing Institute presented at the Experimental Biology 2008 meeting in San Diego, rats that received whole tart cherry powder mixed into a high-fat diet did not gain as much weight or build up as much body fat, and their blood showed much lower levels of inflammation indicators that have been linked to heart disease and diabetes. In addition, they had significantly lower blood levels of cholesterol and triglycerides than the other rats.^(6,8) They also are potent antioxidants, highly active chemicals that have

been increasingly associated with a variety of health benefits, including protection against heart disease and cancer.⁽⁷⁾

MATERIAL AND METHODS:

Animals:

A total 15 adult male Swiss albino rats, weight (200-250) gm , were used in this study ,they were isolated in a relatively controlled environment at temperature of about 25C^o, in the "Animal breeding center " / college of medicine / university of Baghdad . They were given food and free access to water. Rats were divided into three groups as mentioned in table 1

Table 1: Animal grouping

Groups	Number	Note
1 st	5	Given water only
2 nd	5	Given alloxan*
3 th	5	Treated with cherry herbs** after Given alloxan

* Alloxan was given in a dose of 120mg/Kg body weight⁽⁹⁾ .Given to fasted rats injected intraperitoneally⁽¹⁰⁾ .

**Cherry herbs given orally, ones time daily in 1-2 ml /kg dose⁽⁵⁾ .

Animal were sacrificed after 2,4 weeks of experiment. Before sacrifice, rats were anaesthetized by ether, and then the abdominal cavity was opened, pancreas was dissected and blood sample was obtained. Pancreatic blocks were processed for haematoxylin and eosins (H&E) stain⁽¹²⁾ . Morphometrical studies involved in this study were calibration of diameter of the islets (using eye piece micrometer), counting the number of islets / field. Finally results were statistically analyzed using "student-T" test (for significant difference between two groups).P value less than 0.05 was considered to be significant⁽¹³⁾ .

RESULTS:

Blood sugar level:

In this study, blood sugar level of normal control animal showed normal level after 2nd weeks (112mg/dl) and (120mg/dl) after 4th weeks (table 2). On the other hand, alloxan-treated rats showed elevation in blood glucose level (hyperglycemia) ,animals were significantly (P <0.05) raised (350± 2.8mg/dl) after 2nd weeks and (380± 2.5mg/dl) after 4th weeks in experimental animals as compared with that of control groups (112, 120 mg/dl) respectively (table 2) .Cherry's herb fed diabetic rats manifested features of improvement of tissue injury after alloxan treatment, indicated by healthy normal looking of endocrine gland after 2nd weeks of the experiment (140± 2. 8 mg/dl) and (133± 2.9 mg/dl) after 4th weeks (table 2).

Histological & Morphometrical changes:

Pancreatic tissue of normal control arrayed showed normal distribution of islet of Langerhans within the exocrine part, islets were regular with well defined boundaries. Their cells had oval or rounded nuclei after 2nd and 4th weeks (Fig 1). Morphometrical results of pancreatic islets were parallel to a normal pancreas that is described in the histology text books after 2nd weeks (3.3 ± 0.6 µm) and (3.9± 0. 6 µm) after 4th weeks (table4)(Fig4) , the numbers of islets of Langerhans / field were found to be normal in control after 2nd weeks (4.5 ±1.3) and (5.3±2.3) after 4th weeks (table3)(Fig5) . On the other hand, alloxan –Diabetic pancreatic tissue showed shrinkage of islets Langerhans in size after 2nd weeks and 4th weeks (Fig2) signs of necrosis of β-cell destruction and reduction of number of islets / field after 2nd weeks (2.85 ±1.6) and (1.83±0.7) after 4th weeks (table3)(Fig5) also significant reduction in diameter after 2nd and 4th weeks (2.31 ± 0.9 µm) (2.1± 0.7 µm) respectively (table4) (Fig4). In diabetic pancreatic tissue treated with cherry's herbs showed islets cell looks like normal tissue after 2nd and 4th weeks (Fig3), also showed increase in size of the diameter of islets of Langerhans after 2nd weeks (3.4 ± 0.6 µm) and (3.3 ± 0.4 µm) after 4th weeks, numbers of islets / field were found to be normal in diabetic pancreatic tissue treated with cherry's herbs (5.6 ± 1.2) and (5.8± 1.6) (table3)(Fig5).

Table 2: Blood sugar level in experimental group after 2, 4 weeks

Groups	Number	Blood sugar level mg/dl after 2 nd weeks	Blood sugar level mg/dl after 4 th weeks
Control	5	112	120
alloxan	5	350 ± 2.8*	380 ± 2.5*
alloxan+cherry herbs	5	140 ± 2.8	133 ± 2.9

* significant at P<0.05 . Blood sugar ± standard deviation.

Table 3: Showing the number of islets of Langerhans / field for experimental group after 2, 4 weeks

Groups	Number	Number of islets/field after 2 nd weeks	Number of islets/field after 4 th weeks
Control	5	4.5 ± 1.3	5.3 ± 2.3
alloxan	5	2.85 ± 1.6*	1.83 ± 0.7*
alloxan+cherry herbs	5	5.6 ± 1.2	5.8 ± 1.6

* significant at P<0.05 . Data are expressed as mean number of islets / field ± standard deviation.

Table 4: The differences of the diameter of islets of Langerhans throughout the Investigation after 2, 4 weeks

Groups	Number	Diameter of islets (μm) after 2 nd weeks	Diameter of islets (μm) after 4 th weeks
Control	5	3.3 ± 0.6	3.9 ± 0.6
alloxan	5	2.31 ± 0.9 *	2.1 ± 0.7*
alloxan+cherry herbs	5	3.4 ± 0.6	3.3 ± 0.4

* significant at P<0.05 . Data are expressed as mean diameter of islets (μm) ± standard deviation

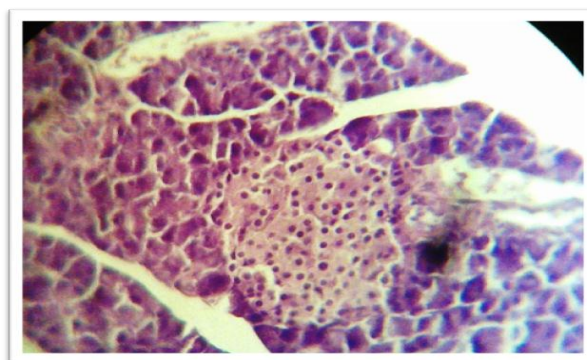


Fig 1: Control pancreatic tissue, showed normal distribution of islet cells, H&E stain 400x

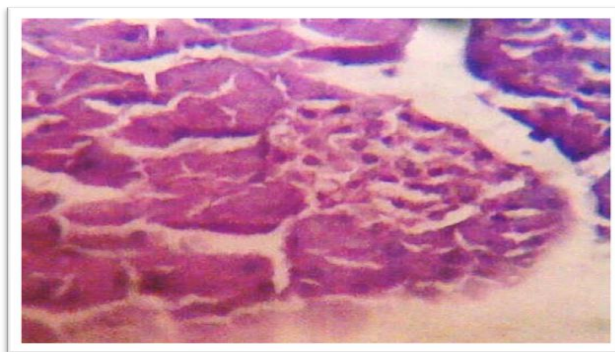


Fig 2:Alloxan-Diabetic pancreatic tissue showed shrinkage ,sing of necrotic islet cells, H&E stain 400x

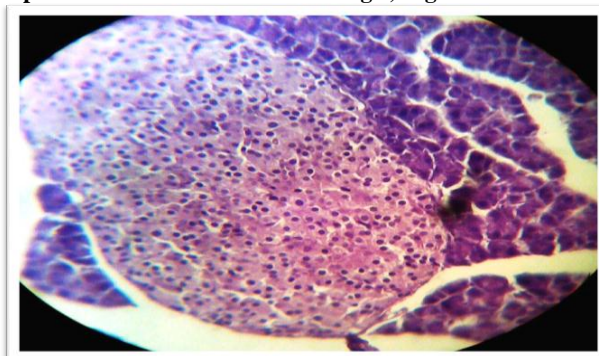


Fig 3: Diabetic pancreatic tissue treated with wild cherry showed islets cells looks like normal, H&E stain 400x

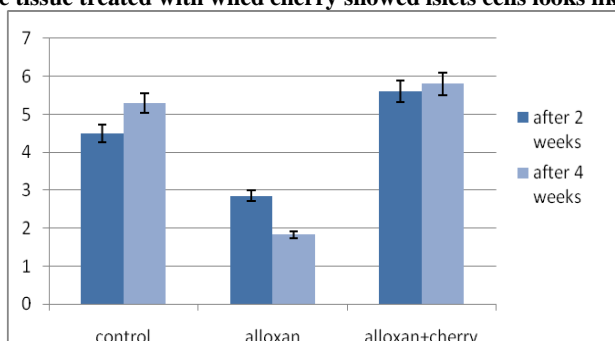


Fig 4: Diameter of the islets of Langerhans in experimental group after 2, 4 weeks

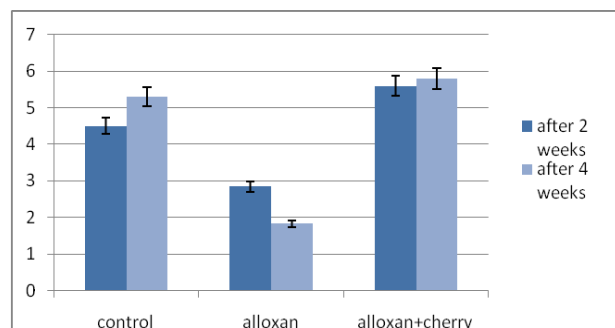


Fig 5: Mean of number of islets of Langerhans / field in experimental group after 2, 4 weeks

DISCUSSIONS:

Alloxan-treated rats, showed significant elevation of blood glucose level are in favor of destructive mechanism of β -cells. Due to a diabetogenic agent (alloxan) which reduces insulin secretion, ⁽¹⁴⁾ These results agree with Goldberg, R. (1998). In the Cherries group, showed normal looking because of the cherries contain anthocyanine, the red pigment. ^(6,8), abundant in cherries that could help lower blood sugar levels in animal's diabetes by regeneration of Beta cells, the mechanism of action by which these anthocyanine boost insulin production is not known. This study agrees with Roy, M ^{2009 (2)} and Mansour H, et al.2002 ⁽¹⁷⁾. the mechanism of this protective action of cherries against alloxan –tissue damage through the anthocyanidin and proanthocyanidin flavonoids in cherries which have antioxidant properties that can help damage cells, this study agree with Tall JM , et al. 2004⁽⁵⁾. (Table 3, 4) (Fig 3, 4, 5).

REFERENCES:

1. Johnson, R, Fueling Body Activities Digestion. In: Biology.6th ed.,New York , McGraw-Hill, , 2002:1030-31.
2. Roy, M., (2009) "Beta Cells and Diabetes - Regeneration of Beta Cells with Herbs. *EzineArticles*
3. Barron, J. (2007) "Diabetes the Echo Effect. Diabetes - program Alternative Health Newsletter.
4. Den Virtuella, F.: *Prunus avium* .2004:11-13.
5. Tall JM, Seeram NP, Zhao C, Nair MG, Meyer RA, Raja SN. "Tart cherry anthocyanins suppress inflammation-induced pain behavior in rat". *Behav. Brain Res.* 2004;153: 181.
6. "Tart Cherries May Reduce Heart/Diabetes Risk Factors". Newswise, Retrieved on July 7, 2008.
7. Chemicals Found In Cherries May Help Fight Diabetes. (Dec. 21, 2004) ScienceDaily.
8. Seymour EM, Singer AAM, Bennink MR, Bolling SF.(2007) Cherry-enriched diets reduce metabolic syndrome and oxidative stress in lean Dahl-SS rats . *Experimental Biology*
9. Buko, V.; Lukiveskaya, O.; Nikiti, V.; Tarasov, Y. and Zavodink, L "Hepatic and pancreatic effect of polyenylphosphatidylcho line in rats with alloxan induced diabetes ". *Cell biochem. Funct.* 1996; 14:131-37.(Medline).
10. Ohno, T.; Kitoh, J; Yamashita ,K. and Ischikawa, Y. "Toxin induced insulin dependent diabetes mellitus in the musk ". *Life Sci.*, 1998;63:455-62.
11. Lysias-Derrida , (2007) - Fertile Trace Eidoloned, MDidea.com
12. Stevens, A. In: Bancroft, J. and Stevens, A. (1982). [Theory and practice of histological Techniques]2nd ed., Churchill livingstone , London,
13. Danial , W. Hypothesis , testing. In [Biostatistics A foundation of for Analysis in the health science]. Weily J and Sons, London 1988:16-18.
14. Goldberg ,R. Prevention and treatment of diabetes and its complication. *Medical clinics of north America* , 1998;82:805-21.
15. Junquera I and Carneiro J basic histology 10th ed , Lange medical books ,New York , 2003;291-320.
16. Adeghate E and Parves S. "Nitric oxide and neuronal and pancreatic beta-cell death" . *Toxicol.*, 2000;153:143-56.
17. Mansour H, Newairy AYousif Mand Sheweita S. "Biochemical study on the effects of some Egyptian herbs in alloxan-induced diabetic rats". *Toxicology* 2002:221-28 .

