

Laparoscopic Varicocelectomy for Bilateral Varicoceles in Infertile Males .

Saad D. Farhan* ,Muayed Abass Fadhel**

ABSTRACT:

BACKGROUND :

Varicoceles, present in 15% to 20% of men, are the most common abnormal finding among men presenting with infertility. Despite the very long history of the disease and many records on different surgical and radiological solutions, the ideal method of spermatic vein ligation for varicocele is still a matter of controversy. The perfect technique would be one that preserves testicular function and eliminates the varicocele with a low rate of recurrence, hydrocele formation and any other complications.

OBJECTIVE:

To assess the efficacy of laparoscopic Varicocelectomy for management of bilateral palpable varicoceles in infertile males.

METHODS:

We analysed the result of 25 patients presented with history of infertility and diagnosed to have bilateral palpable varicoceles treated in our department with Bilateral laparoscopic ligation of the spermatic vessels between January 2009 and November 2010.

RESULTS:

The average operative (Bilateral Laparoscopic Varicocelectomy) time was 34 minutes. There were no intra operative complications in the study group. Hydrocele formation was seen in 3 (6%) patients recurrence was seen in one (2%) patient .The average hospital stay was 18 hours. postoperative analgesics (1-2) doses , daily activities initiation usually started after 48 hrs and physical exercise 72 hrs . non of the patient has developed an atrophic testis as a result of the laparoscopic procedure. eighteen patients (72%)of the patients had improvement of the seminal fluid parameters During follow up period (6 months),with seminal fluid analysis, clinical and ultrasonic examination.

CONCLUSION:

Laparoscopic varicocele ligation is a simple and safe technique, causing minimal morbidity and enabling rapid return to normal activity.

KEYWORDS: laparoscopy ,varicocele, male infertility

INTRODUCTION:

Varicocele has been described as early as the first century by B.C. Amelius Cornelius Celsus wrote, "when the disease has spread also over the testicle and its cord the testicle sinks a little lower, and becomes smaller than its fellow, in as much as its nutrition has become defective⁽¹⁾. The earliest conventional description of a surgical treatment for a

varicocele was performed in 1885 by Barwell ⁽²⁾. However, it was just in the last two decades that early adolescent-onset varicoceles were demonstrated to have a negative influence on testicular growth and function ⁽³⁾.

The detrimental effect of varicocele on spermatogenesis in the infertile male is manifested by low sperm count, decreased sperm motility and low percentage of normal sperm morphology together or in different combinations. Therefore, in well-verified cases operation is recommended⁽⁴⁾.

*,Department of Urology, Medical College, Baghdad University.

Senior Urologist ; Medical City, Surgical Specialties Hospital.

**Surgical Departement, Baghdad Medical College Senior General Surgeon, Baghdad Teaching Hospital- Medical City.

LAPAROSCOPIC VARICOCELECTOMY

Despite the very long history of the disease and many records on different surgical and radiological solutions, the ideal method of spermatic vein ligation for varicocele is still a matter of controversy. The perfect technique would be one that preserves testicular function and eliminates the varicocele with a low rate of recurrence, hydrocele formation and any other complications.⁽⁵⁾

We analysed the results of 25 patients presented with history of infertility and diagnosed to have bilateral palpable varicoceles treated with Bilateral laparoscopic ligation of the spermatic vessels between January 2009 and November 2010.

MATERIALS AND METHODS:

This Prospective study included all consecutive adults patients (age ranged between 18-42years old) who presented with history of infertility and newly diagnosed with Bilateral palpable varicocele (grade 1-3)with an indication for surgical treatment who were seen in the department of urology ,Medical City, during January 2009 and November 2010.All varicoceles were graded ,Based on findings from preoperative physical examination Performed with and without valsalva maneuver in patients standing in a warm room-and scrotal Doppler ultrasound .

The 25 Patients with 50 varicoceles . After providing informed consent ,all patient underwent laparoscopic Bilateral varicocelectomy . After

induction of general anaesthesia, an incision was made just below the umbilicus and a Veres needle was placed into the peritoneal cavity. Three to four liters of carbon dioxide were insufflated through the Veres needle to create a pneumoperitoneum with a pressure of 12 mm Hg. The needle was removed and a 10mm trocar was inserted through the same incision into the peritoneal cavity. A 10mm laparoscope was inserted through the trocar attached to a video-camera and the peritoneal cavity was viewed on a television monitor. In addition to the laparoscope insertion site, at least 2 additional working ports are required to provide access for operating instruments . One access port is positioned halfway between umbilicus and the ipsilateral anterior iliac spine, and another one is placed in the mirror position on the other side. The internal inguinal ring was identified by the appearance of the vas deferens as it separated from the spermatic cord and entered into the deep pelvis. The retroperitoneum was incised along the internal spermatic vessels for approximately 1cm using scissors. After the internal spermatic vessels were separated from the underlying psoas major with forceps, they were dissected from the adjusting Lymphatic vessels and clips(2-4 clips) applied to clamp the vessels.(figures 1-4).

All patients were followed up with seminal fluid analysis and scrotal Doppler Ultrasonography for a period of 3-6 months post operatively.

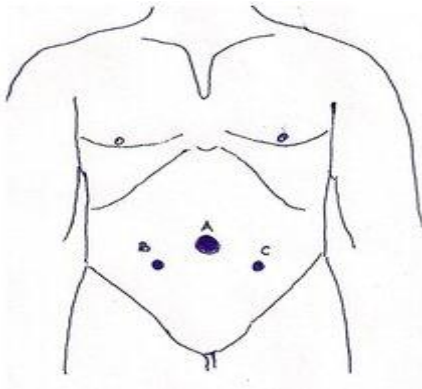


Figure 1: Port Configuration

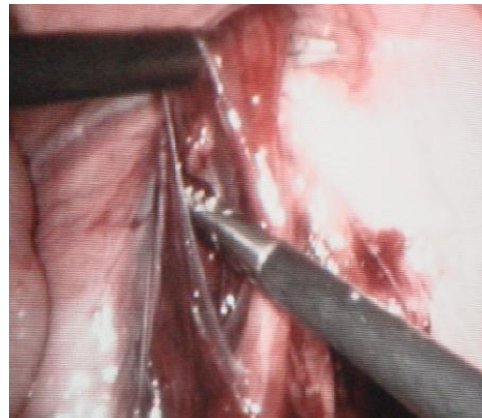
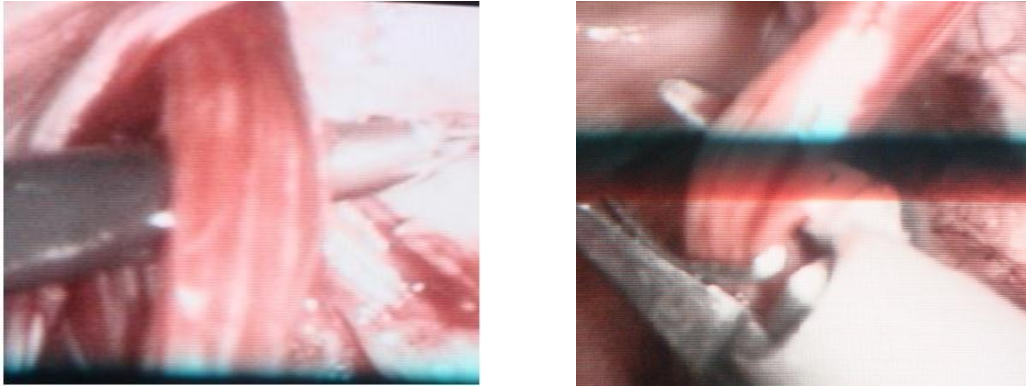


Figure 2: Laparoscopic dissection of the gonadal vessels



Figures 3,4: Operative Procedures.

RESULTS:

The operative details are shown in Table 1. The average operative time (Bilateral Laparoscopic Varicocelectomy) was 34 minutes. There were no intra operative complications in the study group. Among the postoperative complications, hydrocele formation was seen in 3 (6%) patients (non of the patients developed bilateral hydroceles), recurrence (Persistence of venous reflux on color Doppler ultrasonography) was seen in one (2%) patient .The average hospital stay was 18 hours. postoperative analgesics (1-2) doses and Non of the patient required opiate analgesia, daily activities initiation

usually started after 48 hrs and physical exercise 72 hrs. During followed up period all patients were asymptomatic and had marked reduction in the size of the varicoceles . So far, testicular growth appears to be unaffected and no patient has developed an atrophic testis as a result of the laparoscopic procedure. Ten to eighteen patients (40, 72%) of the patients had improvement of the seminal fluid parameters During follow up period (3-6 months),with seminal fluid analysis, clinical and ultrasonic examination.

Table 1: Operative Results

Operative Results		
Operative Time	28-40 minutes	mean 34 minutes
Intra Operative Complications	No	
Hospital Stay	12-24 hours	Mean 18 hours
Pneumoscrotum	1(2%)	
Subcutaneous emphysema	2(4%)	
Analgesia	(1-2)doses	Mean 1.5
Daily activity	24-72	Mean 48hours
Physical exercise	48-96 hours	Mean 72 hours
Hydrocele	3 (6%)	
Recurrence	1 (2%)	
Testicular atrophy	NO	
Seminal fluid parameters improvement	18 (72%) at 6 moths	

DISCUSSION :

A variety of surgical approaches have been advocated for varicocelelectomy. They include minimally invasive procedures, such as laparoscopic varicocele ligation, transvenous percutaneous embolization, and the traditional open surgical approach (retroperitoneal, inguinal and subinguinal).⁽⁶⁾ To date, there have been no randomized, controlled, prospective clinical studies that compare various techniques to describe the best method for the treatment of varicocele in infertile men.⁽⁷⁾

Recently, the laparoscopic approach to varicocele ligation has gained favor for bilateral varicoceles. The built-in magnification of the laparoscope facilitates identification of the spermatic veins and artery, potentially reducing the risk of recurrence of the varicocele and of ischemic damage to the testis. Magnification also allows the surgeon to preserve lymphatics and the genital branches of the genitofemoral nerve that runs along the spermatic vessels, which may reduce lymphocele formation and postoperative pain. Laparoscopic management of varicoceles in adults may reflect the excellent visibility of the posterior abdominal wall achieved using the laparoscope, which allows a thorough search of sites known to be responsible for recurrent varicoceles, namely renal, vas associated, pelvic, and retropubic cross-over veins.⁽⁸⁾

Experienced laparoscopic surgeons report a success rate in adults of 93% to 100%, a varicocele recurrence rate of 2% to 10%, and a hydrocele formation rate of zero to 7%^(9,10) leading some medical centers to employ laparoscopy when intervention is indicated. Hydrocele formation is related to failure to preserve the lymphatic vessels associated with the spermatic cord. Franco.⁽⁸⁾ Suggests complication rates are relatively low for Laparoscopic varicocelelectomy (LV) except for the hydrocele rate, which has been similar to that encountered with the open Palomo approach in case of adolescent male. Keys et al.⁽¹¹⁾ had a hydrocele rate of 12.5%, Pini Prato et al.⁽¹²⁾ 12%, and Méndez-Gallart et al.⁽¹³⁾ 13.5% using laparoscopic mass ligation varicocelelectomy. However, there appears to be a statistically significant decrease in hydroceles when the internal spermatic vessels are simply ligated rather than ligated and divided⁽¹⁴⁾. This study had hydrocele formation in 3 patients (6%). This relatively low incidence may be related to the meticulous dissection of the gonadal vessels from the adjacent lymphatic vessels and we simply ligate (clip) the vessels.

Beck et al.⁽¹⁵⁾ suggested that unligated small internal spermatic veins may be a cause of varicocele recurrence. Rothman et al.⁽¹⁶⁾ also concluded that recurrences are due to either recollateralization or failure to ligate all branches of the venous plexus. Keys et al.⁽¹¹⁾ had a recurrence rate of 8.3%. McManus et al.⁽¹⁷⁾ had none. Méndez-Gallart et al.⁽¹³⁾ showed that recurrence rates and complication rate of LV are similar to those reported with open surgery. Cimador et al.⁽¹⁸⁾ demonstrated that ligation of the artery does not impair testicular growth and thus it is more useful and safe to interrupt the artery to avoid recurrence due to periarterial venous network. Agnifilli et al.⁽¹⁹⁾ suggest that laparoscopic high mass ligation of both testicular artery and vein has very low recurrence rates. Similarly, this study had recurrence in one side of one patient (2%). Kattan et al.⁽²⁰⁾ concluded that LV with internal spermatic artery ligation has lower recurrence rate than without internal spermatic artery ligation with no increase in hydrocele or testicular atrophy rate. This study also had no testicular atrophy during follow up period with clinical and ultrasonic examination.

Tong et al.⁽²¹⁾ demonstrated that lymphatic-sparing LV is a safe, effective and reliable treatment. Huk et al.⁽²²⁾ and Parott et al.⁽²³⁾ carried on comparative assessment of artery-ligating and artery-preserving varicocelelectomy and found that ligation of vein and artery produced better improvement of semen characteristics and percentage of pregnancies in comparison with artery-sparing technique. Even Student et al.⁽²⁴⁾ confirmed using colour Doppler sonography, that ligation of the testicular artery does not lead to major changes in testicular blood supply or sperm quality, Yamamoto et al.⁽²⁵⁾ Diamond et al.⁽²⁶⁾ demonstrated the effect of varicocelelectomy on post-operative spermatogenesis and showed that sperm density and motility improved significantly in the artery-ligated group. Similarly our approach was aimed to clip both the artery and veins.

Although The percentage of improvement of seminal fluid parameters was very promising (72%) at 6 months period in our study, The exact spontaneous pregnancy rate was difficult to estimated as most of our patients was not compliant with next visit when pregnancy achieved.

CONCLUSION:

Laparoscopic varicocele ligation is a simple and safe technique, causing minimal morbidity and enabling a rapid return to normal activity.

REFERENCES:

1. T.B. Hargreave. Varicocele—a clinical enigma. *Br. J. Urol.* 1993;72:401-408 Crossref.
2. R. Barwell. One hundred cases of varicocele treated by the subcutaneous wire loop. *Lancet* i 1885;978 Crossref.
3. C. Pintus, M.J. Rodriguez Matas, C. Manzoni, L. Nanni, L. Perrelli. Varicocele in pediatric patients: comparative assessment of different therapeutic approaches *Br. J. Urol* 2001;57:154 - 57.
4. Cayan S, Shavakhabov S, Kadioğlu A. Treatment of palpable varicocele in infertile men: a meta-analysis to define the best technique. *J Androl.* 2009;30:33-40. Epub 2008 Sep 4.
5. Al-Said S, Al-Naimi A, Al-Ansari A, Younis N, Shamsodini A, A-sadiq K, Shokeir AA. Varicocelectomy for male infertility: a comparative study of open, laparoscopic and microsurgical approaches. *J Urol.* 2008; 180:266-70. Epub 2008 May 21.
6. Mazzoni G, Fiocca G, Minucci S, et al: Varicocele: A multidisciplinary approach in children and adolescents. *J Urol* 1999; 162:1755.
7. Ayeche-Díaz A, Oscoz-Lizarbe M, Pérez-Martínez A, Pisón-Chacón J, Bento L: Treatment of adolescent varicocele: is percutaneous embolization better? *Cir Pediatr;* 2009;22:134-38.
8. Franco I. Laparoscopic varicocelectomy in the adolescent male. *Curr Urol Rep;* 2004; 5:132-6.
9. Hirsch IH, Abdel-Meguid TA, Gomella LG: Postsurgical outcomes assessment following varicocele ligation: Laparoscopic versus subinguinal approach. *Urology* 1998;51:810
10. Abdulmaaboud MR, Shokeir AA, Farage Y, et al: Treatment of varicocele: A comparative study of conventional open surgery, percutaneous retrograde sclerotherapy, and laparoscopy. *Urology* 1998; 52:294.
11. Keys C, Barbour L, O'Toole S, Sabharwal A: Laparoscopic surgery for varicoceles in children: an audit in a single centre. *J Laparoendosc Adv Surg Tech A;* 2009;19 Suppl 1: S107-9.
12. Pini Prato A, MacKinlay GA: Is the laparoscopic Palomo procedure for pediatric varicocele safe and effective? Nine years of unicentric experience. *Surg Endosc;* 2006; 20: 660-64.
13. Méndez-Gallart R, Bautista-Casasnovas A, and Estevez-Martínez E, Varela-Cives R: Laparoscopic Palomo varicocele surgery: lessons learned after 10 years' follow up of 156 consecutive pediatric patients. *J Pediatr Urol;* 2009; 5: 126-31. Epub 2008 Dec 10.
14. Hassan JM,etal , Hydrocele formation following laparoscopic varicocelectomy, *J Urol.* 2006;175:1076-79 .
15. Beck EM, Schlegel PN, Goldstein M: Intraoperative varicocele anatomy: a macroscopic and microscopic study. *J Urol;* 1992;148:1190-94.
16. Rothman CM, Newmark H 3rd, Karson RA: The recurrent varicocele--a poorly recognized problem. *Fertil Steril;* 1981;35:552-56.
17. McManus MC, Barqawi A, Meacham RB, Furness PD 3rd, Koyle MA: Laparoscopic varicocele ligation: are there advantages compared with the microscopic subinguinal approach? *Urology* 2004;64: 357-60; discussion 360-1.
18. Cimador M, Castagnetti M, Ajovalasit V, Libri M, Bertozzi M, De Grazia E: Sub-inguinal interruption of dilated veins in adolescent varicocele: should it be considered a gold standard technique? *Minerva Pediatr;* 2003;55:599-605.
19. Agnifili A, Schietroma M, Carlei F, De Berardis B, Pescosolido A, Giuliani A, Venturoni A, Amicucci G: Recurrences, testicular growth and semen parameters after laparoscopic Palomo varicocelectomy. *Chir Ital;* 2008; 60:549-54.
20. Kattan S. The impact of internal spermatic artery ligation during laparoscopic varicocelectomy on recurrence rate and short post operative outcome. *Scand J Urol Nephrol;* 2001;35:218-21.
21. Tong Q, Zheng L, Tang S, Du Z, Wu Z, Mei H, Ruan Q: Lymphatic sparing laparoscopic Palomo varicocelectomy for varicoceles in children: intermediate results. *J Pediatr Surg;* 2009;44:1509-13.
22. Huk J, Fryczkowski M, Bihun M, Połać R: Laparoscopic varicocele ligation. The comparative assessment of artery-ligating and artery-preserving varicocelectomy. *Wiad Lek;* 2001;54: 621-31.
23. Parrott TS, Hewatt L: Ligation of the testicular artery and vein in adolescent varicocele. *J Urol;* 1994; 152:791-3; discussion 793.

24. Student V, Zátura F, Scheinar J, Vrtal R, Vrána J: Testicle hemodynamics in patients after laparoscopic varicocelectomy evaluated using color Doppler sonography. *Eur Urol*; 1998;33: 91-3.
25. Yamamoto M, Tsuji Y, Ohmura M, Hibi H, Miyake K: Comparison of artery-ligating and artery-preserving varicocelectomy: effect on post-operative spermatogenesis. *Andrologia*; 1995;27:37-40.
26. Diamond DA, Xuewu J, Cilento BG Jr, Bauer SB, Peters CA, Borer JG, Mandell J, Cendron M, Rosoklija I, Zurakowski D, Retik AB: Varicocele surgery: a decade's experience at a children's hospital. *BJU Int*; 2009;104:246-9.