

The Effect of Hyaluronic Acid and Platelet-Rich Plasma on Soft Tissue Wound Healing: An Experimental Study on Rabbits

Wafaa K Fathi
BDS, MSc (Lec.)

Department Oral and Maxillofacial surgery
College of Dentistry, University of Mosul

الخلاصة

الأهداف: تهدف الدراسة إلى تقييم فوائد استخدام الصفايح البلازما وحمض الهيالورونيك عند استخدامها لوحدها أو مع بعضها على التئام الجروح .
الغنية. المواد وطرائق العمل: أجريت هذه الدراسة على (15 أرنباً) مجعياً وكان جميعها من الذكور وقسمت الحيوانات إلى ثلاث مجاميع وفقاً لفترات الشفاء (ثلاثة أيام، اسبوع، اسبوعان) كل مجموعة تحتوي على خمسة أرانب، اجري لكل أرنب اربع شقوق طولية في منطقة الظهر شقان في كل جهة ويبعد بمسافة (1.5 سم) بين شق واخر. وقد ملئت العيوب الشقية بمادة الصفايح الدموية الغنية البلازما وحمض الهيالورونيك، وخليط من كليهما وترك الاخير حكماً. ذبحت الحيوانات بعد اجراء العملية الجراحية وفقاً للفترات الزمنية المذكورة سابقاً. واخذت الخزع منها لغرض اجراء الفحص النسيجي عليها، لتقييم تأثير تلك المواد على تسريع التئام الجرح في الجلد. وبعد ذلك اجري التحليل الاحصائي باستخدام تحليل التباين ومدى دنكن المتعدد عند مستوى (ف ≥ 0.01). **النتائج:** التحليل النسيجي اوضح فرق معنوي بتحسن الجروح عندما عولجت بالصفايح الدموية الغنية البلازما لوحدها وخليط من حمض الهيالورونيك والصفايح الدموية الغنية البلازما عند مقارنتها بالجروح التي عولجت بخامض الهيالورونيك لوحدها او بمجموعة السيطرة في فترة ثلاثة ايام و سبعة ايام بعد اجراء العملية ولكن لوحض عدم وجود فروق ذات دلالة إحصائية في شفاء الجرح بين جميع الفئات في نهاية الأسبوع الثاني . **الاستنتاجات:** ان استخدام الصفايح الدموية الغنية البلازما وحمض الهيالورونيك معا سوف يسرع من التئام الجروح، في حين أن استخدام تركيز منخفض من حمض الهيالورونيك وحده لا يحسن من التئام الجروح مقارنة مع التئام الجرح الطبيعي.

ABSTRACT

Aims: This study aimed to evaluate the benefits of using platelet-rich plasma and hyaluronic acid when used alone or in combination with each other on wound healing. **Materials and methods:** The study performed on 15 adult male rabbits divided into three group according to healing periods (3,7,14 days), each group containing 5 animals. Four longitudinal incisions were made on the back of each rabbit, 2 in the right and 2 in the left. A distance of about 1.5 cm was left between one incision and another. The defects were filled with platelet-rich plasma, hyaluronic acid, or mixture of both, and the last incision served as control. Animals were sacrificed at 3rd, 7th, and 14th day after intervention, and biopsy were taken. Histopathological analyses were performed to evaluate the effect of these materials on acceleration of wound healing of skin. Statistical analyses was performed with Analysis of Variance and Duncan's Multiple Range Analysis Test, using a significant level of $p \leq 0.01$. **Results:** Histopathological analysis revealed significant improvement of wound healing when treated with PRP, and with mixed application of PRP and HA compared with control and HA groups in 3rd and 7th day postoperatively, while there was no significant differences in wound healing between all groups at the end of the second week. **Conclusions:** The use of PRP alone or in combination with HA will accelerate wound healing, while the use of low concentration of HA alone presents no improvement of wound healing in comparison with normal one.

Key words: Platelet-Rich Plasma, Hyaluronic Acid, Soft tissue wound healing, Experimental animals.

Fathi WK. The Effect of Hyaluronic Acid and Platelet – Rich Plasma on Soft Tissue Wound Healing: An Experimental Study on Rabbits. *Al-Rafidain Dent J.* 2012; 12(1): 115-125.

Received: 14/11/2010 **Sent to Referees:** 14/11/2010 **Accepted for Publication:** 28/11/2010

INTRODUCTION

Wound healing is a specific biological process related to general phenomenon of growth and tissue regeneration. It is characterized by the formation of granulation tissue consisting of inflammatory cells, newly formed blood vessels and fibroblasts embedded in a loose collagenous extracellular matrix. Reepithelialization,

angiogenesis and matrix deposition are critical events controlling this process.⁽¹⁾ The science of wound healing is advancing rapidly particularly as a result of new therapeutic approaches such as laser, skin substitutes, gene and stem cell therapy.⁽²⁾ Platelet rich plasma is a new application of tissue engineering and a developing area for clinicians and researchers.⁽³⁾ Platelet

rich plasma is a platelet concentrate easily obtained by centrifugation of autologous blood and enriched with growth factors. These growth factors were described to be released from alpha granules when platelet activation is induced by Ca ions from extracellular media. Platelet growth factors play an important role in angiogenesis and tissue regeneration by controlling cell migration, differentiation and proliferation.⁽⁴⁾ Platelet rich plasma also provides a sterile field as part of its antimicrobial activity.⁽⁵⁾ Wound healing involves secretion of glycosaminoglycans (GAGs) by fibroblasts which form a hydrophilic matrix suitable remodeling during healing.⁽⁶⁾ Hyaluranan, also called sodium hyaluronate (Hy) or Hyaluronic acid,⁽⁷⁾ is a high molecular weight glycosaminoglycan (10⁴ to 10⁷) composed of repeated non-sulfated disaccharide units of N- acetylglucosamine and D-glucuronic acid.⁽⁸⁾ It is one of extracellular matrix and plays an important role in the morphogenesis and tissue healing⁽⁹⁾. It is thought to stimulate migration, adhesion, proliferation and cell differentiation leading to acceleration in the wound healing process.

According to our knowledge the present study is the first designed to evaluate the effect of mixing platelet rich plasma and Hyaluronic acid together on wound healing of skin in rabbits as an accelerating factor of wound healing.

MATERIALS AND METHODS

The present study was implemented in the Department of Oral and Maxillofacial Surgery, Dentistry College, Mosul University. Fifteen healthy local adult male rabbits weighing (1.5-2.5kg) were included in the research, they were divided randomly into three groups according to the healing period (3,7, and 14 days), each containing five animals:

Group I: Consisted of 5 animals, these animals sacrificed 3 days after operation.

Group II: Consisted of 5 animals, these animals sacrificed 7 days after operation.

Group III: Consisted of 5 animals which were sacrificed 14 days after operation.

All of the animals were housed under standard conditions, fed the same diet and kept in the same environment during the study period. The materials tested in the

study were autologous platelet rich plasma (PRP) and Hyaluronic acid (HA) (Crespine gel/, Biopolymer GmbH8 and Co.KG D-56410 Montabaur, Germany). Prior to surgery, the PRP was obtained by aspiration of two milliliters of autologous blood drawn from the heart of each rabbit (cardiac puncture was done with 23 gauge needle) and combined with 0.5ml of an anticoagulant citrate dextrose phosphate (ACD-A) in sterile tube. The blood was centrifuged at 2000 rpm for 10min. to separate plasma containing platelet from R.B.C., the plasma was drawn off the top and centrifuged for an additional 10min at 3200 rpm to separate the platelets and the plasma containing platelets was drawn from bottom for another cycle of centrifuge at 4000 rpm for 5min. At the time of application, the PRP about (50µl) was combined with equal volume of sterile solution of 10% CaCl₂ (a citrate inhibitor that allow the plasma to coagulate and cause activation of platelet to release the growth factors).⁽¹⁰⁾ General anesthesia was obtained by an intramuscular injection of ketamine hydrochloride general anesthetic solution (50 mg/kg of body weight) and xylazin at dose of 0.5, 0.3ml/kg of body weight^(11,12). Complete anesthesia had been obtained within 5min, the surgical field was shaved, cleaned and disinfected with povidone iodine solution and covered with sterile towel. After that the rabbit was laid on its abdomen and given local anesthesia in the area (about 0.25ml of lidocaine 2% with epinephrine 1:80,000, New Stetic com. Colombia), four small incisions (about 1.5 cm length, 0.5 cm depth) were made in the skin of the rabbit back using blade no.15. (a distance of about 2cm was left between one incision and another), the dermis and epidermis were reflected gently by blunt dissector. For the control site, the defect was filled with gelatin sponge alone, whereas in the remaining defects the gelatin sponge was used as a vehicle for the application of autologous PRP(25µl), Hyaluronic Acid (0.01ml), or a mixture of autologous PRP and hyaluronic acid. Following application of materials, the wounds were irrigated with normal saline and closed with one stitch black silk suture (Nantong Jianan Medical Products Co.,LTD. China) and disinfected by

povidone iodine ,then the animal was given 0.5 ml oxytetracycline (Iran). I.M. postoperatively (and continuously for three days). A number was inserted in the rabbit's ear for labeling the date of operation were done for each animal and the animal was isolated for the remaining time of the operation day. The suture removal was done after 7 days.

In group I,II, and III the animals slaughtered at day 3,7,and 14 subsequently following surgery. Following slaughter, biopsy specimens were taken and subjected to histopathological examination. The histopathological examination was performed by two specialists of oral pathology using double blind checking manner. Wound healing was measured by assessment of reepithelialization and inflammatory response to surgery.

To measure the degree of reepithelialization, the criteria established by Sinha and Gallagher were used:⁽¹³⁾

- Grade 0 : Reepithelialization at the edge of the wound.
- Grade 1: Reepithelialization covering less than half of the wound.
- Grade 2: Reepithelialization covering more than half of the wound.
- Grade 3: Reepithelialization covering the entire wound, with irregular thickness.
- Grade 4: Reepithelialization covering the entire wound, normal thickness.

The degree of inflammation was measured with the resolution phases of inflammatory processes described by Co-tran *et al*:⁽¹⁴⁾

- Grade 1: Acute inflammation (pyogen membrane is formed).
- Grade 2: Predominance of diffuse acute inflammation (predominance of granula-

tion tissue).

-Grade 3, Predominance of chronic inflammation (fibroblasts beginning to proliferate).

-Grade 4, Resolution and cicatrization (reduction or disappearance of chronic inflammation, although occasional round cells may persist).

The data were analyzed using SPSS under window program (version 12.0) . A descriptive statistic was made for each variable. The following statistical tests were used:

One way analysis of variance test (ANOVA).

Duncan's multiple range analysis.

Statistical significant difference was accepted for $P \leq 0.01$.

RESULTS

Among the 15 rabbit involved in the study, no animal died throughout the period of the research and all of them remained apparently healthy. All of the wounds healed normally with no post operative complications *Reepithelialization*:at the 3rd post operative day, the reepithelialization was faster (Reepithelialization covering more than half of wound as shown in (Figure 1) in incisions treated with PRP (mean= 3.0) and mixed application (Hyaluronic acid and PRP) (mean= 3.0) than in those treated by hyaluronic acid alone (mean = 0.6) and control (mean = 0.6), where thin epidermis at the edges of the wound in half of cases was noticed, and in other half the wound showed reepithelialization covering less than half of wound (Figure 2).

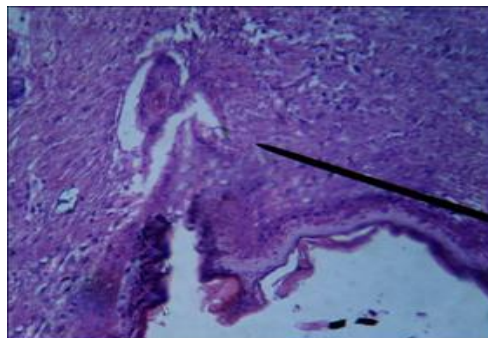


Figure (1): Photomicrograph in PRP,and mixed applied of PRP and HA cutaneous wound in rabbits at 3rd p.o (10X). reepithelialization cover more than half of wound.

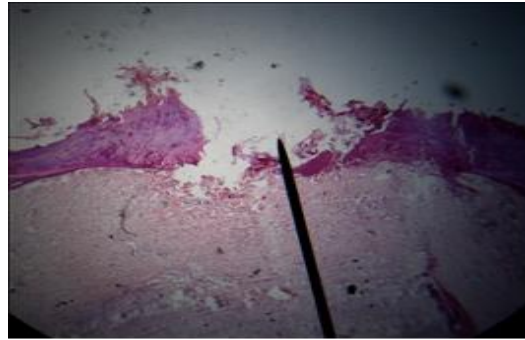


Figure (2): Photomicrograph of control and HA cutaneous wound at 3rd p.o day in a rabbit (20X). Notice the epithelial covering is less than half of wound.

Analysis of variance (ANOVA) and Duncan's multiple range analysis showed

significant difference ($P \leq 0.01$) between study groups Figure (3), Table (1).

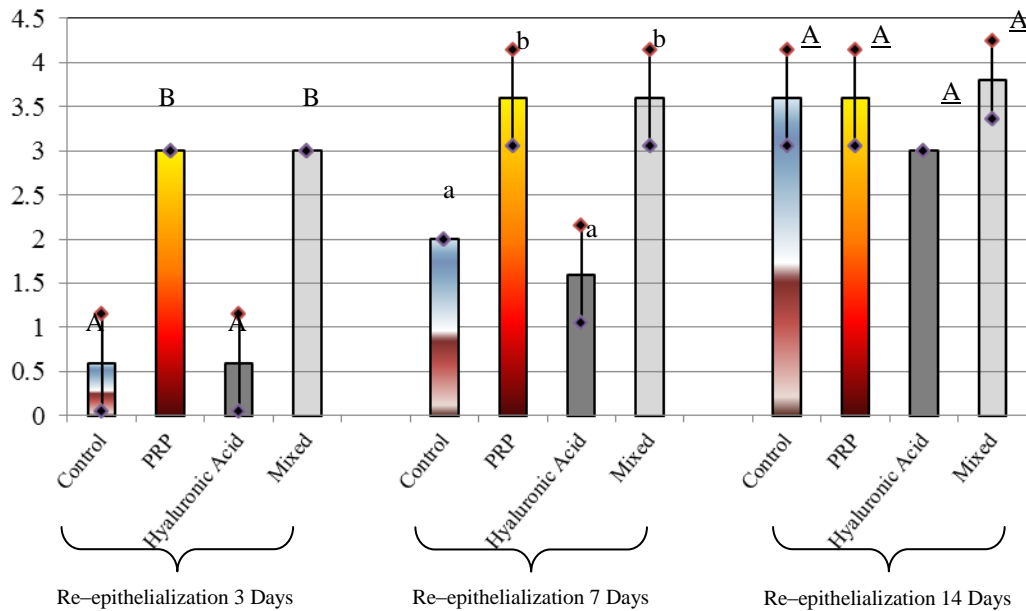


Figure (3): Descriptive statistic and Duncan's Multiple Range Analysis for Re epithelialization score.

Table (1): Analysis of Variance for Re-epithelialization score.

		Sum of Squares	df	Mean Square	F-value	P-value
3 Days	Between Groups	28.800	3	9.600	64.000	0.000*
	Within Groups	2.400	16	0.150		
	Total	31.200	19			
7 Days	Between Groups	16.600	3	5.533	24.593	0.000*
	Within Groups	3.600	16	0.225		
	Total	20.200	19			
14 Days	Between Groups	2.150	3	0.717	4.095	0.025*
	Within Groups	2.800	16	0.175		
	Total	4.950	19			

* Significant differences existed at $p < 0.01$

At the 7th post operative day, there was increased epithelial thickness in wound defects treated by PRP and with mixed application (mean=3.60), the reepi-

thelialization was grade 3 (i:e) the reepithelialization covering the entire wound although of irregular thickness (Figure 4).

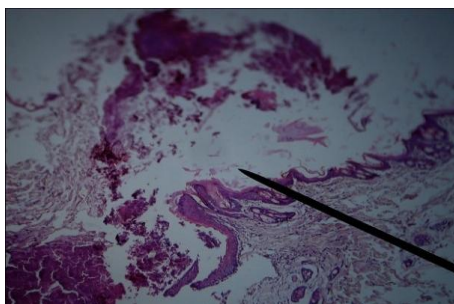


Figure (4): Photomicrograph of cutaneous wound in 7th p.o day of PRP and mixed treated group rabbit (4X). Complete epithelization of entire wound with thin irregular margin.

While there was less epithelial thickness in control (mean=2.00) and in hyaluronic acid group (mean=1.60). The majority of these two samples showed grade 2

of reepithelialization (i:e) reepithelialization covering more than half of the wound Figure (5).

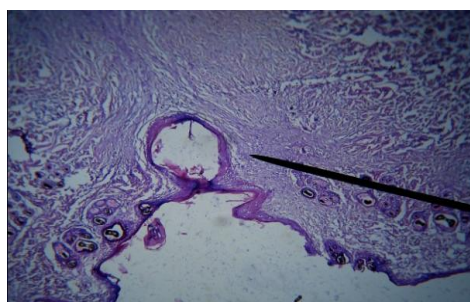
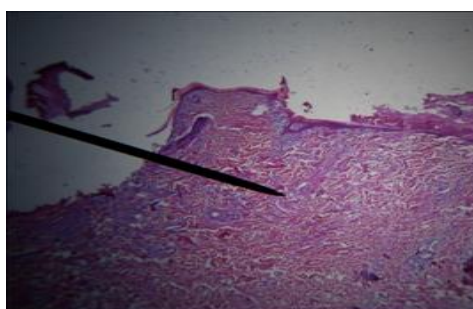


Figure (5): Photomicrograph of cutaneous wound in 7th p.o day of control and HA treated group rabbit (4X). Incomplete epithelization covering more than half of wound .

Analysis of variance (ANOVA) and Duncan's multiple range analysis showed significant differences ($P \leq 0.01$) between study groups Figure(3), Table(1).

By the end of 2nd week most of all treated cases showed grade 4 of reepithelialization (i:e) reepithelialization covering the entire wound, normal thickness Figure (6). and only few cases (2 of control, 2 of

hyaluronic acid, and 1 of mixed treated wound defects) showed grade 3 of thelialization. Analysis of variance (ANOVA) and Duncan's multiple range analysis reveled no significant differences among study groups at $P \leq 0.01$ Figure (3), Table (1).



Figure(6): Photomicrograph of all treated wound at 14th p.o day in rabbit (10X). Note complete wound healing.

Inflammation

At 3rd post operative day after operation, a significant increase in number of new vascularization, inflammatory cell, collagen arrangement, and number of fibroblast was noticed in wound defects

treated with PRP and mixed application (mean=2.60) (Figure 7), when compared with both control and wounds treated by hyaluronic acid only (mean=1.40), which showed marked acute inflammation (Figure 8).

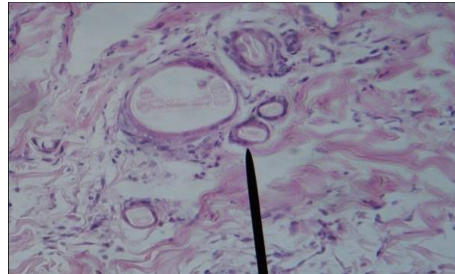


Figure (7): Photomicrograph in PRP and mixed application group of cutaneous wound in rabbit at 3rd p.o day (40X). Numerous newly formed blood vessels with increased inflammatory infiltrated.

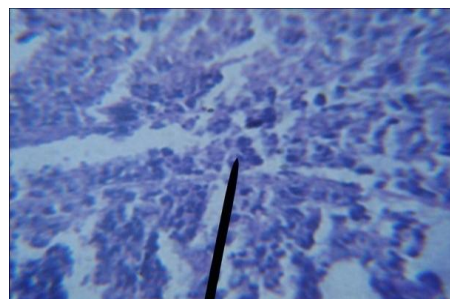
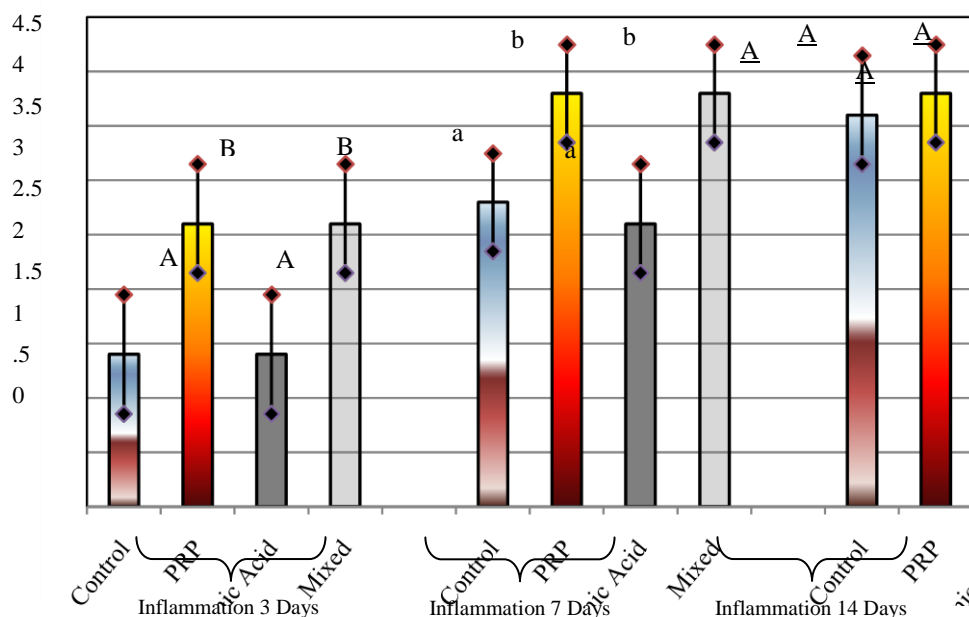


Figure (8): Photomicrograph in HA and control cutaneous wound in 3rd p.o day (40X). show irregular collagen arrangement.

Analysis of variance and Duncan's multiple range analysis showed significant

differences ($P \leq 0.01$) among the study groups Figure (9), Table (2).



Means with different letters were statistically significant at $P \leq 0.01$.

Figure (9): Descriptive statistic and Duncan's Multiple Range Analysis for Inflammation.

Table (2): Analysis of Variance for Inflammation score.

		Sum of Squares	df	Mean Square	F-value	P-value
3 Days	Between Groups	7.200	3	2.400	8.000	0.002*
	Within Groups	4.800	16	0.300		
	Total	12.000	19			
7 Days	Between Groups	6.150	3	2.050	9.111	0.001*
	Within Groups	3.600	16	0.225		
	Total	9.750	19			
14 Days	Between Groups	.550	3	0.183	0.733	0.547
	Within Groups	4.000	16	0.250		
	Total	4.550	19			

* Significant differences existed at $p < 0.01$.

At day 7th following operation, statistically significant differences were noticed ($P \leq 0.01$) (Table 2) between PRP and mixed application (these samples showed the most resolved phases of acute inflammatory process and there was predominance of chronic inflammation i.e. proliferation of fibroblast) (mean=3.80) Figure (11) when compared to control sample (mean=2.80) and hyaluronic acid alone (mean=2.60) which showed predominance of granulation tissue and beginning of resolution of acute inflammatory

process Figure (10). By the end of 2nd week, the wounds in all defects showed complete resolution of inflammatory process, however only a few cases (2 in control, 2 in hyaluronic acid treated wound, and 1 case in PRP and with mixed sample) showed prevalence of chronic inflammation (where fibroblast proliferation had begun to take place) Figure (12). (ANOVA) and Duncan's multiple range test showed no significant differences ($P \leq 0.01$) Figure (9), Table (2).

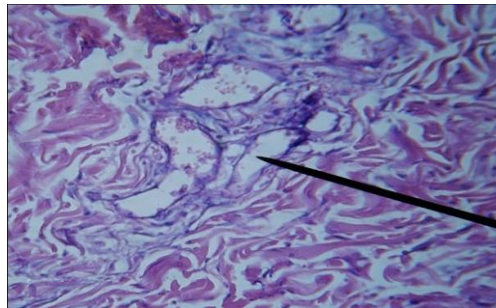
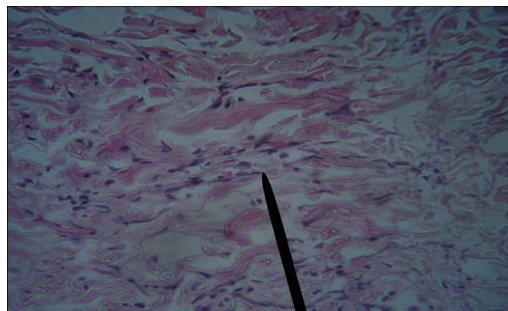


Figure (10): Photomicrograph of cutaneous wound in 7th p.o day of control and HA treated group rabbit (40X). Predominance of granulation tissue formation.



Figure(11): Photomicrograph of PRP and mixed experimental cutaneous wound at 7th p.o day in rabbit (40X). Shows great fibroblast proliferation and inflammatory cell infiltration.

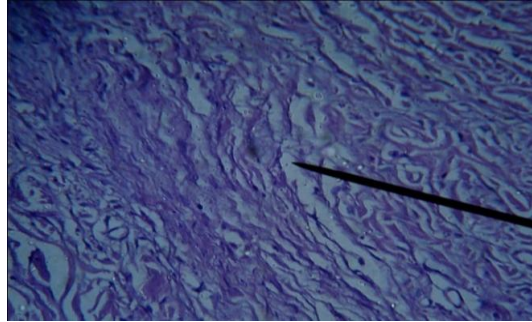


Figure (12): Photomicrograph in experimental all groups in cutaneous wound at 14th p.o day (40X). Shows resolution of chronic inflammation and heavy proliferation of fibroblast.

DISCUSSION

Recent in vivo and in vitro studies have suggested that various autocrine and/or paracrine growth factors are present in the serum play important roles in the wound healing of various tissue, including soft and hard tissue.⁽¹⁵⁾ The action of these growth factors vary with regard to environment in which the growth factors are placed, it may be complimentary or even inhibitory. A platelet rich plasma (PRP) which is known to contain multiple growth factors which are especially important in wound healing and may contribute to tissue formation and epithelialization. Autologous platelet concentrate or PRP is a concentration of at least five autologous growth factors and has been shown to accelerate wound healing. PRP is appealing in that it is an easily derived in the initiation of healing response.⁽¹⁶⁾

Another important factor is hyaluronic acid (HA) which is naturally biocompatible, biodegradable and lacks immunogenicity,⁽¹⁷⁾ and its one major member of GAG present in the skin. During the inflammatory phase intact HA in the blood clot of wound helps in the physical stabilization of the matrix. It also stimulates cell infiltration and migration, and controls the degradation of fibrin. The degradation products of HA- fibrin matrix act as regulator molecules of wound healing process.⁽¹⁸⁾

Evaluation Of Reepithelialization

It has been demonstrated that the wounds treated by PRP with or without subsequent application of HA at the 3rd and 7th postoperative day healed faster than in control wound and wound treated

with HA alone and there was a significant increase in epithelial thickness, while there was no significant difference at 14th post-operative day among all treated wounds, this may be attributed to the diverse biological effects associated with PRP through a variety of growth factors present in α - granules of platelet and most of these factors may have action on multiple cell and tissue type. Among these factors epithelial growth factor (EGF), which stimulate angiogenesis, endothelial chemotaxis, epithelial and mesenchymal cell mitogenesis, and collagen synthesis.⁽¹⁹⁾ EGF act upon the basal cell at wound edge to promote an epithelial proliferation which migrate into nutrient granulation tissue on the surface of the cell adhesion molecules in the clot. So it stimulate the basal cell of skin to lay down the specific component of basement membrane.⁽³⁾

Evaluation of inflammation

The wounds treated with PRP alone and with mixed application of both PRP and HA showed the most resolved phase within the acute inflammatory phase during the first week than those obtained with HA treated wounds and with those left to heal on their own. While all the wounds were completely healed at the end of second week postoperatively. The faster resolution of acute inflammation in PRP treated wound is attributed to the secretory proteins contained in the α - granules of platelet including platelet derived growth factor (PDGF),⁽²⁰⁾ vascular endothelial growth factor,⁽²¹⁾ and transforming growth factor- β (TGF- β).^(19, 20) These growth factors aid healing by attracting un-

differentiated cells in the newly formed matrix and triggering cell division.⁽²⁰⁾ PRP may suppress cytokine release and limit inflammation, interacting with macrophages to improve tissue healing and regeneration,⁽²²⁾ and promote new capillary growth.^(23, 24)

Regarding the effect of HA on tissue regeneration it is related to the interaction of HA with CD44 which drive the maintenance and establishment of collagen synthesis and normal skin function. Hyaluronic acid is present in the extracellular matrix of basal keratinocytes and the structural integrity of dermal collagen fragments and fibroblast penetration.⁽²⁵⁾ Decreased levels of HA correlate to impaired local inflammatory response and reduced tissue repair due to degeneration of the granular tissue matrix.^(25, 26)

According to the scope of the present research the effect of PRP in wound healing showed similar positive result of PRP in acceleration of epithelial migration, the angiogenic response and tissue fill. However, these results agree with those studies induced by Lee et al, have noted acceleration of epithelialization in treatment of lower equine wound with PRP and faster resolution in inflammatory response,⁽²⁷⁾ and with the finding reported by Vaterio et al, who showed acceleration in skin reepithelialization by using PRP during fat grafting in patient who underwent plastic surgery.⁽²⁸⁾ Alsabaawe, and Hom *et al*, who stated that there was an increased of epithelialization rate and regression of acute inflammatory process in PRP treated skin wounds in rabbits during week 1 postoperative period compared to week 2 where there was no statistical differences found in epithelial thickness and inflammation stage between PRP treated wound and control, where the epithelialization returned to normal texture and there was improvement of wound healing in term of reducing the inflammatory process.^(29,30) These results came in agreement with the present study in that the epithelialization and inflammatory response reached the complete stage in wound healing at the end of second week. While Margolis and his colleagues⁽³¹⁾ carried out a retrospective study in patients with diabetic neuropathic ulcers who receive an adjuvant

therapy such as PRP, PDGF, or graft skins were found to have wound less likely to heal. Concerning the results gained by application of hyaluronic acid alone showed no significant differences in epithelial thickening rather than inflammatory response when compared to normal so there was no acceleration of wound healing. The explanation of this may be related to molecular weight specific, purity, and dose specific of hyaluronic acid. In this line Bettinger et al suggest that the exogenous HA retard healing of partial thickness wound in adult,⁽³²⁾ moreover, in another study induced by Icono et al revealed that the application of exogenous HA dampens the fibrotic healing response in injured fetal mouse limb organ culture.⁽³³⁾ Conversely, several authors claimed that the administration of exogenous HA of high concentration of high molecular weight to adult tissue injuries promotes rapid healing and decreased fibrosis that normally occur in skin burns,⁽³⁴⁾ also Ruggiero et al reported the effect of HA in scarless fetal wound healing in rabbit wounds showed increased granulation tissue and enhanced collagen deposition with fibrosis.⁽³⁵⁾

Nevertheless, the results of the present study reveal acceleration of wound healing in mixed application group (PRP and HA) it may be attributed to influence of PRP on wound healing rather than HA which act as a mucoadhesive and retain the therapeutic agent at its site of action/absorption.⁽³⁶⁾ It is the first time to evaluate the effect of both PRP and HA on skin wound healing so there is no available study that support this result.

CONCLUSION

Within the limits of the present study, it can be concluded that the PRP will accelerate wound healing when applied alone or in combination with hyaluronic acid. In addition, it is emphasized that there was no beneficial effect of using low concentration of HA on healing skin wounds as it was solely applied.

REFERENCES

1. Chohn IK, Diegelman RF, Lindlab W Jed. Wound Healing: Biochemical and Clinical Aspects. Philadelphia/ Lon-

- don. WB saunder.1992.
2. Falanga V. Advanced Treatment for Non-Healing Chronic Wound. *EWMA Journal*. 2004; 4(2):4-6.
 3. Marx RE, Garge AK. Dental and Craniofacial Application of Platelet-Rich Plasma. Quintessence publishing co. China. 2005; Pp:4-24.
 4. Jesus Torres, Faleh M, Tamimi, Isabel F. Tresguerres, Mohammad H, Alkhraisat, Ameem Khraisat, Enrique Lopez- Cabarcos, and Luis Blanco. Effect of Solely Applied Platelet- Rich Plasma on Osseous Regeneration Compared to Bio-Oss: A Morphometric and Densitometric Study on Rabbit Calvaria. *Clinical Implant and Related Research*. 2008; 10(2): 106- 111.
 5. Bielecki T, Gazdzi KT, Arendt J, Szczepanski T, Kor,W, Wielkoszynski T. Antimicrobial Effect of Autologus Platelet Gel Enriched with Growth Factors and other Active Substances: An in Vitro Study. *J of Bone and Joint Surgery British*. 2007; 89(3):417-420.
 6. Mary A. Kosir, Christian Q, Wenlion Wang, and Gerardus Trom P. Matrix Glycosaminoglycans in the Growth Phase of Fibroblasts: More of Story in Wound healing. *J of Surgical Research*. 2000; 29: 45-52.
 7. Aslan M, Simsek G, Dayi E. The effect of Hyaluronic Acid Supplemented Bone Graft in Bone Healing Experimental Study in Rabbits. *J Biomater Appl*. 2006; 20:209-219.
 8. Prince CW. Roles of Hyaluronan in bone Resorption BMC. *Musculoskel et al Disord*. 2004; 5:12.
 9. Dechert TA, Ducale AE, Ward SL, Yager DR. Hyaluronan in Human Acute and Chronic Dermal Wounds. *Wound Repair Regen*. 2006; 14:252-285.
 10. Al-Juma'a Dirar A. The Effect of PRP and Propolis on Healing of Bone Defect in Rabbit. M.Sc Thesis, College of Dentistry, University of Mosul. 2008.
 11. Laurence DR, Bennet DN, Brown MJ. *Clinical Pharmacology*. 8th edition. Churchill Livingstone.1997; Pp: 373-395.
 12. Katzung BG. *Basic and Clinical Pharmacology*. 7th edition. Appleton and Lange. Stamford, Connecticut. 1998; Pp: 420-423.
 13. Sinha UK, Gallagher LA. Effects of Steel Scalpel, Ultrasonic Scalpel, Co2 Laser, and Monopolar and Bipolar Electrosurgery on Wound Healing in Guinea Pig Oral Mucosa. *Laryngoscope*.2003; 113:228-236.
 14. Cotran RS, Kumar V, Collins T. 2000. Cited by Fabio Camacho- Alonso, Pia Lopez- Jornet. Clinical- Pathological Study of the Healing of Wounds Provoked on the Dorso- Lingual Mucosa in 186 Albino Rats. *Otolaryngology-Head and Neck Surgery*. 2007; 136 (1):119-124.
 15. Sasaki T, and Watanabe. Stimulation of Osteoinduction in Bone Wound Healing by High Molecular Hyaluronic acid. *Bone*. 1995;16(1):9-15.
 16. Rebecca L Knox, Allen R Hunt, John C.Collins, Marie De Smet, Sera Barnes. Platelet- Rich Plasma Combined with Skin Substitute for Chronic Wound Healing: A Case report. *J of American Society of Extra- Cor Poreal Technology*. 2006; 38:260-264.
 17. Vercruysee KP, Prestwich GD. Hyaluronate Derivatives in Drug Delivery. *Crit Rev ther Carrier Syst*.1998; 15: 513-555.
 18. Prathiba. V, and Gupta P.D. Cutaneous Wound Healing: Significance of Proteoglycans in Scar Formation. *Current Science*. 2000; 78(6): 1-5.
 19. Nikolidakis D, and Jausen JA. The Biology of Platelet- Rich Plasma and its Application in Oral Surgery: Literature Review. *Tissue Eng part B: Rev*.2008; 14 (3): 249-258.
 20. Bahanot S, and Alex JC. Current Application of Platelet Gel in Facial Plastic Surgery. *Facial Plast Surg*. 2002; 18(1) : 27-33.
 21. El-Sharkway H, Kantarci A, Deady J. Platelet- Rich Plasma: Growth Factors and Pro- Anti- Inflammatory Properties. *J Periodontol*. 2007; 78(4): 661-669.
 22. Mishra A, Woodall Jr, Vierra A. Treatment of Tendon and Muscle Using Platelet- Rich Plasma. *Clin Sports Med*. 2009; 28(1):113-125.
 23. Millington JT, and Norris TW. Effective Treatment Strategies for Diabetic Foot Wound, *J Fam Prad*. 2000;

- 49(11suppl): 540-548.
24. McAleer JP, Sharma S, Kaplan EM, Persich G. Use of Autologous Platelet Concentrate in Anon Healing Lower Extremity Wound. *Adv Skin Wound Care*. 2006; 19(7): 354-363.
 25. Fisher GJ, Varani J, Voorhees JJ. Looking older: Fibroblast Collapse and Therapeutic Implication . *Arch Dermatol*. 2008; 144(5): 666-672.
 26. Gariboldi S, Palazzo M, Zanobbio L. " Low Molecular Weight Hyaluronic Acid Increases the Self Defense of Skin Epithelium by Induction of Beta- Defensin 2 via TLR2 and TLR4". *J Immunol*. 2008; 181(3): 2103-2110.
 27. Lee HW, Reddy SM, Palcanis GK, Jack EL, Rahemtulla FG, Kang-Jey Ho, Chen DT, Davis CR, and Feldman DS. Efficacy of Platelet- Rich Plasma on Wound Healing in Rabbits. *J periodontology*. 2008; 79(4): 691-696.
 28. Vaterio Cervelli, Pietro Geutise, Maria Giovanna S, Monica Grimaldi, Carlo Umberto, Luigi Giuls O.S Pagnoli, and Augusto Orlandi. Application of Platelet-Rich Plasma in Plastic Surgery, Clinical and in Vitro Evaluation. *Tissue Engineering: Part C*. 2009; 15(00).
 29. Alsabawee Yhayha A. Evaluation of the Effect of Platelet- Rich Plasma on Skin Wound Healing by Primary Intention: An Experimental Study. M.Sc Thesis, College of Dentistry, University of Mosul. 2009.
 30. Hom DB, Linzie BM, and Huang TC. The Healing Effects of Autologus Platelet Gel on Acute Human Skin Wound. *Arch Facial Plastic Surgery*. 2007; 9:174-183.
 31. Margolis DJ, Allen-Taylor L, Hoffstad O, and Berlin JA. Diabetic Neuropathic Foot Ulcer: The Association of Wound Size, Wound Duration, and Wound Grade on Healing. *Diabetes Care*. 2002; 25(10):1835-1839.
 32. Bettinger, David Aimast, Bruce j Gore, and Dennis. Hyaluronic Acid Impedes Reepithelialization of Skin Graft Donor Sites. *J Burn Care*. 1996; 17(4): 302-304.
 33. Icono JA, Ehrlich HP, Keefer KA, and Krummel TM. Hyaluronan Induces Scarless Repair In Mouse Limb Organ Culture. *J Pediatr Surg*. 1998; 33: 554-567.
 34. Yang Y Ges. Effect of Hyaluronic acid- Stimulating Factors on Scar Formation in Wound Healing Process of Deep Partial Thickness Burn. *Chung Hue Cheng Hsing Shao Shang Waikotsa Chi*. 1998; 11:331-342.
 35. Ruggiero SL, Bertolami CN, Bronson RE, Damiani PJ. Hyaluronidase Activity on Rabbit Skin wound granulation tissue fibroblasts. *J Dent Res*. 1987; 66: 1278-1287.
 36. Brown MB, and Jones SA. Hyaluronic Acid: A Unique Topical Vehicle for Localized Delivery of Drugs to the Skin. *JEADV*. 2005; 19:308-318.