

## **EFFECT OF TAURINE AND VITAMINE E IN TREATING ATHEROSCLEROSIS INDUCED EXPERMENTALLY BY HYDROGEN PEROXIDE IN RABBITS.**

**E R AL-Kennany**

Department of Pathology, College of Veterinary Medicine, University of Mosul, Mosul-Iraq

(Received May 8, 2004; Accepted July 24, 2004)

### **ABSTRACT**

This study was conducted to determine the effects of taurine and vitamin E on atherosclerotic lesions in H<sub>2</sub>O<sub>2</sub>-induced atherosclerosis model in rabbits. Rabbits were firstly treated with daily intake of 0.5% H<sub>2</sub>O<sub>2</sub> in drinking water for 60 days, then divided into 3 groups left for 12 weeks and treated as follow: Group 1; no further treatment, Group 2; treated with taurine that dissolved in drinking water at 0.3% (w/v) daily, and Group 3; treated with vitamin E in the diet as 400 mg/Kg feed. Results confirmed the persistency of atherosclerotic lesions till 12 weeks post treatment with H<sub>2</sub>O<sub>2</sub>. Taurine and vitamin E treatment showed the same effects on some biochemical profiles. Taurine treatment decreased serum levels of total cholesterol by 41.5%, triglycerides by 31.5% as well as a decreased in serum atherogenic low-density lipoprotein (LDL) and very low-density lipoprotein (VLDL) cholesterol by 50.2% and 51.5%, respectively. The same treatment increased antiatherogenic high-density lipoprotein (HDL) cholesterol by 23.3%. Aortic biopsies from taurine treated rabbits and stained with Sudan IV reveal reduction in the areas of sudanophilia and, the histological examination also demonstrated regression in fatty streaks and foam cells in the intimae. Furthermore, taurine treatment elucidate a significance reduction in tissues malondialdehyde (MDA) level; liver (31%), heart (31.9%) and, aorta (46.7%), concomitant with significant elevation in tissues glutathione (GSH) level; liver (190.6%), heart (113%) and, aorta (86.2%). In conclusion, taurine reduce the severity of atherosclerotic lesions induced by H<sub>2</sub>O<sub>2</sub> treatment and its antioxidative effect may related to the anti-atherosclerotic action.

**تأثير التورين وفيتامين E في علاج التصلب العصيدي المحدث تجريبياً بواسطة  
بيروكسيد الهيدروجين في الأرانب**

أنتصار رحيم الكناني

فرع علم الأمراض/كلية الطب البيطري/جامعة الموصل. موصل ، العراق

### **الخلاصة**

تم تصميم هذه الدراسة للتعرف على التأثيرات التي يبدئها استخدام التورين على أفات، التصلب العصيدي المحدث تجريبياً بواسطة بيروكسيد الهيدروجين ذو التركيز 0,5 % في ماء الشرب يومياً لمدة 60 يوماً، بعدها تم تقسيم الأرانب الى ثلاثة مجاميع تركت لفترة 12 أسبوعاً وعممت

كلائي: المجموعة الأولى: تركت بدون أي معاملات أخرى ، المجموعة الثانية: تمست معاملتها يومياً بالتورين المذاب بماء الشرب بتركيز 0,3 % (وزن/حجم)، و المجموعة الثالثة: تمست معاملتها بفيتامين E المضاف للعلف بنسبة 400 ملغم / كغم علف. بينت النتائج استمرار تواجد وتطور آفات التصلب العصيدي في الأرانب بالرغم من مرور 12 أسبوعاً على انتهاء المعاملة ببروكسيد الهيدروجين. كذلك أظهر التورين تأثيرات على بعض المعاملات متطابقة التي حد كبر مع التأثيرات المحدثة من قبل فيتامين E. لقد أدى التورين الى خفض معدي في مستويات كل من في المصل : الكولسترول الكلي (بنسبة 5, 41 %) و الكليسيريدات الثلاثية (بنسبة 5 , 31%) فضلاً عن الشحوم البروتينية ذات الكثافة الواطئة LDL (بنسبة 2 , 50 %) و الشحوم البروتينية ذات الكثافة الواطئة جداً VLDL بنسبة (5 , 51 %) . ومن جانب آخر، عمل التورين على زيادة معنوية في مستوى الشحوم البروتينية ذات الكثافة العالية HDL (بنسبة 3 , 23 %). وبينت نماذج أبهر الأرانب المعاملة بالتورين والمصبوغة بصيغة Sudan IV انخفاضاً بالمناطق المصبوغة والتي أيدتها الفحص النسجي المتمثل بتراجع ملحوظ في الأشرطة الدهنية والخلايا الرغوية في البطانة. وأدت المعاملة الطويلة بالتورين الى انخفاض معنوي في تراكيز مالوندايديهايد الأنسجة : الكبد (31 %) ، القلب (9 , 31 %) والأبهر (7 , 46 % ، والمتران مع الأرتفاع المعنوي في تركيز كلوتاتايون الأنسجة : الكبد (6 , 190 ) والقلب (113 %) والأبهر (2 , 86 %). وأستنتج من هذه الدراسة، أن للتورين تأثيراً مخفضاً لشدة آفات التصلب العصيدي المحدث تجريبياً ببروكسيد الهيدروجين وأن فعل التورين المضاد للأكسدة قد يعود لفعله المضاد للتعصد.

#### INTRODUCTION

H<sub>2</sub>O<sub>2</sub>- induced atherosclerosis was experimentally reported in chickens (1), rats (2) and recently in rabbits (3). This model of atherosclerosis is characterized by pronounced hypercholesterolemia and development of fatty and proliferative lesions.

Taurine, a sulfur-containing amino acid (2-methanesulphonic acid), is widely distributed in animal tissues, and has a variety of physiological and pharmacological functions (4, 5). Epidemiological study, WHO-CARDIAC study, suggests that taurine intake is beneficial for preventing cardiovascular disease (6). Several studies remarked on taurine action towards lipid metabolism namely; hypolipidemic and hypocholesterolemic actions (7-9). However, less attention has focused on the anti-atherosclerotic effects of taurine. Kondo et al (10) reported that taurine prevents the formation of atherosclerotic lesions in mice, independently of serum cholesterol levels.

The present study was designed to investigate the effects of long-term treatment with taurine and vitamin E supplementation on the development of atherosclerotic lesion induced experimentally by H<sub>2</sub>O<sub>2</sub> in rabbits.

#### MATERIALS AND METHODS

Male local breed rabbits weighing 1.1-1.2 Kg were used. The animals were fed standard diet and given tap water *ad libitum* . All animals were firstly, subjected to Experimentally-induced oxidative stress by the *ad libitum* supply of drinking water containing 0.5% H<sub>2</sub>O<sub>2</sub> (6% Evans Medical Ltd., England as described by Wohaieb et. al. (11) for 60 days.

Thereafter, animals were divided into three groups, each consisted of five rabbits, remaining for 12 weeks and treated as follows : Group 1 (G1), received no treatment; Group 2 (G2), treated with taurine ( Taurine ( 2-Amino-ethan sulfonsaure), Fluka AG,Switzerland ) that dissolved in drinking water at 0.3% (w/v) daily as described previously (12). Animals of group 3 (G3) were placed on standard diet supplemented with 400mg of vitamin E per kg as  $\alpha$ -tocopherol acetate (Vit E , Uvedco, Jordan ).

At the end of experiment, blood samples were collected from a marginal ear vein and lipid profiles namely; total cholesterol (Tch), triglycerides (TGS) and high-density lipoprotein cholesterol (HDL-C) were measured by an enzymatic methods using a commercial kit ( Rand ox, France ). Low-density lipoprotein cholesterol (LDL-C) was calculated following the Friedewald formula (13), whereas the very low-density lipoprotein cholesterol (VLDL-C) was measured according to a procedure described elsewhere (14). Rabbits were killed by cervical dislocation and immediately after death; the entire aorta from aortic valve to the bifurcation was dissected. Fats and tissues adhering to the adventitia were removed and the aorta was opened longitudinally and was flattened on strips of paper with the intimal side up. After adherence to the paper strips, the vessels were fixed face down overnight with 10% buffered formalin at room temperature, and therefore stained with Sudan IV (15), to visualize areas of atherosclerotic plaque. Aortic tissues after fixation were routinely embedded in paraffin and 5 $\mu$  sections were cut and stained with hematoxylin-eosin, Masson's trichrom and, alcian blue pH 2.5 (16). The extent of lipid peroxidation as malondialdehyde (MDA) and glutathione (GSH) concentration of the liver, heart and aorta immediately after death were measured by thiobarbituric acid (TBA) test (17) and Moron et. al. Assay (18), respectively. All data were expressed as mean  $\pm$  Standard error (SE). Statistical differences were determined using one-way ANOVA followed by Tukey's test. P values of  $< 0.05$  were considered significant.

## RESULTS

H<sub>2</sub>O<sub>2</sub>-treated rabbits for 60 days showed the following serum profiles; Tch (544.4  $\pm$  17.67mg/dl), TGS (143.8  $\pm$  0.54 mg/dl), HDL (32.2  $\pm$  0.82 mg/dl), LDL (502.2  $\pm$  1.39mg/dl) and, VLDL (44.1  $\pm$  0.17mg/dl). However, H<sub>2</sub>O<sub>2</sub>- treated rabbits for 60 days and left for 12 weeks with no any further treatment ( G1 ), had higher levels of serum profiles, namely; Tch ( 417.2  $\pm$ 17.67) and, TGS (116.4  $\pm$ 25.4) concomitant with an atherogenic level of LDL-C ( 354.6  $\pm$ 22.1) and, VLDL-C (20.7 $\pm$ 0.17) as compared with G2 and G3 ( Fig.1). In contrast HDL-C level was lowered (34.8  $\pm$ 0.62).

After 12 weeks of treatment the H<sub>2</sub>O<sub>2</sub>-induced atherosclerosis with taurine or vitamin E (G2 and G3), there was significance depression in the level of Tch (41.5% and 46.3%); TGS (31.5% and 48.8%); LDL-C (50.2% and 49.6%); and, VLDL-C (51.5% and 49.3%) as compared with the non treated group. However, HDL-C was significantly elevated by 23.3% (taurine) and 28.7% (Vit. E). Furthermore, Fig.1 clarify that there was no significant difference in Tch and LDL-C levels in rabbits treated with taurine or vitamin E. Aortic specimens of the G1 rabbits, revealed sudanophilia in the intimal layer appeared grossly as an elevated streaks or spots which was sharply demarcated. Histologically, aortic sections elucidate a proliferative lesion, i.e. presence of foam cells in intimae and media; proliferation of vascular smooth muscle cells (VSMC) in media toward the intimae (Figs. 2: A, B); infiltration of few mononuclear inflammatory cells namely, lymphocytes. Alcian blue stained sections revealed increase acid mucopolysaccharide (Fig.3-A). The internal elastic lamina was fragmented and split into several layers that cleared by Masson's trichrome stain (Fig. 3-B)

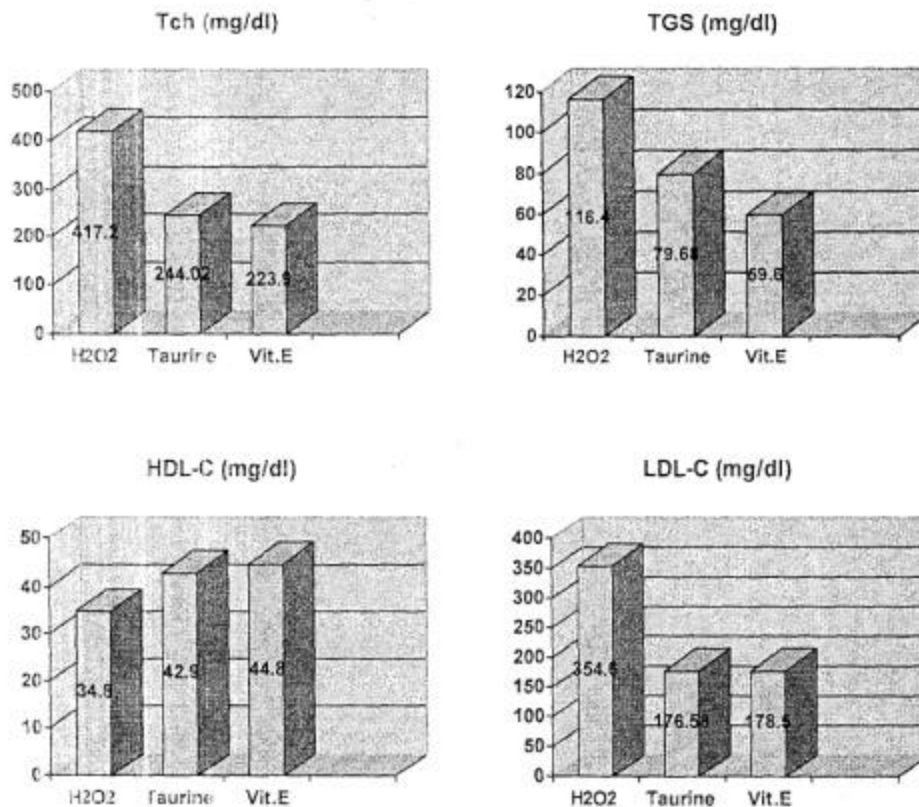


Fig. 1 Effects of taurine and vitamin E on serum lipid profile. Rabbits treated with 0.5% H2O2 in drinking water *ad libitum* for 60 days and then left for 12 weeks : without any further treatment (H2O2), treated with taurine dissolved in drinking water at 0.3% (w/v) daily (Taurine) and, fed a standard diet supplemented with 400 mg vit. E per Kg (Vit E). Tch= total cholesterol; TGS= triglycerides; HDL-C= high-density lipoprotein cholesterol; LDL-C= low-density lipoprotein cholesterol; VLDL-C= very low-density lipoprotein cholesterol. Data are the mean of 5 animals. Significant difference ( $P < 0.05$ ).

In taurine- and vitamin E- treated rabbits (G2 and G3), the Sudan IV staining biopsies shows a reduction in areas of sudanophilia (not estimated statistically) as compared with other group (G1). Also, similar findings in histology of sections obtained from G2 and G3 rabbits, which includes regression in fatty streaks and foamy cells in intimae concomitant with proliferation of VSMC (Figs.4:A,B). Furthermore, a decrease in mucopolysaccharides with presence of intact elastic membranes, have been observed in alcian blue stained sections (Fig. 5). Although, the H2O2- treated rabbits for 60 days revealed an MDA concentrations in liver, heart and, aorta 522.2, 412.3 and, 534.6 nmol/g wet weight, respectively. Moreover, these rabbits showed the following levels of tissue GSH 0.413, 0.582 and, 0.154 in liver, heart and, aorta, respectively.

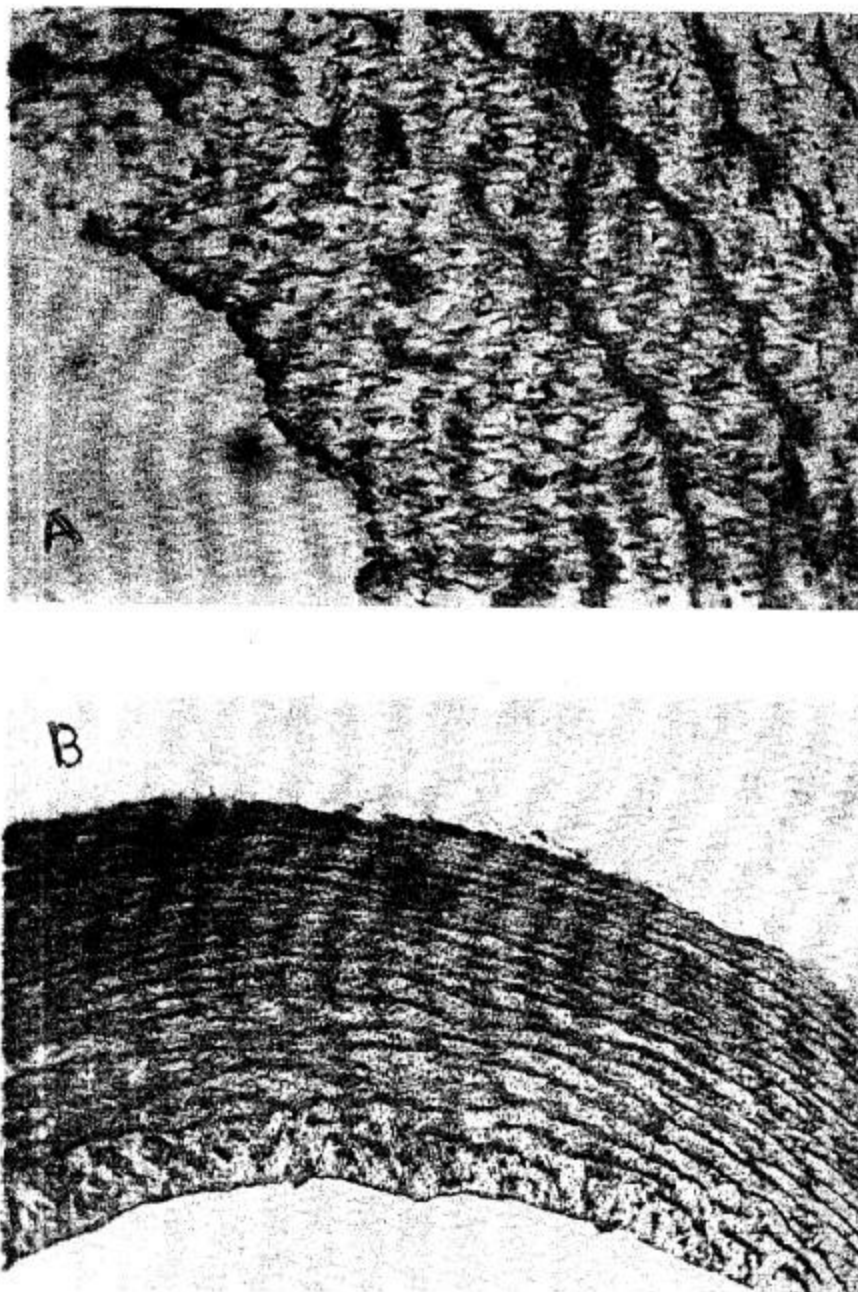


Fig.2 Histomicrograph of rabbit aorta obtained from H<sub>2</sub>O<sub>2</sub>-treated group for 60 days and left for 12 weeks without any further treatment. A) Foam cells in intima and media (arrow). H&E, 400X. B) Foam cells and proliferation of vascular smooth muscle cells in media (arrow). H&E, 200X.






Fig.3 Histomicrograph of rabbit aorta obtained from H<sub>2</sub>O<sub>2</sub>-treated group for 60 days and left for 12 weeks without any further treatment. A) Note, increase acid mucopolysaccharide in intima and media. Alcian blue pH 2.5, 200X. B) Fragmentation of internal elastic lamina. Note the several layers of this lamina. Masson's trichrom, 400X.

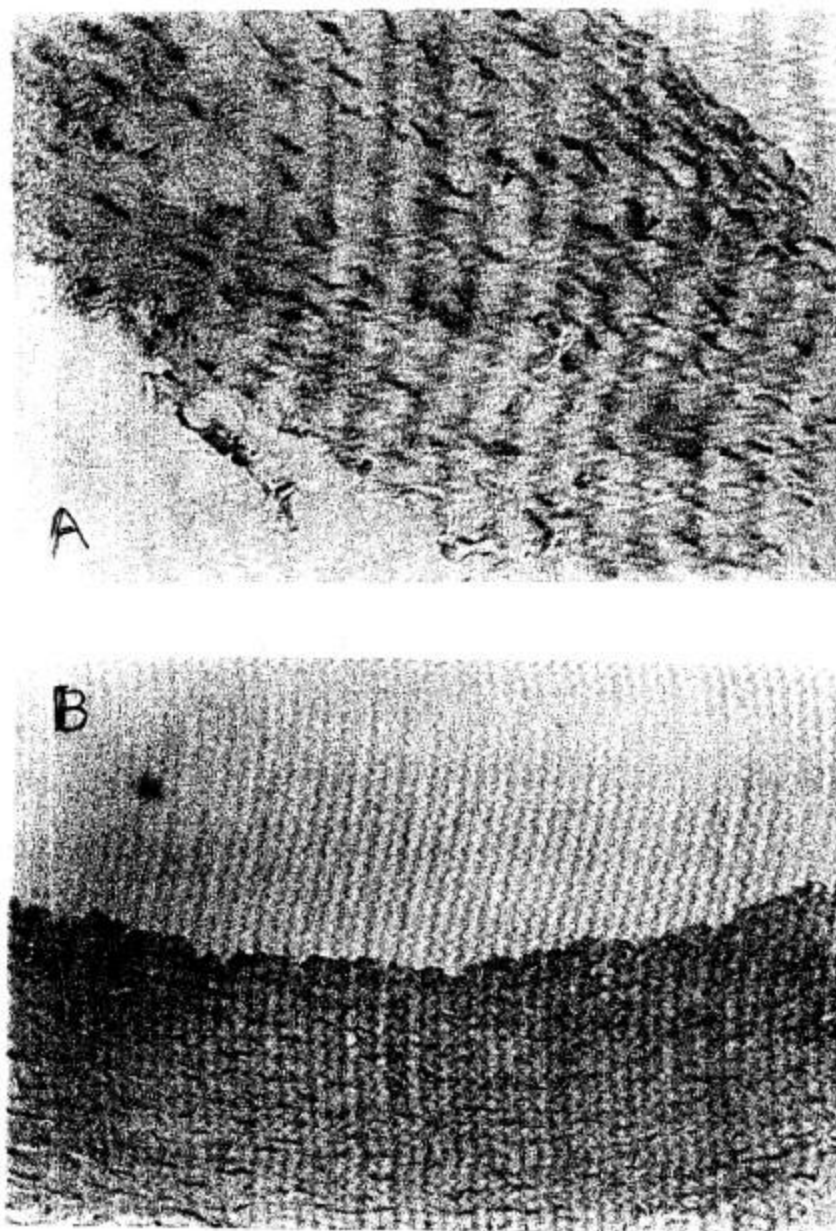


Fig.4 Histomicrograph of rabbit aorta obtained from H<sub>2</sub>O<sub>2</sub>-treated group for 60 days and left for 12 weeks treated with A) taurine in drinking water. Note regression in numbers of foam cells in intimae as compared with its presence in Fig.2A. H&E, 400X. B) vitamin E supplemented with diet ( 400 mg/Kg). Same lesion as in A. H&E, 200X.

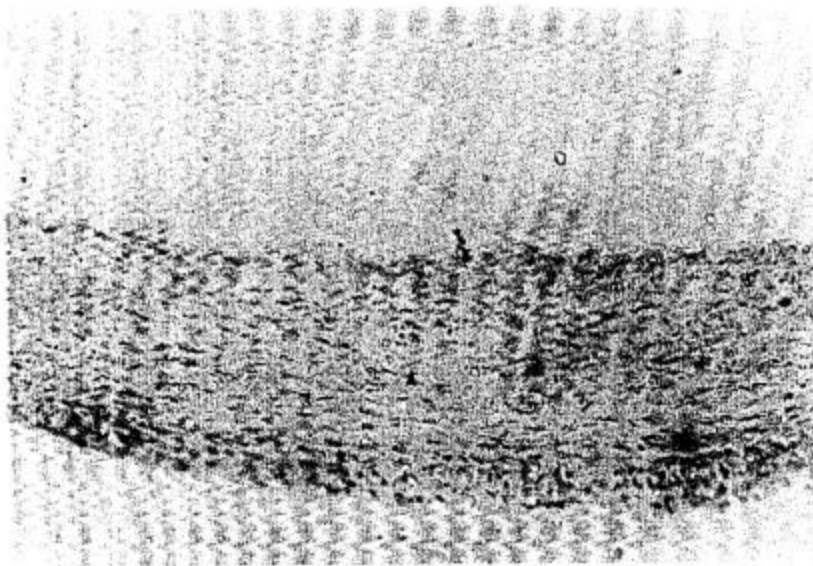


Fig.5 Histomicrograph of rabbit aorta obtained from H<sub>2</sub>O<sub>2</sub>-treated group for 60 days and left for 12 weeks treated with taurine in drinking water. Note , proliferation of vascular smooth muscle cells with intact elastic laminae ( arrow ).Alcian blue pH 2.5, 200X.

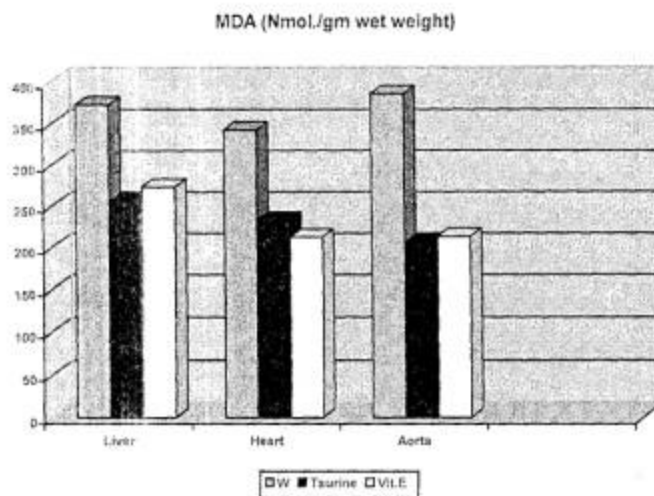


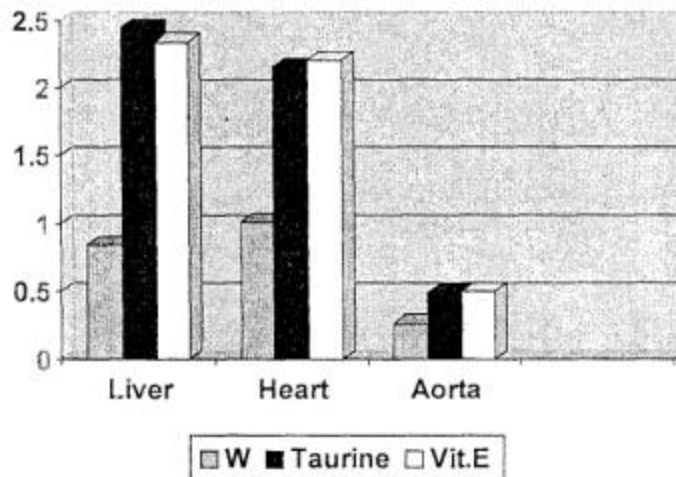
Fig. 6 Effect of taurine and vitamin E on malondialdehyde ( MDA ) concentration in H<sub>2</sub>O<sub>2</sub>-treated rabbits for 60 days and then left for 12 weeks; without any further treatment ( W ), treated with taurine dissolved in drinking water at 0.3% (w/v) daily (Taurine) and , dietary supplementation with vitamin E ( 400 mg/ Kg diet ) (Vit E). Data are the mean of 5 animals. Significant difference P < 0.05.



Fig. 6 shows that rabbits treated with 0.5% H<sub>2</sub>O<sub>2</sub> in drinking water for 60 days and left for 12 weeks with no any further treatment (G1), still had an elevated levels of tissues MDA : in liver, heart and, aorta ( 373.4 ± 42.5, 342.7 ± 22.7 and, 385.8 ± 44.5 nmol/gm wet weight, respectively ) as compared with G2 and G3. In contrast, those rabbits showed a lowered level of tissue GSH; liver (0.843 ± 0.03), heart (1.009 ± 0.03) and, aorta (0.262 ± 0.01 mmol/gm wet weight) as mentioned by Fig.7.

The tissues MDA level of G2 and G3 rabbits were significantly reduced as compared with that of corresponding G1 rabbits; liver ( 31.3% and 26.8%), heart (31.9% and 37.5%) and, aorta ( 46.7% and 44.6%) respectively ( Fig. 6). Whereas, those rabbits clarify a significant elevation of tissue GSH ; in liver (190.6% and 177.6%), heart (113.1% and 118.9%) and, aorta ( 86.2% and 91.6%) respectively, as compared with G1 levels ( Fig. 7 ).

### GSH (Mmol./gm wet weight)



**Fig. 7** Effect of taurine and vitamin E on tissue glutathione in H<sub>2</sub>O<sub>2</sub>-treated rabbits for 60 days and then left for 12 weeks; without any further treatment (W), treated with taurine dissolved in drinking water at 0.3% (w/v) daily (Taurine) and, fed a standard diet supplemented with 400 mg vit. E per Kg (Vit E). Data are the mean of 5 animals. Significant difference P < 0.05.

### DISCUSSION

The data of this study indicates that taurine treated the progression of atherosclerosis induced in rabbits by H<sub>2</sub>O<sub>2</sub>. Treatment with taurine not only decreased atherogenic lipoproteins but also increased antiatherogenic HDL. These alterations in the serum lipoprotein profile are expected to be beneficial for the prevention of atherosclerosis, since epidemiological and genetic studies have indicated that levels of serum HDL are

inversely correlated with atherosclerotic risk (19). When rabbits were treated with 0.5% H<sub>2</sub>O<sub>2</sub> in drinking water daily for 60 days, serum cholesterol and triglycerides as well as atherogenic lipoprotein (both LDL and VLDL) were markedly elevated, which resulted in the formation and development of aortic lesions (3).

It has been reported on capability of taurine to suppress atherosclerosis in New Zealand white rabbits fed a cholesterol-rich diet (20) and, in watanabe heritable hyperlipidemic (WHHL) rabbits (12). However, those studies approved no effect of taurine on serum cholesterol level, our study reveal (Fig.1) a prominent effect of taurine in lowering serum cholesterol level (58.48%). The precise reason for discrepancy between these studies

is not clear. The hypocholesterolemic effects of taurine have been studied in rodents (21). It was suggested that taurine seems to stimulate conversion of cholesterol to bile acid by stimulating cholesterol 7  $\alpha$ -hydroxylase, this leads to decreases in liver and serum cholesterol levels and increases in cholesterol synthesis (22).

An early stage of atherogenesis is characterized by accumulation of foam cells in the vessel wall. These foam cells are lipid-laden macrophages and are thought to be the result of an unrestricted uptake of oxidized LDL via scavenger receptors (23). Our results demonstrated that aortic sections in taurine-treated rabbits (G2) revealed reduction in areas of sudanophilia and histologically include regression of fatty streaks and foam cells in intimae. Thus, it is suggested that the antiatherosclerotic effect of taurine is mainly due to improvement in the serum lipoprotein profiles. Kamata et al (21) reported that long-term treatment with taurine prevents attenuation of endothelium-dependent relaxation of the aorta in mice fed a high-cholesterol diet. Moreover, Murakami et al (12) find that activity of Acyl-CoA: Cholesterol acyltransferase (ACAT) was significantly low in aorta of taurine administered WHHL rabbits. ACAT is a key enzyme responsible for cholesterol esterification in tissues and cells (24). These facts indicate the beneficial effects of taurine on endothelial functions through prevention of LDL oxidation. Taken together, these results indicate that the antioxidant effects of taurine are expected not only to inhibit accumulation of oxidized LDL in macrophages and smooth muscle cells, but to restore functions of endothelial cells.

Taurine treatment for 12 weeks also decreased tissues MDA levels in rabbits suffering H<sub>2</sub>O<sub>2</sub>-induced atherosclerosis (Fig.6). Taurine functions as an antioxidant in a variety of biological systems (5) and protects against oxidative damage under many conditions, decreasing rates of MDA formation (25). The decrease in aortic MDA and lower susceptibility of LDL to lipid peroxidation concomitant with elevated level of tissue GSH in taurine-treated rabbits implies participation of anti-oxidant effects as opposable mechanism by which taurine reduces atherosclerotic lesion.

Natural antioxidants, such as vit. E has been shown to reduce the development of H<sub>2</sub>O<sub>2</sub>-induced atherosclerosis in rabbits (10). Our results confirm this fact.

In conclusions, the present results demonstrated the antiatherosclerotic effects of taurine in H<sub>2</sub>O<sub>2</sub>-induced atherosclerosis in rabbit model.

## REFERENCES

- 1- Al-Kennany ER. A study on the capability of oxidative stress by hydrogen peroxide to induce atheromatous lesions experimentally in chickens. Ph.D. thesis, University of Mosul, 1998.

- 2- Khudiar KK .The role of aqueous extracts of olive ( *Olea Europaea* ) leaves and garlic ( *Allium Sativum* ) in ameliorating the effects of experimentally induced atherosclerosis in rats. PhD thesis, University of Baghdad, 2000.
- 3- Al-Allaf' ESM . The effect of garlic and vitamin E on the pathogenesis of atherosclerosis induced by hydrogen peroxide in rabbits. M Sc thesis, University of Mosul, 2004.
- 4- Wright CE, Tallan HH, Lin YY .Taurine: Biological update . *Annul Rev Biochem* 1986; 55: 427-453.
- 5- Huxtable RJ. Physiological actions of taurine. *Physiol Rev* 1992; 72: 101-163.
- 6- Yamori Y, Liu L, Ikeda K, Miura A, Mizushima S, Miki T, Nara Y . Distribution of twenty-four hour urinary taurine excretion and association with ischemic heart disease mortality in 24 populations 16 countries: results from the WHO-CARDIAC study. *Hypertens Res* 2001; 24: 453-457.
- 7- Sugiyama K, Ohishi A, Omura Y, Muramatsu K. Comparison between the plasma cholesterol-lowering effects of glycine and taurine in rats fed on high cholesterol diet. *Agric Biol Chem* 1989; 53: 1647-165
- 8- Kanata C, Sugiura M, Kojima S, Kasuya Y. Restoration of endothelium-dependent relaxation in both hypercholesterolemia and diabetes by chronic taurine. *Euro J Pharmacol* 1996; 302: 47-53.
- 9- Murakami S, Kondo-Ohta Y, Tomisawa K. Improvement in cholesterol metabolism in mice given chronic treatment of taurine and fed a high-fat diet. *Life Sic* 1999; 64: 83-91.
- 10- Kondo Y, Toda Y, Kitajima H, Oda H, Nagate T, Kameo K, Murakami S .Taurine inhibits development of atherosclerotic lesions in apolipoprotein E-deficient mice. *Clin Exper Pharmacol Physiol* 2001; 28: 809-815.
- 11- Wohaieb SA, Tohala SH, Al-Dewachi OS. Effect of vitamin E on hydrogen peroxide-induced oxidative stress in rabbits. *Iraqi J Vet Sci* 1994; 7: 81-84.
- 12- Murakami S, Kondo Y, Sakurai T, Kitajima H, Nagate T. Taurine suppresses development of atherosclerosis in watanabe heritable hyperlipidemic (WHHL) rabbits *Atherosclerosis* 2002; 163: 79-87.
- 13- Friedewald WT, Levy RI, Fredrickson DS. Estimation of the concentration of low density lipoprotein cholesterol in plasma without use of the preparative ultracentrifuge. *Clin Chem* 1972; 18: 499-502.
- 14- Bauer JD. *Clinical Laboratory Methods*, 9<sup>th</sup> ed. Missouri: The C.V. Co, West line Industrial, 1982; 555.
- 15- Llera-Moya de la M, Rothblat GH, Glick JM, England JM .Etoposide treatment suppresses atherosclerotic plaque development in cholesterol-fed rabbits. *Arterioscler Thromb* 1992; 12: 1363-1370.

16- Culling GFA, Allison RT, Barr WT. Cellular pathology techniques, 4<sup>th</sup> ed. Butte- Worth, London.

*Iraqi Journal of Veterinary Sciences, Vol. 19, No. 1, 2005 (45-56)*

- 17- Gilbert D, Stump DD, Roth EFJr. A method to correct for errors caused by generation of interfering compounds during erythrocyte lipid peroxidation. *Anal Biochem* 1984; 137: 282-286.
- 18- Moron MS, Depierre JW, Mennervik B. Levels of glutathione, glutathione reductase and glutathione S-transferase activities in rat's lung and liver. *Biochem Biophys Acta* 1979; 582: 67-73.
- 19- Stampfer MJ, Sacks FM, Salvini S, Willett WE, Hennekens CH. A prospective study of cholesterol, a polipoproteins, and the risk of myocardial infarction. *N Eng J Med* 1991; 325: 373-381.
- 20- Petty MA, Kinz J, DiFrancesco GF. The effects of taurine on atherosclerosis development in cholesterol-fed rabbits. *Euro J Pharmacol* 1990; 180: 119-127.
- 21- Kamata K, Sugiura M, Kojima S, Kasuya Y. Restoration of endothelium-dependent relaxation in both hypercholesterolemic and diabetes by chronic taurine. *Euro J Pharmacol* 1996; 303: 47-53.
- 22- Murakami S, Kondo Y, Tomisawa K, Nagate T. Prevention of atherosclerotic lesion development in mice by taurine. *Drugs Exp Clin Res* 1999; XXV: 227-234.
- 23- Ross R. The pathogenesis of atherosclerosis: A perspective for the 1990s. *Nature* 1993; 362: 801-809.
- 24- Suckling KJ, Strange EF. Role of acyl-CoA: Cholesterol acyltransferase in cellular cholesterol metabolism. *J Lipid Res* 1985; 26: 647-671.
- 25- Kaplan B, Aricioglu A, Erbas D, Erbas S, Turkozkan N. The effects of taurine on perfused heart muscle malondialdehyde levels. *Gen Pharmacol* 1993; 24: 1411-1413.