

## Evaluation of Early Active Mobilization Protocol of Extensor Tendon Repair At Zone V, VI and VII

Azzam Raheem Abbas\*, Zakaria Y. Arajy\*\*

### ABSTRACT:

#### BACKGROUND:

Extensor tendon injuries are relatively common. The thin overlying skin makes the tendons vulnerable to sharp injuries. Yet tendon adhesions during the healing phase is a frequent outcome, it might limit the full recovery of the patient.

#### OBJECTIVE:

This prospective clinical study was done to evaluate the postoperative protocol of early active mobilization using simple, easy to made static splint. It provides the surgeon with guidelines to treat patients with extensor tendons injuries. It helps the patients to attain best results and least complications.

#### PATIENTS AND METHODS:

In this prospective study 27 cases of fresh injury of extensor tendon at zone V to VII were treated with primary repair (within 24 hour) or delayed primary in the Medical City teaching complex between March 2009 to March 2011. A protocol of early active mobilization was undertaken, using an easy to follow rehabilitation plan.

#### RESULTS:

Twenty seven patients included in this study, with age ranging between 20 – 60 years. All were assessed according to the Dargon criteria at the sixth postoperative week. The most common injury was caused by glass 74%. Patients were followed up to one year, and 63% of the patients had excellent

**RESULTS:**  
The most common complication was tendon rupture in 4 cases, 14.7%.

#### CONCLUSION:

The early mobilization of repaired extensor tendon reduces the formation of adhesion as compared to rigid immobilization. We recommend the use of this protocol following extensor tendon repair in the hand at zone V, VI, and VII in cooperative patient .It will give fairly acceptable results.

**KEYWORDS:** extensor tendon injury, dargon criteria,early active mobilization.

### INTRODUCTION :

Injuries of the extensor mechanism seem relatively simple to treat, but in fact they have to be given the same degree of attention as flexor tendon injury<sup>(1)</sup>. Extensor tendon injury are very common (61,3%) of tendon injuries of the hand<sup>(2)</sup>,and reported to be more than flexor tendon injuries<sup>(3)</sup>. The extensor tendons are particularly vulnerable to trauma because their superficial location in a clenched fist, the thin mobile subcutaneous tissue offers little protection, and lacerations of the extensor tendons are common over joints that are easily exposed to contamination<sup>(4)</sup>. The complex

extensor system is covered by thin, pliable dorsal skin, leaving the tendons susceptible to trauma and exposure. These injuries may be more difficult to treat than those of flexor tendon system, because of the complex anatomy of the extensor system, any minimum discrepancies in tendon length and tension can lead to significant functional deficits following tendon injury and repair<sup>(5)</sup>. The management of these injuries demands the same skill and knowledge as required for flexor tendon repair, on the dorsum of the hand and fingers there is a relative lack of soft tissue, therefore adhesion of the tendon to the skin are common, the bone and joints being very close to the dorsal surface are injured concurrently with extensor tendon. These tendons are extra synovial in most parts except

\* Surgical , Specialization Hospital Medical City.

\*\*Iraqi Board for Medical Specialization Baghdad Iraq.

## EARLY ACTIVE MOBILIZATION OFTEN EXTENSOR TENDON REPAIR

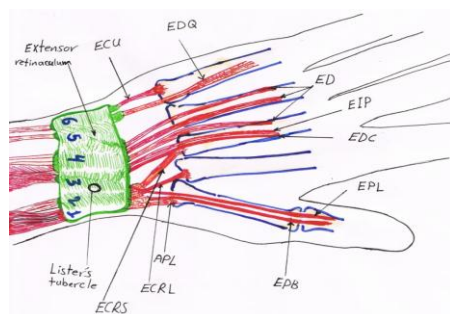
under the extensor retinaculum, they have no vincula, and their blood supply is segmental, arising from the surrounding soft tissue and paratenon. Extensive dissection devitalizes these tendons and promotes scarring and adherence to adjacent structures<sup>(6)</sup>.

Rehabilitation after repair of extensor tendon injuries had been less addressed in the literature than that of flexor tendons<sup>(7)</sup>. In extensor tendon repair, static splinting was accepted as the normal postoperative modality and the patient's hand is placed in volar positioning splint in the first 3 weeks, passive extension is allowed in the splint. At week 4, gentle active extension is started, no passive flexion is allowed at any time, in the next 2 weeks, active flexion is initiated and graded resistance exercise are added to the regimen. During the entire time the patient is evaluated continuously for presence of extensor lag, this type of rigid immobilization protocol had a high risk of complications e.g. adhesion and joint stiffness<sup>(8)</sup>. Early dynamic splinting was also used as a rehabilitation protocol for zone IV to VIII (proximal phalanx to distal forearm), but cautioned that requires professional supervision and highly motivated patient, the patient actively flexes the involved fingers followed by passive extension with rubber band<sup>(9)</sup>. Since 1990, a controlled active mobilization protocol was advocated by many surgeons to be used after extensor tendon repair from zone III to zone VIII, and this protocol designed to limit tendon adhesion and maintain joints mobility and also easy to prepare, cheap, available, easy to follow and have less

complications than other regimens.<sup>(10)</sup> This rehabilitation protocol is applied after the first operative day without the need for hand therapist and carried by the patient himself and involve putting the patient's hand in volar splint with 45 degree of wrist extension, flexion of the metacarpophalangeal (MP) joint to a least 50 degree and both proximal interphalangeal (PIP) and distal interphalangeal (DIP) joints were free, for thumb injuries the carpometacarpal (CM) joint and the MP joint were kept in neutral position. Then the patient starts two active exercise, the first was a combined interphalangeal (IP) and MP joints extension, and the second was MP joint extension with IP joint flexion, and in case of thumb injury the IP joint was actively flexed to about 60 degree, the frequency of the two exercise was 4 times in 1 session and 4 session each day for the first 4 weeks postoperatively, then the final assessment of progress was done using dargon criteria at 6<sup>th</sup> weeks postoperatively.

### ANATOMIC CONSIDERATION

The extensor system is composed of extrinsic and intrinsic muscles. The extrinsic muscles originate proximal to the wrist, their tendons passing over the dorsal aspect to insert into the hand and the wrist. At the wrist they are held in position by a transverse retinaculum band that prevents dorsal bowing on wrist extension. The tendons are held in horizontal position under the extensor retinaculum by vertical bands that form the six dorsal compartments through which all extensor tendons pass (fig. 1)



**Figure 1: Extensor tendon compartments and related tendons; ECU:extensor carpi ularis, ECRB:extensor carpi radialis brevis, ECR: extensor carpi radialis longus, APL: abductor pollicis longus, EDQ: extensor digitorum quinti, EDC:extensor digitorum, EIP:extensor indicis proprius, EPL:extensor pollicis longus, EPB:extensor pollicis Brevis.**

The number and position of the extensor tendons are more variables on the ulnar side of the hand<sup>(11)</sup>.

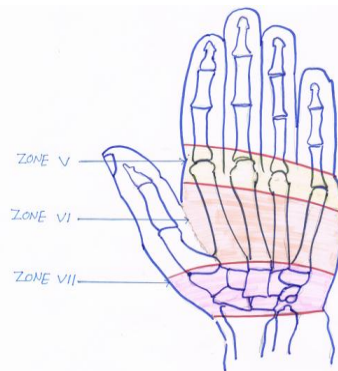


Figure 2: Extensor zone V,VI,VII of the hand

### PETIENTS AND METHODS:

This prospective study included 27 patients of acute extensor injuries that were treated from March 2009 to August 2011 in the Medical City teaching complex.

#### Preoperative assessment:

Routine history taking with details of the injury, the object causing the injury, the dominant hand and the position during the injury, Physical examination, included the zone, and the possible tendons involved together with any associated injury. Investigations done included routine haematological, and radiological exams. Before the surgical repair, we explain the injury to the patient and how it will be treated as well as inherent problems associated with injury, the need for extensive postoperative rehabilitation, the potential need for more than one surgery, and the likely outcome should also explained.

#### Operative Procedure:

General anesthesia was used in all cases, after the hand is scrubbed of gross contamination, a tourniquet is placed at the upper arm and the arm and the hand are prepared and draped with sterile technique, wound needs to be irrigated by normal saline solution and all devitalized tissue excised. Wide exposure was performed to allow meticulous repair. Exploration of a segment of extensor retinaculum may be necessary to find the tendon end. The suture technique applied was modified Kessler using 4-0 prolene sutures. Skin closure was done with polyethylene 3-0 sutures, a corrugate drain is inserted, plaster of Paris slab was applied on the volar side with wrist dorsiflexed to 45 degree and the slab extended distal to MP joint which were kept in full extension, the IPI joint and the DIP joint were kept fully extended, the patients were instructed to elevate their hands, and (cefotaxime) was started by intravenous route for three days.

#### Rehabilitation protocol:

On the second postoperative day, the drain, and the slab was removed and a new slab was applied, the wet plaster of Paris was molded over the volar side of the limb with the wrist in 45 degree of dorsiflexion and MP joint flexed at least 50 degree with the PIP joint & DIP joint were left free [fig-3]. The splint is secured with crepe bandage.

First postoperative day:

A controlled active mobilization begins, and the patients instructed to carry out two exercises actively, these include: combined IP (both PIP & DIP joints), MP joint extension and MP joint extension with IP joint flexion.

The frequency of above two exercises is limited to four times in one session and four sessions each day for the first four weeks postoperatively, for the easy of comprehension of the patient is taught the formula 4x4x4 (4 times in one session, 4 sessions each day, for the first 4 weeks).

Fifth to sixth postoperative day:

Patients are reviewed for dressing, if dressing is clean; the patients are reviewed on the 10<sup>th</sup> to 12<sup>th</sup> day for suture removal. In case with infection, offending suture are removed and the patient is reviewed every two to three days with twice change of dressing till the infection cleared. Patients are instructed to continue active mobilization as advised even in the presence of infection.

Fourth postoperative week:

The patient are evaluated for extension lag, if that lag is greater than 30 degrees, the splint is continued to be worn for another two weeks, and the original exercise are continued but with unlimited frequency, if no extensor lag is found or the lag is less than 30 degree, the splint is

## EARLY ACTIVE MOBILIZATION OFTEN EXTENSOR TENDON REPAIR

discarded during the day and worn at night for a further two weeks.

After four weeks, the previous exercise is replaced with gentle flexion of the MP joint and IP joint, steadily increasing to full flexion and power grip, this fist making is performed with unlimited frequency during the day.

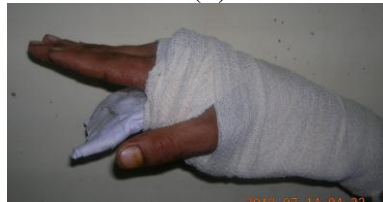Sixth postoperative week:

The splint is removed and extensor strengthening exercises advised, like flexion of the interphalangeal (IP) joints and active extension and flexion at metacarpophalangeal joint, with wrist in neutral position to improve the excursion of the repaired extensor tendon, this was done with unlimited frequency.

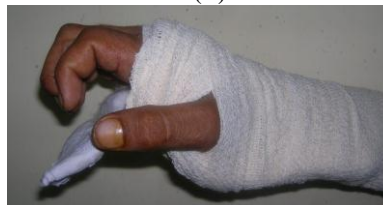The final assessment of progress is done according to Dargon criteria, details in table 1 below<sup>(20)</sup>.



(A)



(B)



(C)

**Figure 3 A: The splint B- combined IP and MPJ joint extension exercise C-IP joint flexion with MCP joint extension exercise**

**Table 1: Dargon criteria**

Results	Range of Movement
Excellent	No extensor lag
	No flexion lag
Good	Extension lag < 15degree
	No flexion lag
Fair	Extension lag 15 to 45 degree
	Pulp to palm distance <2 cm
Poor	Extension lag > 45 degree
	Pulp to palm distance >2 cm

## EARLY ACTIVE MOBILIZATION OFTEN EXTENSOR TENDON REPAIR

### RESULTS:

Twenty seven patients of fresh extensor tendon injuries were included in this study, their ages ranged from 20 to 55 years. There were 22 males (81.5%) and 5 females (18.5%). The dominant hand was involved in 20 of patients (74%) as shown in the table 2 below.

**Table 2: Patients details**

Age (years)	No. of Cases	%	Male	%	Female	%	Dominant Hand	%
20 - 30	5	18.5%	6	22.2%	1	3.7%	2	7.4%
31 - 40	14	51.8%	10	37%	-	-	5	18.5%
41 - 50	4	14.8%	4	14.8%	3	11.1%	9	33.3%
51 - 60	4	14.8%	2	7.4%	1	3.7%	4	14.8%

The nature of injuries was sharp cut in 23 patients (85.1%), with crush injuries in 4 patients (18.6%), details are shown in table 3:

**Table 3: Nature and mode of injuries.**

Nature of injuries	Mode of injuries	Number of cases
Sharp cut injuries	20 glass injuries (74%) 2 knife injuries (7.4%) 1 other injuries (3.7%)	23(85.1%)
Crush injuries	3 blast injuries (11.1%) 1 RTA (3.7%)	4(18.6%)

The most common site of injuries were zone VI, VII and zone V respectively, and the most common tendon injured was EDC, EI, and EDM as shown in the table below:

**Table 4: Details of zone of injuries and tendon injured.**

Number of cases	Zone of injury	Tendon which injured	%
19	VI	EDC, EI, and EDM	70.3%
5	VII	EDC, EI, APL, EPB, ECRL, ECRB & EPL	18.5%
3	V	EDC, EI, EDM	11.1%

Only 5 patients (18.5%) had single tendon injury, While 22 patients (81.4%) had multiple tendon injuries.

**Table 5: Complications.**

Post operative complications	Number of cases	%
Tendon rupture	4	14.8%
Adherent scar	2	7.4%
Wound infection	2	7.4%

At the end of the 6<sup>th</sup> weeks post operatively, the overall outcome result are summarized in the table 6 below;

## EARLY ACTIVE MOBILIZATION OFTEN EXTENSOR TENDON REPAIR

Table 6: Overall result at 6<sup>th</sup> post operative weeks , according to Dargon Criteria.

No. of cases	Results	%
17	Excellent	63%
8	Good	29.6%
-	Fair	-
2	Poor	7.4%

### DISCUSSION:

The complex extensor system is covered by thin skin, leaving the tendons susceptible to trauma and exposure. Contrary to popular belief, these injuries may be more difficult to treat than those of flexor tendon system because of the complex anatomy of the extensor system and any minimum discrepancies in tendon length and tension can lead to significant functional deficits following tendon injury and repair<sup>[5]</sup>. A flurry of innovation in postoperative rehabilitation therapy for extensor tendon injury has developed. Initially, it was believed that the lack of synovial lining, except at the level of the extensor retinaculum, limited tendon adhesion formation. In extensor tendon repairs, static splinting was accepted as the normal postoperative therapy modality, however, several articles have demonstrated improved functional outcome after early mobilization protocol<sup>(7,14,18)</sup>. The intention of this paper is to demonstrate that the appropriate form of therapy is variable, depending on the affected digit, zone of injury, available time for recovery and patient cooperation. The therapeutic postoperative protocol used by our study is the early active motion after the first 24 hours of repair. It is carried out using an easy to made POP splint, the results were evaluated after the sixth postoperative weeks as advocated by Hung et al.<sup>(13)</sup>.

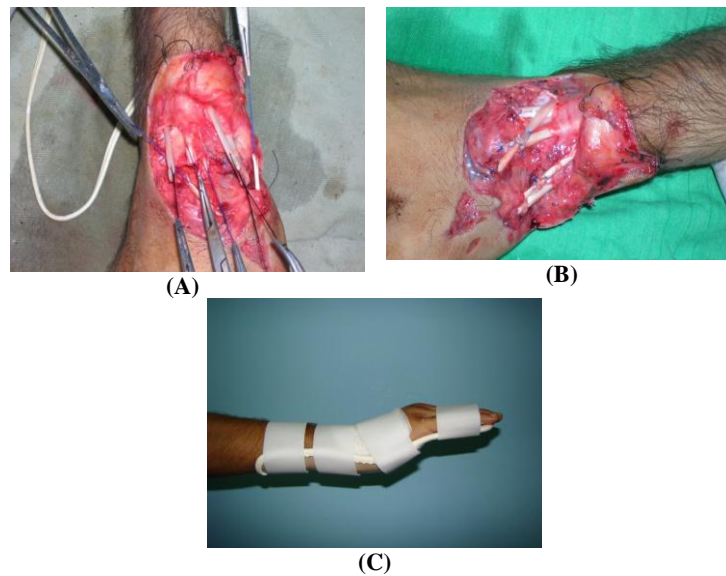
In this prospective study, 27 patients with extensor tendon injury were subjected to early active mobilization protocol and were followed up to one year. In our study fourteen patients (51,8%) were between 30 – 40 years of age. These findings were not consistent with Narender Saini et al.<sup>(14)</sup>, whose study showed that most of his patients were < 30 years old, and also inconsistency with other series where young adults between 18 – 30 years were more affected<sup>(15,16)</sup>. This inconsistency was because of fact that most of the injuries in our study were victims of glass injury that occurred due to blast explosions, so it was not restricted to young working age group whose being seen in the above studies. Males were affected more than females 15:5

these findings were consistence with a study by Pandey and Goyal<sup>(17)</sup>. In our series, twenty patients (74%) had their dominant hand involved. Nineteen (77.3%) of injuries were in zone VI (metacarpal region) followed by five (18.5%) in zone VII (dorsal retinaculum) and this is consistence with Narender Saini et al. study<sup>[14]</sup>, were most common injuries occur in zone VI and VII. This observation is understandable since these zones were vulnerable to trauma more frequently. In our study, the tendon most common involved were EDC, EI and EDM, these finding were consistence with the finding of Slater and Bynum<sup>[15]</sup>. In twenty two (81.4%) of cases, primary repair were done (within 24 h. after trauma), and in the remaining 5 (18.6%) patients, delayed primary repair were done within one week post injury since they had crushed injury and the wound was not clean enough for primary repair. The final assessment of progress was done with Dargon criteria<sup>[12]</sup> as mentioned above. At the end of sixth week, seventeen (63%) of patients showed excellent results and eight (29.6%), showed good results. These findings were consistence with Narender Saini et al.<sup>(14)</sup> results that showed( 91%) excellent results and also consistence with Sylaidis, Youatt and Logo<sup>(18)</sup> who showed twenty-two(92%) good to excellent results. Our results are comparable with rehabilitation protocol using dynamic splinting by Cosby and Wehbi, who had 92% of good to excellent results injuries at zone IV to VII<sup>(7)</sup>. In two of patients (7.4%) the results were poor; those two patients were two of five patients who had crush injuries. The most common complications, were tendon rupture four cases (14.8%) which was inconsistency with Narender Saini et al.<sup>[14]</sup> who showed no tendon rupture in any of their patients, this was attributed to poor compliance of some patients, being uncooperative with our protocol in performing the exercise with caution while wearing the splint and with limited frequency. These 4 patients were operated upon later on three weeks after the rupture, and during this period, they were subjected to static splint, and

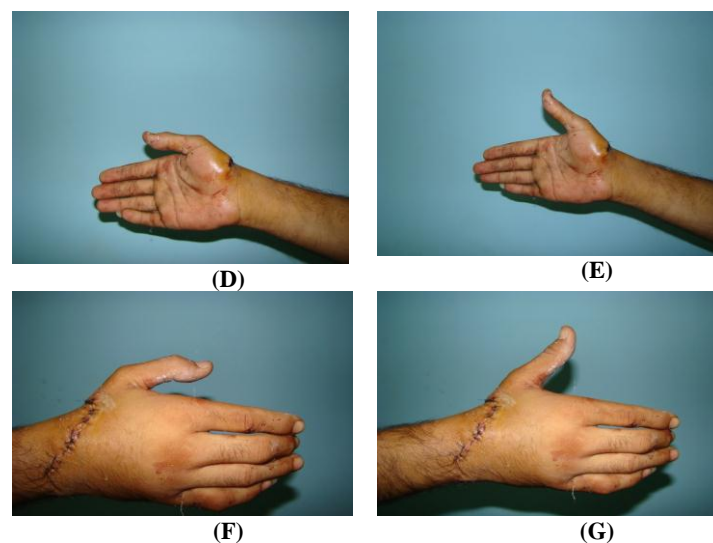
## EARLY ACTIVE MOBILIZATION OFTEN EXTENSOR TENDON REPAIR

after the second operation, they were subjected to the same protocol of early active mobilization. These were evaluated again in the same manner, two of them had excellent outcome, and the other two had good outcome according to Dargon criteria<sup>(12)</sup>. The second most common complication was adherent scar, two patients (7.4%), which was consistency with Narender Saini et al<sup>(14)</sup>, who showed 31% of adherent scar, The third most common complication was wound infection, it occurred in two patients (7.4%), which responded to daily change of dressing and

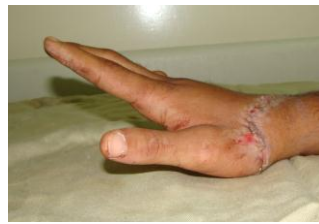systemic antibiotics. Despite the wound infection, the patient continued to undergo the mobilization protocol and still had good result. The early repair and mobilization of extensor tendons prevent formation and adhesion as compared to rigid immobilization. While using dynamic splinting is both expensive and cumbersome and requires frequent input from an experienced capable hand therapist. Our patients showed no complaint and it was easy for them to follow the rehabilitation plan, thus helping to attain excellent results.



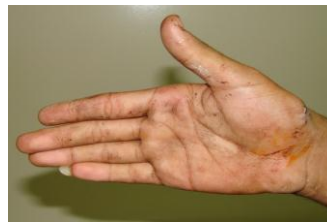**Figure 6: Shows case no. 1 A- Cut APL,EPB,ECRL,ECRB,EPL,EDC of index and EIP at zone VI. B- Repair of the extensor tendons. C-Patient hand in splint after the first 24 hour**



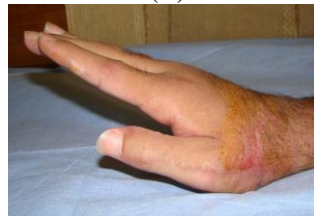**D-G. Views of early active mobilization of wrist and thumb 5<sup>th</sup> postoperative day.**



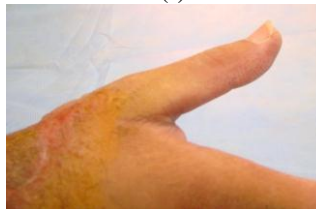(H)



(I)



(J)



(K)

H. Active extension of the wrist 2<sup>nd</sup> postoperative week.

I. Active extension of the thumb 2<sup>nd</sup> postoperative week.

J. Active extension of the wrist and MP joint of the index finger 6<sup>th</sup> postoperative week

K. Active flexion and extension of the thumb at 6<sup>th</sup> postoperative week.

#### CONCLUSION:

The early mobilization of repair extensor tendon, reduces the formation of adhesions.

The static splint is easy to prepare and to apply. Patients subjected to this protocol, should be carefully selected, since uncooperative and poor compliant patients are not good candidate for early active mobilization protocol.

We recommend the use of this protocol following extensor tendon repair at zone V, VI, and VII of the hand.

#### REFERENCES:

- Hart RG., Uehara DT., Kutz JE., Extensor tendon injuries of the hand. *Emerg. Med. Clin. North Am.* 1993;11:637.
- Tuncal : D , Yovus N , Terziogly A ,Alslan G. The rate of upper extremity deep structure injuries through small penetrating laceration . *Ann plast surg* 2005;55:146-48.
- Hagus MF . The result of tendon suture of the hand : A review of 500 patients . *Acta orthop Scand.* 1954; 24:258.
- Donald M Ditmars Jr., Mortan L. Kadson , Nan Boyer ,Tendon injuries of the hand . In *Georgiade plastic ,maxillofacial and reconstructive surgery* 3<sup>rd</sup> edition 1997;92:1000-1010.
- Steven J. Bates and James Chang. Repair of the extensor tendon system. In *Grabb and Smith plastic surgery* , 5<sup>th</sup> edition 2007;83:810-16.
- Kelly AP Jr. Primary tendon repair :A study of 789 consecutive tendon severances . *J Bone Joint Surg Am*1956;41:581-98.
- Crosby CA,Wehbe MA. Early protected motion after extensor tendon repair . *J Hand Surg* 1999;24:1061-70.
- Wolter Kluwer,Soni,Prashant. ;Stern,Colette A.;Foreman,K Bo ;Rockwell,W Bradford: *Advances in extensor tendon diagnosis and therapy,plastic & reconstructive surgery* February 2009;123-issue2-:52e-7e.
- Browne E2 Jr, Ribik CA :Early dynamic splinting for extensor tendon injuries . *Am J Hand Surg* 1989;14:72-76.
- Evans RB, Burkhalter WG ;A study of the dynamic anatomy of the extensor tendons and Implications for treatment . *J Hand Surg Am* 1986;11:774-79.
- Von Schoeder HP ,Botte MJ. Anatomy of the extensor tendons of the fingers :variation and multiplicity . *J Hand surg* 1995;20A:27.
- Dargon EL . Management of the extensor tendon injuries of the hand . *Surg Gynecol Obstet* 1969;128:1269.
- Hung LK, Chan A, Chang J, et al.Early controlled active mobilization with dynamic splintagr for treatment of extensor tendon injuries. *J Hand Surg(Am)*. 1990;15:251.
- Narender Saini ,Mohan Sharma , VD Sharma , Purnima Patni: Outcome of early active mobilization after extensor tendon repair.P.R.S. July 30,2008;336-41.
- Slater RR Jr , Bynum DK. Simplified functional splinting after extensor tenorrhaphy. *J Hand Surg Am* 1997;22:445-51.



## EARLY ACTIVE MOBILIZATION OFTEN EXTENSOR TENDON REPAIR

---

16. Kelly AP Jr. Primary tendon repair :A study of 789 consecutive tendon severances . J Bone Joint Surg Am1956;41:581-98.
17. Pandey VK,Goyal A. Study of extensor injuries of the hand and the wist .Indian J Orthop 1988;22:126.
18. Sylaidis P , Youatt M, Logan A. Early active mobilization for extensor tendon injuries . J Hand Surg Br 1999;22:594-96.
19. Newport ML, Shuka A. Electrophysiological basis of dynamic ext. splinting J Hand Surg Am 1992;17:272-77.