

□ Association of *Helicobacter Pylori* and Nasal Polyposis

Ahmed Muhamad AI –Abbasi*, Aseel Hamid Jasim**

ABSTRACT :

BACKGROUND:

Helicobacter pylori is recognized as an important human pathogen by virtue of its association with peptic ulcer disease , gastric cancer , gastric lymphoma and high prevalence of infection worldwide. Recently this organism was detected in tonsil and adenoid tissue after adenotonsillectomy , as well as in mucosa of patients with chronic rhinosinusitis , but its association with simple nasal polyposis has not been investigated yet in our country .

OBJECTIVE:

To investigate a possible contribution of *Helicobacter pylori* (*H.pylori*) in the etiopathogenesis of simple nasal polyps .

Study Design: Prospective clinico –pathological investigation.

METHODS :

Twenty eight patients with nasal polyposis were studied for the presence of *Helicobacter pylori* in the nasal polyp specimens by histopathological examination of serial sections stained by modified Giemsa stain .

RESULTS:

Helicobacter pylori was detected in 10 (35%) of total 28 simple nasal polyps specimens.

CONCLUSION:

This study found a significant percentage 10/28 patients (35%) with *Helicobacter pylori* infection in nasal polyps and to confirm the role of *Helicobacter pylori* in the etiopathogenesis of nasal polyposis , extensive epidemiological studies would be necessary.

KEYWORDS : nasal polyp , *helicobacter pylori* , giemsa stain

INTRODUCTION :

Helicobacter pylori is a Gram-negative , spirally shaped bacterium , 0.5-0.9 Mm wide by 2-4 Mm long . It is strictly micro-aerophilic , it has a tuft of sheathed unipolar flagella , and it is specially adapted to colonizing mucous membrane⁽¹⁾ . *Helicobacter pylori* has been investigated in several organs of human including the oral cavity, but investigation of association of *Helicobacter pylori* with the nasal polyposis has not been studied in our country yet .

Theories only are known about the pathophysiology of nasal polyp formation . It does appear to be partially related to the patient's underlying allergic status⁽²⁾. However, nasal polyps may occur even in the absence of detectable environmental allergies⁽³⁾. A myriad of inflammatory mediators have been implicated in their pathogenesis⁽⁴⁾. In addition , for reasons that remain unclear , the natural course of nasal polyps is variable.

Helicobacter pylori colonizes gastric mucosa and can be found in gastric juice⁽⁵⁾. Reflux of gastric juice has been suggested to be associated with glue ear⁽⁶⁾. Recently , this organism was also detected in tonsil and adenoid tissue after adenotonsillectomy , as well as in mucosa of patients with chronic rhinosinusitis^(6,11).

Helicobacter pylori were discovered in human dental plaque⁽¹²⁾, oral lesions⁽¹³⁾, and saliva⁽¹⁴⁾. Thus , contribution of *Helicobacter pylori* to the etiopathogenesis of simple nasal polyp is possible .The present study was planned to investigate the presence of *Helicobacter pylori* by histopathological examination of nasal polyp specimens.

A large number of stains are available for the detection of *Helicobacter pylori* in histological sections , all are non –specific⁽¹⁵⁾ . More than one study regard the modified Giemsa stain as the method of choice because it is sensitive, cheap , easy to perform and reproducible^(15,16). Immunohistochemistry staining is now recognized as the gold standard because it is highly sensitive and specific staining method in detecting *Helicobacter pylori*⁽¹⁷⁾.

*Assistant professor of Otorhinolaryngolog
Basrah College of Medicine Basrah –Iraq.

**Lecturer of Pathology Basrah College
of Medicine Basrah –Iraq.

HELICOBACTER PYLORI AND NASAL POLYPOSIS

A variety of diagnostic technique for the detection and identification of bacteria in clinical samples based on characteristic DNA sequences have been documented . Nucleic acid –based detection systems can allow the identification of bacteria without the need for isolation in pure culture or the propagation of living organisms⁽¹⁸⁾. This technique is especially useful for the detection of organisms that cannot easily be grown in vitro⁽¹⁹⁾, as is the case for *Helicobacter pylori*.⁽²⁰⁾ Polymerase chain reaction (PCR) , a technique for the amplification of DNA sequences in vitro , has been widely used to assist in the diagnosis of infectious diseases^(21,23).The speed and sensitivity of the technique make it ideal for "high-throughput" automated screening of blood and tissue samples. Furthermore, PCR can detect copy of a target DNA sequences and therefore requires only small samples for analysis .

MATERIALS AND METHODS:

MATERIALS:

Twenty eight specimens of nasal polyps were obtained from patients with simple nasal polyposis who underwent nasal polypectomy , between January 2007 and December 2009 in Basrah General Hospital , the specimens derived from 20 men and 8 women , aged between 21 to 65 years (mean:38.4 years).All the lesions were bilateral . The study approved by the ethical committee of Basrah Medical College Patients were subjected to an assessment protocol that included careful history review ; full ear , nose and throat examination , emphasizing on laryngeal examination by recordable telescopic examination to visualize changes in posterior aspect of larynx (edema and congestion which indicates posterior laryngitis). All patients were questioned about the classical symptoms of gastroesophageal reflux (heartburn , acid taste and regurgitation) and other conditions like asthma or chronic bronchitis and smoking habit.

METHODS:

Simple nasal polyps of 28 patients were removed by the conventional method of intranasal polypectomy , the polyps size range (0.5-0.7) cm width and (1-3)cm length, the specimens were immediately sent for histopathologist , fixed in 10% formalin , processed routinely and placed in paraffin wax blocks in way allows the microtome knife to cut the specimens perpendicular to the mucosal surface .

Six serial sections of 3-4Mm are taken for each case to overcome the patchy distribution of *H.pylori* ⁽¹⁵⁾.One of the sections stained by haematoxylin and eosin stain using Mayers haematoxylin which gives the best results in staining *H.pylori* in addition to the histopathological diagnosis of the case ⁽¹⁵⁾, the other 5 sections stained by modified Giemsa stain .The latter stain is also a non specific stain for *H.pylori* , however, it gives sensitivity of 94%^(24,25).The stain used in dilution of 1:20 with distilled water and add 2 drops of concentrated acetic acid and stain for 30 minutes , *Helicobacter* will stain blue/grey and the background pink/pale blue.

The sections examined on x 20 - x40 lens of microscope when heavy colonization present , but if the colonization sparse ,examination by oil lens is required⁽¹⁵⁾.

RESULTS:

Fifteen patients out of the total 28 (53%) , gave history of gastroesophageal reflux symptoms (heartburn , acid taste and regurgitation) , but only 4 (14%) had positive laryngoscopic findings (diffuse posterior laryngitis). *Helicobacter pylori* was observed in specimens of 10 patients (35%) ,which belonged to the group (4 patients) who had positive laryngoscopic finding of gastroesophageal reflux (table 1).The polyps were recurrent in 9 patients (32%). No patient gave history of peptic ulcer, gastric carcinoma , gastric lymphoma, asthma or chronic bronchitis and all of them were non smoker .

Table 1: Demographic and clinical data of the studied patients.

Mean age / years	38.4
Sex :Male/Female	18/10
GER* symptoms	15/28
GER* laryngoscopic signs	4/28
<i>H .pylori positive</i>	10/28

*GER : Gastroesophageal reflux.

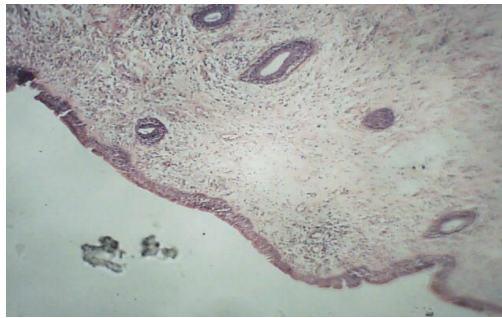

Fig. 1: Simple nasal polyp. Edematous stroma infiltrated by chronic inflammatory cells with scattered mucous gland , and covered by respiratory epithelium- H &E stain ×20

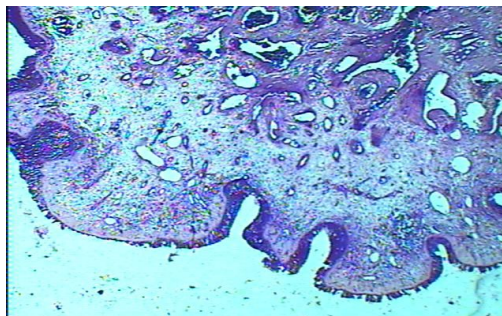
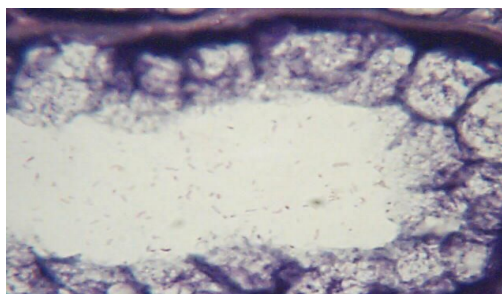
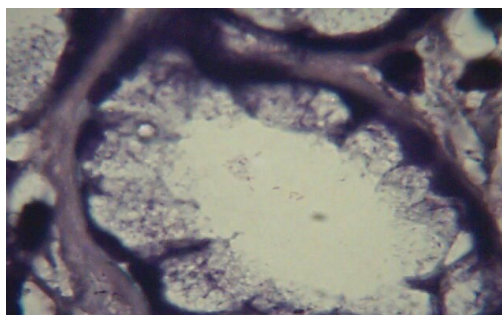


Fig. 2: Simple nasal polyp –Giemsa stain x20



(Fig.3)



(Fig. 4)

Fig. 3 &4 : Section of mucous secreting gland within nasal polyp showing colonization of *Helicobacter pylori* , the bacteria present in the mucous overlying mucosa and do not invade the mucosa – Giemsa stain x1000.

DISCUSSION:

This study was performed to detect *Helicobacter pylori* in tissues of simple nasal polyps, because previously, isolation of *Helicobacter pylori* from the mucosa of patients with chronic rhinosinusitis has been reported^(13,14). This study investigated the association of *Helicobacter pylori* and nasal polyposis.

The study did determine the presence of *Helicobacter pylori* in ten specimens (35%). Furthermore, the data presented in the current report support the clinical impression that *Helicobacter pylori* is the organism probably playing a role in the pathogenesis of simple nasal polyp. This result is different from another study done by the use of urease test GUT plus, it was unable to confirm the presence of *Helicobacter pylori* in the nasal polyps tissue⁽²⁶⁾, while in Koc study (examination by the immunohistochemical analysis with *Helicobacter pylori* antibody) 6/30 specimens (20%) showed positive result⁽²⁷⁾, however; additional epidemiological studies are necessary.

The passage of nasopharyngeal content into the nose occurs frequently in patients with nasal obstruction to clear their noses. Probably negative pressure produced in the nasal cavity may cause reflux of the nasopharyngeal content into nose. Several PH monitoring studies were done to discuss the association of laryngopharyngeal symptoms with gastroesophageal reflux disease^(28,31). Thus, in this study, the possible role of *Helicobacter pylori* in simple nasal polyps was investigated. In recent studies, a close relationship between gastroesophageal reflux and chronic sinusitis was detected^(12,13).

Ozdek et al.⁷ reported a possible role of *Helicobacter pylori* in chronic rhinosinusitis and found *Helicobacter pylori* positive in 4 of their 12 patients with chronic rhinosinusitis. In another study, Unver et al.⁽¹¹⁾ investigate *Helicobacter pylori* colonization in adenotonsillectomy specimens and found a (57.89%) rate of presence of *Helicobacter pylori*. In the present study *Helicobacter pylori* was detected in 10 (35%) of 28 patients with simple nasal polyp, therefore, we think that an ascending route for *Helicobacter pylori* infection in simple nasal polyposis is unlikely.

CONCLUSION :

The present study could find significant indicator that *Helicobacter pylori* played a role at the tissue level in the pathogenesis of nasal polyp, but these results should be confirmed by

extensive epidemiological study including larger numbers of patients using PCR and conventional bacteriological and biochemical tests for detection of *Helicobacter pylori* in nasal polyps.

ACKNOWLEDGMENT :

We would like to express our thanks to Dr. Saad Abdul - Baqi for his help in taking photographs.

REFERENCES:

1. Ketley JM. Compylobacter and helicobacter :enteritis ; gastritis ; peptic ulcer. In : Greenwood D, Slack R , Peutherer J , Barer M , Eds . Medical microbiology a guide to microbial infections : pathogenesis , immunity , laborrotary diagnosis & control . Philadelphia : Churchill livingstone. 2007;300-8 .
2. Bernstein JM, Gorfien J , Noble B. Role of allergy in nasal polyposis : a review .Otolaryngo Head Neck Surg.Dec.1995;113:724-32.
3. Settipane GA, Chafee FH .Nasal polyps in asthma and rhinitis. A review of 6,037 patients .J Allergy Clin Immuno 1977;59:17-21 .
4. Singh H ,Ballow M. Role of cytokines in nasal polyposis . J Investig Allergol Clin Immuno 2003;13:6-11 .
5. Tasker A, Dettmar PW, Panetti M , Koufman JA , Birchall JP .Reflux of gastric juice and glue ear in children . Lancet. 2002;359:493 .
6. Selimoglu MA ,Ertekin V , Tan H, Selimoglu E. Idiopathic cyclic vomiting syndrome associated with gastroesophageal reflux and chronic sinusitis . J Pediatr. 2003;143:545.
7. Ozdek A, Cirak MY , Samim E .A possible role of *Helicobacter pylori* in chronic rhinosinusitis: a preliminary report .Laryngoscope 2003;113:679-82 .
8. Ulualp SO , Toohill RJ , Hoffmann R , Shaker R. Possible relationship of gastroesophagopharyngeal acid reflux with pathogenesis of chronic sinusitis . Am J Rhinol 1999;13:197-202 .
9. Bothwell MR ,Parsons DS ,Talbot A ,Barbero GJ ,Wilder B. Outcome of reflux therapy on pediatric chronic sinusitis. Otolaryngol Head Neck Surg 1999;121:255-65 .
10. Unver S , Kubilay U , Sezen OS ,Coskuner T .Investigation of *Helicobacter pylori* colonization in adenotonsillectomy specimens by means of the CLO test .Laryngoscope .2001;111:2183-86 .

HELICOBACTER PYLORI AND NASAL POLYPOSIS

11. Uygur –Bayramicli O , Yavuzer D . Dabak R ,Aydin S ,Kurt N .Helicobacter pylori colonization on tonsil tissue .Am J Gastroenterol 2002;97:2470 .
12. Cammarota G ,Tursi A ,Montalto M .Role of dental plaque in the transmission of Helicobacter pylori infection .J Clin Gasrtenterol . 1996;22:174-77 .
13. Mravak- Stipetic M ,Gall –Troselj K , Lukac J . Detection of Helicobacter pylori in various oral lesions by nested polymerase chain reaction (PCR).J Oral Pathol Med . 1998;27:1-3 .
14. Li C , Musich PR ,Ha T .High prevalence of Helicobacter pylori in saliva demonstrated by noval PCR assay .J Clin Pathol.1995;48:662-66.
15. Price AB .The histological recognition of Helicobacter pylori . In: Lee A , Megraud F ,Eds .Helicobacter pylori : techniques for clinical diagnosis and basic research . London: WB Saunders .1996;33-49 .
16. Rotimi O , Cairns A , Gary S ,Moayyedi P , Dixon M. Histological identification of Helicobacter pylori : comparison of staining methods .J Clin Pathol .2002;53:756-9 .
17. Haqqani MT. Ocriidine orange stain in histological identification of Helicobacter pylori .J Clin Pathol .2001;54:734 .
18. Salyers AA , Whitt DD. Bacterial pathogenesis :A molecular approach .Washington ,DC :American society for microbiology .1994 .
19. Ieven M .Detection ,specification and identification ,2 : detection . In : Williams P ,Ketley J,Salmond G ,Eds .Methods in microbiology : Bacterial pathogenesis .London , England : Academic Press.1997;41-50.
20. Megraud F. A growing demand for Helicobacter pylori culture in near future . Ital J Gastroenterol Hepatol .1997;29:574-6.
21. Zhang Y ,Isaacman DJ, Wadowky RM ,Rydquist –White J , Post JC ,Ehrlich GD .Detection of Setreptococcus pneumonia in whole blood by PCR .J Clin Microbiol.1995;33:596-601.
22. Wong KC ,Ho BSW ,Egglestone SI ,Lewis WHP .Duplex PCR system for simultaneous detection of Neisseria gonorrhoeae and Chlamydia trachomatis in clinical specimens. J Clin Pathol .1995 ;48:101-4 .
23. Brook MD , Currie B , Desmarchelier PM .Isolation and identification of Burkholderia pseudomallei from soil using selective culture techniques and the polymerase chain reaction .J Appl Microbiol .1997;82:589-96 .
24. Molyneux AJ ,Haris MD . H.pylori in gastric biopsy –should you trust the pathological report? .Roy Coll Phys Lond .1993;27:119-20 .
25. Potter HV ,Loffeld RJ, Stobberingh E , Van Spreuwel JP, Arends JW.Rapid staining of campylobacter pylori . histopathology. 1987;11:1223 .
26. Szczygielski K , Jurkiewicz D , Rapiejko P . Detection of Helicobacter pylori in nasal polyps specimens using urease test GUT plus .2005;19:309-311 .
27. Koc C , Arikan OK , Atasoy P , Aksoy A .Prevalence of Helicobacter pylori in patients with nasal polyps : a preliminary report. Laryngoscope. 2004;114:1941-44.
28. Contencin P , Nancy P . Nasopharyngeal PH monitoring in infants and children with chronic rhionopharyngitis .Int J Pediatr Otorhinolaryngol 1991;22:249-256 .
29. Contencin P ,Maurage C , Ployet MJ .Gastroesophageal reflux and ENT disorders in children .Int J Pediatr Otorhinolaryngol .1995;32:135-44 .
30. Fennerty MB .Extraesophageal reflux disease :presentations and approach to treatment .Gastroenterol Clin North Am .1999;28:861-73 .
31. Tauber S , Gross M , Issing WJ .Association of laryngopharyngeal symptoms with gastroesophageal reflux disease .Laryngoscope 2002;112:879-86 .