



# The Effect of Orally Administered *Lactobacillus rhamnosus* as “Systemic Probiotics” on C-Reactive Protein Levels and Wound Healing of Oral Mucosa in Rabbits

Rashad Sinan Attarbashi<sup>1\*</sup> , Faehaa Azher Al-Mashhadane<sup>2</sup> , Rasha Farouk Albannaa<sup>3</sup> 

<sup>1,2</sup>Department of Dental Basic Sciences, University of Mosul, Mosul, Iraq

<sup>3</sup>Acute Dental Care, Leeds Dental Institute, University of Leeds/ United Kingdom

## Article information

Received: 26 November 2023

Accepted: 21 January 2024

Available online: 15 March 2024

## Keywords

Probiotics

*Lactobacillus rhamnosus*

Oral mucosa

Wound healing

CRP

## \*Correspondence:

rashad.22dep1@student.uomosul.edu.iq

## Abstract

**Aims:** This study investigates the beneficial role of *Lactobacillus rhamnosus* in oral wound healing. **Materials and methods:** Twenty-five rabbits were divided into three main groups; First was the Negative Control group (group I) with five rabbits, these had neither surgery nor treatment. The second was the Positive control group (group II) with ten rabbits, these had an incisional cut of 1cm in their buccal mucosa but none had received any treatment. The rabbits in this group were subdivided into two subgroups (a and b) with five animals each according to the time of euthanasia, as explained below. The third was the treatment group (group III) with ten rabbits. These all had the same oral incision and received probiotic drops (VITRON® Farma, Turkey); an already prepared solution containing *Lactobacillus rhamnosus*, 5 oral drops (0.25 ml)/kg to be swallowed once daily starting from the first day of study till the day of euthanizing. Animals in this group were also subdivided equally into a and b subgroups according to the time of euthanasia. The rabbits from group I and subgroups IIa and IIIa were euthanized on the third-day post-surgery. All other rabbits from subgroups IIb and IIIb were euthanized on the seventh-day post-surgery. Serum samples were collected and mucosal tissue at wound sites was excised for histological analysis. **Results:** The serum levels of C-reactive protein (CRP) in the third-day groups of the study indicated a highly significant difference ( $P \leq 0.001$ ), as well as between the groups on the seventh day which also showed a noticeable decrease in the concentration of these cytokines. A microscopic inspection in the Positive Control group after three days revealed a wound with inflammatory exudate, fibrin deposition, and destruction of the epithelium layer of mucosa with slight re-epithelialization. The seventh-day tissue of the positive control group showed highly inflammatory cell infiltration, fibrin deposition, re-epithelialization, and minimal granulation tissue formation. In contrast, the treatment group's mucosal wounds on three postsurgical days showed a wound site with little inflammatory exudate, early signs of re-epithelialization, and well-formed granulation tissue, while on day seven showed a wound site with no inflammatory exudate, well-developed re-epithelialization, well granulation tissue formation and signs of angiogenesis. **Conclusion:** Systemic probiotic *Lactobacillus rhamnosus* enhanced the wound healing of oral mucosa in rabbits.

## الخلاصة

**الأهداف:** تبحث هذه الدراسة في الدور النافع للبكتريا العسوية *Lactobacillus rhamnosus* في تحسين التئام الجروح الفموية. **المواد وطرق العمل:** الدراسة شملت خمسة وعشرون أرنب، تم تقسيم الأرناب المختبرية الى ثلاث مجاميع رئيسية: مجموعة السيطرة السالبة I (خمسة ارناب) الذين لم تجرى عليهم أي عملية جراحية ولم يتم تجربتهم أي دواء. ومجموعة السيطرة الموجبة II (عشرة ارناب)، تم تقسيمهم الى مجموعتين فرعيتين: أ، ب (خمسة ارناب لكل واحدة)، تم عمل جرح في النسيج المخاطي لبطانة الخد قياسه سننيمترا واحدا، ولم يتم تجريب هذه المجموعة أي علاج. اما المجموعة الثالثة (عشرة ارناب) والمسماة بمجموعة العلاج، تم تقسيمهم ايضا الى مجموعتين فرعيتين بالتساوي: أ، ب وتم عمل جرح في البطانة المخاطية للفم وتجربتهم البروبيوتك ليتم ابتلاعه الى الجهاز الهضمي وذلك بتقطير خمس قطرات فموية (0.25 مل/كغم) من محلول ال (VITRON) الجاهز والمحتوي على *Lactobacillus rhamnosus* بجرعات يومية منذ بداية التجربة الى نهايتها. تم قتل الحيوانات من المجاميع (I, IIa, IIIa) بطريقة القتل الرحيم في اليوم الثالث، أما الحيوانات في المجموعتين (IIb, IIIb) فقد ذبحت بالقتل الرحيم في اليوم السابع. تم جمع عينات السيروم لتحليلها مختبريا، وتم اقتطاع النسيج المخاطي المحيط بمنطقة الجرح لغرض إجراء التحليل النسيجي. **النتائج:** كانت مستويات CRP في مجاميع اليوم الثالث من الدراسة تشير الى وجود فرق معنوي عالي، وكذلك الحال بين مجاميع اليوم السابع والتي أظهرت وجود فرق احصائي ملحوظ في تراكيز هذه المؤشرات المناعية. أظهر الفحص النسيجي لمجموعة العلاج بعد ثلاثة أيام من الجراحة جرحا يحتوي على إفرازات التهابية تحتوي على ارتشاح خلايا التهابية معتدلة، وترسب الفيبرين، وتدمير الطبقة الظهارية من الغشاء المخاطي مع إعادة التشكل الظهاري وأنسجة حبيبية جيدة، بينما في اليوم السابع أظهرت هذه مجموعة العلاج موقع الجرح بدون إفرازات التهابية مع إعادة الظهارة المتطورة والأنسجة الحبيبية بشكل جيد مع تكوين الأوعية الدموية. **الاستنتاجات:** تناول البروبيوتك *Lactobacillus rhamnosus* عن طريق الفم يعزز من شفاء الجروح في الغشاء المخاطي للفم.

## INTRODUCTION

Globally, wounds are a major cause of morbidity and mortality, primarily from microbial infections. Among the current wound treatment techniques are: pharmaceutical therapy, debridement, irrigation, antiseptic use, and tissue grafting. However, there are unfavorable side effects such as bleeding, tissue damage, delayed wound healing, and possible bacterial resistance linked to various therapeutic modalities [1].

Despite the important developments in the pharmacological field, there are currently few natural or biological products available that could accelerate the healing process of wounds with no or minimal side effects. Additionally, infection-related morbidity and death have gotten worse due to the rise in resistant bacteria, the high cost of treatment, and a lack of new medications, particularly in the developing world [2]. Therefore, research on safe, all-natural, and efficient wound-healing agents is desperately needed.

Probiotics are described by the WHO as "live microorganisms that, when administered in adequate amounts, confer a health benefit on the host" [3].

*Lactobacillus rhamnosus* is one of the most favorable strains of biotherapeutic bacteria since it can grow rapidly, adhere firmly, and resist bile acids to stay for a more extended time inside the gut and apply stronger effects as compared to other

bacteria, including protecting the gut lining [4].

The ability of gut microbiota to preserve intestinal homeostasis is widely recognized. On the other hand, dysbiosis, or the disturbance of this equilibrium, has several negative effects, including systemic and localized inflammation. Patients and medical professionals are often concerned about inflammation caused by surgery since it can result in both infectious and non-infectious problems. Restoring gut microbiota following surgical disturbances may hasten the healing process locally and reduce systemic inflammation, both of which may be advantageous for particular individuals [5].

The pro-inflammatory cytokine CRP is an inflammatory protein that is mostly produced during the acute stage of an infectious or inflammatory event. According to the research, CRP is not just a biomarker of inflammation but it's also actively involved in it [6].

During the acute period of inflammation, the blood's CRP concentration rises noticeably, reaching a peak after around 48 hours. As soon as the stimulation causing the elevated production ceases, the blood concentration rapidly returns to normal. CRP levels rise and decline more quickly with the beginning and removal of the inflammatory stimuli [7].

This study focused on the effect of orally administered *Lactobacillus rhamnosus* as systemic probiotics on wound contraction,

serum levels of CRP, and histopathological changes during the mucosal healing process in rabbits' mouths.

## **MATERIALS AND METHODS**

### **Ethical approval**

The Research Ethics Committee and the Scientific Committee at the Department of Basic Dental Sciences, College of Dentistry, University of Mosul approved this study. Approval No.: UoM-Dent.23/16.

### **Animals**

Twenty-five local male rabbits, weighing 1-1.5 kg and ranging in age from 12 to 18 months were used in this study. They were housed individually in cages with a specific ambient temperature of  $24\pm 2^{\circ}\text{C}$ , a light-dark cycle of 12 hours, and free access to water and regular food [8].

### **Surgical procedure**

The surgical procedure involved an intramuscular injection of xylazine hydrochloride, a sedative and muscle relaxant, and ketamine hydrochloride, an anesthetic and analgesic, at a dose of 5, 50 mg/Kg into the thigh muscle to anaesthetize the animals [9].

The sedated animal was then placed on its side on the surgical board. With a surgical blade no. 15 and mouth retractor, a 1 cm horizontal incision was created in the animal buccal mucosa.

The twenty-five rabbits were divided into three main groups; the first was the negative control group (group I) with five rabbits, these had neither surgery nor treatment. The second was the positive control group (group II) with ten rabbits,

these had an incisional cut of 1cm in their buccal mucosa but none had received any treatment. The rabbits in this group were subdivided into two subgroups (a and b) with five animals each according to the time of euthanasia, as explained below. The third was the treatment group (group III) with ten rabbits. These all had the same oral incision and received probiotic drops (VITRON®Farma, Turkey); an already prepared solution containing *Lactobacillus rhamnosus*, 5 oral drops (0.25 ml)/kg to be swallowed once daily starting from the first day of study till the day of euthanizing. Animals in this group were also subdivided equally into a and b subgroups according to the time of euthanasia. The rabbits from group I and subgroups IIa and IIIa were euthanized on the third-day post-surgery (3PO). All other rabbits from subgroups IIb and IIIb were euthanized on the seventh day post-surgery. Five milliliters of blood were taken from the jugular vein of euthanized rabbits into plain tubes, and stored for thirty minutes at room temperature [10].

The serum was separated and transported to Eppendorf tubes and stored at ( $-20^{\circ}\text{C}$ ) until the time of analysis with rabbit C-Reactive Protein kits BT LAB (Bioassay Technology Laboratory) Cat.No E0016Rb. In addition, the wounded area was surgically excised by surgical scissors, cleaned with normal saline, and put in 10% formalin for histological investigation. These sections were examined by three histopathologists for histological changes.

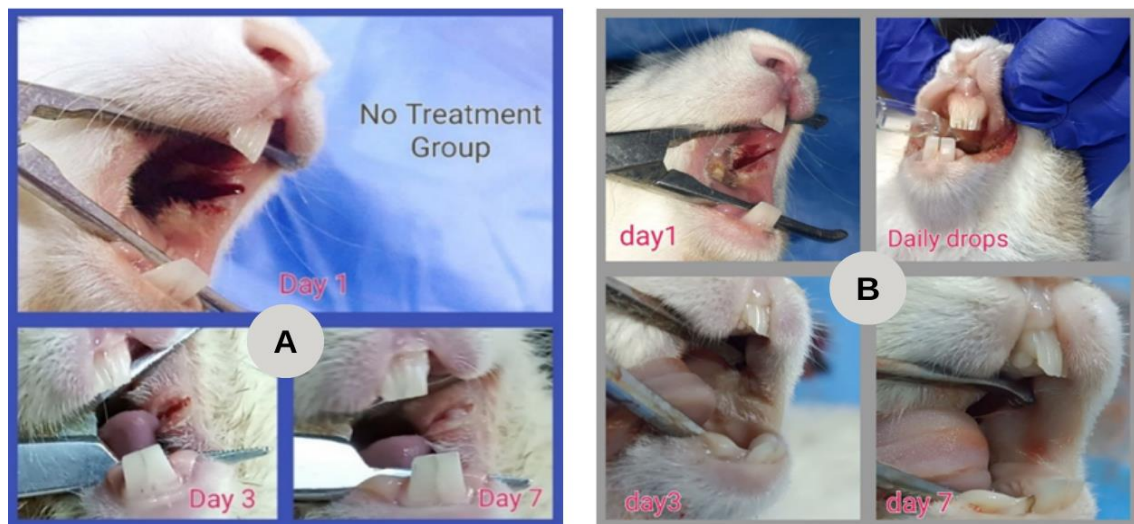**Statistical analysis of serum results**

The serum data was organized in an Excel spreadsheet and analyzed using the IBM SPSS Statistics® software, v.25. The results were expressed by mean values ± standard deviation. Since the data were not distributed normally according to the Shapiro-Wilk test, they were statistically analyzed by the nonparametric tests. To compare between two independent groups, the non-parametric Mann-Whitney test was used. The comparisons within groups were analyzed by the Kruskal-Wallis test. Values of  $p < 0.05$  indicated statistical significance.

**RESULTS**

**Clinical observations**

The animals were under continual observation by the veterinarian. Throughout the trial period, no unusual signs or symptoms in the activity, behavioral patterns, or other clinical observations were noted in any of the groups, except for local changes in the wound area in comparison to the control group. The wounds were checked regularly (Figure 1), and their sizes were determined using a ruler immediately after surgery (day 1) and on days 3 and 7 post-surgery (Table 1)



**Figure (1):** Mucosal wound healing in Control positive (A) and treatment (B) groups on days 1, 3 and 7.

**Table (1):** The size of the wound during the healing process.

Group	Size of wound		
	1 <sup>st</sup> day	3 <sup>rd</sup> day	7 <sup>th</sup> day
Positive control	10 mm	6-8 mm	3-4 mm
Treatment	10 mm	4-6 mm	1-2 mm

By calculating the rate of wound contraction as a percentage of the initial wound size, the healing process of the wound was evaluated according to the below equation:<sup>[1]</sup>

$$\% \text{ WCR} = (\text{Initial wound size} - \text{Specific day wound size}) / (\text{Initial wound size}) \times 100$$

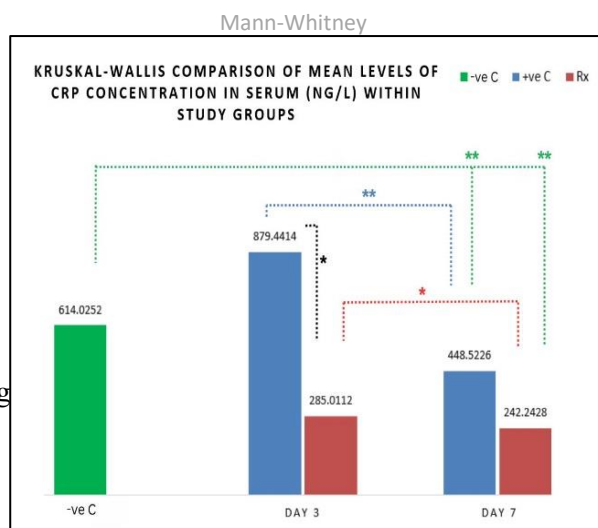
The wound closure rate was used as a parameter and it indicated that the wound closure rate in the treatment group was faster than that of the positive control group according to measurements of wound healing as shown in (Table 2)

**Table (2):** The wound contraction ratio during healing for all study groups.

Groups	Wound contraction ratio (WCR)%		
	Day 1	Day 3	Day 7
Control positive	0%	30%	65%
Probiotic Group	0%	50%	85%

**Serum CRP results**

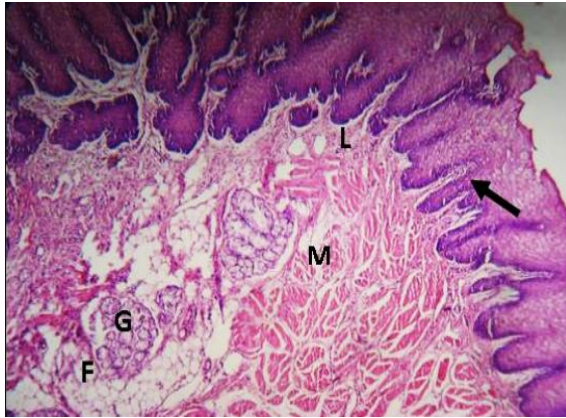
The results showed a highly significant difference in CRP mean levels among groups with a significant value of 0.001 according to Kruskal-Walli’s test. As shown in Figure (2), the CRP levels revealed a gradual increase from 614±177 ng/L in the control negative (green bar) going up to 879±293 ng/L on 3<sup>rd</sup> postoperative day (3PO) in the control positive group (blue bars) then 448±172 ng/L at the end of the experiment. On the other hand; the treated group (red bars) showed a significant decrease in the CRP 285±126 ng/L on 3PO, and 242±45 ng/L on the 7<sup>th</sup> postoperative day (7PO) and remained less than the level of other groups which indicates less inflammatory cytokine and better healing.



**Figure (2):** CRP levels of mean values within study groups on days 3 and 7 compared by the Kruskal-Walli’s test. (-C) =Negative Control; (+C) = Positive Control; (Rx)= Treatment group.Mann-Whitney comparison (dashed lines) between two independent groups: (\*) indicates a significant difference at  $P \leq 0.05$ ; (\*\*) indicates a highly significant difference at  $P \leq 0.01$ .

**Histopathological Analysis**

Histopathological sections were prepared from each mucosal specimen. Each slide was examined under a light microscope by a well-experienced histopathologist who read inflammatory cell infiltration (ICI), re-epithelialization (RE), and Granulation tissue formation (GT) scoring. The means of these readings were regarded as a final score. The histological appearance of the normal buccal mucosa of rabbits showed a very thick non-keratinized stratified squamous epithelium. The lamina propria had long slender papillae, a dense fibrous connective tissue containing collagen and some elastic fibers, rich blood supply giving off anastomosing capillary loops into papillae [11]. The mucosa was firmly attached to the underlying muscle by dense collagenous connective tissue with fat and minor salivary glands Figure (3).



**Figure (3):** light micrograph of the normal buccal mucosa of rabbit in group I showing very thick non-keratinized stratified squamous (black arrow) of the covering epithelium. The lamina propria (L) have long slender papillae. The mucosa is firmly attached to the underlying muscle(M) by dense collagenous connective tissue with fat(F) and minor salivary glands (G). H&E.[X-40]

Based on these standards, a histological study was conducted to evaluate the factors influencing the wound healing process:

1- Inflammatory Cells Infiltration scoring scale.

Score 1: Nil. The absence of inflammatory cells was observed in the area.

Score 2: Mild. Few inflammatory cells are seen, less than half of the area.

Score 3: Moderate. Inflammatory cells might be observed in more than half of the area.

Score 4: Severe. Inflammatory cells are seen in abundant quantity, more than three-quarters of the area.

2- Granulation tissue formation scoring criteria:

Score 1: no granulation tissue formed.

Score 2: The amount of granulation tissue in the gap is small.

Score 3: The number of granulation tissue formed is moderate.

Score 4: The overall granulation tissue formed is profound.

3- Grading system for assessment of Re-epithelialization.

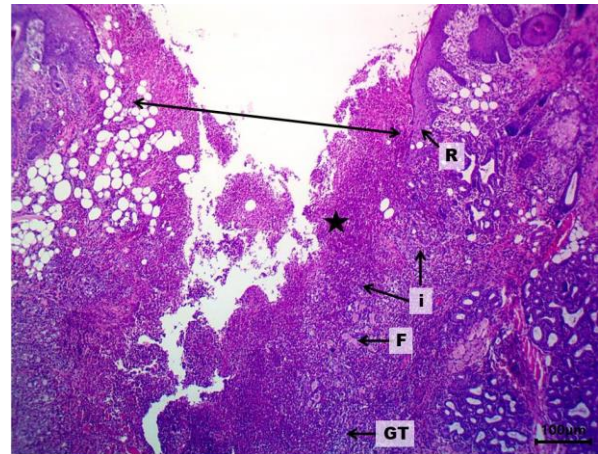
Score 0: Re-epithelialization at the edge of the wound.

Score 1: Re-epithelialization covering less than half of the

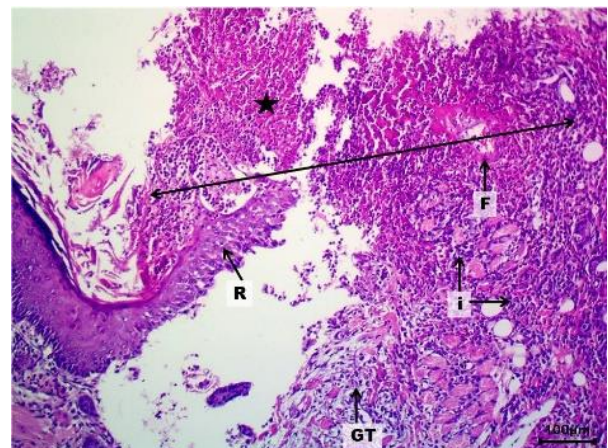
wound. Score 2: Re-epithelialization covering more than 1/2 of the wound.

Score 3: Re-epithelialization covering all of the wound, irregular thickness.

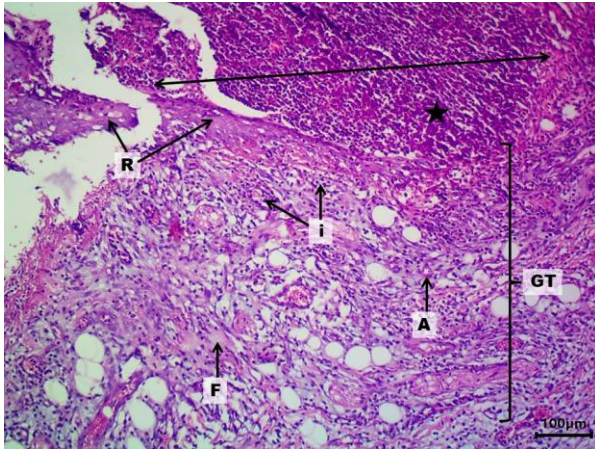
Score 4: Re-epithelialization covering the whole wound, thickness is normal [11].



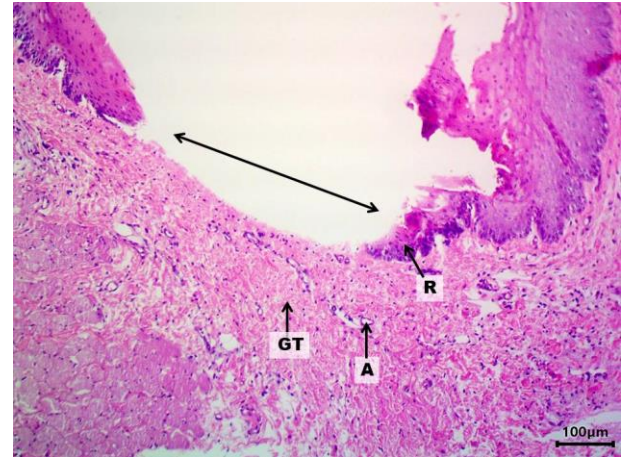
**Figure (4):** Histological section of oral mucosa of rabbit of control positive (No treatment group) after 3 days showing wound site (↔) with the inflammatory exudate (star), containing highly inflammatory cells infiltration (score 3) (I), and fibrin deposition (F), destruction of epithelium layer of mucosa with few re-epithelialization (score 1) (R), and few granulations tissue (score 1) (GT). H&E stain, 100X.



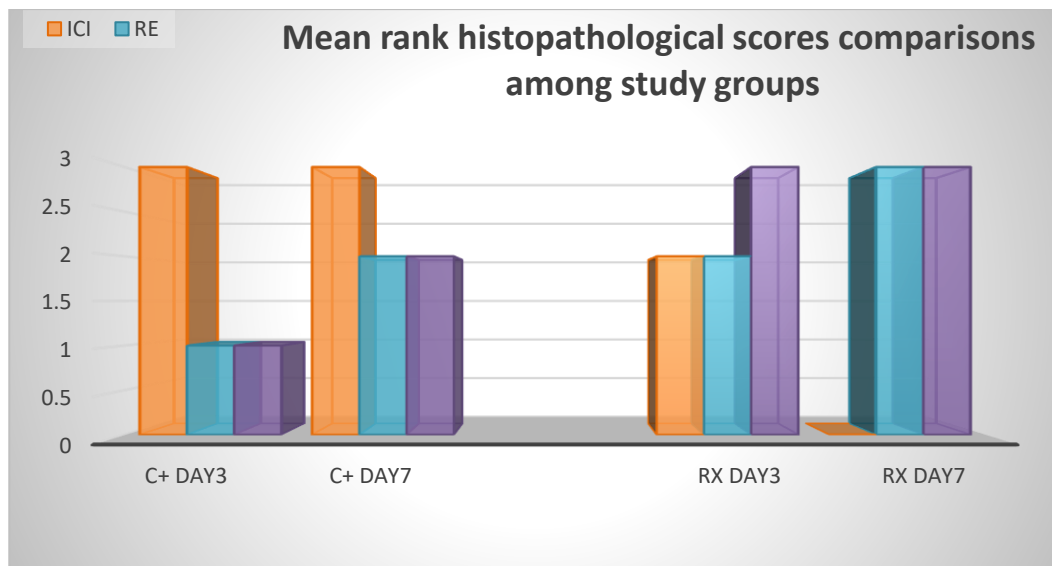
**Figure (5):** Histological section of rabbit oral mucosa of control positive (No treatment) group (7 days) demonstrating wound site (↔) with the inflammatory exudate (star), containing highly inflammatory cells infiltration (score 3) (I), and fibrin deposition (F), re-epithelialization (score 2) (R), and few Granulations tissue (score 2) (GT). H&E stain, 40X.



**Figure (6):** Histological section of rabbit oral mucosa of the treatment group after on 3PO revealing wound site ( $\leftrightarrow$ ) with the inflammatory exudate (star), containing moderate inflammatory cells infiltration (score 2) (I), and fibrin deposition (F), destruction of epithelium with re-epithelialization (score 2) (R), and well granulation tissue (score 3) (GT). H&E stain, 40X



**Figure (7):** Histological section of rabbit oral mucosa of the treatment group on 7PO revealing wound site ( $\leftrightarrow$ ) without the inflammatory exudate (score 0) with well-developed re-epithelialization (score 3) (R), and well granulation tissue (score 3) (GT) with angiogenesis (A). H&E stain, 40X.



**Figure (8).** Comparison of histopathological mean rank scores between Control and Treatment Groups at day 3 and day 7. (ICI)= Inflammatory Cell Infiltration; (RE)= Re-epithelialization; (GT)= Granulation Tissue; (C+) = Control Positive group; (Rx)= Treatment group.

## DISCUSSION

Orally administered probiotics work by altering the microbiome of the host, e.g., by inhibiting infections, generating active chemicals or metabolites, opening up cellular

channels in epithelial cells, adjusting the action of the nervous system, and modifying the function of the mucosal defense system, or changing gene expression of some inflammatory mediators [12].

Based on research done on mice, Moriera *et al.* explained the possible mechanism of systemic probiotics on remote tissue like the skin as the majority of the health benefits linked to *Lactobacillus* are attributed to its capacity to generate a wide variety of bioactive metabolites and acids, including carbon dioxide, hydrogen peroxide, bacteriocin, diacetyl, and organic acids (lactic and acetic acids). Nevertheless, little is known about the processes behind the advantageous effects of probiotics when taken orally on distant tissues. The substances that are causing this activation may be *Lactobacillus* structural elements or metabolic products [13].

In comparison between the healing mechanism in mucosa and skin, Tagiliari *et al.* studied the impact of probiotics on rat skin healing, demonstrating that probiotics and their metabolites are thought to regulate several biological processes, with the intestine-skin axis being the focus of research on how they affect wound healing. Probiotics' systemic effects involve enhancing the relationship between the cutaneous and intestinal microbiota, reducing inflammation, changing the microbiota's composition in both locations, and controlling the natural immune system. When taken orally, oral medication enhances the gut microbiota and increases the absorption of vital nutrients for wound healing, including vitamins, minerals, and co-factors for the main enzymes that control cutaneous healing [14].

The clinical pictures in Figure (1) and the percentages of wound contraction in Table (2) showed that the probiotic group's wound

closure rate took less time than that of the untreated group which means a faster and better quality of healing in the presence of probiotic at the middle and the end of the experiment as compared to the Positive Control, resulting in a smaller and scarless wound area which could be of great benefits in treating oral wounds like ulcers, trauma or post-surgical wounds

#### **CRP serum levels**

*Lactobacillus rhamnosus* is a probiotic strain that shows great promise. It has been discovered that *L. rhamnosus* itself protects intestinal epithelial cells and lowers inflammatory indicators like IL-1, interleukin-8 (IL-8), and C-reactive proteins (CRP) [6]. This explains why there was more reduction in CRP levels in the treated group than the untreated ones in this study as shown in Figure (2) where the *L. rhamnosus* seemed to work as an inhibitor of CRP.

Although A the pro-inflammatory cytokine, CRP is essential for the host's defense mechanisms against infection and damage [12], its levels were firstly increased in the untreated group three times more than the treated ones on 3PO (3 postoperative days) and about double on 7PO (7 postoperative days). Therefore, it might be responsible for the inflammatory signs in both groups during the early phase, but at the end of the experiment, the high level of CRP in the untreated group can explain the lower quality of wound healing on 7PO as compared to its level in the other group treated with systemic probiotic, where the low level of pro-inflammatory cytokine is a good indicator of



better healing due to the effect of probiotics which also on inhibit the pro-inflammatory cytokines by stimulating the anti-inflammatory cytokines like IL-10 [7]. The same outcome was found by Lopez *et.al* who concluded that probiotics may control cytokine synthesis and trigger antimicrobial immune responses, they also promote the development of more IL-10, which in turn suppresses the inflammatory response and produces antibodies, thereby balancing and promoting healing [15].

### **Histopathology**

The four subsequent stages of hemostasis, inflammation, proliferation, and remodeling are critical as different cell types play a wide range of independent roles to orchestrate the complex process of wound healing. Starting from the outside inward, the healing process improves the collagen's structure by reorganizing the fibers. In the current investigation, the amount of scar tissue and collagen deposition was decreased in rabbits given *L. rhamnosus* orally at the end of the trial. However; a study of different probiotic strains by Al-Abdallah *et al.* showed that type III collagen filled the scar area more, which increased the amount of type I collagen produced [16].

Several biological processes are triggered right away after tissue damage to rebuild the damaged tissue. In addition to endothelial cells, keratinocytes, and fibroblasts, the immune system's monocytes, neutrophils, lymphocytes, and dendritic cells are among the cells involved in wound healing [17].

As the excessive inflammation promotes tissue injury and delays the wound healing process, the above results proved better healing outcomes with probiotics and matched with clinical pictures where the control positive group showed incomplete wound closure on 7PO when compared to the treatment group whose wound healed almost completely at the end of the week [18].

Singh *et al.* (2017) explained the role of oral treatment with *L. rhamnosus* in increasing the levels of the pro-angiogenic VEGF (Vascular Endothelial Growth Factor) cytokine in the wound site and described "Angiogenesis" as an essential element of wound healing that transports nutrients and oxygen to the new tissue for cell metabolism. Both the blood flow and the density of blood vessels in the granulation tissue were enhanced by the oral administration of *L. rhamnosus* [19].

In Figure (7) new blood vessel formation is seen after 7 days of treatment. This is in agreement with previous studies, like (Campos *et al.*) study, which indicated that probiotic supplementation promotes wound healing, potentially as a result of a faster neovascularization process and a weakened inflammatory response [20].

Granulation tissue, which is made up of fibroblasts, blood vessels, and several leukocyte subtypes such as mast cells, neutrophils, and macrophages, is essential for the healing of wounds. The numerous inflammatory mediators generated following the damage activate and attract these cells to the wound site [21].

In the bar chart in Figure (8) of this study, ICI disappeared gradually in the treated animals by scoring a mean rank of 0 on 7PO, indicating less or no inflammation (i.e. better healing) as compared to the untreated animals at this stage. Another sign of better quality of mucosal healing in the probiotic group was the higher rate of re-epithelialization and granulation tissue formation in the group where *L. rhamnosus* was administered daily for a whole week.

### CONCLUSION

To the best of our knowledge, this is the first study to demonstrate that giving probiotics orally soon after wounding has a beneficial impact on the healing of oral mucosal wounds in rabbits. The results imply that orally giving *Lactobacillus rhamnosus* probiotics, resulted in improved healing of mucosal wounds among the treatment group and revealed a significant decrease of serum pro-inflammatory CRP, accelerating wound closure, improvement of blood supply, and attenuation of scar formation, concluding that using probiotics might have a promising role in the treatment of oral wounds in animals and human as well.

A small sample size and a brief study period are two of the research's limitations. However, we believe that systemic probiotic administration has a good impact on the oral mucosa's ability to repair wounds in rabbits and may have a similar effect in humans. Further research is required to verify these findings.

### Conflicts of Interest

The authors declare that there are no conflicts of interest regarding the publication of this manuscript.

### Acknowledgment

All thanks to the College of Dentistry at the University of Mosul for all support.

### REFERENCES

- [1] S. G. G/giorgis, D. Ambikar, A. Tsegaw, and Y. M. Belayneh, "Wound Healing Activity of 80% Methanolic Crude Extract and Solvent Fractions of the Leaves of *Justicia schimperiana* (Hochst. ex Nees) T. Anderson (Acanthaceae) in Mice," *J Exp Pharmacol*, vol. 14, pp. 167–183, 2022, doi: 10.2147/JEP.S340177.
- [2] A. Teka *et al.*, "In vitro antimicrobial activity of plants used in traditional medicine in Gurage and Silti Zones, south central Ethiopia," *BMC Complement Altern Med*, vol. 15, no. 1, Aug. 2015, doi: 10.1186/s12906-015-0822-1.
- [3] D. Merenstein *et al.*, "Emerging issues in probiotic safety: 2023 perspectives," *Gut Microbes*, vol. 15, no. 1. Taylor and Francis Ltd., 2023. doi: 10.1080/19490976.2023.2185034.
- [4] V. Sanborn, M. A. Azcarate-Peril, J. Updegraff, L. Manderino, and J. Gunstad, "Randomized clinical trial examining the impact of *Lactobacillus rhamnosus* GG probiotic supplementation on cognitive functioning in middle-aged and older adults," *Neuropsychiatr Dis Treat*, vol. 16, pp. 2765–2777, 2020, doi: 10.2147/NDT.S270035.

- [5] R. Matzaras, N. Anagnostou, A. Nikopoulou, I. Tsiakas, and E. Christaki, "The Role of Probiotics in Inflammation Associated with Major Surgery: A Narrative Review," *Nutrients*, vol. 15, no. 6. Multidisciplinary Digital Publishing Institute (MDPI), Mar. 01, 2023. doi: 10.3390/nu15061331.
- [6] K. Asadullah, W. Sterry, and H. D. Volk, "Interleukin-10 therapy - Review of a new approach," *Pharmacological Reviews*, vol. 55, no. 2. American Society for Pharmacology and Experimental Therapy, pp. 241–269, 2003. doi: 10.1124/pr.55.2.4.
- [7] Y. Sun *et al.*, "Interleukin-10 inhibits interleukin-1 $\beta$  production and inflammasome activation of microglia in epileptic seizures," *J Neuroinflammation*, vol. 16, no. 1, Mar. 2019, doi: 10.1186/s12974-019-1452-1.
- [8] A.-M. Axell *et al.*, "Continuous testosterone administration prevents skeletal muscle atrophy and enhances resistance to fatigue in orchidectomized male mice," *Am J Physiol Endocrinol Metab*, vol. 291, pp. 506–516, 2006, doi: 10.1152/ajpendo.00058.2006.- Androgens.
- [9] F. Ricci *et al.*, "Surfactant lung delivery with LISA and InSurE in adult rabbits with respiratory distress," *Pediatr Res*, vol. 90, no. 3, pp. 576–583, Sep. 2021, doi: 10.1038/s41390-020-01324-2.
- [10] A. H. Naji, W. T. Al-Watter, and G. A. Taqa, "The Effect of Xylitol on Bone Alkaline Phosphatase Serum Level and Bone Defect Diameter in Rabbits," *Journal of Applied Veterinary Sciences*, vol. 7, no. 1, pp. 6–10, 2022, doi: 10.21608/javs.20.
- [11] A. D. Al-Moula, M. H. Ahmed, M. H. Ahmed, A.-M. Ad, A. Mh, and A. M. H. "Study on the Effect of Methotrexate on the Oral Tissues of Adult Male Rabbits," 2013. [Online]. Available: [www.rafidaintentj.net](http://www.rafidaintentj.net)
- [12] G. Lopez-Castejon and D. Brough, "Understanding the mechanism of IL-1 $\beta$  secretion," *Cytokine and Growth Factor Reviews*, vol. 22, no. 4. pp. 189–195, Aug. 2011. doi: 10.1016/j.cytogfr.2011.10.001.
- [13] C. F. Moreira *et al.*, "Lactobacillus rhamnosus CGMCC 1.3724 (LPR) Improves Skin Wound Healing and Reduces Scar Formation in Mice," *Probiotics Antimicrob Proteins*, vol. 13, no. 3, pp. 709–719, Jun. 2021, doi: 10.1007/s12602-020-09713-z.
- [14] E. Tagliari, L. F. Campos, A. C. Campos, T. A. Costa-Casagrande, and L. de NORONHA, "Effect of probiotic oral administration on skin wound healing in rats," *Arquivos Brasileiros de Cirurgia Digestiva*, vol. 32, no. 3, 2019, doi: 10.1590/0102-672020190001e1457.

- [15] C. Togo, A. P. Zidorio, V. Gonçalves, P. Botelho, K. de Carvalho, and E. Dutra, “Does probiotic consumption enhance wound healing? A systematic review,” *Nutrients*, vol. 14, no. 1. MDPI, Jan. 01, 2022. doi: 10.3390/nu14010111.
- [16] T. M. Al-Abdullah and F. A. Al-Mashhadane, “Effects of local nandrolone decanoate on TGF-1 $\beta$  and IGF-1 in the healing of the muscle wound,” *Iraqi Journal of Veterinary Sciences*, vol. 37, no. 4, pp. 949–956, Oct. 2023, doi: 10.33899/ijvs.2023.139125.2885.
- [17] P. C. Smith and C. Martínez, “Wound healing in the oral mucosa,” in *Oral Mucosa in Health and Disease: A Concise Handbook*, Springer International Publishing, 2018, pp. 77–90. doi: 10.1007/978-3-319-56065-6\_6.
- [18] H. N. Wilkinson and M. J. Hardman, “Wound healing: Cellular mechanisms and pathological outcomes,” in *Advances in Surgical and Medical Specialties*, Taylor and Francis, 2023, pp. 341–370. doi: 10.1098/rsob.200223.
- [19] S. Singh, A. Young, and C. E. McNaught, “The physiology of wound healing,” *Surgery (United Kingdom)*, vol. 35, no. 9. Elsevier Ltd, pp. 473–477, Sep. 01, 2017. doi: 10.1016/j.mpsur.2017.06.004.
- [20] L. F. Campos, E. Tagliari, T. A. C. Casagrande, L. de Noronha, A. C. L. Campos, and J. E. F. Matias, “Effects of probiotics supplementation on skin wound healing in diabetic rats,” *Arquivos Brasileiros de Cirurgia Digestiva*, vol. 33, no. 1, pp. 1–6, 2020, doi: 10.1590/0102-672020190001e1498.
- [21] M. B. Serra *et al.*, “From Inflammation to Current and Alternative Therapies Involved in Wound Healing,” *International Journal of Inflammation*, vol. 2017. Hindawi Limited, 2017. doi: 10.1155/2017/3406215.