



# Kirkuk Journal of Medical Sciences

## REVIEW ARTICLE

## Effect of Vitamin D Deficiency on the Occurrence and Recurrence of Benign Paroxysmal Positional Vertigo: A Narrative Review

Raid M. Al-Ani <sup>1,\*</sup>, Taghreed S Saeed Al-Rawi <sup>2</sup>, Ahmad Nasrat Aljuboori <sup>3</sup>, and Harith Ahmed<sup>4</sup>

<sup>1</sup>Department of Surgery/Otolaryngology, College of Medicine, University of Anbar, Anbar, Iraq

<sup>2</sup>Department of Biochemistry College of Medicine, University of Anbar, Anbar, Iraq

<sup>3</sup>Department of Otolaryngology, Hamad Medical Corporation, Faculty of Medicine, Qatar University, Qatar

<sup>4</sup>Al-Emadi Hospital, Qatar

\*Corresponding author email: med.raed.alani2003@uoanbar.edu.iq

Received: 25 January 2024

Accepted: 28 March 2024

First published online: 01 April 2024



DOI:10.32894/kjms.2024.146373.1091.

## ABSTRACT

Benign paroxysmal positional vertigo (BPPV) is a short-lived attack of rotatory vertigo provoked by certain head movements. The most acceptable theories for its pathogenesis are canalithiasis and cupulolithiasis as a result of the detachment of otoconia from the otolithic membrane. Although canal repositioning maneuvers resolve BPPV, recurrence is a common feature. During the last two decades, there is a revolution in research in understanding many aspects of this disorder. The advanced age, female gender, migraine, Meniere's disease, trauma, and infection are recognized examples of the BPPV causes. Vitamin D deficiency or insufficiency is considered a risk factor for the occurrence and recurrence of the disease as indicated by many investigations. Therefore, estimation of vitamin D serum level in all subjects with BPPV is highly recommended. In addition to canal repositioning procedures such as the Epley maneuver, vitamin D supplementation in patients with deficient or insufficient vitamin D is the best treatment for primary BPPV. In this review, we discussed the updating knowledge of the risk factors of BPPV as an initiator for the disease or a risk factor for its recurrence.

**Key words:** Rotatory vertigo; Vitamin D; Benign paroxysmal positional vertigo; Dizziness.



© Authors;

licensed under Creative Commons Attribution 4.0 International (CC BY 4.0)

## INTRODUCTION

**B**enign paroxysmal positional vertigo (BPPV) is considered the most common cause of rotatory vertigo with a prevalence of 10% of individuals during their lifetime [1]. It can be defined as short-lived vertiginous attacks provoked by movement of the head in certain positions such as looking upward. BPPV usually runs in a benign course, however, 86% of sufferers complain of reduced daily activities and might lose certain days from work [1].

The symptoms of BPPV appear when the otoconia detached from the utricle and saccule and pass through the semicircular duct (canalithiasis) or is attached to the cupula (cupulolithiasis) [2].

The components of the otoconia are calcium carbonate ( $\text{CaCO}_3$ ) and glycoproteins which are connected to the hair cells by protein fibers. Active calcium inside the vestibular organ is responsible for the formation, maturation, and degeneration mechanisms of the otoconia. A prior study by Lundberg et al. reported that vitamin D has a role in the metabolism of calcium inside the vestibular organ [3].

All the three semicircular canals might be involved in BPPV, however, the posterior canal is commonly involved, followed by the horizontal or lateral canal, and the least superior canal [4]. Posterior BPPV is usually treated with canal repositioning techniques (Epley or Semont maneuvers or their modifications) with a successful result reaching 100% following 2 or several maneuvers [5, 6]. Recurrence might happen following these maneuvers. A recent study from Korea reported a recurrence rate of 22.1% following 5 years after the initial treatment [7].

In the past, it is believed that female gender, head injury, diabetes mellitus, hypertension, hyperlipidemia, Ménière's disease, and migraine were considered risk factors for BPPV recurrence [8, 9]. A recent meta-analysis of 14 studies with 3060 patients with BPPV reported that vitamin D deficiency is considered a risk factor for BPPV recurrence [10].

Knowing the risk factors for the occurrence and recurrence of BPPV is an essential step to reducing the frequency of the disease and preventing its recurrence. Vitamin D deficiency is one of these risk factors that need to be taken into consideration among physicians dealing with this condition. Hence, this review was conducted to explore the association between vitamin D deficiency and the state of the disease regarding its occurrence and recurrence.

## • Epidemiology

BPPV is considered the most common type of vestibular vertigo reaching about 20–30% of diagnoses in specialized vertigo clinics. The disease has a great impact on the health system with an annual cost of \$ 2 billion [1]. BPPV is the most prevalent cause of dizziness with approximately 10% among the general population [11]. Besides, the prevalence per year is 1.6%, and the incidence per year is 0.6% [1]. BPPV is diagnosed in around 24.1% of the patients attending the hospital with vertigo or dizziness [12].

Although BPPV could occur at any age, it exhibited to be more in the 6<sup>th</sup> and 7<sup>th</sup> decades. The disease is affected women more than men with a male-to-female ratio of 1:2.4 [12]. Recurrence is a common feature of the BPPV with a recurrence rate per year of 15–20% [13, 14].

Elderly females with no regular physical activity have a higher incidence of 2.6 times than those with regular physical exercise [15]. Furthermore, vitamin D deficiency (< 10 ng/ml) or insufficiency (10–20 ng/ml) have more risk to develop BPPV (odds ratios of 23.0 and 3.8 respectively) [16]. Therefore, vitamin D supplement is useful for treating a recurrent form of BPPV.

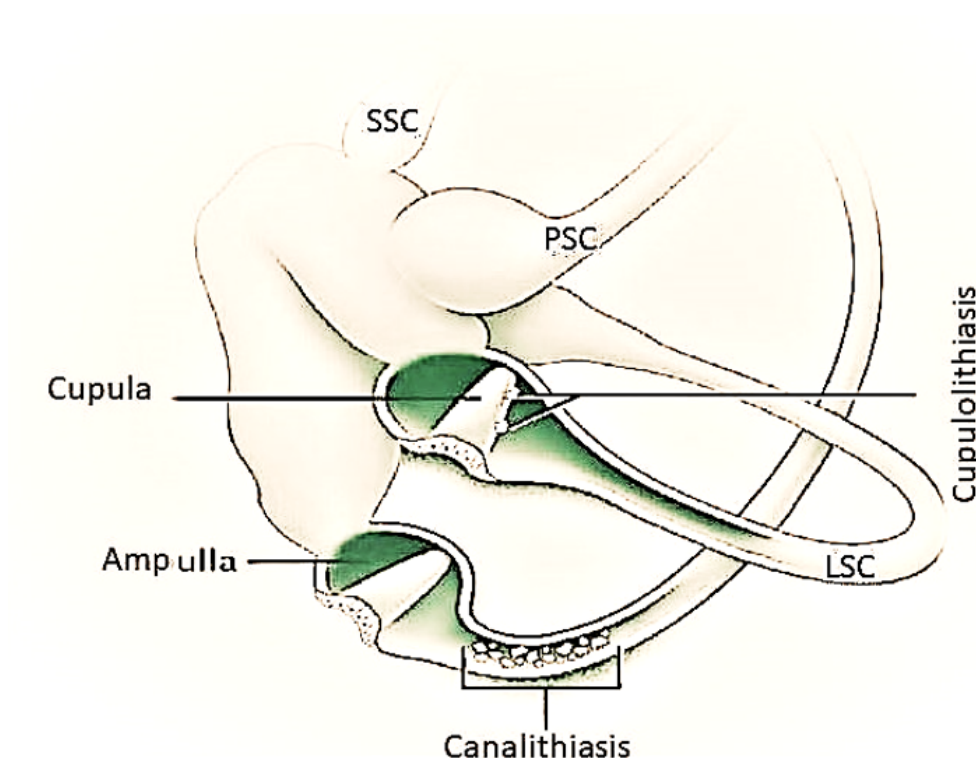
## • Pathophysiology

Maintained body balance depends on three peripheral inputs, namely the eye (70%), the vestibular system of the inner ear (15%), and proprioception from the neck and ankle (15%). The organelles of the vestibular system consist of the macula (in the utricle and saccule) and crista ampullaris (in the ampulla of each semicircular duct). These organelles are responsible for detecting any abnormalities in the position of the head and body. The macula detects linear acceleration and crista ampullaris for angular acceleration. The vertiginous attack of BPPV is due to an abnormal signaling from the involved semicircular duct which results in an illusion sense of movement [17].

There are two possible mechanisms of BPPV: Canalithiasis and cupulolithiasis (**Figure 1**).

Cupulolithiasis is defined as the adherence of the otoconia debris or masses to the cupula which renders the gravity to be sensitive. However, there is no evidence that otoconia attach persistently or strongly to the cupula [18].

Owing to the deposition of otoconia in the cupula, there is an increment in the cupular load resulting in changes in cupular deflection which causes an abnormal sense of movement. This theoretical mechanism is behind the



**Figure 1.** The left semicircular canals and vestibule demonstrate the most accepted theories of benign paroxysmal positional vertigo pathogenesis (canalithiasis and cupulolithiasis). PSC = posterior semicircular canal, LSC = lateral semicircular canal, and SSC = superior semicircular canal.

chronic type of BPPV [19].

Canalithiasis is due to the floating of free particles inside the semicircular duct and is considered a causal effect of the vertiginous attack of the BPPV. This theoretical mechanism was described *in vivo* firstly by Parnes and McClure (1992) [20]. The abnormal signal occurs when gravity pulls these particles (otoconia) through the involved semicircular duct creating a plunger-like effect that leads to displacement of the ipsilateral cupula.

Canalithiasis is the most common form of BPPV during clinical practice [21, 22]. A previous study supported the theory which said that the canaliths' source came from the detachment of otoconia from the utricular otolithic membrane [23]. Utricular otoconia is responsible for the majority of BPPV cases. However, saccular otoconia is less likely to be the cause of the BPPV because it is relatively far away from the semicircular ducts [24].

#### • Causes

There are several possible causes of BPPV (Table 1). We discussed briefly these causes below:

Many studies indicated that advanced age might be a risk factor for BPPV [11, 24, 25]. The mean age of patients with BPPV ranged from 44.39 – 67 years (Table 2). An experimental study on rats by Jang et al. reported that otoconial

degeneration occurs mostly in older ones [26]. Krieger et al. indicated that BPPV should be put on the top of the differential diagnosis list of dizziness and falls in geriatric individuals [27]. However, a recent systematic review revealed that age is not considered a risk factor for the recurrence of BPPV [10]. While, a recent study from Iraq reported that the age might be a risk factor for BPPV recurrence [28]. BPPV due to migraine occurs in the young age group. Besides, migraine is associated with a high incidence of falls in subjects with lateral semicircular canal BPPV [29]. This indicates that migraine may determine the type of BPPV. Furthermore, a large cohort study from Taiwan reported that BPPV has a higher risk of a migraine diagnosis [30]. A recent study from Italy reported that migraine is one of the risk factors for the recurrence of BPPV following successful canalith repositioning procedures (CRPs) [31]. Other risk factors for recurrence reported by the same study include female gender, age, hyperlipidemia, diabetes mellitus, hypertension, osteoporosis, vitamin D deficiency, and vascular diseases [31].

There is a recognized association between BPPV and Meniere's disease. According to a recent systematic study, the frequency of BPPV in Meniere's disease is 14%. BPPV occurs mostly in the ipsilateral side of hydrops, in the female gender, and in more advanced stages of the disease. Canalithiasis of the lateral or horizontal canal is more seen

**Table 1. Risk factors for occurrence and recurrence of benign paroxysmal positional vertigo.**

Risk factors for occurrence	Risk factors for recurrence
Female gender	Advanced age
Elderly	Female gender
Trauma	Ménière's disease
Migraine	Hypertension
Infection	Migraine
Meniere's disease	Hyperlipemia
Osteoporosis	Vitamin D deficiency
Vitamin D insufficiency	Osteoporosis
Sleeping habits	Diabetes mellitus
Sudden sensorineural hearing loss of unknown cause	Head trauma
Diabetes mellitus	Osteoporosis
Chronic neck and head pain	Multiple canal involvement
Inner ear abnormalities	Delayed BPPV treatment using CRP
Pigmentation abnormalities	Vascular diseases
Estrogen deficiency	Number of previous vertigo attacks
Neurological disorders	

in Meniere's disease than idiopathic BPPV. Meniere's disease causes a recurrence rate of BPPV and needs more CRPs [32].

Different viruses might be implicated as causative agents of BPPV. A previous study indicated that serological levels of certain viruses (adenovirus, herpesvirus, cytomegalovirus, and Epstein–Barr virus) are higher in subjects with BPPV than in healthy individuals [33]. In the era of COVID-19, BPPV might occur following COVID-19, this may be due to direct damage by the virus on the otolithic membrane of the peripheral vestibular system as a result of the inflammatory response [34].

Trauma whether accidental or surgical is a well-known cause of BPPV [35]. Head injury is considered a risk factor for BPPV [7].

Other factors that they mentioned in **Table 1** are risk factors for the occurrence and or recurrence of BPPV [31, 35].

#### • **Effect of Vitamin D on benign paroxysmal positional vertigo**

A recent global investigation over 20 years (2002–2021) analyzed the trends of scientific research on BPPV. The study found that there is a significant improvement in the understanding of BPPV. Besides, the association between BPPV and osteoporosis and vitamin D are the main hot topics that were studied in these years [36].

The composition of otoconia consists of inorganic calcium carbonate crystallites deposited on a framework of an organic matrix of glycoproteins (otoconin 90 is the main source). Many investigations indicated that vitamin D is important for the normal development of otoconia and the maintenance of its integrity, which subsequently pre-

serves the normal otolith function [24, 37]. The clinical features of BPPV appear following the dislodgment of otoconia from its membrane inside the semicircular ducts. There is a significant correlation between osteoporosis and BPPV. In osteoporosis, there is abnormal metabolism of calcium and vitamin D and this is considered the principal factor in the occurrence of BPPV [38].

ELISA method is used for the assessment of serum levels of 25-hydroxy vitamin D. According to the published Endocrine Society's Practice Guidelines on Vitamin D, the reference ranges of serum vitamin D were low if less than 20 ng/mL, insufficient 21–29 ng/mL, and sufficient if it is above 30 ng/mL [39].

Many studies reported that there is insufficient or deficient vitamin D in patients with BPPV (**Table 2**).

Recurrent BPPV is defined when the patients mentioned 2 or more histories of episodic vertigo which were the same as the presenting symptom (positional vertigo) at the time of the diagnosis, for at least one month between the attacks [40]. Many researchers reported that vitamin D deficiency is a risk for the recurrence of BPPV (**Table 2**).

It is advisable to screen all subjects with BPPV for vitamin D deficiency as well as treat them with CRPs depending on the involved semicircular canal. If there is the detection of insufficient vitamin D, it is recommended to add a daily dose of 800 IU of vitamin D and 1000 mg of calcium carbonate as a supplementary treatment [41]. Additionally, patients with serum vitamin D levels of 20–30 ng/mL might get benefit from vitamin D supplementation in preventing the recurrence of BPPV [42].

**Table 2.** Role of vitamin D in benign paroxysmal positional vertigo in certain various studies. BPPV = benign paroxysmal positional vertigo, CRPs = canalith repositioning procedures, PSC = posterior semicircular canal, LSC = lateral semicircular canal, and SSC = superior semicircular canal.

No.	Author	Year	Country	Study design	Number of patients	Mean age (years) ± SD	Male/female	Side	Type	Recurrence	Treatment	Main outcome
1	Bülki et al. [24]	2013	Austria	Cohort study	18	67	7/11	11 right, 7 left	PSC BPPV	4	CRPs	Low serum vitamin D levels in subjects with BPPV might get benefit from vitamin D supplementation.
2	Jeong et al. [16]	2013	Korea	Case-control study	100 patients, 192 control	61.8 ± 11.6	37/63 patients, 91/101 controls	NA	Idiopathic, BPPV	NA	NA	Decreased vitamin D level might be associated with BPPV.
3	Talaat et al. [37]	2016	Egypt	Cohort study	93 (28 in group 1 and 65 in group 2)	50.8 ± 12.8 (group1) 50.5 ± 11.4 (group2)	13/15 (group 1), 29/36 (group 2)	NA	Unilateral, idiopathic, PSC BPPV	5 (group 1), 43 (group 1)	Multiple Epley's maneuvers	Correction of vitamin D reduce greatly the BPPV recurrence.
4	Rhim [43]	2016	South Korea	Retrospective case series study	232	No recurrence 50.77 ± 17, Recurrence 48.37 ± 13.9	63/169	NA	Idiopathic BPPV	41	CRPs	Vitamin D is considered a risk factor for BPPV recurrence independent of gender, age, duration of follow-up, and BPPV form.
5	Maslovara et al. [11]	2018	Croatia	Comparative study	40	64 ± 12	11/29	NA	10 with PSC BPPV (canalithiasis), 9 with PSC BPPV (cupulolithiasis)	5/40	Epley maneuver	1. There is no statistically significant differences in the serum vitamin D3 level in subjects with or without BPPV recurrence. 2. 47.5% of patients with vitamin D deficiency, 35% with insufficiency, and 17.5% with a normal level
6	Rhim [2]	2019	South Korea	Cohort study	332	Median age 50 years (IQR, 24 years).	100/232	NA	Canalolithiasis 190, Cupulolithiasis 112, Both 30	53	CRPs	Vitamin D is considered a risk factor for BPPV recurrence.
7	Rhim [44]	2020	South Korea	Case-control study	25 study group, 50 control group	Median, age: 45 years	4/21 case group, 8/42 control group	NA	Idiopathic BPPV	7 case group, 13 control group	Vitamin D injection	Injection of vitamin D3 has no effect on the BPPV recurrence when the gender, age, and BPPV form between patient with or without vitamin D deficiency.
8	Jeong et al. [41]	2020	Korea	Randomized controlled trial	445 treated group, 512 control group	62.2 ± 11.7 Intervention group, 61.6 ± 12.2 observational group	341/616	NA	BPPV	NA	Vitamin D	Vitamin D and calcium supplementation in BPPV patients with decreased serum level of vitamin D may be considered to prevent BPPV recurrence.
9	Han et al. [45]	2021	China	Retrospective case series	201	61.8 ± 9.4	0/201	NA	138, with PSC BPPV, 42 with LSC canalithiasis, and 21 with LSC cupulolithiasis.	NA	CRPs	No significant differences in bone metabolism in postmenopausal female patients with different types of idiopathic BPPV

Table 2. Continued ...

No. Author	Year	Country	Study design	Number of patients	Mean age (years) ± SD	Male/female	Side	Type	Recurrence Treatment	Main outcome
Elmoursy and Ab-bas [21]	2021	Egypt	Cohort study	60	46.02 ± 12.56	24/36	NA	57, with PSC BPPV, 3, With LSC BPPV	CRPs	1. Vitamin D is considered a risk factor of occurrence and recurrence of BPPV. 2. Vitamin D supplementation reduces the recurrence of BPPV.
Resuli et al. [46]	2022	Turkey	Case-control study	Patient group 258, Control group 100	Patient group 43.70 ± 15.44, Control group 44.63 ± 15.42	Patient group 71/187, Control group 35/65	NA	PSC = 222, BPPV, LSC= 26, BPPV, ASC, BPPV=7, Mixed BPPV = 3	CRPs	1. Low vitamin D levels is found in patients with BPPV.2. Vitamin D did not affect the rate of vertigo subtypes.
Sharma et al. [47]	2022	India	Cohort study	40	50	14/26	NA	PSC BPPV	CRPs	Vitamin D supplementation may have a benefit for individuals with BPPV and low serum vitamin D levels.
Libonati et al. [48]	2022	Italy	Multicenter randomized 3-arm clinical trial	128	59.7 ± 14.0 in arm 1, 62.0 ± 9.4 in arm 2, 62.7 ± 12.6 in arm 3	89/39	NA	Recurrent BPPV	CRPs	Supplementation with vitamin D + antioxidants may have a role in preventing BPPV recurrence.
Thomas et al. [49]	2022	India	prospective case-control study	49 patients, 49 control	44-39	16/33	31 left, 17 right, 1 bilateral	PSC BPPV	NA	1.No association between calcium and vitamin D serum levels with BPPV. 2. Low vitamin D serum level may be a risk factor of BPPV recurrence.
Sánchez et al. [50]	2023	Mexico	Randomized Clinical Trial	35	62 ± 13	7/33	NA	PSC BPPV = 39	CRPs plus, Vitamin D injection	Vitamin D supplementation improves the quality of life of the patients with BPPV.
Cobb et al. [25]	2023	USA	Cohort study	173	66.2 ± 11.8	42/131	142 Unilateral, 21 Bilateral	169 PSC BPPV	NA	Low vitamin D serum level may be considered as a risk factor for occurrence and recurrence of BPPV.
Miśkiewicz-Orczyk et al. [51]	2023	Poland	Case series	35	46.57 ± 11.32	7/28	NA	Idiopathic PSC BPPV	NA	No significant associations between the age, body mass index or vitamin D3 serum levels, and bone densitometry findings in subjects with primary BPPV.

## CONCLUSION

Vitamin D insufficiency or deficiency might be a recognized cause of the occurrence and recurrence of BPPV. Many researchers advocate adding vitamin D and calcium supplementation to the standard CRPs in patients with BPPV and low vitamin D serum levels.

## ETHICAL DECLARATIONS

### • Acknowledgements

None.

### • Ethics Approval and Consent to Participate

Not required.

### • Consent for Publication

Not applicable.

### • Availability of Data and Material

No patient data are presented in the study.

### • Competing Interests

The authors declare that there is no conflict of interest.

### • Funding

Self funded.

### • Authors' Contributions

All stated authors contributed significantly, directly, and intellectually to the work and consented it to be published.

## REFERENCES

- [1] Von Brevern M, Radtke A, Lezius F, Feldmann M, Ziese T, Lempert T, et al. Epidemiology of benign paroxysmal positional vertigo: a population based study. *Journal of Neurology, Neurosurgery & Psychiatry* 2007;78(7):710–715. <https://doi.org/10.1136/jnnp.2006.100420>.
- [2] Rhim GI. Serum vitamin D and long-term outcomes of benign paroxysmal positional vertigo. *Clinical and Experimental Otorhinolaryngology* 2019;12(3):273–278. <https://doi.org/10.21053/ceo.2018.00381>.
- [3] Lundberg YW, Zhao X, Yamoah EN. Assembly of the otoconia complex to the macular sensory epithelium of the vestibule. *Brain research* 2006;1091(1):47–57. <https://doi.org/10.1016/j.brainres.2006.02.083>.
- [4] Parnes LS, Agrawal SK, Atlas J. Diagnosis and management of benign paroxysmal positional vertigo (BPPV). *Cmaj* 2003;169(7):681–693.
- [5] Waleem S, Malik SM, Ullah S, ul Hassan Z. Office management of benign paroxysmal positional vertigo with Epley's maneuver. *J Ayub Med Coll Abbottabad* 2008;20:77.
- [6] Sinsamutpadung C, Kulthaveesup A. Comparison of outcomes of the Epley and Semont maneuvers in posterior canal BPPV: A randomized controlled trial. *Laryngoscope Investigative Otolaryngology* 2021;6(4):866–871. <https://doi.org/10.1002%2Flio2.619>.
- [7] Kong TH, Song MH, Shim DB. Recurrence rate and risk factors of recurrence in benign paroxysmal positional vertigo: a single-center long-term prospective study with a large cohort. *Ear and Hearing* 2022;43(1):234–241. <https://doi.org/10.1097/aud.0000000000001093>.
- [8] Zhu CT, Zhao XQ, Ju Y, Wang Y, Chen MM, Cui Y. Clinical characteristics and risk factors for the recurrence of benign paroxysmal positional vertigo. *Frontiers in neurology* 2019;10:1190. <https://doi.org/10.3389%2Ffnneur.2019.01190>.
- [9] Su P, Liu YC, Lin HC. Risk factors for the recurrence of post-semicircular canal benign paroxysmal positional vertigo after canalith repositioning. *Journal of neurology* 2016;263:45–51. <https://doi.org/10.1007/s00415-015-7931-0>.
- [10] Chen J, Zhang S, Cui K, Liu C. Risk factors for benign paroxysmal positional vertigo recurrence: a systematic review and meta-analysis. *Journal of neurology* 2021;268:4117–4127. <https://doi.org/10.1007/s00415-020-10175-0>.
- [11] Maslovara S, Butkovic Soldo S, Sestak A, Milinkovic K, Rogic-Namacinski J, Soldo A. 25 (OH) D3 levels, incidence and recurrence of different clinical forms of benign paroxysmal positional vertigo. *Brazilian journal of otorhinolaryngology* 2018;84:453–459. <https://doi.org/10.1016/j.bjorl.2017.05.007>.
- [12] Kim HJ, Lee JO, Choi JY, Kim JS. Etiologic distribution of dizziness and vertigo in a referral-based dizziness clinic in South Korea. *Journal of the Neurological Sciences* 2021;429. <https://doi.org/10.1007/s00415-020-09831-2>.
- [13] Brandt T, Huppert D, Hecht J, Karch C, Strupp M. Benign paroxysmal positioning vertigo: a long-term follow-up (6–17 years) of 125 patients. *Acta otolaryngologica* 2006;126(2):160–163. <https://doi.org/>

- 10.1080/00016480500280140.
- [14] Nunez RA, Cass SP, Furman JM. Short-and long-term outcomes of canalith repositioning for benign paroxysmal positional vertigo. *Otolaryngology—Head and Neck Surgery* 2000;122(5):647–652. [https://doi.org/10.1016/s0194-5998\(00\)70190-2](https://doi.org/10.1016/s0194-5998(00)70190-2).
- [15] Bazoni JA, Mendes WS, Meneses-Barriviera CL, Melo JJ, Costa VdSP, de Castro Teixeira D, et al. Physical activity in the prevention of benign paroxysmal positional vertigo: probable association. *International archives of otorhinolaryngology* 2014;p. 387–390. <https://doi.org/10.1055/s-0034-1384815>.
- [16] Jeong SH, Kim JS, Shin JW, Kim S, Lee H, Lee AY, et al. Decreased serum vitamin D in idiopathic benign paroxysmal positional vertigo. *Journal of neurology* 2013;260:832–838. <https://doi.org/10.1007/s00415-012-6712-2>.
- [17] You P, Instrum R, Parnes L. Benign paroxysmal positional vertigo. *Laryngoscope investigative otolaryngology* 2019;4(1):116–123. <https://doi.org/10.1002/liao2.230>.
- [18] Kalmanson O, Foster CA. Cupulolithiasis: A Critical Reappraisal. *OTO open* 2023;7(1):e38. <https://doi.org/10.1002/oto2.38>.
- [19] Kim HJ, Park J, Kim JS. Update on benign paroxysmal positional vertigo. *Journal of neurology* 2021;268:1995–2000. <https://doi.org/10.1007/s00415-020-10314-7>.
- [20] Parnes LS, McClure JA. Free-floating endolymph particles: a new operative finding during posterior semicircular canal occlusion. *The Laryngoscope* 1992;102(9):988–992. <https://doi.org/10.1288/00005537-199209000-00006>.
- [21] Elmoursy MM, Abbas AS. The role of low levels of vitamin D as a co-factor in the relapse of benign paroxysmal positional vertigo (BPPV). *American Journal of Otolaryngology* 2021;42(6):103134. <https://doi.org/10.1016/j.amjoto.2021.103134>.
- [22] Bukurov B, Nenezic D, Pot D, Radivojevic N, Ivosevic T, Jotic A. Adoption of clinical practice guidelines in cases of benign paroxysmal positional vertigo. *European Archives of Oto-Rhino-Laryngology* 2023;p. 1–7. <https://doi.org/10.1007/s00405-023-07981-3>.
- [23] Kao WTK, Parnes LS, Chole RA. Otoconia and otolithic membrane fragments within the posterior semicircular canal in benign paroxysmal positional vertigo. *The Laryngoscope* 2017;127(3):709–714. <https://doi.org/10.1002/lary.26115>.
- [24] Büki B, Ecker M, Jünger H, Lundberg YW. Vitamin D deficiency and benign paroxysmal positioning vertigo. *Medical hypotheses* 2013;80(2):201–204. <https://doi.org/10.1016/j.mehy.2012.11.029>.
- [25] Cobb LH, Bailey VO, Liu YF, Teixido MT, Rizk HG. Relationship of vitamin D levels with clinical presentation and recurrence of BPPV in a Southeastern United States institution. *Auris Nasus Larynx* 2023;50(1):70–80. <https://doi.org/10.1016/j.anl.2022.05.011>.
- [26] Jang YS, Hwang CH, Shin JY, Bae WY, Kim LS. Age-related changes on the morphology of the otoconia. *The Laryngoscope* 2006;116(6):996–1001. <https://doi.org/10.1097/01.mlg.0000217238.84401.03>.
- [27] Krieger J, Frackowiak M, Berger M, Heneka MT, Jacobs AH. Falls at advanced age—The importance to search for benign paroxysmal positional vertigo (BPPV). *Experimental gerontology* 2022;165:111868. <https://doi.org/10.1016/j.exger.2022.111868>.
- [28] Al-Rawi TSS, Al-Ani RM. Vitamin D Deficiency and the Risk of Recurrent Benign Paroxysmal Positional Vertigo. *Cureus* 2024;16(1). <https://doi.org/10.7759/cureus.52433>.
- [29] Kim EK, Pasquesi L, Sharon JD. Examining Migraine as a predictor of benign paroxysmal positional vertigo onset, severity, recurrence, and associated falls. *Cureus* 2022;14(8). <https://doi.org/10.7759/cureus.28278>.
- [30] Shih IA, Hsu CY, Li TC, Wang SJ. Benign Paroxysmal Positional Vertigo Is Associated with an Increased Risk for Migraine Diagnosis: A Nationwide Population-Based Cohort Study. *International Journal of Environmental Research and Public Health* 2023;20(4):3563. <https://doi.org/10.3390/ijerph20043563>.
- [31] Casani AP, Gufoni M. Recurring benign paroxysmal positional vertigo after successful canalith repositioning manoeuvres. *Acta Otorhinolaryngologica Italica* 2023;43(2 Suppl 1):S61. <https://doi.org/10.14639/2F0392-100X-suppl.1-43-2023-08>.
- [32] Kutlubaev MA, Xu Y, Hornibrook J. Benign paroxysmal positional vertigo in Meniere’s disease: systematic review and meta-analysis of frequency and clinical characteristics. *Journal of neurology* 2021;268(5):1608–1614. <https://doi.org/10.1007/s00415-019-09502-x>.
- [33] Hanci D, Ulusoy S, Muluk N, Cingi C. Do viral infections have a role in benign paroxysmal positional vertigo. *B-ENT* 2015;11(3):211–218.
- [34] Picciotti PM, Passali GC, Sergi B, De Corso E. Benign paroxysmal positional vertigo (BPPV) in COVID-19. *Audiology research* 2021;11(3):418–422. <https://doi.org/10.3390/2Faudiolres11030039>.



- [35] Yetiser S. Review of the pathology underlying benign paroxysmal positional vertigo. *Journal of International Medical Research* 2020;48(4):0300060519892370. <https://doi.org/10.1177/0300060519892370>.
- [36] Zhou F, Yu B, Luo J, Ma Y, Li J, Zhang T, et al. Global trends in the research on benign paroxysmal positional vertigo: A 20-year bibliometric and visualization analysis. *Frontiers in Neurology* 2022;13:1046257. <https://doi.org/10.3389/fneur.2022.1046257>.
- [37] Talaat HS, Kabel AMH, Khaliel LH, Abuhadied G, El HAERA, Talaat AS, et al. Reduction of recurrence rate of benign paroxysmal positional vertigo by treatment of severe vitamin D deficiency. *Auris Nasus Larynx* 2016;43(3):237–241. <https://doi.org/10.1016/j.anl.2015.08.009>.
- [38] AlGarni MA, Mirza AA, Althobaiti AA, Al-Nemari HH, Bakhsh LS. Association of benign paroxysmal positional vertigo with vitamin D deficiency: a systematic review and meta-analysis. *European Archives of Oto-Rhino-Laryngology* 2018;275:2705–2711. <https://doi.org/10.1007/s00405-018-5146-6>.
- [39] Holick MF, Binkley NC, Bischoff-Ferrari HA, Gordon CM, Hanley DA, Heaney RP, et al. Evaluation, treatment, and prevention of vitamin D deficiency: An endocrine society clinical practice guideline (Journal of Clinical Endocrinology and Metabolism (2011) 96,(1911–1930)). *Journal of Clinical Endocrinology and Metabolism* 2011;96(12). <https://doi.org/10.1210/jc.2011-0385>.
- [40] Jeong S, Choi S, Kim J, Koo J, Kim H, Kim J. Osteopenia and osteoporosis in idiopathic benign positional vertigo. *Neurology* 2009;72(12):1069–1076. <https://doi.org/10.1212/01.wnl.0000345016.33983.e0>.
- [41] Jeong SH, Kim JS, Kim HJ, Choi JY, Koo JW, Choi KD, et al. Prevention of benign paroxysmal positional vertigo with vitamin D supplementation: A randomized trial. *Neurology* 2020;95(9):e1117–e1125. <https://doi.org/10.1212/wnl.0000000000010343>.
- [42] Bigelow RT, Carey JP. Randomized controlled trial in support of vitamin D and calcium supplementation for BPPV. *AAN Enterprises*; 2020. <https://doi.org/10.1212/wnl.0000000000010349>.
- [43] Rhim GI. Serum vitamin D and recurrent benign paroxysmal positional vertigo. *Laryngoscope investigative otolaryngology* 2016;1(6):150–153. <https://doi.org/10.1002%2Flio2.35>.
- [44] Rhim GI. Effect of vitamin D injection in recurrent benign paroxysmal positional vertigo with vitamin D deficiency. *International Archives of Otorhinolaryngology* 2020;24:423–428. <https://doi.org/10.1055/s-0039-3402431>.
- [45] Han WW, Wu YQ, Fan ZY, Yang XY, Guan QF, Yan W, et al. Characteristics of bone metabolism in postmenopausal female patients with different types of idiopathic benign paroxysmal positional vertigo: A single-centre retrospective study. *American Journal of Otolaryngology* 2021;42(6):103149. <https://doi.org/10.1016/j.amjoto.2021.103149>.
- [46] Resuli AS, Bedir A, Özgür A, et al. The relationship between benign paroxysmal positional vertigo and vitamin D. *Cureus* 2022;14(6). <https://doi.org/10.7759/cureus.26068>.
- [47] Sharma K, Ojha T, Dabaria R, Chhabra B, Trivedi BB, Bansal M. Relation between posterior canal benign paroxysmal positional Vertigo and vitamin D Deficiency. *Indian Journal of Otolaryngology and Head & Neck Surgery* 2022;p. 1–4. <https://doi.org/10.1007/s12070-021-03070-1>.
- [48] Libonati GA, Leone A, Martellucci S, Gallo A, Albera R, Lucisano S, et al. Prevention of Recurrent Benign Paroxysmal positional Vertigo: the role of combined supplementation with vitamin D and antioxidants. *Audiology Research* 2022;12(4):445–456. <https://doi.org/10.3390/audiolres12040045>.
- [49] Thomas RJ, Goutham M, Bhat VS, Kamath SD, Aroor R, Bhandary SK. Association of serum calcium and vitamin D with benign paroxysmal positional Vertigo. *International Archives of Otorhinolaryngology* 2022;26:365–369. <https://doi.org/10.1055/s-0041-1724093>.
- [50] Sánchez JM, Leonardo JCH, Niembro JKI, Lesser JC. Therapeutic Effect of the Correction of Vitamin D Deficiency in Patients with Benign Paroxysmal Positional Vertigo—A Randomized Clinical Trial. *International Archives of Otorhinolaryngology* 2023;26:666–670. <https://doi.org/10.1055/s-0041-1730992>.
- [51] Miśkiewicz-Orczyk K, Pluskiewicz W, Kos-Kudła B, Miśiołek M. Assessment of Osteoporosis and Vitamin D3 Deficiency in Patients with Idiopathic Benign Paroxysmal Positional Vertigo (BPPV). *Medicina* 2023;59(5):862. <https://doi.org/10.3390/medicina59050862>.