



Impact of damiana (*Turnera diffusa*) against amitriptyline induced heart injury, dysfunctions and DNA damage in male rats

A.A. Al-Ankoshy¹, E.M. Tousson², S.S. Allam² and A.M. El-Atrash²

¹Department of Human Physiology, Faculty of Medicine, Jabir Ibn Hayyan Medical University, Baghdad, Iraq, ²Zoology Department, Faculty of Science, Tanta University, Tanta, Egypt

Article information

Article history:

Received 20 February, 2023
Accepted 20 November, 2023
Available online 01 January, 2024

Keywords:

Amitriptyline
Antidepressant
Damiana
Heart
Rats

Correspondence:

A.A. Al-Ankoshy
azhar.azher@jmu.edu.jg

Abstract

Amitriptyline (AMT) is a tricyclic antidepressant and an inhibitor of lysosomal acid sphingomyelinase. Amitriptyline has a bad reputation for its cardiovascular complications in psychiatric patients. However, the mechanisms implying the cardiovascular toxicity of amitriptyline are still unknown. This study aimed to clarify damiana's preventive and therapeutic role as adjuvant herbal therapy against amitriptyline-induced heart injury in rats. A total of 36 male albino rats were equally distributed into six groups (1st, control; 2nd, damiana; 3rd, Amitriptyline; 4th, co-treated amitriptyline rats with damiana; 5th, post-treated amitriptyline rats with damiana; 6th, self-healing Amitriptyline rats). A significant elevation in cardiac enzymes (CK-MB, LDH, CKP, and Myoglobin), AST, ALP, sodium ions, cholesterol, triglycerides, LDL, and cardiac DNA damage, injury, and proliferating cell nuclear antigen (PCNA) immunoreactivity in treatment rats with amitriptyline and self-treated group as compared to control and damiana groups. In contrast, potassium ions and HDL revealed a significant depletion in amitriptyline and self-healing Amitriptyline rats' groups as compared to control and damiana groups. Co- and post-treatment of rats with damiana showed a modulation and improvement of cardiac toxicity with a better result in co-treatments than post-treatments. This study suggests using damiana, which is promising in protecting heart structure and functions.

DOI: [10.33899/IJVS.2023.138409.2806](https://doi.org/10.33899/IJVS.2023.138409.2806), ©Authors, 2023, College of Veterinary Medicine, University of Mosul.
This is an open access article under the CC BY 4.0 license (<http://creativecommons.org/licenses/by/4.0/>).

Introduction

Research has suggested that antidepressant use may significantly influence the dysregulation of the autonomic nervous system (ANS) seen in depressed or anxious people (1,2). Psychiatrists administer antidepressant drugs that are used to treat major depressive disorder, anxiety disorders, chronic pain, and addiction (1). Cardiac toxicity is typically included during medication development and risk assessment; tricyclic antidepressants adversely affect all body systems (2,3). Amitriptyline hydrochloride is a tricyclic antidepressant (TCA) and analgesic derived from dibenzocycloheptene. It is also used for migraine prevention, neuropathic pain syndromes, fibromyalgia, bipolar disorder, and nocturnal enuresis (4). Amitriptyline is a serotonin

reuptake inhibitor that blocks histamine-H1 receptors, alpha 1 α 1-adrenergic receptors, and muscarinic receptors, causing sedative, hypotensive, and anticholinergic effects (5,6). Amitriptyline, unfortunately, causes cardiovascular damage in psychiatric patients (7,8). Traditional medicine has been introduced with pharmaceuticals in recent years, based on their usage in combination with other medicines to improve medicinal efficacy, and they have established a solid reputation for effectiveness, causing a boom in the treatment area (9-13). Our study group has recently started investigating *Turnera diffusa*, also known as damiana, a therapeutic herb. Damiana, or *Turnera diffusa* Willd, has a long history of use as herbal aphrodisiac (14,15). *Turnera diffusa* is a member of the Turneraceae family of plants. It is a tiny shrub that grows in the tropical and subtropical regions

of the United States. The Maya used it to treat various ailments (16,17). There are at least 20 compounds in Damiana leaves (1, 8-cineole, P-cymene, - and -pinene, thymol, -copaene, and calamine), as well as tannins, flavonoids, -sitosterol, Damiani, and the glycosides gonzalitosin, arbutin, and tetracyclin B (18). Damiana is safe in both men and animals.

This study aimed to determine the effect of damiana as an adjuvant herbal therapy for amitriptyline-induced cardiac damage in rats.

Materials and methods

Ethical approve

The research's approach was approved by the Institutional Ethical Committee for Animal Care and Use, with a code of Faculty of Science, Tanta University, Egypt (IACUC-SCI-TU-0241).

Experimental animals

36 male albino rats were brought from the National Research Center in Giza, Egypt, at 10-12 weeks and weighing roughly 150 grams. Before the experiment began, the rats were divided into six groups, each with six rats. Rats remained in the animal house of our faculty for one week before starting the experiment. They were kept on a standard rodent diet and water *ad libitum*, normal temperature conditions (23±2°C) in a 12h light/dark cycle, and a minimum relative humidity of 40%.

Damiana's aqueous extract production

Damiana dried leaves from a neighbourhood market of clinical plants in Egypt were shacked to powder and soaked in boiled water for 24 hours at 37°C, then extracted and stored at -30°C in the dark until used (15,19).

Experimental groups

Group 1 control group (animals not given any drug). Group 2 damiana group (80 mg damiana/kg body weight/daily/ orally via a stomach tube) for four weeks (17). Group 3 amitriptyline (Tryptizol; El Kahira Pharm and Chem Ind Co) group (70 mg amitriptyline/kg body weight/daily/intraperitoneally injected) for four weeks (17). Group 4 co-treated group (70 mg amitriptyline/kg body weight/daily/intraperitoneally injected) + (80 mg damiana/kg body weight/daily/orally) for four weeks. Group 5 post-treated Co-treated group (70 mg amitriptyline/kg body weight/daily /intraperitoneally injected) for four weeks followed by (80 mg damiana/kg body weight/daily/orally) for another four weeks. Group 6 self-treated group (70 mg amitriptyline/kg body weight/daily/intraperitoneally injected) for four weeks and left for self-recovery without any drugs for successive 4 weeks.

At the end of the experimental period, rats were fasted overnight. Rats from each group were euthanized with

intraperitoneal sodium pentobarbital (30 mg/kg; Danish company Lundbeck) for complete dissection.

Blood and serum samples

Blood was collected from the inferior vena cava and separated by centrifugation at 3000 rpm for 15 minutes. The collected serum was stored at -18°C until analysis to estimate blood parameters.

Cardiac function biomarkers

Serum lactate dehydrogenase (LDH) activity was estimated by a kinetic method described by Zilva and Pannall (20). In contrast, creatine kinase (CPK) levels in sera were determined via an akinetic method as described by Alotaibi *et al.* (21). Creatine kinase myoglobin (CK-MB) and myoglobin levels in sera were estimated as described by Elgharabawy *et al.* (22). Serum aspartate aminotransferase (AST) and alkaline phosphatase (ALP) activities were detected using a colorimetric method according to Moustafa *et al.* (23) and Saggi *et al.* (24), respectively. Serum of Total protein levels according to Tousson *et al.* (25).

Electrolyte estimation

The electrolyte levels as potassium ions and sodium ions were detected according to Abd Eldaim *et al.* (26) by using profitable kits from India known as Sensa core for electrolytes.

Lipid profile estimation

Complete lipid profiles [triglyceride, cholesterol, high-density lipoprotein-cholesterol (HDL-C), and low-density lipoprotein-cholesterol (LDL-C)] in sera were detected according to Aldubayan *et al.* (27) and Salama *et al.* (28) by using kits from ELLTECH.

Comet assay

The comet assay (single-cell gel electrophoresis) technique was used to analyze and quantify DNA damage in the cardiac tissues according to the approach derived from Abd Eldaim *et al.* (29).

Histopathological examination

Cardiac tissue samples were fixed with 10% formalin (natural buffer) solution for 48 hours and then processed for paraffin sectioning, stained with hematoxylin and eosin (H and E) for histopathological investigation, according to Tousson (30).

Immunohistochemical detection of proliferating cell nuclear antigen (PCNA)

The detection of PCNA expressions was assayed according to Tousson *et al.* (31) using the avidin-biotin complex method. The stained cells were quantitated by color thresholding using the Image -J- program.

Statistical analysis

The data was presented as means and SEM. Using one-way ANOVA, data were compared between the Amitriptyline and the other five groups. When $P \leq 0.05$, the P value became significant. Analysis was conducted utilizing (Graphpad Prism, Graphpad Software, Inc., La Jolla, CA, USA).

Results

Changes in cardiac enzymes

Table 1 revealed that amitriptyline (AMT) induced significant elevation in CK-MB, myoglobin, CPK, LDH, AST, and ALP levels compared to control. In contrast, there was a substantial decrease in CK-MB, myoglobin, CPK, LDH, AST, and ALP in co-treated (DE+AMT) and post-treated (AMT+DE) groups. Low significance improvement appeared in the treated group (ST AMT) as compared to co-treated (DE+AMT) and post-treated (AMT+DE) groups.

Changes in lipid profile

Table 2 revealed a significant elevation in cholesterol, triglycerides, LDL, and HDL depletion in intoxicated rats by amitriptyline (AMT) compared with control. On the other hand, there was a significant deficit in cholesterol,

triglycerides, LDL, and a significant elevation in HDL in co-treated (DE+AMT) and post-treated (AMT+DE) groups when compared with AMT and ST AMT.

Changes in serum electrolytes

Table 3 revealed that serum sodium ions are significantly elevated with a significant decrease in the levels of potassium ions in intoxicated rats by amitriptyline (AMT and ST AMT) when compared with Control. On the other hand, there was a significant decrease in the levels of sodium ions with a substantial increase in potassium ions in co-treated (DE+AMT) and post-treated (AMT+DE) groups when compared with AMT and ST AMT.

Comet assay results

Intoxicated (AMT+ST AMT) groups exhibited a significant increase in DNA damage ($P < 0.05$) that was indicated by an increase in tail length, tail DNA%, and tail moment as compared to control and Damiana (DE) groups. Co-treated (DE+AMT) and post-treated (AMT+DE) groups revealed a significant decrease in this elevated DNA damage, with the best results in the co-treated (DE+AMT) group (Table 4 and Figure 1). On the other hand, no significant difference in DNA damage (tail length) was observed between control and Damiana.

Table 1: Variations in AST (U/I), ALP (U/I), CPK (U/I), CK-MB (ng/ml), Myoglobin (ng/ml), and LDH (U/I)

Groups	Control	DE	AMT	DE+AMT	AMT+DE	ST AMT
CK-MB	0.138 [#] ±0.001	0.133 [#] ±0.001	0.29*±0.004	0.25* [#] ±0.003	0.274* [#] ±0.004	0.297*±0.004
CPK	3517 [#] ±75.08	3323 [#] ±29.61	5174*±186.7	3745 [#] ±47.7	3690 [#] ±49.26	4167*±93.44
LDH	172.8 [#] ±13.75	154.4 [#] ±4.844	565.8*±24.9	337.2* [#] ±6.84	362.8* [#] ±2.557	601.6*±5.537
Myoglobin	13.88 [#] ±0.259	13.82 [#] ±0.12	17.78*±0.13	14.28* [#] ±0.16	14.52* [#] ±0.07	17.16*±0.108
AST	154.6 [#] ±4.37	141.4 [#] ±2.50	281.4*±5.11	229* [#] ±4.147	246* [#] ±3.033	260.6*±4.389
ALP	147.2 [#] ±3.023	140.0 [#] ±0.447	193.0*±4.63	14* [#] ±3.444	196* [#] ±3.564	175.4* [#] ±2.112

Data were expressed as mean±SE of 6 observations. *: Significant difference from the control group at $P < 0.05$, #: Significant difference from the AMT group at $P < 0.05$.

Table 2: Variations in the levels of cholesterol (mg/dl), Triglycerides (mg/dl), HDL (mg/dl), and LDL (mg/dl)

Groups	Control	DE	AMT	DE+AMT	AMT+DE	ST AMT
Cholesterol	93.2 [#] ±1.772	88.4 [#] ±1.249	178.0*±5.376	127.4* [#] ±2.94	143.0* [#] ±3.56	160.6*±2.25
Triglycerides	110.4 [#] ±1.63	100.0 [#] ±2.236	191.2*±4.91	121.2* [#] ±2.64	121.6* [#] ±2.29	130.4* [#] ±3.34
HDL	14.2 [#] ±0.37	14.6 [#] ±0.6	19.6*±0.6	16.1* [#] ±0.447	18.8* [#] ±0.374	22.0*±0.5477
LDL	54.92 [#] ±1.88	53.8 [#] ±1.89	127.0*±4.12	86.76* [#] ±2.91	99.88* [#] ±2.960	112.5*±3.339

Data were expressed as mean±SE of 6 observations. *: Significant difference from the control group at $P < 0.05$, #: Significant difference from the AMT group at $P < 0.05$.

Table 3: Variations in sodium ions (mEq/l) and potassium ions (mEq/l)

Groups	Control	DE	AMT	DE+AMT	AMT+DE	ST AMT
Na ⁺	139.3 [#] ±0.26	138.1 [#] ±0.267	152.3*±2.29	139.4 [#] ±0.553	141.2 [#] ±0.414	160.5*±2.275
K ⁺	5.054 [#] ±0.021	4.954±0.066	4.13*±0.036	5.462 [#] ±0.517	5.006 [#] ±0.03	4.616* [#] ±0.04

Data were expressed as mean±SE of 6 observations. *: Significant difference from the control group at $P < 0.05$, #: Significant difference from the AMT group at $P < 0.05$.

Table 4: Comet assay parameters obtained by image analysis in cells of all groups after the treatment experiment

Group	Tailed (%)	Untailed (%)	Tails length (µm)	Tail DNA (%)	Tail moment
Control	2	98	1.45 [#] ±0.12	1.54	2.23
DE	2	98	1.43 [#] ±0.15	1.55	2.22
AMT	29	71	9.42 [*] ±0.68	8.11	76.40
DE+AMT	9.5	90.5	3.56 [#] ±0.47	2.56	9.11
AMT+DE	10	90	3.86 [#] ±0.25	2.69	10.38
ST AMT	18.5	81.5	6.02 ^{#*} ±0.34	4.90	29.50

Significant difference from the control group (G1) at *P<0.05. Significant difference from amitriptyline group (G3) at #P<0.05.




Figure 1: Photomicrograph representation of DNA damage in the heart, using the comet assay. G1, control group; G2, Damiana group; G3, Amitriptyline group; G4, co- treated group; G5, post-treated group; G6, self-treated groups.

Histopathology results

Heart sections in control and damiana groups showed single, oval, and centrally located nuclei of cardiac myocytes with regularly arranged cardiac myofibres (Figures 2A and B). Heart sections in the Amitriptyline group revealed severe tissue injury with marked myocardial hypertrophy, cytoplasmic vacuoles, and collections of nuclei that showed deformation in sizes and shapes (Figure 2C). Heart sections in co-treated amitriptyline combined with the damiana group (G4) revealed moderate damage and clear improvement of all changes in the form of nucleus and cardiac muscle tissue (Figure 2D). Also, the heart sections post-treated with amitriptyline with the damiana group (G5) revealed mild to

moderate damage and mild myocardial hypertrophy, a few myofibrillar structures with striations, branched appearance and continuity with adjacent myofibrils, nuclear pyknosis and mild cytoplasmic vacuoles (Figure 2E). Heart sections in the self-treated Amitriptyline (G6) group revealed strong injury with revealed hydrophobic changes of myofibrillar structure with striations, marked myocardial hypertrophy, nuclear pyknosis, moderate cytoplasmic vacuoles (Figure 2F).

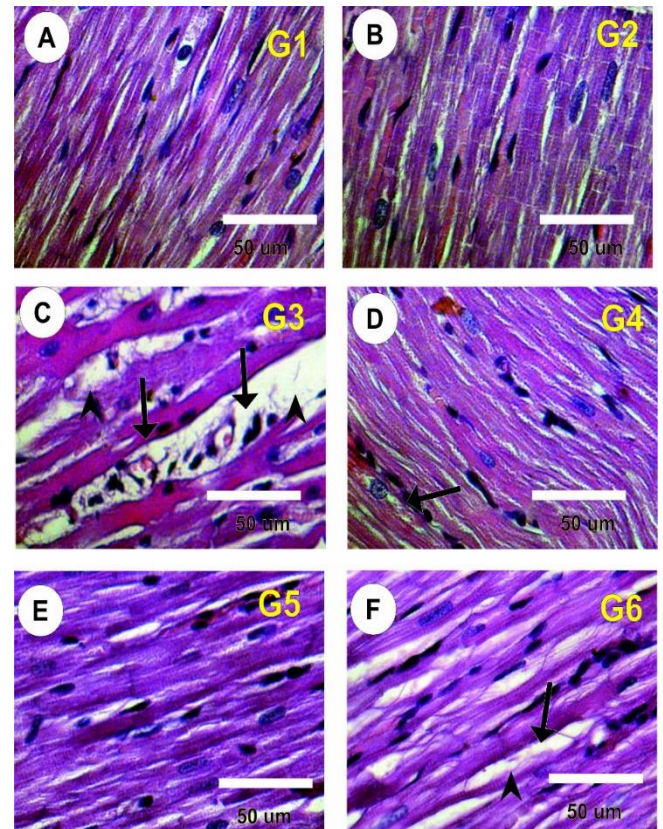


Figure 2: Photomicrographs of rat heart sections in the different groups stained with Haematoxylin and eosin. A and B: Heart sections in control (G1) group and damiana (G2) group showed normal, oval, and centrally located nuclei of cardiac myocytes with regularly arranged cardiac myofibres. D: Heart sections of the Amitriptyline group (G3) revealed

marked hypertrophy, vacuolation, deformation in sizes and shapes of the nucleus, and disturbance of cardiac myofibers (black arrows). F: Heart sections in co-treated Amitriptyline with Damiana group (G4) showed moderate regular distribution in nuclei of cardiac myocytes (black arrows). G: Heart sections in post-treated Amitriptyline with Damiana group (G5) showed moderate myofibers and nucleus. H: heart sections in the self-treated Amitriptyline group (G6) revealed marked hypertrophy.

PCNA expression changes in the heart

Heart sections in control (G1) damiana (G2) groups showed moderate positive reactions for PCNA expressions in cardiac nuclei (Figures 3A and B). Heart sections in the Amitriptyline-treated rat group (G3) showed vital positive responses for PCNA expressions in the cardiac seats (Figure 3C). On the other hand, heart sections in co-treated and post-treated Amitriptyline with the damiana group (G4 and G5) revealed mild to moderate reaction for PCNA expressions (Figures 3D and 3E). Heart sections in the self-treated Amitriptyline-treated rat group (G6) showed a moderate positive reaction for PCNA expressions in the cardiac nuclei (Figure 3F).

Discussion

Amitriptyline is widely prescribed for depressed patients and other mental illnesses. The mechanism of the myocardial cell damage associated with amitriptyline treatment is uncertain. Damiana is a heart muscle tonic in traditional medicine and has proven to have potential therapeutic properties on cardiac toxicity (32). However, little is known about herbal plants as protective agents against the cardiac toxicity caused by Amitriptyline. This study was designed to study the impact of Damiana (*Turnera diffusa*) on Amitriptyline-induced cardiac dysfunctions in rats. Current results revealed that treated rats with Amitriptyline induced a significant elevation in the cardiac markers (CK, CK-Mb, LDH, and myoglobin) and cardiac enzymes (AST and ALP) levels by comparison to the control group, in contrast, a significant depletion in cardiac markers and enzymes after Co- or post-treatment of Amitriptyline with Damiana as compared to Amitriptyline group. Our results agree with Acosta and Ramos (33), who revealed that amitriptyline induced severe abnormalities of the sarcolemmal integrity using LDH release of cultured myocardial cells. In addition, these results were by Boles *et al.* (34) and Sorodoc *et al.* (35), who reported that Amitriptyline induced elevation in cardiac enzymes, Mattila and Saarnivaara (36), who reported that rabbits injected with amitriptyline showed myocardial dysfunction and death. Likewise, Kaur *et al.* (37) showed that Amitriptyline may be responsible for cardiac dysfunction. Also, Tsujikawa *et al.* (38) reported that antidepressant drugs (TCAs) are a major cause of fatal drug poisoning due to their cardiotoxicity.

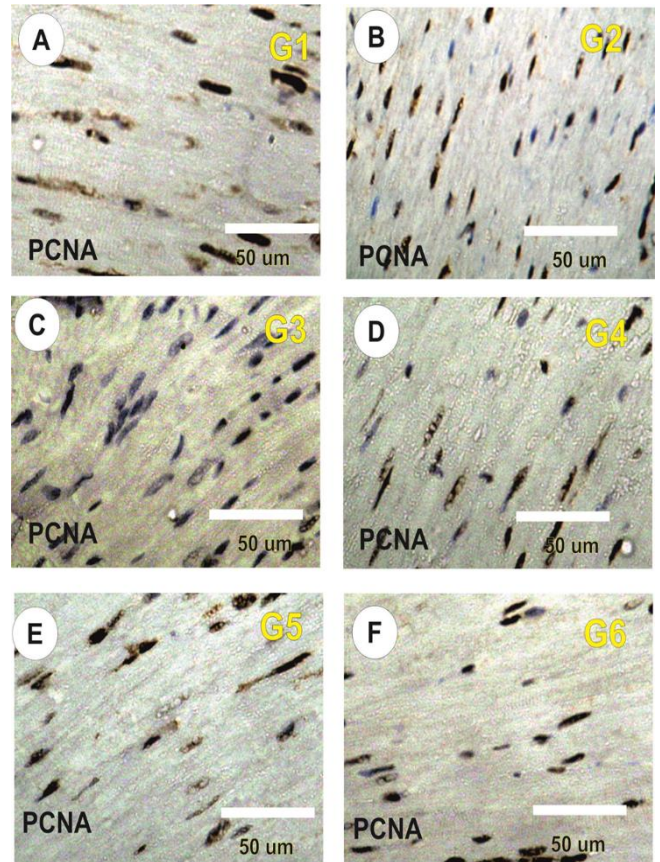


Figure 3: Photomicrograph of rat heart sections is stained with PCNA expression in different groups. A and B: Moderate positive reaction for PCNA expressions in control (G1) and Damiana (G2) groups. C: Strong positive reaction for PCNA expressions in Amitriptyline-treated rat group (G3). D and E: Mild to moderate reaction for PCNA expressions heart sections in co-treated and post-treated Amitriptyline with Damiana group (G4, G6). F: Mild positive reaction for PCNA expressions in self-treated Amitriptyline rat group (G6) group.

The existing drug appears to affect the heart muscle due to changes in the level of cholesterol and triglycerides (13,39). The current study showed a significant decrease in cholesterol, triglycerides, and LDL and increased HDL levels in the amitriptyline group. In contrast, a significant increase in cholesterol, triglycerides, LDL and a significant decrease in HDL was shown after Co- or post-treatment of amitriptyline with Damiana. These results were consistent with Kopf *et al.* (40) and Eker *et al.* (41), who reported that antidepressant treatment significantly increased lipid profiles.

Electrolytes such as sodium, potassium, magnesium, and calcium are involved in heart contraction and relaxation. Significant changes are observed in Na and K ions in the amitriptyline group compared to the control. On the other

hand, rats treated with damiana showed substantial improvement in the level of Na and K ions compared to the amitriptyline group.

Current histopathological results revealed that the cardiac tissue in treated rats with amitriptyline revealed severe tissue injury with marked myocardial hypertrophy and DNA damage with strong positive PCNA expression, indicating the myocardial injury and deformation of nuclei of cardiomyocytes and disarrangement or disordered cardiac myofibres. Treatment of amitriptyline with damiana showed significant improvement in cardiac tissues compared to the amitriptyline group. The current result was by Tousson *et al.* (17), who reported that amitriptyline induced testicular injury and DNA damage, and the treatment with damiana modulates the alterations in testicular functions and structure.

The current result was by Sorodoc *et al.* (35), who concluded in their study that the use of a high dose of amitriptyline led to diffuse myocardial alterations such as dilated capillaries, hemorrhagic areas with variable sizes and, in over 30% of the treated animals, few small foci of acute myocardial necrosis characterized by pyknosis or karyolysis. Marti *et al.* (42) demonstrated that long-term amitriptyline treatment induced myocardial cell damage in patients.

Current results agree with Cohen *et al.* (43), who have an association between tricyclic antidepressants and an increased risk of myocardial infarction. Furthermore, the increase of cardiac enzymes, AST, ALP, and AST values with increased lipid profile levels, heart damage indicators, and histopathological and PCNA immunoreactivity alterations supported this conclusion, and the treatment with damiana improved cardiac functions and structure.

Conclusion

Heart diseases in psychiatric patients that use amitriptyline are life-threatening. So, it is essential to assess the cardiac health status of the patient, and control the complication of amitriptyline on the heart using an herbal substance that enhances its action without any side effects. This study suggests amitriptyline-induced cardiac toxicity and uses damiana, promising in protecting heart functions and structure against antidepressants such as amitriptyline.

Acknowledgment

Thanks to Professor Dr. Tousson Ehab Lab's help in biochemical analysis.

Conflicting interests

The author(s) declared no potential conflicts of interest concerning this article's research, authorship, and publication.

References

1. Licht CM, de Geus EJ, van Dyck R, Penninx BW. Longitudinal evidence for unfavorable effects of antidepressants on heart rate variability. *Biol Psychiatry*. 2010;68(9):861-8. DOI: [10.1016/j.biopsych.2010.06.032](https://doi.org/10.1016/j.biopsych.2010.06.032)
2. O'Regan C, Kenny RA, Cronin H, Finucane C, Kearney PM. Antidepressants strongly influence the relationship between depression and heart rate variability: Findings from the Irish longitudinal study on ageing (TILDA). *Psychol Med*. 2015;45(3):623-36. DOI: [10.1017/S0033291714001767](https://doi.org/10.1017/S0033291714001767)
3. El Atrash A, Tousson E, Gad A, Allam S. Hematological and biochemical changes caused by antidepressants amitriptyline induced cardiac toxicity in male rats. *Asian J Cardiol Res*. 2019;23:1-6. [\[available at\]](#)
4. Coluzzi F, Mattia C. Mechanism-based treatment in chronic neuropathic pain: The role of antidepressants. *Curr Pharm Design*. 2005;11(23):2945-60. DOI: [10.2174/1381612054864993](https://doi.org/10.2174/1381612054864993)
5. Gupta MA, Gupta AK. The use of antidepressant drugs in dermatology. *J Eur Acad Dermatol Venereol*. 2001;15(6):512-8. DOI: [10.1046/j.1468-3083.2001.00278.x](https://doi.org/10.1046/j.1468-3083.2001.00278.x)
6. Pariante CM. Why are depressed patients inflamed? A reflection on 20 years of research on depression, glucocorticoid resistance and inflammation. *Eur Neuropsychopharmacol*. 2017;27(6):554-559. DOI: [10.1016/j.euroneuro.2017.04.001](https://doi.org/10.1016/j.euroneuro.2017.04.001)
7. Smith EL, Schuchman EH. The unexpected role of acid sphingomyelinase in cell death and the pathophysiology of common diseases. *FASEB J*. 2008;22(10):3419-3431. DOI: [10.1096/fj.08-108043](https://doi.org/10.1096/fj.08-108043)
8. Hasan AF, Mutar TF, Tousson EM, Felemban SG. Therapeutic effects of *Turnera diffusa* extract against amitriptyline-induced toxic hepatic inflammation. *J Biol Sci*. 2021;21(2):395-408. DOI: [10.1016/j.matpr.2021.07.409](https://doi.org/10.1016/j.matpr.2021.07.409)
9. Elbandrawy MM, Sweef O, Elgamel D, Mohamed TM, Elgharabawy RM. Ellagic acid regulates hyperglycemic state through modulation of pancreatic IL-6 and TNF- α immunoreactivity. *Saudi J Biol Sci*. 2022;29(5):3871-80. DOI: [10.1016/j.sjbs.2022.03.016](https://doi.org/10.1016/j.sjbs.2022.03.016)
10. Mohamed AE, El-Magd MA, El-Said KS, El-Sharnouby M, Tousson EM, Salama AF. Potential therapeutic effect of thymoquinone and/or bee pollen on fluvastatin-induced hepatitis in rats. *Sci Rep*. 2021;11(1):1-2. DOI: [10.1038/s41598-021-95342-7](https://doi.org/10.1038/s41598-021-95342-7)
11. El-Masry T, Al-Shaalan N, Tousson E, Buabeid M, Al-Ghadeer A. Potential therapy of vitamin B17 against Ehrlich solid tumor induced changes in Interferon gamma, nuclear factor kappa B, DNA fragmentation, p53, Bcl2, survivin, VEGF and TNF- α expressions in mice. *Pak J Pharm Sci*. 2020;33(1):393-401. DOI: [10.36721/PJPS.2020.33.1.SUP.393-401.1](https://doi.org/10.36721/PJPS.2020.33.1.SUP.393-401.1)
12. El-Masry TA, Altwaijry N, Alotaibi B, Tousson E, Albohgdady A, Saleh A. Chicory (*Cichorium intybus* L.) extract ameliorates hydroxyapatite nanoparticles induced kidney damage in rats. *Pak J Pharm Sci*. 2020;33(3):1251-60. DOI: [10.36721/PJPS](https://doi.org/10.36721/PJPS)
13. Alotaibi B, Tousson E, El-Masry TA, Altwaijry N, Saleh A. Ehrlich ascites carcinoma as model for studying the cardiac protective effects of curcumin nanoparticles against cardiac damage in female mice. *Environ Toxicol*. 2021;36(1):105-13. DOI: [10.1002/tox.23016](https://doi.org/10.1002/tox.23016)
14. Baez-Parra KM, Alcaraz-Melendez L, Santamaria-Miranda A, Heredia JB, Leon-Felix J, Muy-Rangel MD, Angulo-Escalante MA. Leaf morphology and anatomy of varieties of *Turnera diffusa* var. *diffusa* and *Turnera diffusa* var. *aphrodisiaca* (Ward) Urb. *Afr J Tradit Complement Altern Med*. 2018;15(1):110-6. DOI: [10.21010/ajtcam.v15.1.11](https://doi.org/10.21010/ajtcam.v15.1.11)
15. Hasan AF, Hameed HM, Tousson E, Massoud A, Atta F, Youssef H. Role of oral supplementation of damiana (*Turnera diffusa*) reduces the renal toxicity, apoptosis and DNA damage associated with amitriptyline administration in rats. *Biomed Pharmacol J*. 2022;15(3):1245-53. DOI: [10.13005/bpj/2460](https://doi.org/10.13005/bpj/2460)

16. Zhao J, Dasmahapatra AK, Khan SI, Khan IA. Anti-aromatase activity of the constituents from damiana (*Turnera diffusa*). J Ethnopharmacol. 2008;120(3):387-93. DOI: [10.1016/j.jep.2008.09.016](https://doi.org/10.1016/j.jep.2008.09.016)
17. Tousson E, Hafez E, Zaki S, Gad A, Elgharabawy RM. Evaluation of the testicular protection conferred by damiana (*Turnera diffusa* Willd.) against amitriptyline-induced testicular toxicity, DNA damage and apoptosis in rats. Biomed Pharmacother. 2020;132:110819. DOI: [10.1016/j.biopha.2020.110819](https://doi.org/10.1016/j.biopha.2020.110819)
18. Başer KC, Mondello L. Introduction to your guide to the ISEO conference. J Essent Oil Res. 2011;23(1):1-234. DOI: [10.1080/10412905.2004.9700489](https://doi.org/10.1080/10412905.2004.9700489)
19. LaLone CA, Hammer KD, Wu L, Bae J, Leyva N, Liu Y, Solco AK, Kraus GA, Murphy PA, Wurtele ES, Kim OK. Echinacea species and alkalimides inhibit prostaglandin E2 production in RAW264. 7 mouse macrophage cells. J Agric Food Chem. 2007;55(18):7314-22. DOI: [10.1021/jf063711a](https://doi.org/10.1021/jf063711a)
20. Zilva JF, Pannall PR, Mayne PD. Clinical chemistry in diagnosis and treatment. USA: Year Book Medical Pub; 1988.
21. Alotaibi B, El-Masry TA, Tousson E, Alarfaj SJ, Saleh A. Therapeutic effect of rocket seeds (*Eruca sativa* L.) against hydroxyapatite nanoparticles injection induced cardiac toxicity in rats. Pak J Pharm Sci. 2020;33(4):1839-1845. [\[available at\]](#)
22. Elgharabawy RM, El Sayed IE, Rezk NA, Tousson E. Therapeutic impact of costus (*Saussurea lappa*) against ehrlich solid tumor-induced cardiac toxicity and DNA damage in female mice. Front Pharmacol. 2021;12. DOI: [10.3389/fphar.2021.708785](https://doi.org/10.3389/fphar.2021.708785)
23. Moustafa AH, Ali EM, Moselhey SS, Tousson E, El-Said KS. Effect of coriander on thioacetamide-induced hepatotoxicity in rats. Toxicol Indust Health. 2014;30(7):621-9. DOI: [10.1177/0748233712462470](https://doi.org/10.1177/0748233712462470)
24. Saggu S, Sakeran MI, Zidan N, Tousson E, Mohan A, Rehman H. Ameliorating effect of chicory (*Chichorium intybus* L.) fruit extract against 4-tert-octylphenol induced liver injury and oxidative stress in male rats. Food Chem Toxicol. 2014;72:138-146. DOI: [10.1016/j.fct.2014.06.029](https://doi.org/10.1016/j.fct.2014.06.029)
25. Tousson E, El-Moghazy M, Massoud A, El-Atrash A, Sweef O, Akel A. Physiological and biochemical changes after boldenone injection in adult rabbits. Toxicol Ind Health. 2016;32(1):177-82. DOI: [10.1177/0748233713501365](https://doi.org/10.1177/0748233713501365)
26. Abd Eldaim MA, Tousson E, El Sayed IE, Awd WM. Ameliorative effects of *Saussurea lappa* root aqueous extract against Ethephon-induced reproductive toxicity in male rats. Environ Toxicol. 2019;34(2):150-9. DOI: [10.1002/tox.22669](https://doi.org/10.1002/tox.22669)
27. Aldubayan MA, Elgharabawy RM, Ahmed AS, Tousson E. Antineoplastic activity and curative role of avenanthramides against the growth of Ehrlich solid tumors in mice. Oxid Med Cell Longev. 2019;2019:12. DOI: [10.1155/2019/5162687](https://doi.org/10.1155/2019/5162687)
28. Salama AF, Tousson E, Shalaby KA, Hussien HT. Protective effect of curcumin on chloroform as by-product of water chlorination induced cardiotoxicity. Biomed Prev Nutr. 2014;4(2):225-30. DOI: [10.1016/j.bionut.2014.02.004](https://doi.org/10.1016/j.bionut.2014.02.004)
29. Abd Eldaim MA, Tousson E, Soliman MM, El Sayed IE, Abdel Aleem AA, Elsharkawy HN. Grape seed extract ameliorated Ehrlich solid tumor-induced hepatic tissue and DNA damage with reduction of PCNA and P53 protein expression in mice. Environ Sci Poll Res. 2021;28:44226-38. DOI: [10.1007/s11356-021-13904-8](https://doi.org/10.1007/s11356-021-13904-8)
30. Tousson E. Histopathological alterations after a growth promoter boldenone injection in rabbits. Toxicol Ind Health. 2016;32(2):299-305. DOI: [10.1177/0748233713500821](https://doi.org/10.1177/0748233713500821)
31. Tousson E, Ali EM, Ibrahim W, Mansour MA. Proliferating cell nuclear antigen as a molecular biomarker for spermatogenesis in PTU-induced hypothyroidism of rats. Reprod Sci. 2011;18(7):679-86. DOI: [10.1177/1933719110395401](https://doi.org/10.1177/1933719110395401)
32. Johnson L, Strich H, Taylor A, Timmermann B, Malone D, Teufel-Shone N, Drummond R, Woosley R, Pereira E, Martinez A. Use of herbal remedies by diabetic Hispanic women in the southwestern United States. Phytother Res. 2006;20(4):250-255. DOI: [10.1002/ptr.1820](https://doi.org/10.1002/ptr.1820)
33. Acosta D, Ramos K. Cardiotoxicity of tricyclic antidepressants in primary cultures of rat myocardial cells. J Toxicol Environ Health. 1984;14(2-3):137-143. DOI: [10.1080/15287398409530568](https://doi.org/10.1080/15287398409530568)
34. Boles RG, Lovett-Barr MR, Preston A, Li BU, Adams K. Treatment of cyclic vomiting syndrome with co-enzyme Q10 and amitriptyline, a retrospective study. BMC Neurol. 2010;10:1-5. DOI: [10.1186/1471-2377-10-10](https://doi.org/10.1186/1471-2377-10-10)
35. Sorodoc V, Sorodoc L, Ungureanu D, Sava A, Jaba IM. Cardiac troponin T and NT-proBNP as biomarkers of early myocardial damage in amitriptyline-induced cardiovascular toxicity in rats. Int J Toxicol. 2013;32(5):351-357. DOI: [10.1177/1091581813503888](https://doi.org/10.1177/1091581813503888)
36. Mattila MJ, Saarnivaara L. Amitriptyline toxicity. Lancet. 1970;296(7683):1138-9. DOI: [10.1016/S0140-6736\(70\)92339-1](https://doi.org/10.1016/S0140-6736(70)92339-1)
37. Kaur H, Hota D, Bhansali A, Dutta P, Bansal D, Chakrabarti A. A comparative evaluation of amitriptyline and duloxetine in painful diabetic neuropathy: A randomized, double-blind, cross-over clinical trial. Diabetes Care. 2011;34(4):818-822. DOI: [10.2337/dc10-1793](https://doi.org/10.2337/dc10-1793)
38. Tsujikawa S, Matsuura T, Hori K, Mori T, Kuno M, Nishikawa K. Superior efficacy of lipid emulsion infusion over serum alkalization in reversing amitriptyline-induced cardiotoxicity in Guinea Pig. Anesth Analg. 2018;126(4):1159-1169. DOI: [10.1213/ANE.0000000000002707](https://doi.org/10.1213/ANE.0000000000002707)
39. Massoud AA, El-Atrash A, Tousson E, Ibrahim W, Abou-Harga H. Light and ultrastructural study in the propylthiouracil-induced hypothyroid rat heart ventricles and the ameliorating role of folic acid. Toxicol Ind Health. 2012;28(3):262-70. DOI: [10.1177/0748233711410915](https://doi.org/10.1177/0748233711410915)
40. Kopf D, Westphal S, Luley CW, Ritter S, Gilles M, Weber-Hamann B, Lederbogen F, Lehnert H, Henn FA, Heuser I, Deuschle M. Lipid metabolism and insulin resistance in depressed patients: Significance of weight, hypercortisolism, and antidepressant treatment. J Clin Psychopharmacol. 2004;24(5):527-531. DOI: [10.1097/01.jcp.0000138762.23482.63](https://doi.org/10.1097/01.jcp.0000138762.23482.63)
41. Eker ÖO, Özsoy S, Baki EK, Doğan H. Metabolic effects of antidepressant treatment. Arch Neuropsychiatry. 2017;54(1):49. DOI: [10.5152/npa.2016.12373](https://doi.org/10.5152/npa.2016.12373)
42. Martí V, Ballester M, Udina C, Carrió I, Alvarez E, Obrador D, Pons-Lladó G. Evaluation of myocardial cell damage by In-111-monooclonal antimyosin antibodies in patients under chronic tricyclic antidepressant drug treatment. Circulation. 1995;91(6):1619-23. DOI: [10.1161/01.CIR.91.6.1619](https://doi.org/10.1161/01.CIR.91.6.1619)
43. Cohen HW, Gibson G, Alderman MH. Excess risk of myocardial infarction in patients treated with antidepressant medications: Association with use of tricyclic agents. Am J Med. 2000;108(1):2-8. DOI: [10.1016/S0002-9343\(99\)00301-0](https://doi.org/10.1016/S0002-9343(99)00301-0)

بالأميتريبتيلين، والمجموعة الرابعة هي مجموعة الجرذان التي عوملت بنفس الوقت بكل من الأميتريبتيلين والدميانا والمجموعة الخامسة هي المجموعة المعاملة بالأميتريبتيلين ثم عولجت بعد ذلك بواسطة الدميانا والمجموعة الأخيرة كانت مجموعة الجرذان المعاملة بالأميتريبتيلين ذاتية الشفاء. أظهرت النتائج ارتفاع كبير في وظائف القلب، وإنزيمات القلب ناقلة امين الالنين وناقلة امين الاسبارتيت، وأيونات الصوديوم، والكوليسترول والدهون الثلاثية، والبروتينات الدهنية واطنة الكثافة والحمض النووي القلبي، والتفاعل المناعي PCNA كذلك انخفاض في أيونات البوتاسيوم والبروتينات الدهنية عالية الكثافة في الجرذان المعالجة بالأميتريبتيلين ومجموعة الجرذان المعاملة بالأميتريبتيلين ذاتية الشفاء مقارنة بمجموعات الضابطة والدميانا. كما أظهر العلاج المشترك واللاحق (المجموعة الرابعة والخامسة) تعديل وتحسين أنزيمات ووظائف القلب مع أفضل نتيجة في العلاجات المشتركة (المجموعة الرابعة) مقارنة بالمعاملات اللاحقة (المجموعة الخامسة). ونستخلص من ذلك أن الأميتريبتيلين له تأثير سلبي على القلب وعلى مرضى القلب الذين يعانون من أمراض نفسية قد تهدد الحياة. لذلك، من المهم تقييم الحالة الصحية للقلب للمريض. والتحكم في مضاعفات الأميتريبتيلين على القلب، وذلك باستخدام مستخلص أوراق نبات الدميانا لتعزيز أي آثار جانبية. تقترح هذه الدراسة استخدام الدميانا التي تمثل نتيجة واعدة في حماية أنسجة القلب والإنزيمات.

تأثير الداميانا على سمية وتلف الحمض النووي للقلب التي يسببها الأميتريبتيلين في ذكور الجرذان

أزهار أزهر العنكوشي¹، ايهاب مصطفى طوسون²، سهر سامي علام² و عفاف مختار الأطرش²

¹ فرع فسلجة الإنسان، كلية الطب، جامعة جابر بن حيان الطبية، بغداد، العراق، ² قسم علم الحيوان، كلية العلوم، جامعة طنطا، طنطا، مصر

الخلاصة

أميتريبتيلين هو مضاد للاكتئاب ثلاثي الحلقات ومثبط للحمض الليكوزومي سفينجوميليناز. يتمتع أميتريبتيلين بسمعة سيئة بسبب مضاعفاته القلبية الوعائية لدى المرضى النفسيين. ومع ذلك فإن الآليات تشير إلى أن السمية القلبية الوعائية للأميتريبتيلين لا تزال غير معروفة. تهدف هذه الدراسة إلى توضيح الدور الوقائي والعلاجي للدميانا كعلاج عشبي مساعد ضد سمية القلب الناجمة عن استخدام الأميتريبتيلين في الجرذان. تم توزيع عدد 36 من ذكور الجرذان البيضاء بالتساوي الى ست مجموعات. المجموعة الأولى هي المجموعة الضابطة، والثانية هي مجموعة الداميانا، والمجموعة الثالثة هي مجموعة الجرذان التي عوملت