



## Nanopiperine reduces the Toxicity of Sodium Benzoate on Female Rats Reproductive System

Huda jassim mohammed and Saadeya Ali Al-Gnami

Department of Physiology and Pharmacology, Veterinary Medicine Collage, Al-Qadisiyah University, Iraq.

Email: [hudaalhelali68@gmail.com](mailto:hudaalhelali68@gmail.com)

- This article is a part of the master thesis of the first author.

### Abstract

#### Objective :

The current study aimed to investigate the possibility of using nano-piperine to reduce the toxic effects of sodium benzoate on the female reproductive system of female rats .

#### Methods:

fourty female Wister rats with an average weight of  $150 \pm 10$  g were used, dosed for 30 consecutive days they divided randomly into four equal groups (10 per group). The animals were allowed to acclimatize for 14 days before the experiment . The first group (C) was given 1 ml of distilled water orally as a control group. The second group (T1) was given sodium benzoate orally in a dose of 100 mg/kg B.W. The third group (T2) was given Nano-piperine orally in a dose of 25 mg /kg /B.W. The fourth group (T3) was given both sodium benzoate and Nano-piperine at the same time . After the end of treatments , ovary and uterus samples were removed from all animals and reserved them in formalin 10% for histological examination

#### Results:

The result of our study showed follicular inhibition and congestion of ovarian stroma in T1 group when compared with the control group . The structure of ovary in T2 group is similar to that of the control group . In T3 group the structure of the ovary looked almost normal , and increase in follicular growth wave when compared with the T1 group . The result of the uterine sections indicated degeneration and vacuolation of epithelial cells and complete absence of uterine gland ,. and infiltration of inflammatory cells in the endometrium . On the other hand , uterus section in T2 group revealed normal uterus cells without any significant lesion . while the uterine tissue in animals of T3 group showed a hyperplasia in epithelial cells , and proliferation of uterine glands and normal columnar epithelium of uterus .

#### Conclusion :

Nano-piperine at dose of 25 mg/kg has the ability to reduce histological changes on the female reproductive system resulting from treatment with sodium benzoate .

**Key words :nano-piperine, sodium benzoate, female reproductive system.**

### Introduction

The ability to preserve food was one of the great developments in human history (1). used food storage ingredients. With the chemical formula  $C_7H_5NaO_2$ . White paint benzoic acid salt is one of the most widely does not smell. It is present in grain or



powder shape. It used in a number of products, cosmetics and medications as a preservative (2). In some conditions, such as multiple sclerosis and liver disease, benzoic acid is used in the treatment (3). They are able to prevent bacteria and fungus growth and are thus used for food and drinks preservation (4). Sodium benzoate has been used to preserve some materials, including jams, soft drinks, fruit juices, and gelatin (5). It was commonly used for many years due to its good persistence and excellent solubility in water (6). Sodium benzoate is allowed to be used in the preservation of products as a safe substance. It can induce skin, eye irritation, and the respiratory system, whether it is used for brief periods of time. However, long term exposure, cause complications higher skin irritation (7). During recent years Functional compounds of food source has many attention in terms of disease prevention and health benefits (8). In this context, black pepper, which is classified in the *Pipera-ceae* family, has assumed a very great importance in terms of biological activity (9). Black pepper mainly contains piperine, which is an alkaline substance that has many health benefits (10) (11). Piperine is isolated from several members of the *Pipera-ceae* family, when proven that piperine acts as an antioxidant by inhibiting free radicals and lipid peroxidation (12). Piperine has great the attention of medicinal chemists and health professionals due to its numerous benefits including antioxidant, antitumor, anti-hypertensive, anti-asthmatics, analgesic, antipyretic, anti-diarrheal, anti-inflammatory, anxiolytic, antispasmodic, hepato-protective, anti-depressant, antibacterial,

## Results

The results of the statistical analysis in table .3-1 showed a significant decrease ( $p \leq 0.05$ ) in the number of ovarian follicles(

immunomodulatory, antifungal, anti-apoptotic, antithyroid, antimutagenic, antimetastatic, and anti-spermatogenic (13). It additionally inhibits various metabolizing enzymes, thus increasing the oral bioavailability of multiple drugs, nutrients, and vaccines . Furthermore , it boosts the cognitive actions and fertility as well (14). so, we used nano-piperine to investigate its possible protective role nanopiperine against the deleterious effect of sodium benzoate on female reproductive system of adult female rats .

## Material and Methods

### Experimental design :

In this study , 40 female Wister rats with an average weight of (150  $\pm$ 10 g) were used, divided randomly into four equal groups (10 per group) dosed for 30 successive days .The first group (C) was given 1ml of distilled water orally as a control group. The second group (T1) was given sodium benzoate (indian) orally in a dose of 100 mg/kg B.W. The third group (T2) was given nano-piperine (china) orally in a dose of 25 mg /kg /B.W. The fourth group (T3) was given both sodium benzoate and nano-piperine at the same time .

### Histopathological preparation :

Slide preparation was undertaken according to method proposed by Luna (23) .

### 2-3 Statistical Analysis

The The data was presented in the form of means and standard errors (SE). A one-way analysis of variance (ANOVA) with least significant difference LSD was used for the analysis. When  $p < 0.05$ , the results were considered statistically significant (24).

primary, secondary and Graffian) in T1 group when compared with the control group. While it showed a significant increase



( $p \leq 0.05$ ) in the number of ovarian follicles for the T2 and T3 groups when compared with the T1 group. The result of this study showed follicular inhibition and congestion of ovarian stroma in T1 group when compared with the control group. The structure of ovary in T2 group is similar to that of the control group. In T3 group the structure of the ovary looked almost normal, and increase in follicular growth wave was spotted when compared with the T1 group. The result of the histological section of uterus indicated degeneration and vacuolation of epithelial cells and, disappearance of uterine gland; and infiltration of inflammatory cells in the endometrium. On the other hand, uterus section in T2 group revealed normal uterus cells without any significant occupied lesion. The uterine tissue in animals of T3 group showed a hyperplasia in epithelial cells and proliferation uterine gland and normal columnar epithelium of uterus.

(Table .3 -1) : the Effect of nano-piperine on follicles number in Wister females rats treated with Sodium Benzoate .

Group	Primary	Secondary	Graffian
C	12.5±0.53 <sup>A</sup>	6 ±0 <sup>A</sup>	3.25±0.46 <sup>A</sup>
T1	4.12±0.64 <sup>B</sup>	2.5±0.53 <sup>B</sup>	1.50±0.53 <sup>B</sup>
T2	16.62±0.74 <sup>c</sup>	8.25±0.46 <sup>c</sup>	5.25±0.70 <sup>c</sup>
T3	8.12±0.35 <sup>D</sup>	4.62±0.51 <sup>D</sup>	3.12±0.83 <sup>A</sup>
LSD0.05	0.601	0.448	0.667

Numbers = mean ± Standard Error ( SE).

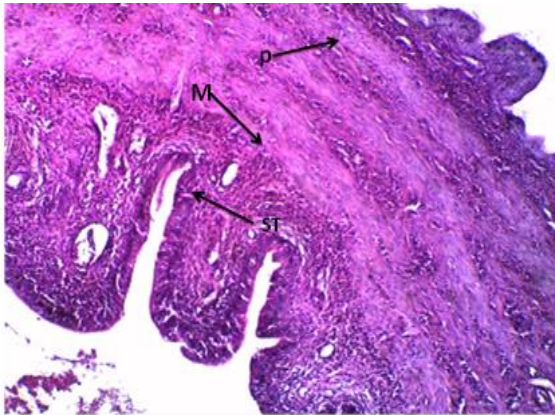
Different letters = Significant Differences ( $p < 0.05$ ).

C= Control group, received with distilled water orally for (30) days.

T1= Received with sodium benzoate orally (100 mg /kg B.W/day) for (30) days.

T2= Received with nano-piperine orally (25 mg/kg B.W/day).

T3= Received with sodium benzoate and nano-piperine orally for (30) days



Figure(1): Shows uterine tissue in the control group: picture is demonstrate normal uterus cells without any significant occupied lesion (SOL) Endometrium (red arrow) , Myometrium (M) , Perimetrium (P) and simple Tubular gland (ST).10X

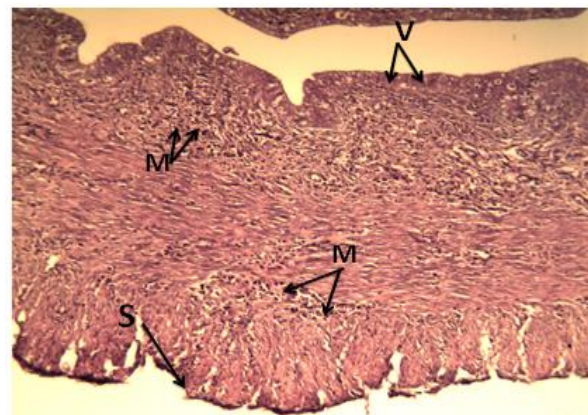
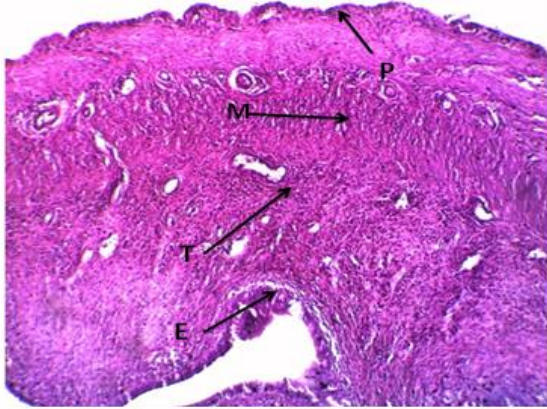


Figure (2): Shows uterine tissue in T1 group, there is a degeneration and vacuolation of epithelial cells (V) , which lining the uterus disappearance of uterine glands in the endometrium, infiltration of inflammatory cells in the endometrium and muscularis (M) with thickening of serosa (S) (10x) H&E



Figure(3): Shows uterine tissue in T2 group, there is a normal uterus cells without any significant occupied lesion (SOL) Endometrium (E), Myometrium (M), Perimetrium (P) and simple Tubular gland (T).10x

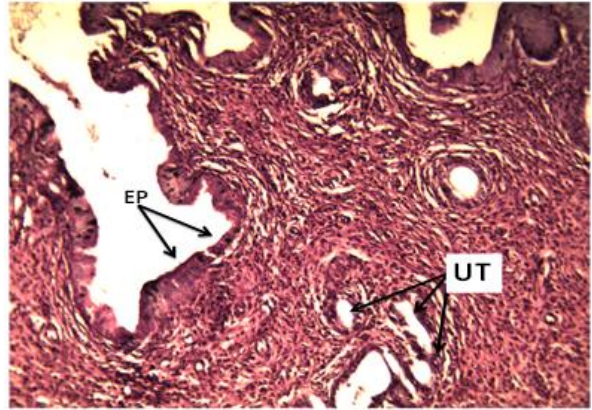


Figure (4): shows uterine tissue in T3 group, there is normal columnar epithelium (EP) of uterus with proliferation of uterine glands (UT) in the endometrium (10X)H&E.

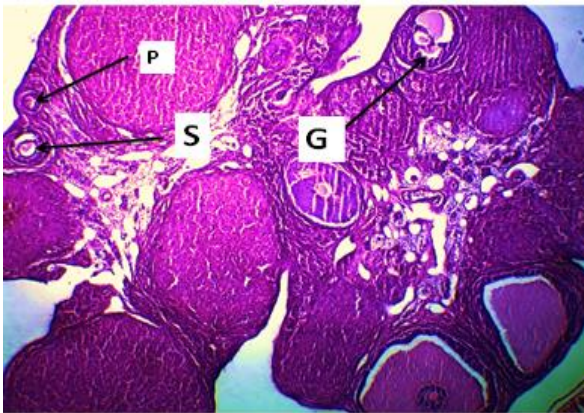


Figure (5): Shows Ovarian tissue in control group, there is normal ovarian cells without any significant occupied lesion (SOL) primary follicle (P) ,secondary follicle (S) and Graafian follicle (G).10X.

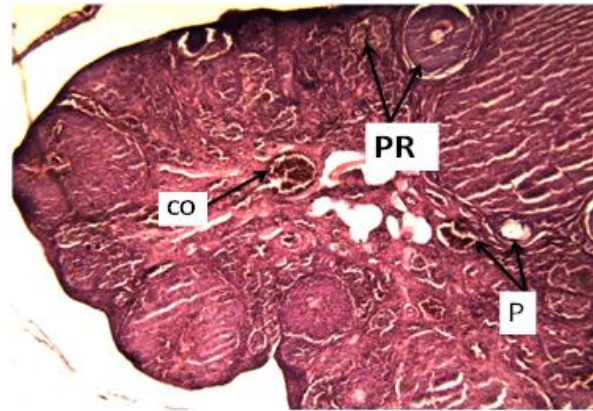


Figure (6): Shows Ovarian tissue in T1 group, there is a marked inhibition of follicular growth wave which characterized by the presence of few pre-mordial (P) and primary follicle (PR) , also there is a congestion in the ovarian stroma (CO)(4X)H&E.

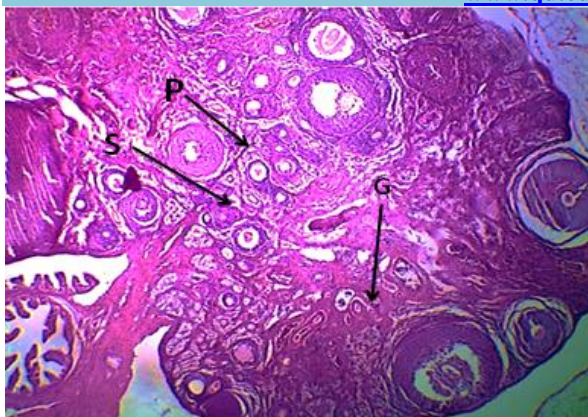


Figure (7): ovarian tissue in T2 group demonstrates normal ovarian cells, primary follicle (P) , secondary follicle (S) and Graafian follicle (G).10X.

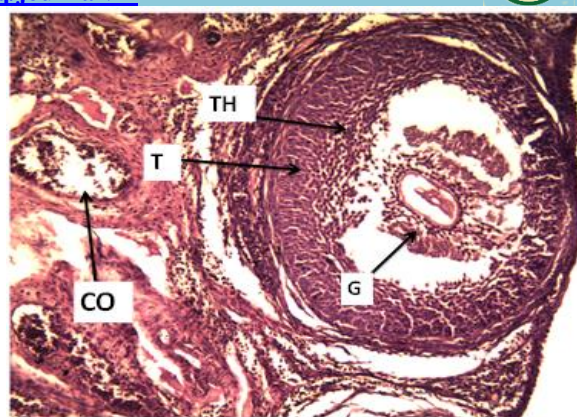


Figure (8):Shows Ovarian tissue in T3 group, there is a higher magnification , large Graafian follicle (G) with ova and large antrum & surrounded by theca interna ( TH) and theca externa (T) , also there is mild congestion (CO) of blood vessels (40X)H&E.

## Discussion

The results of the current study showed a significant decrease ( $p \leq 0.05$ ) in follicles numbers for female rats of the T1 group when compared with the control group (table 4-1). This is may be attributed to that sodium benzoate causes As a result of lack of FSH hormone, although the growth of follicles is subject to several growth factors and hormones, FSH hormone is one of the most important regulators of this process (15) . Where its deficiency hinders the process of formation and development of ovarian follicles , and consequently a decrease in their numbers . (16) (17) .On the other hand, when treating female rats with Nano-piperine at a dose of 25 mg/kg, which led to a significant increase ( $p \leq 0.05$ ) in follicles numbers . This is may be due to is due to the effect of piperine on the increase in the level of FSH. Whereas the study (18) , confirmed that FSH has a positive correlation between the number of follicles and the dose given of FSH to mice. also (19) , indicated that there is a positive correlation between the level of FSH in the serum and the average size of the follicles The results of the study

also showed a significant increase ( $p \leq 0.05$ ) in number follicles for female rats of the T3 group when compared with the group of T1. This is may be due to is that the increase in follicles numbers is due to the antioxidant effect of piperine, which caused a reduction in the harmful effects of sodium benzoate through positive results such as an increase in the level of FSH , as this hormone is responsible for stimulating the growth of ovarian follicles (20) .The results of histological section of uterus in T1 shows there is degeneration and vacuolation of epithelial cells , which lining the uterus disappearance of uterine glands in the endometrium , infiltration of inflammatory cells in the endometrium and muscularis with thickening of serosa Infiltration of inflammatory cells mainly macrophages with hemorrhage in the muscularis (fig. 2) . This is may be due to is due to the harmful effect of free radical formation by sodium benzoate treatment, as well as the decrease in reproductive hormones. when treating female rats with Nanopiperine at a dose of 25 mg/kg showed the results show normal uterus cells



without any significant occupied lesion ( fig.3 ), This is may be due to is due to the positive effect of the antioxidant Nano-piperine, as well as to the increase of estrogen hormone, which acts as a growth hormone for the tissues of the reproductive organs, supports the endometrium and supports the uterine muscle, as well as the production of quantities of thin watery mucus in the cervix that sperm penetrate (21) .On the other hand , when treating female rats with Nano-piperine at a dose of 25 mg/kg and sodium benzoate 100mg/kg show marked hyperplasia in the epithelial cells which lining the uterus . proliferation and dilation of uterine gland in the endometrium and normal columnar epithelium of uterus with proliferation of uterine glands in the endometrium (fig. 4) due the positive effect of Nano-piperine in resisting oxidative stress by reducing radicals and increasing antioxidants, thus increasing reproductive efficiency by increasing sex hormones that are reflected on the genitals. Also the results of histological section of ovary show There is marked inhibition of follicular growth wave which characterized by presence of few primordial and primary follicle and congestion in the ovarian stroma When compared with the control group . (fig.6) . Most of these changes are due to the stress damage caused by treatment with sodium

benzoate, which plays an important role in reproductive efficiency and function, as oxidative stress contributes to the rates of several pathological changes that may affect the efficiency and reproductive function of both sexes. (22) . On the other hand when treating female rats with Nano-piperine at a dose of 25 mg/kg show normal ovarian cells, primary follicle ,secondary follicle and Graafian follicle. (fig.7 ) . The structure of the ovary in this group is similar to that of the control group, in which evolved antral follicles, a normal granulosa cell layer, a detectable single layer, and several corpus luteum are also seen. However, a small number of atretic follicles are visible , When compared with the control group . This is may be due to is due to the positive effect of nano-piperine on increasing hormones and antioxidant levels. This is reflected in the tissues of the ovaries, follicles, and others . The results of the study also showed increase in the follicular growth wave which characterized by presence high number in secondary follicle , primary and primordial follicle and large graffian follicle with ova and large antrum for female rats of the T3 group when compared with the group of T1 (fig. 8 ) . This is may be due to is due to the positive antioxidant effect of nanopiperine, reducing the activity of free radicals and increasing the antioxidant effect .

## References

- 1-Saad, B., Bari, M. F., Saleh, M. I., Ahmad, K., and Talib, M. K. M. (2005). Simultaneous determination of preservatives (benzoic acid, sorbic acid, methylparaben and propylparaben) in foodstuffs using high-performance liquid chromatography. *Journal of Chromatography A*, 1073(1-2), 393-397.
- 2- Lennerz, B. S., Vafai, S. B., Delaney, N. F., Clish, C. B., Deik, A. A., Pierce, K. A., ... and Mootha, V. K. (2015). Effects of sodium benzoate, a widely used food preservative, on glucose homeostasis and metabolic profiles in humans. *Molecular genetics and metabolism*, 114(1), 73-79.
- 3- Yadav, A., Kumar, A., Das, M., and Tripathi, A. (2016). Sodium benzoate, a food preservative, affects the functional and activation status of splenocytes at non cytotoxic dose. *Food and Chemical Toxicology*, 88, 40-47.
- 4- Tsay, H. J., Wang, Y. H., Chen, W. L., Huang, M. Y., and Chen, Y. H. (2007). Treatment with sodium benzoate leads to malformation of zebrafish larvae. *Neurotoxicology and teratology*, 29(5), 562-569.
- 5- Zhang, G., and Ma, Y. (2013). Spectroscopic studies on the interaction of sodium benzoate, a food preservative, with calf thymus DNA. *Food chemistry*, 141(1), 41-47.



- 6- Ren, L., Meng, M., Wang, P., Xu, Z., Eremin, S. A., Zhao, J., ... and Xi, R. (2014). Determination of sodium benzoate in food products by fluorescence polarization immunoassay. *Talanta*, 121, 136-143.
- 7- Schosler P, Do Nascimento Filho I, Santos Freitas L , Melecchi MI,Rodrigues Vale MG, and Bastos Caramao E. (2004). Selective Extraction of Benzoic acid from Landfill Leachate by solid-phase extraction and ion-exchange chromatography. *J Chromatogr A*. 1027(1-2):167–70 .
- 8- Ul-Haq, I., Butt, M. S., Randhawa, M. A., & Shahid, M. (2019). Hepatoprotective effects of red beetroot-based beverages against CCl4-induced hepatic stress in Sprague Dawley rats. *Journal of Food Biochemistry*, 43(12), e13057.
- 9- Zadorozhna, M., Tataranni, T., and Mangieri, D. (2019). Piperine: role in prevention and progression of cancer. *Molecular biology reports*, 46(5), 5617-5629.
- 10- Acharya, S. G., Momin, A. H., and Gajjar, A. V. (2012). Review of piperine as a bio-enhancer. *Am J Pharm Tech Res*, 2, 32-44.
- 11- Ahmad, N., Fazal, H., Abbasi, B. H., Farooq, S., Ali, M., and Khan, M. A. (2012). Biological role of *Piper nigrum* L.(Black pepper): A review. *Asian Pacific Journal of Tropical Biomedicine*, 2(3), S1945-S1953.
- 12- Mittal, R., and Gupta, R. L. (2000). In vitro antioxidant activity of piperine. *Methods and findings in experimental and clinical pharmacology*, 22(5), 271-274.
- 13- Smilkov, K., Ackova, D. G., Cvetkovski, A., Ruskovska, T., Vidovic, B., and Atalay, M. (2019). Piperine: old spice and new nutraceutical?. *Current pharmaceutical design*, 25(15), 1729-1739.
- 14- Wattanathorn, J., Chonpathompikunlert, P., Muchimapura, S., Pripem, A., and Tankamnerdthai, O. (2008). Piperine, the potential functional food for mood and cognitive disorders. *Food and Chemical Toxicology*, 46(9), 3106-3110.
- 15- Durlinger, A.L.L., Gruijters, M.J.G., Kramer, P., Karels, B., Kumar, T.R., Matzuk, M.M., Themmen, A.P.N. (2001). anti-müllerian hormone attenuates the effects of FSH on follicle development in the mouse ovary . *Endocrinology* 142(11):4891-4899 .
- 16- BK, C., Scaramuzzi, R., and Webb, R. (1995). Control of antral follicle development and selection in sheep and cattle. *Journal of Reproduction and Fertility Supplement*, 49, 335-350.
- 17- Kumar, T. R., Wang, Y., Lu, N., and Matzuk, M. M. (1997). Follicle stimulating hormone is required for ovarian follicle maturation but not male fertility. *Nature genetics*, 15(2), 201-204.
- 18- Wei, S., Gong, Z., Guo, H., Zhang, T., and Ma, Z. (2017). FSH and eCG impact follicles development and expression of ovarian FSHR and caspase-9 in mice. *Iranian Journal of Veterinary Research*, 18(2), 79.
- 19- Abbara, A., Patel, A., Hunjan, T., Clarke, S. A., Chia, G., Eng, P. C., and Dhillon, W. S. (2019). FSH requirements for follicle growth during controlled ovarian stimulation. *Frontiers in endocrinology*, 579.
- 20- Wang, Y., Rippstein, P. U., and Tsang, B. K. (2003). Role and gonadotrophic regulation of X-linked inhibitor of apoptosis protein expression during rat ovarian follicular development in vitro. *Biology of reproduction*, 68(2), 610-619.
- 21- Ilie ,I.R. (2020). *Reproduction Endocrinology . in Introduction to Endocrinology (pp.143-175) . Cham : Springer International Publishing .*
- 22- Chandra, A., Surti, N., Kesavan, S., and Agarwal, A. (2009). Significance of oxidative stress in human reproduction. *Archives of Medical Science Special Issues*, 2009(1), 42-42 .
- 23- Luna, L. G. (1968). *Manual of histologic staining methods of thearmed for ces institute of pathology. 3rd Edn.Mcgraw-Hill Book Company.New York:258.*
- 24- Joda, M.(2008). *The Progressive Statistical Analysis By UsingSPSS.1St Ed.Walse House Editions ,Amman Jordan*