



## Hematological, biochemical, and histological alteration induced by nano silver material on male rats

E.A. Jabori<sup>1</sup> , H.Kh. Ismail<sup>2</sup> , L.W. Khaleel<sup>1</sup>  and A.A. Al-Hadidy<sup>3</sup> 

<sup>1</sup>Department of Physiology and Biochemistry, College of Veterinary Medicine, University of Baghdad, Baghdad, <sup>2</sup>Department of Pathology and Poultry Diseases, College of Veterinary Medicine, <sup>3</sup>Department of Biology, College of Science, University of Mosul, Mosul, Iraq

### Article information

#### Article history:

Received December 14, 2022  
Accept March 29, 2023  
Available online June 18, 2023

#### Keywords:

Nanomaterial  
Hematological  
Toxic metallic Silver  
Liver  
Rats

#### Correspondence:

E.A. Jabori  
[dr.anaamanad83@gmail.com](mailto:dr.anaamanad83@gmail.com)

### Abstract

This study investigates the effects of I/P injection of nano silver materials in the dose 0.2, 0.4, 0.6 mg/kg B.W. for 21 days on blood parameters, cardiac and hepatic tissue histology, and their functions. The results showed a significant increase in the blood parameters of treated animals in compared with the control group. The histological study showed that the histological alteration is more pronounced in the animals that treated with the dose 0.6 mg/kg B.W. which is characterized by inflammatory reaction with degeneration and necrosis of hepatocytes. In contrast, the histological alteration of cardiac muscle showed generalized congestion of blood capillaries, degeneration, and necrosis of cardiomyocytes with inflammatory reaction. Our conclusion of this study showed that the nano silver materials have a pronounced cytotoxic impact on the histological structure and function of the liver and heart besides the influence on the blood parameters (RBCs, platelets, hemoglobin, WBCs, MCV, MCH, MCHC).

DOI: [10.33899/ijvs.2023.137239.2660](https://doi.org/10.33899/ijvs.2023.137239.2660), ©Authors, 2023, College of Veterinary Medicine, University of Mosul.  
This is an open access article under the CC BY 4.0 license (<http://creativecommons.org/licenses/by/4.0/>).

### Introduction

One of the most active topics today, nanotechnology, is the current materials science, demonstrating certain features. The applications for nanomaterials are expanding quickly (1). Numerous studies on synthetic nanomaterials have been conducted in recent years, and their description is a developing area of nanotechnology due to the widespread usage of nanomaterials in the fields of physics, chemistry, biology, and medicine, anti-inflammatory (2,3). Several antibacterial medicinal products, including toothpaste, gynecological suppositories, and wound dressings, were created using Nano silver elements (3). Additionally, there is a biological and toxicological reaction to these features (4). Nano silver components will be used in this. When nano silver materials are ingested, they can accumulate in the parenchymal organs and has causes toxic damage to the liver, kidneys, and heart (5). The toxicity of nano silver

materials occurs due to the release of silver ions in the blood after the ingestion of nano silver (6). Nano silver materials are more toxic than metallic nanomaterials, such as aluminum, iron, nickel, and manganese (7). Nano silver materials toxicity can be affected by their shape, size, concentration, dose, how they get into the body, how long they stay there, and whether or not they are in an aggregated state (8).

This research aims to assess the toxic effect of nano silver material on the cardiac and hepatic tissues and hematological and biochemical in male rats.

### Materials and methods

#### Ethical approve

The scientific committee has approved this study of the college of veterinary medicine- University of Baghdad at the seventh congress dated 11/1/2022, that the concurrent

conducting experiment did not violent the laws of animal rights and the euthanasia is applied in accordance of this guidelines, and approval issue number and date is UM.VET.2022.014.

### Animal and experimental design

A total of 20 white Albino rats (male; 4 weeks of age, weight 200-250 g) were kindly provided from the animal house of the Veterinary college at the University of Mosul. Rats were fed a standard commercial meal and housed at a regular temperature 22-25°C. Before the trial started, all rats were acclimated for 7 days. Rats were split equitably into four groups, each of which had five rats, as follows: The first group was a control group treated with distal water intraperitoneally for 21 days. The second group was treated with nano silver material at a dose of 0.2 mg/kg body weight intraperitoneally for 21 days. The third group was treated with 0.4 mg/kg body weight intraperitoneally for 21 days. The fourth group was treated with 0.6 mg/kg body weight intraperitoneally for 21 days (9).

### Blood and serum samples collection and smear

Blood samples of this study were collected from the animals in all groups. A capillary tube with heparin was implanted in the inner corner of the eyeball. This tube was used to draw blood from the eye veins. Blood samples were put in gel tubes. The blood was then clotted, and the tubes were put in the centrifuge at 3000 rpm for 15 minutes to separate the serum. The serum was then put in the freezer at -20 C for ALT and AST estimation. Anticoagulant ethylene diamine tetra acetic acid (EDTA) was used to take blood samples, which were then used for manual hematological analysis. Blood samples were collected EDTA anticoagulant to analyze biochemical and physiological parameters, and Leishman stain was used for blood smear staining (10).

### Biochemical analysis

the serum of each sample was collected and used to measure hepatic enzymes such as ALT and AST. The enzymatic parameters related to the liver and heart were detected using a spectrophotometer. The wavelength for the measurement of AST and ALT is 340-1020 (China origin) (11).

### Histopathological analysis

To analyze the histopathological alterations, liver and heart tissue sections preserved in 10% neutral buffer formalin are processed, embedded in paraffin, sectioned at 4.5-5 m using a rotary microtome, and finally stained with Hematoxylin and eosin (12).

### Determination of hematological parameters

The hematological parameter, red blood cell count (RBCs count), packed cell volume (PCV), hemoglobin concentration (Hb), white blood cells (WBCs), and platelet

count were analyzed with a hematology analyzer (Swelb ALFA) (13,14).

### Statistical analyses

The results of the present study were plotted as mean  $\pm$  Standard deviation. The data were analyzed using SPSS, and the statistical evaluation was done using the One-Way Analysis of Variance (ANNOVA) option was used which is followed by the Duncan test. The level of statistical significance was set at  $P < 0.05$  (15).

## Results

### Blood parameters

The current study showed that compared to the control group, animals treated with silver nanomaterials caused significant differences in Hb, total WBCs, lymphocyte, granulocyte numbers, and RBC counts. There were significantly increased Hb and RBCs in animals post intraperitoneally treatment with 0.2, 0.4, and 0.6 mg/kg B.W. of nano silver materials. The WBCs were higher in the treated group in the treated animals with 0.6 mg/kg B.W. than 0.2 and 0.4 mg/kg B.W. However, at the same time, lymphocyte percentage was significantly increased in the group of animals treated with 0.6 mg/kg B.W. compared with other groups. Additionally, there were no significant differences in MCV, MCH, MCHC, and RDW of all groups compared with the control group (Figures 1-4) at  $p < 0.05$ . The PLTs count is increased in group 4 compared with G1, G2, and G3 (Figure 5).

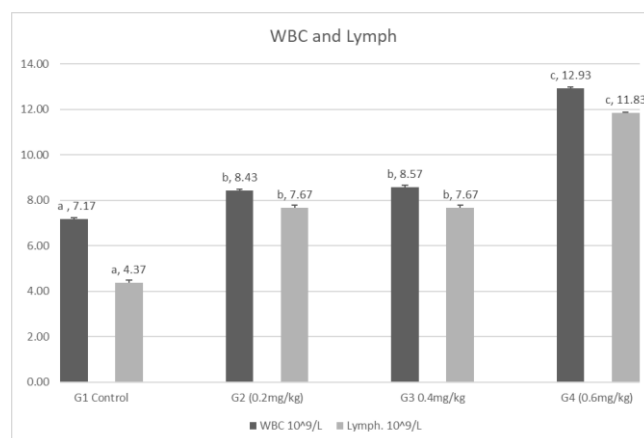


Figure 1: Nano silver material effect on rats' WBCs, both in nano silver materials treated and non-treated groups.

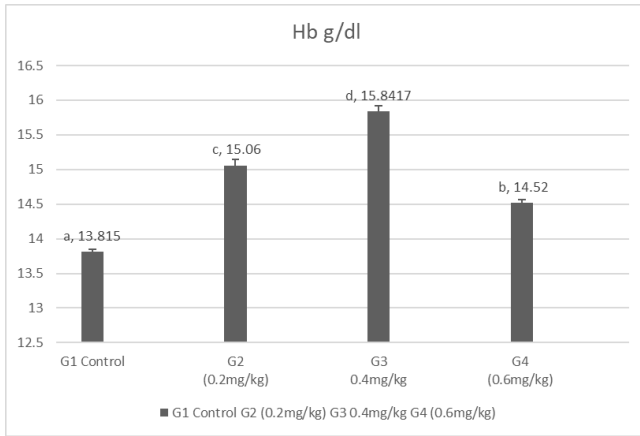


Figure 2: Nano silver material effect on hemoglobin in rats in both groups, treated and non-treated.

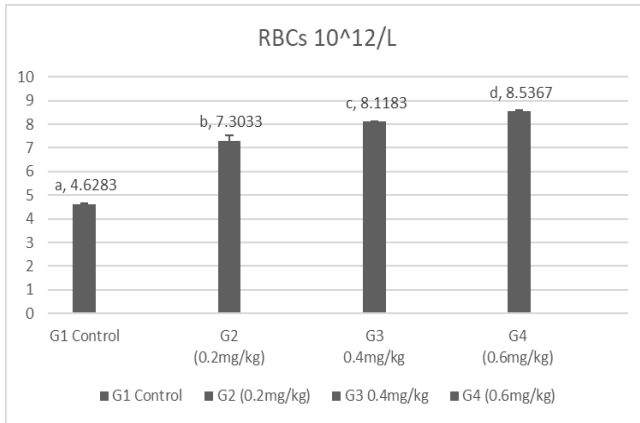


Figure 3: Nano silver material effect on rats' RBCs, both groups Nano silver materials treated and non-treated.

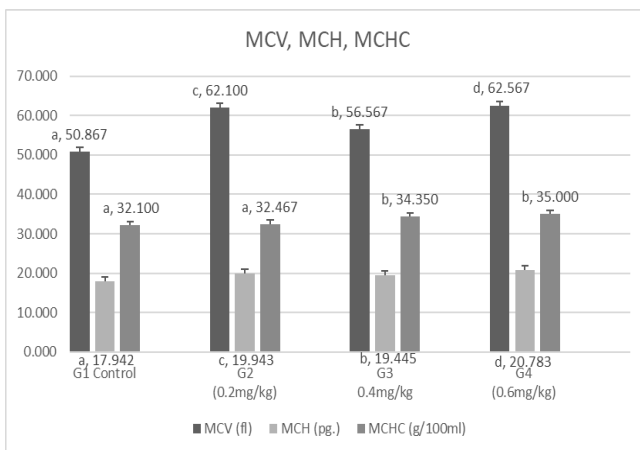


Figure 4: Nano silver material effect on Blood parameters in rats, both groups of nano silver materials treated and non-treated.

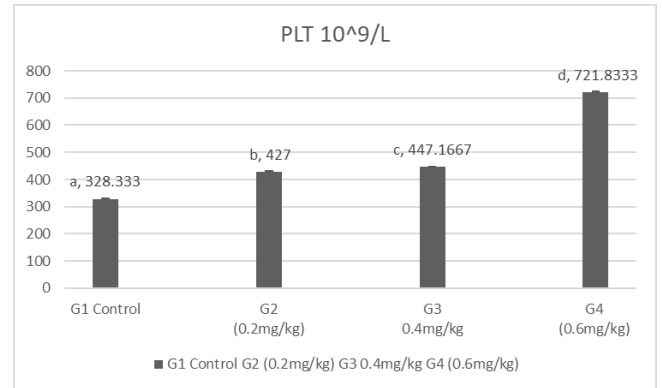


Figure 5: Nano silver material effect on PLT in rats, both groups nano silver materials treated and non-treated groups.

### Red blood cells morphology

Microscopically, normal blood cells have a biconcave disk shape and has a polar center area. Many types of red blood cells shape were noticed in blood smears of animals injected with nano silver materials with different doses. This abnormal shape included hypochromic normocytic and hypochromic macrocytic red blood cells seen in the blood smear of rats injected with 0.2 mg/kg B.W. In contrast, the blood smear of rats injected with the dose of 0.4 mg/kg B.W. nano silver materials showed different abnormalities of shape and size are seen in this group which includes hypochromic normocytic, echinocytes, acanthocytes, and stomatocyte shape of red blood cells. As for the blood smear of rats injected with 0.6 mg/kg B.W. of nano silver materials showed the same abnormal morphology of red blood cells seen in the 0.4 mg/kg B.W. group in addition to Target shape cells and Rouleaux shape cells which appeared as rouleau which stacks as a chain (Figure 6-10).

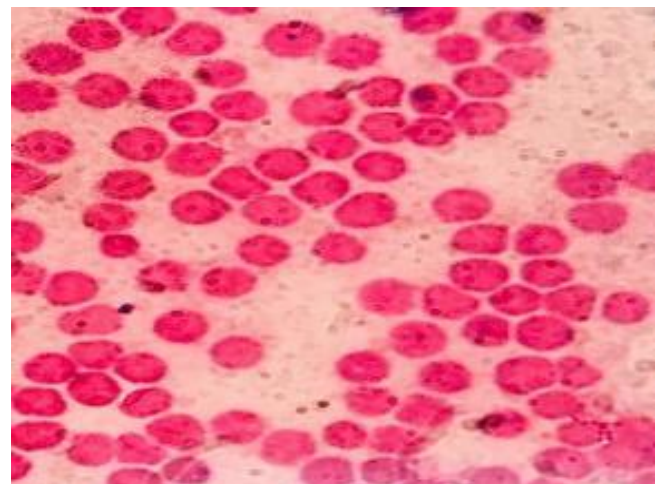


Figure 6: Rat blood smear treated with 0.2 mg/kg nano silver material showed RBCs Macrocytic hypochromic. Leishman stain, 1000x.

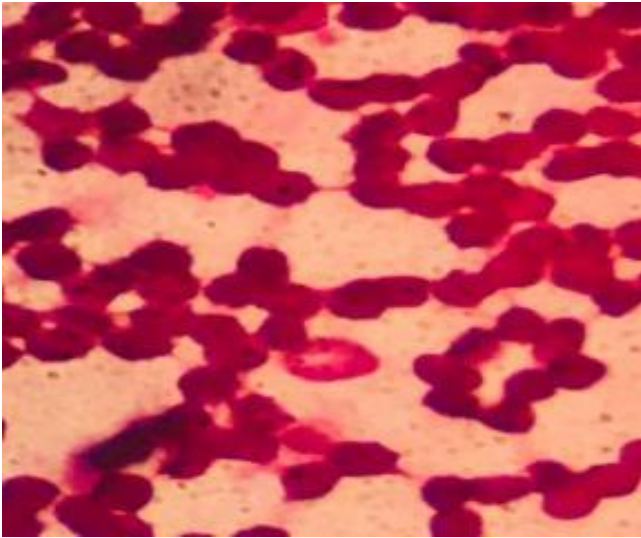


Figure 7: Rat blood smear treated with 0.4 mg/kg nano silver materials showed Rouleux formation and stomatocytes RBCs. Leishman stain, 1000x.

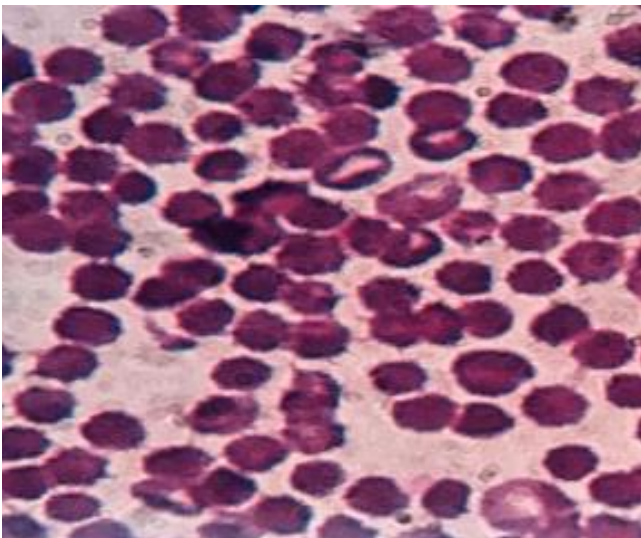


Figure 8: Rat blood smear treated with 0.4mg/kg nano silver materials showed stomatocyte RBCs and echinocytes RBCs. Leishman stain, 1000x.

**Body weight and toxicity symptoms**

Throughout this study, all rats were observed to detect the mortality and any abnormal symptoms of the toxic effect of nano silver materials. All injected groups with 0.2, 0.4, and 0.6 mg/kg B.W. of nano silver material for 21 days showed no mortality of animals of all groups showed depletion in the food intake led to a decrease in body weight in addition to dullness with alopecia compared with the control group The 0.6 mg/kg B.W. injection causes significant depletion of animal's body weight (Figure 11).

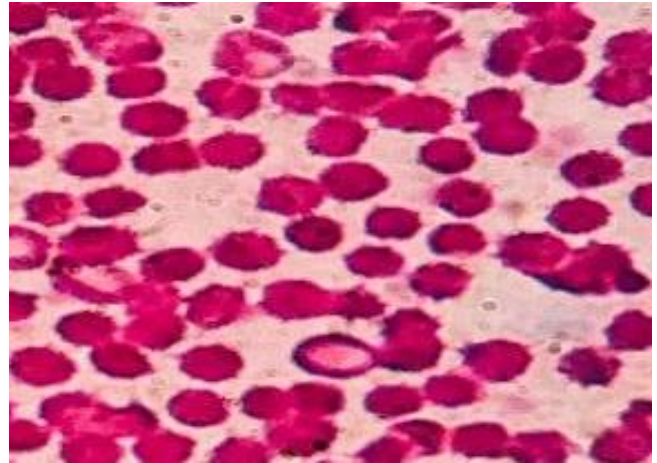


Figure 9: Rat blood smear treated with 0.4mg/kg nano silver material showed stomatocyte RBCs and echinocytes RBCs. Leishman stain, 1000x.

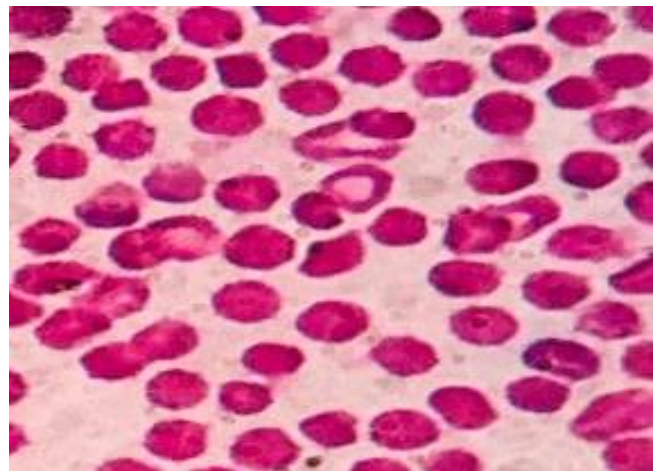


Figure 10: Rat blood smear treated with 0.4 mg/kg nano silver materials showed target RBCs. Leishman stain, 1000x.

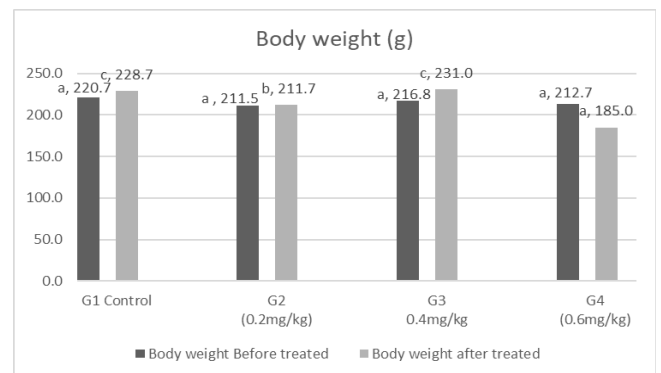

Figure 11: Nano silver material effect on body weight in rats, both groups of nano silver materials treated and non-treated groups.

**Liver function tests**

The effect of intraperitoneal injection of nano silver materials on the hepatic function tests by estimation of ALT, AST serum level showed significant alteration in animals 21 days post-injection with 0.6 mg /kg B.W. compared with 0.2,0.4 and control group (Figure 12).

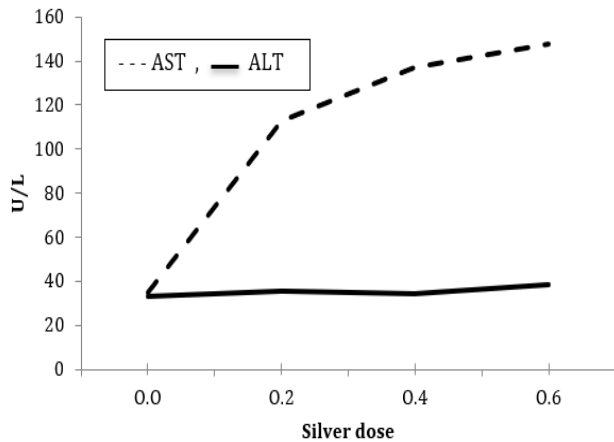


Figure 12: Nano silver material effect on serum enzymatic markers of hepatic function including AST, ALT in rats compared to the control group

**Hepatic histological lesion**

The microscopic histological examination of hepatic specimens staining with Hematoxylin and eosin of the control group showed normal architecture of hepatic tissue. While in the group of animals treated with nano silver materials at different doses 0.2, 0.4,0.6mg/kg B.W. showed a degenerative, necrotic inflammatory reaction. At the dose of 0.2 mg/kg B.W., the histological alteration is characterized by angiectasis of blood vessels (Central vein, portal vein), sinusoid congestion, and hyperplasia of Kupffer cells were also observed. Extravasated blood cells in between the hepatocytes, centrilobular hepatocytes necrosis with Focal inflammatory especially mononuclear cells, recent thrombus formation of the portal vein with periportal inflammatory cells infiltration, other section showed perivascular cuffing of inflammatory cells. While rats treated with 0.4 mg/kg B.W. nano silver materials which shown severe congestion of the central vein surrounded by necrotic hepatocytes, replacement of eosinophilic materials deposition were replaced to necrotic hepatocytes Foci of inflammatory cells infiltration were also observed. As for the hepatic section taken from rats treated with 0.6 mg/kg, B.W. showed more severe histological alteration than the other groups characterized by generalized blood vessels congestion, multifocal inflammatory cells infiltration in the hepatic parenchyma and the portal trait. Necrosis of periportal hepatocytes congestion of sinusoids also observed (Figures 13-20) .

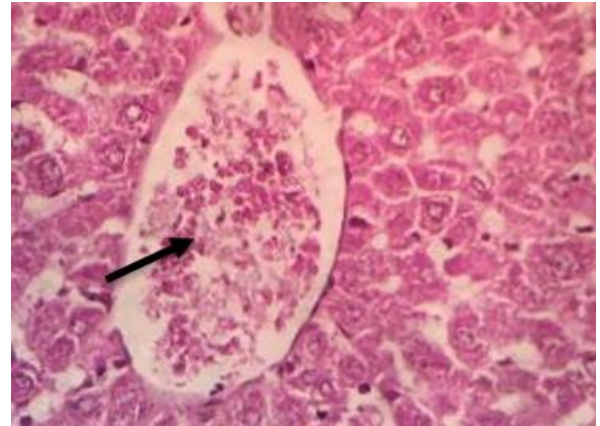


Figure 13: Liver tissue treated with nano silver materials at a dose of 0.2mg/kg showed angiectasis of the blood vessel (black arrow). H&E, 400x.

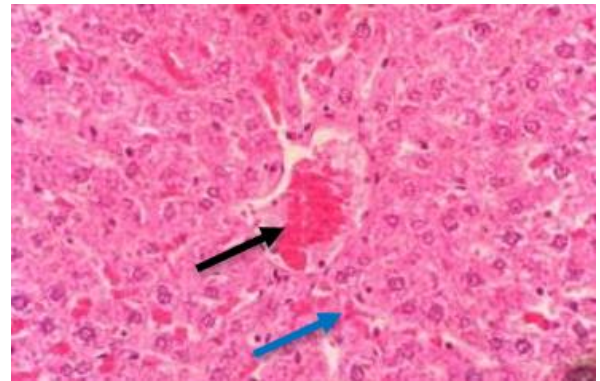


Figure 14: Liver tissue of rats treated with nano silver materials showed congestion of the central vein (black arrow) and sinusoid (blue arrow), also observed. H&E 400x.

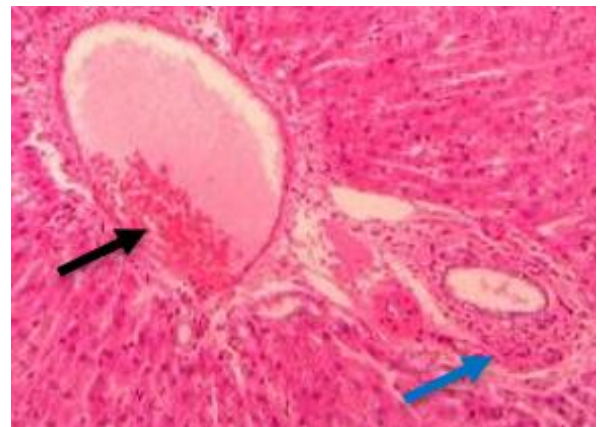


Figure 15: Liver tissue of the rats treated with nano silver materials at dose 0.2 showed thrombus formation (black arrow) and infiltration of the inflammatory cell (blue arrow). H&E 400x.

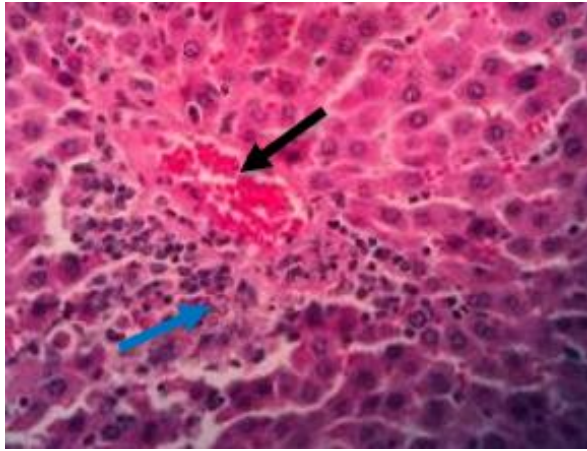


Figure 16: liver tissue treated with nano silver materials at a dose of 0.4 mg/kg showed severe congestion of the central vein (black arrow) and infiltration of inflammatory cells around the blood vessels (blue arrow). H&E 400x.

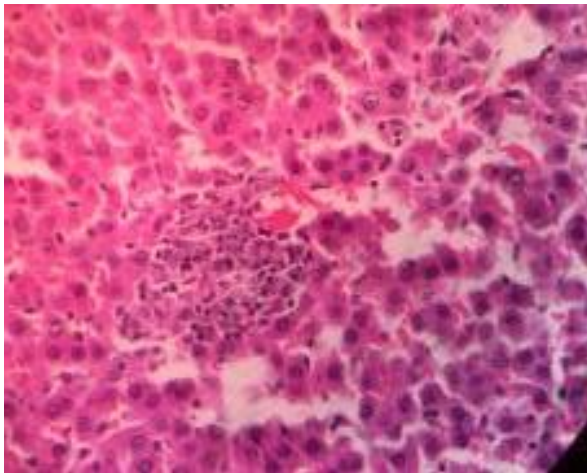


Figure 17: Liver tissue of the rats treated with silver nanomaterials at a dose of 0.4 mg/kg showed foci of inflammatory cells infiltrated in the hepatic parenchyma. H&E, 400x.

#### **Heart tissue lesions**

The cardiac histopathological alteration was seen by hematoxylin and eosin staining taken from treated animals with 0.2mg/kg B.W. of nano silver materials showed histological alteration of cardiomyopathy which was characterized by generalized congestion of blood capillaries, vacuolation of myocardiocytes with inflammatory cells infiltration seen in degenerative foci in myocardial cells thicken of capillaries wall also observed. Hemorrhage with discontinuation of myocardial fibers in other sections with vacuities. As for the histological lesions of the myocardial muscle of rats treated with 0.4 mg/kg B.W. nano silver materials showing cardiomyopathy, which is characterized

by vasculitis, loss striation of myocardial fibers, severe infiltration of inflammatory cells, vacuolation and necrosis of myocytes, edema in between muscle fibers with discontinuation of myocardial fibers also observed. While the rats that were treated with 0.6 mg/kg B.W. showed more severe histological alteration, which was characterized by cardiomyopathy, including foci of extravasated erythrocytes scattered within the myocardial muscle fibers, multifocal necrosis of individual and numbers of cardiomyocytes with myofiber vacuolation which accompanied by mixed infiltration of inflammatory cells, especially mononuclear cells, there is a replacement of fibrous tissue also observed (Figure 21-27).

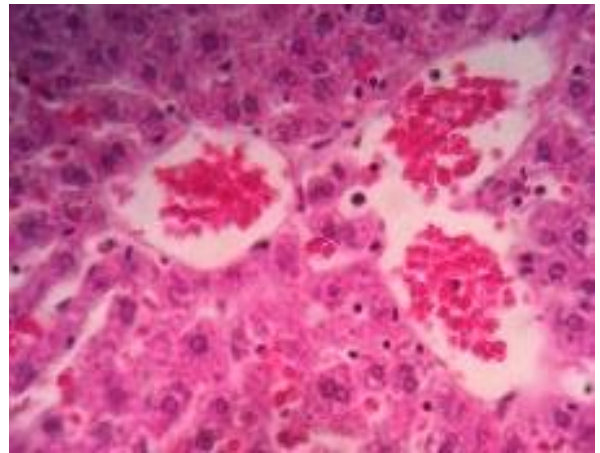


Figure 18: Liver tissue of the rats treated with silver nanomaterials at a dose of 0.6 mg/kg showed severe congestion of blood vessels with necrosis of hepatocytes. H&E,400x.

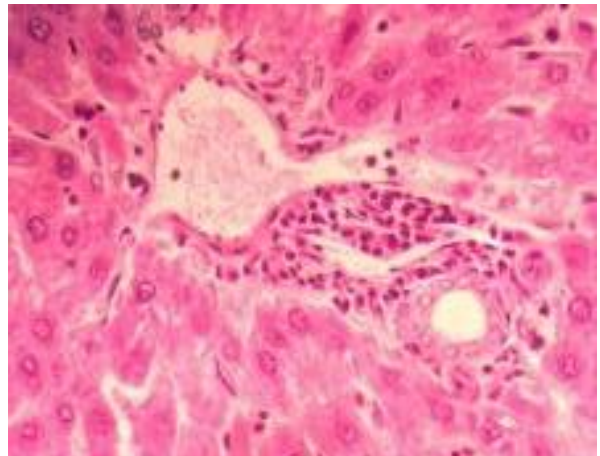


Figure 19: Liver tissue treated with nano silver materials at 0.6 mg/kg necrosis of periportal hepatocytes in the hepatic with congestion sinusoid also observed. H&E,400x.

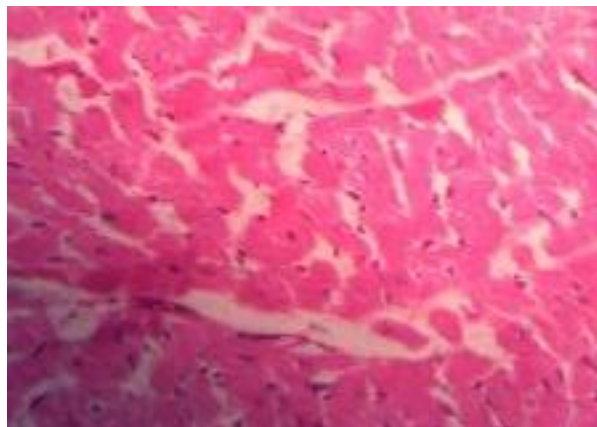


Figure 20: liver tissue of the rats treated with silver nanomaterials showed Extravasated blood cells and Kupffer cell. H&E, 400X.

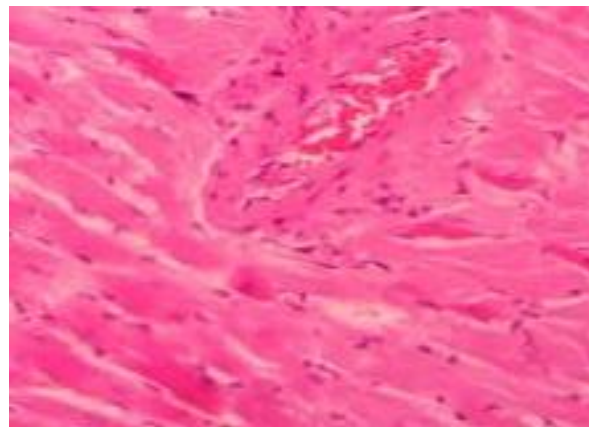


Figure 23: Heart tissue of the rats treated with nano silver materials at a dose of 0.2 mg/kg showed angiectasis of the blood vessel, thickening of capillaries wall. H&E, 400x.

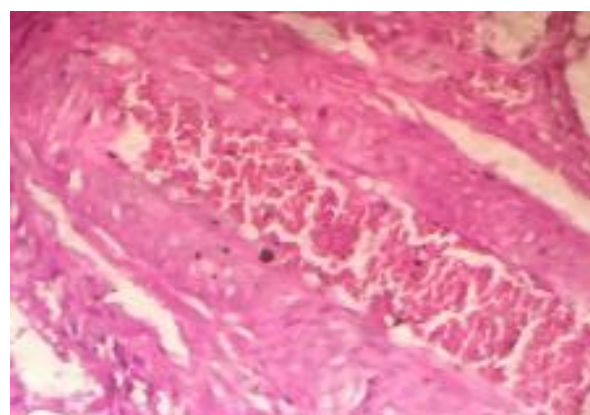


Figure 21: Heart tissue in rats treated with nano silver materials at 0.2mg/kg showed congestion and thickening of the capillaries wall. H&E, 400x.

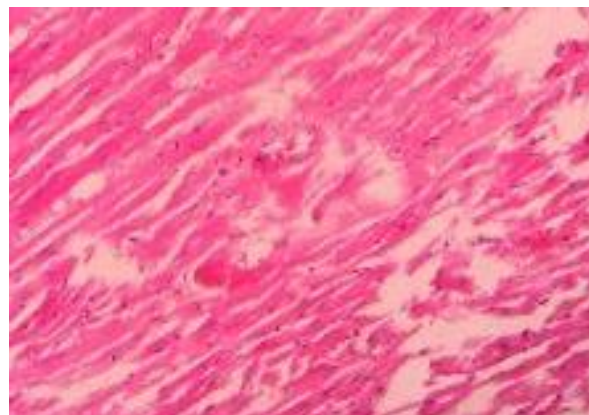


Figure 24: Heart tissue treated with silver nanomaterials at a dose of 0.2 mg/kg showed discontinuation of myocardial fiber and edema. H&E, 400x.

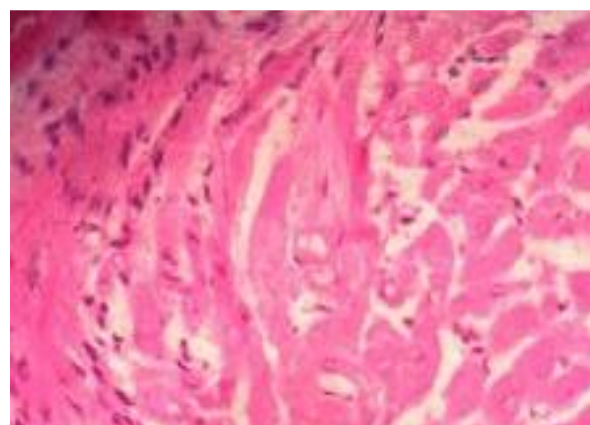


Figure 22: Heart tissue in rats treated with nano silver materials at 0.2mg/kg showed infiltration of inflammatory cells and loss of striation of myocardial fiber. H&E, 400x.

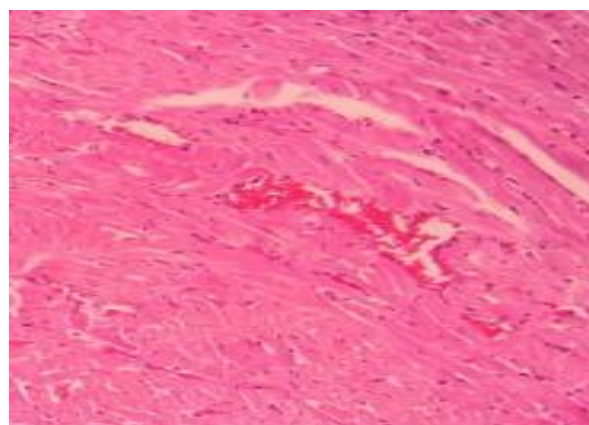


Figure 25: Heart tissue treated with nano silver materials at 0.6 mg/kg myocardial pathology foci of extravasated erythrocytes scattered in myocardial muscle fibers. H&E, 400x.

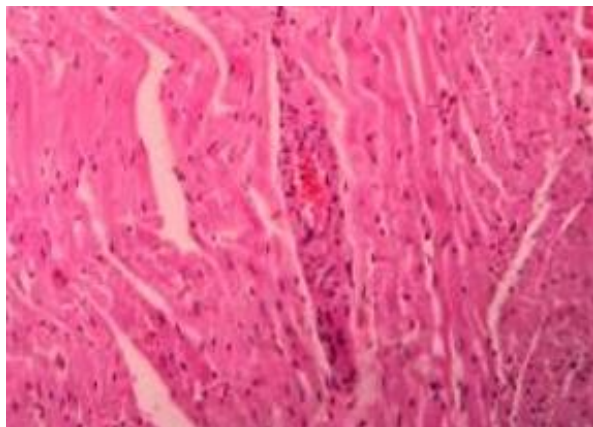


Figure 26: Heart tissue of rats treated with nano silver materials showed vasculitis in addition to inflammatory cell infiltration (black arrow). H&E, 400x.

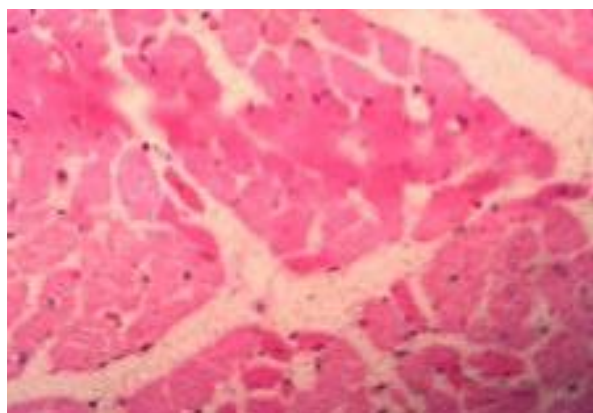


Figure 27: Heart tissue of rats treated with nano silver materials showed loss of striation of myocardial fiber with edema. H&E, 400x.

## Discussion

The result of hematological parameters showed that the RBC number had changed. These RBC changes may be due to nanoparticles affecting how hemoglobin is made when red blood cells mature in the bone marrow (10). This may occur due to an increase in immunogenic response. Various types of neutrophils, which serve as the body's first line of defense and play an essential role in immunity, can signal an infection or a harmful or allergic reaction to drugs or substances (11).

While the RBC count was larger in the group that was treated than in the group that was not, it means there was fewer RBCs destruction. It could be due to the toxic effects of nano silver materials that cause more RBCs formation in the bone marrow (12). The impact of nano silver materials on the blood-producing system caused a reduction in RBCs (13). Additionally, nano silver materials interfere with

immune system function (14,15). The absence of erythropoietin in the bloodstream may have contributed to the slight decrease in red blood cells and hemoglobin (16). Anemia that is normochromic and normocytic can occur when erythropoietin levels in the blood are reduced (17). Although hypochromic anemia is a catch-all phrase for all anemias, this disorder is almost always caused by an iron shortage (18). The administration of nano silver materials causes a rise in platelet count, which significantly impacts blood coagulation and causes clot formation within blood arteries, accelerating the development of atherosclerosis (19).

The interaction of nano silver materials with the blood and blood components may lead to changes in hematological parameters like WBCs, RBCs, and platelets. Red blood cells move oxygen from the alveoli to other bodily regions. Red blood cells are highly significant connective tissues crucial to the system organ's functionality. Consequently, a variety of disorders can be diagnosed using pathological markers. The form, size, and number of the tee will alter, which can be used to estimate the disease's prognosis. Hemolysis is when erythrocytes break apart. This will cause their contents, like hemoglobin, to leak into the surrounding area (20).

RBCs have an irregular form as a result of pathogenic events that affect how the bone marrow functions This will cause macrocytic RBCs to form, otherwise, the erythrocytes in the bone marrow wouldn't be able to make enough hemoglobin, this would lead to hypochromic erythrocytes, when seen in three dimensions, the white stomatocytes look like bowls, when diskocytes changed into spherocytes, these cells showed up as a step along the way, Acanthocytes can be detected in patients with chronic disease like (chronic alcoholic disease), also occur in deficiency of pyruvate kinase RBCs have an oval form because of defective membrane proteins (21). Disorder is to blame for this oval and teardrop-shaped erythrocytes are formed due to bone marrow infiltration and vasculature damage Phagocytes appear to produce bite cells when they remove RBCs portions and a Heinz body (21). According to a number of scientists, nanoparticles connected to DNA or other biological components that include sulfur and phosphorus can be hazardous to cells (22). Investigators have established a connection between the generation of free radicals, which alters the structure of cell membranes, and the cytotoxicity of silver nanoparticles (23). AgNPs also have harmful characteristics and limited metabolic activity (24). Silver nanoparticles' chemical makeup, shape, size, aggregation, surface, and function all impact the biokinetics of their lethal action (25). Because of this direct interaction with RBCs, which results in oxidative stress, membrane damage, and hemolysis, silver nanoparticles are harmful However, taxonomy has other impacts on red blood cells (RBCs), and little is known about how they function (26,27).

Compared to controls, all animals exposed to nano silver materials show a steady decline in mean body weights over



time However, non-significant evidence revealed that their buildup in various sites at concentrations that could cause functional change and subsequently impair the body's metabolic rate No untreated animal in this investigation showed an increase in food consumption during the trial, so we hypothesized that continuous exposure to large doses of nanoparticles particles could cause a reduction in overall metabolism The acquired results were discovered to agree with a prior study (27) that documented a considerable decrease in rats body weight treated by different doses 0.2, 0.4 mg/Kg for 21 days. Additionally, Sarhan and Hussein (26) showed that short-term intraperitoneal injection of nano silver materials in dose 2000 mg/Kg showing no discernible impact in body weight (28).

Nonetheless, it was revealed that male rats injected intraperitoneally with 0.2, 0.4, and 0.6 mg/ Kg of nano silver materials did not experience any appreciable amount of the drug changes in body weight (29). The large weight growth found after receiving a high dose of nano silver particles may result from long effects of using nano silver materials (30). Given that the consistent weight gain shown in this trial occurred without any apparent increase in food intake (31). Furthermore, it was established that male rats were treated with 0.2 mg/kg body weight with nano silver materials during a 21-day timeframe, and that there were no differences in body weight compared to the control group This could be a sign of the nano silver material's early harmful effects Previous research indicated that the toxicity of medications or chemical compounds can cause changes in body weight (32,33). Due to the body's oxidation of fats and the release of free radicals, these effects could be attributed to oxidative stress (34). Also reporting the findings are Yildirimer *et al.* (35).

In the current study, after 21 days of therapy, rats treated with 0.6 mg/kg nano silver materials had considerably higher levels of the AST enzyme. Rats were treated with nano silver materials at doses of 0.2 and 0.4 mg/kg had non-significant ALT levels. Rat serum ALT levels were increased by this investigation at ( $P < 0.05$ ) levels. Although there was no clear pattern in the response of AST and ALT to intraperitoneal injections of nano silver materials in rats, this may indicate a partial inactivation of enzyme activity or a reduction of enzyme production (36), while a different study by Shrivastava *et al.* (37) indicated the possibility of nano silver materials affecting the activity of transaminase enzymes, the liver was identified as one of the significant locations and target organ for the accumulation of the nanoparticles (35,36).

The current research confirmed cardiotoxicity and hepatotoxicity by nano silver materials The results showed that nano silver materials can cause histological alteration in hepatic tissue and cardiomyocytes following the I/P injection and the severity of these histological alterations depends on the doses of nano silver materials the histological alteration of hepatic tissue was more severe than the others.it

characterized by degenerative necrotic and inflammatory reactions in addition to vascular responses This means that nano silver materials cause hepatotoxic effects these results were also reported by Tang *et al.* (38). The hepatotoxicity occur as a result of the production of free radicals which then cause oxidative stress (39). Liver is one of the most fundamental targets of the oxidative stress due to delayed clearance of nanoparticles stored in the liver which cause production of free radicals, then there will be infiltration and accumulation of phagocytic cells in the liver (40). More over the I/P injection of nano silver materials also cause histological alteration in the myocardial muscle which characterized by cardiomyopathy, by presence of focal area of necrosis accompanied by hemorrhage edema with inflammatory cells infiltration this occur as a results of nano silver materials toxic effects due to the release of silver ions (41), this will cause cellular toxicity and oxidative stress silver ions induce inflammatory reactions (41). These results agree with the findings of researchers Kim *et al.* (27) who showed that the different doses of nano silver materials cause toxic effects after oral administration on the liver, kidney, heart and spleen Also, the same results were reported by Samberg *et al.* (42) nano silver materials affect the myocardial muscle because nano silver materials promoted the persistent vasoconstriction of the myocardial muscle this will lead to the increase in the release of ROS then could be oxidative stress medication (42). Others showed that the nano silver materials have direct effects and not caused by Ag ions and ROS, membrane injury they noticed that nano silver materials have a direct effect on ion channels at Nano balance (43).

Metallic nano silver materials have widespread medical and industries application. This will lead to an excess of dangerous mammalian exposure to nano silver materials which cause a toxic effect on pivotal organs such as the respiratory, digestive, vascular, and hepatobiliary systems (44). The hematological results showed a distinction in the RBCs, Hb, PCV, Total WBCs, granulocytes, lymphocytes, MCH, MCV, and MCHC in treated groups compared with the control group. This distinction may indicate that nano silver material affects the hemoglobin, synthesis, and maturation of RBCs in the bone marrow. These results are also reported by Al-Baker *et al.* (10). Moreover, the I/P injection of nano silver materials interacts with the blood and its constituent, which will cause an immunogenic response and alteration in the hematological parameters, WBCs, Platelets, etc. (45), due to disturbances in the maturation and signaling pathways of the cells which can affect RBCs and the development of the other cells (46,47). Concerning the morphology of RBCs, we found abnormal shapes of RBCs. This occurs as a result of problems with bone marrow function. In addition, RBCs in the bone marrow make enough hemoglobin, leading to hypochromic RBCs .

The cytotoxic effect of nano silver material is linked to free radical formation, which causes a change in cell shape

(22). These results agreed with Al-Baker *et al.* (10). The body weight of the treated animals showed a gradual decrease with time relative to the control group. This happens perhaps as a consequence of alteration in the function and metabolic rate of the body organs; there may be a decrease in the metabolic rate of a response to the treatment with nano silver material (27).

It was shown by Abdelhalim and Moussa (12) that the treatment with nano silver material showed no change in body weight.

The decrease in body weight may be a symptom of any toxic effect of nano silver materials. A previous study showed a change in body weight due to toxicity induced by drugs or chemical substances (33) regarding the effect of nano silver materials on liver enzymes. This study showed that the treatment with nano silver materials caused an increase in the level of ALT and AST compared to the control group. This occurs due to the accumulation of several nanomaterials in the liver, which is the target organ and dominant site of the accumulation of nanoparticles (35,36), also reported by Shrivastava *et al.* (37).

## Conclusion

The goal of this study is to investigate the harmful effects of metabolic nano silver materials, and we found that all doses of nano silver materials used in this study affected the physical altitude of treated animals, disturbances in the histology and function of the liver and heart, as well as disorganization of blood parameters also observed in this research.

## Acknowledgments

The authors thank the University of Mosul and the college of veterinary medicine for supporting our study.

## Conflict of interest

The authors declare that they have no conflict of interest.

## References

- Naiwa HS. Handbook of nanostructural materials and nanotechnology. New York: Academic Press; 2000. 1-5 p.
- Song JY, Kim BS. Biological synthesis of bimetallic Au/Ag nanoparticles using persimmon (*Diopyros kaki*) leaf extract. Korean J Chem Eng. 2008;25(4):808-811. DOI: [10.1007/s11814-008-0133-z](https://doi.org/10.1007/s11814-008-0133-z)
- Ali ZS, Khudair KK. Synthesis, characterization of silver nanoparticles using *Nigella sativa* seeds and study their effects on the serum lipid profile and DNA damage on the rats' blood treated with hydrogen peroxide. Iraqi J Vet Med. 2022;43(2):23-37. [\[available at\]](#)
- Wen H, Dan M, Yang Y, Lyu J, Shao A, Cheng X, Chen L, Xu L. Acute toxicity and genotoxicity of silver nanoparticle in rats. PloS One. 2017;12(9):e0185554. DOI: [10.1371/journal.pone.0185554](https://doi.org/10.1371/journal.pone.0185554)
- Oberdörster G. Safety assessment for nanotechnology and nanomedicine: Concepts of nanotoxicology. J Intern Med. 2010;267(1):89-105 DOI: [10.1111/j.1365-2796.2009.02187.x](https://doi.org/10.1111/j.1365-2796.2009.02187.x)
- Park EJ, Bae E, Yi J, Kim Y, Choi K, Lee SH, Yoon J, Lee BC, Park K. Repeated-dose toxicity and inflammatory responses in mice by oral administration of silver nanoparticles. Environ Toxicol Pharmacol. 2010;30:162-168. DOI: [10.1016/j.etap.2010.05.004](https://doi.org/10.1016/j.etap.2010.05.004)
- Yousof SM, Erfan H, Hosny MM, Shehata SA, El-Sayed K. Subacute toxic effects of silver nanoparticles oral administration and withdrawal on the structure and function of adult albino rats' hepatic tissue. Saudi J Biologic Sci. 2022;29(5):3890-3898. DOI: [10.1016/j.sjbs.2022.02.054](https://doi.org/10.1016/j.sjbs.2022.02.054)
- Tang J. Status of biological evaluation on silver nanoparticles. J Biomed Eng. 2008;25:958-961. [\[available at\]](#)
- Culling CF, Allison RT, Barr WT. Cellular pathology technique. 4<sup>th</sup> ed. New York: Butterworth; 1985. 642 p.
- Ismail HK, Abdullah OA. Pathological and bacteriological study of bovine renal lesions slaughtered in Mosul region. Iraqi J Vet Sci. 2017;2(31):51-56. DOI: [10.33899/ijvs.2017.145565](https://doi.org/10.33899/ijvs.2017.145565)
- Kumar P, Clark M. Clinical medicine. 5<sup>th</sup> ed. London: WB Saunders Company; 2003. 592 p.
- Murray R. Aspartate aminotransferase. St Louis: The CV Mosby Co; 1984.
- AL-Baker A, AIKshab AA, Ismail HK. Effect of silver nanoparticles on some blood parameters in rats. Iraqi J Vet Sci. 2020;34(2):389-95. DOI: [10.33899/ijvs.2020.165812](https://doi.org/10.33899/ijvs.2020.165812)
- Ismail HK, AIKshab AA, AL-Baker AA. Effect of orally-administered silver nanoparticles (Ag-NPs) on some biochemical parameters in kidney of rats. Indian J Med Forensic Med Toxicol. 2020;14(4):1733. DOI: [10.37506/ijfmt.v14i4.11793](https://doi.org/10.37506/ijfmt.v14i4.11793)
- Reddy MV. Statistical methods in psychiatry research and SPSS. Oakville: Apple Academic Press; 2019. 336 p.
- Abdelhalim MA, Moussa SA. The dimensional hematological alterations induced in the blood of rats in vivo by intraperitoneal administration of gold nanoparticles. J Nanomed Nanotechnol. 2012;3(4):138. DOI: [10.4172/2157-7439.1000138](https://doi.org/10.4172/2157-7439.1000138)
- Zhang XD, Wu HY, Wu D, Wangm YY, Chang JH, Zhai Z, Meng A, Liu P, Zhang L, Fan F. Toxicological effects of gold nanoparticles in vivo by different administration routes. Int J Nanomed. 2010;5:771-781. DOI: [10.2147/ijn.s8428](https://doi.org/10.2147/ijn.s8428)
- Hauck TS, Anderson RE, Fischer HC, Newbigging S, Chan WC. In vivo quantum-dot toxicity assessment. Small. 2010;6(1):138-144. DOI: [10.1002/smll.200900626](https://doi.org/10.1002/smll.200900626)
- Rajendoran V, Krishnaswamy K. Effect of *Solanum villosum* extract and its silver nanoparticles on hematopoietic system of diethylnitrosamine-induced hepatocellular carcinoma in rats. Innovare J Health Sci. 2017;5(1):13-16. [\[available at\]](#)
- Guyton CA, Hall JE. Textbook of medical physiology. 10<sup>th</sup> ed. London: Academic Press; 2000. 730-801 p.
- Gjetting T, Arildsen NS, Christensen CL, Poulsen TT, Roth JA, Handlos VN, Poulsen HS. In vitro and in vivo effects of polyethylene glycol (PEG)-modified lipid in DOTAP/cholesterol-mediated gene transfection. Int J Nanomed. 2010;5:371. DOI: [10.2147/ijn.s10462](https://doi.org/10.2147/ijn.s10462)
- Dobrovoiskaia MA, Clogston JD, Neun BW, Hall JB, Patri AK, McNeil SE. Method for analysis of nanoparticle hemolytic properties in vitro. Nano Lett. 2008;8:2180-2187. DOI: [10.1021/nl0805615](https://doi.org/10.1021/nl0805615)
- Savage DG, Ogundipe A, Allen RH, Stabler SP, Lindenbaum J. Etiology and diagnostic evaluation of macrocytosis. Am J Med Sci. 2000;319(6):343-352. DOI: [10.1016/s0002-9629\(15\)40772-4](https://doi.org/10.1016/s0002-9629(15)40772-4)
- Ajdary M, Moosavi MA, Rahmati M, Falahati M, Mahboubi M, Mandegary A, Jangjoo S, Mohammadinejad R, Varma RS. Health concerns of various nanoparticles: A review of their in vitro and in vivo toxicity. Nanomaterials. 2018;8(9):634. DOI: [10.3390/nano8090634](https://doi.org/10.3390/nano8090634)
- Keren DF, Perkins SL, Piscitelli JB, Rizzo KA, Shier LR, Wong AK, Zwick DL, Eberie C, Girgis GM, Salansky S. Hematology, clinical microscopy, and body fluids glossary. USA: College of American Pathologists; 2012. 1-64 p.
- Morones JR, Elechinguerra JL, Camacho A, Holt K, Kouri JB, Ramirez JT, Yacamán MJ. The bacterial effect of silver nanoparticles. Nanotechnol. 2005;16(10):2346-2353. DOI: [10.1088/0957-4484/16/10/059](https://doi.org/10.1088/0957-4484/16/10/059)

27. Nirmala R, Sheikh FA, Kanjwal MA, Lee JH, Park SJ, Navamathavan R, Kim HY. Synthesis and characterization of bovine femur bone hydroxyapatite containing silver nanoparticles for biomedical applications. *J Nanoparticle Res.* 2011;13(5):1917-1927. DOI: [10.1007/s11051-010-9944-z](https://doi.org/10.1007/s11051-010-9944-z)
28. Mocan T, Clichici S, Agoston CL, Simon S, Ilie, IR, Biris AR, Muresan A. Implication of oxidative stress mechanisms in toxicity of nanoparticles. *Acta Physiol Hung.* 2010;97(3):247-255. DOI: [10.1556/Aphysiol.97.2010.3.1](https://doi.org/10.1556/Aphysiol.97.2010.3.1)
29. Chen LQ, Fang L, Ling J, Ding CZ, Kang B, Huang CZ. Nanotoxicity of silver nanoparticles to red blood cell, size dependent adsorption, uptake, and hemolytic activity. *Chem Res Toxicol.* 2015;28(3):501-509. DOI: [10.1021/tx500479m](https://doi.org/10.1021/tx500479m)
30. Mandeep SB. Nanotoxicity in systemic circulation and wound healing. *Chem Res Toxicol.* 2017;30(6):1253-1274. DOI: [10.1021/acs.chemrestox.7b00068](https://doi.org/10.1021/acs.chemrestox.7b00068)
31. Sarhan OM, Hussein RM. Effects of intraperitoneally injected silver nanoparticles on histological structures and blood parameters in the albino rat. *Int J Nanomed.* 2014;9:1505-1517. DOI: [10.2147/ijn.s56729](https://doi.org/10.2147/ijn.s56729)
32. Kim YS, Song MY, Park JD, Song KS, Ryu HR, Chung YH, Chang HK, Lee JH, Oh KH, Kelman BJ, Hwang IK. Subchronic oral toxicity of silver nanoparticles. *Part Fibre Toxicol.* 2010;7(1):1-1. DOI: [10.1186/1743-8977-7-20](https://doi.org/10.1186/1743-8977-7-20)
33. Abood HM. Histopathological and immunohistochemical study of the effect of silver nanoparticles and moringa on the liver and kidneys of male rabbits treated with a high cholesterol diet [master's thesis]. Karbala: College of Science, University of Karbala; 2021.
34. Sulaiman FA, Adeyemi OS, Akanji MA, Oloyede HO, Sulaiman AA, Olatunde A, Hoseni AA, Olowolafe YV, Nlebedim RN, Muritala H, Nafiu MO. Biochemical and morphological alterations caused by silver nanoparticles in Wistar rats. *J Acute Med.* 2015;5(4):96-102. DOI: [10.1016/j.jacme.2015.09.005](https://doi.org/10.1016/j.jacme.2015.09.005)
35. Egbuna C, Ifemeje JC, Nwaka AC, Olisah MC, Lukong CB, Patrick-Iwuanyanwu KC, Ifemeje MO, Iheukwumere IH, Iheukwumere CM. Blood glucose level and serum lipid profile of Wistar albino rats fed four species of local beans consumed in south-east Nigeria. *Eur J Biomed.* 2020;7(5):30-39. [\[available at\]](#)
36. Luaibi NM, Qassim HA. Effect of silver nanoparticles (AgNps) on rats body weight. *Biochem Cell Arch.* 2018;18(1):137-139. [\[available at\]](#)
37. Tang MS, Wettach GR, Eby CS. Evaluation of a patient with highly high mean corpuscular hemoglobin and mean corpuscular hemoglobin concentration. *Clin Chem.* 2020;66(3):497-498. DOI: [10.1093/clinchem/hvz036](https://doi.org/10.1093/clinchem/hvz036)
38. Ahamed M, Posgai R, Gorey TJ, Nielsen M, Hussain SM, Rowe JJ. Silver nanoparticles induced heat shock protein 70, oxidative stress and apoptosis in *Drosophila melanogaster*. *Toxicol Appl Pharmacol.* 2010;242(3):263-269. DOI: [10.1016/j.taap.2009.10.016](https://doi.org/10.1016/j.taap.2009.10.016)
39. Yildirim L, Thanh NT, Loizidou M, Seifalian AM. Toxicology and clinical potential of nanoparticles. *Nano Today.* 2011;6(6):585-607. DOI: [10.1016/j.nantod.2011.10.001](https://doi.org/10.1016/j.nantod.2011.10.001)
40. Adeyemi OS, Sulaiman FA. Co-administration of iron sulfate and nitroglycerin promoted oxidative stress and mild tissue damage in Wistar rats. *Comp Clin Pathol.* 2014;23(5):1525-1533. DOI: [10.1007/s00580-013-1817-2](https://doi.org/10.1007/s00580-013-1817-2)
41. Shrivastava S, Bera T, Singh SK, Singh G, Ramachandrarao P, Dash D. Characterization of antiplatelet properties of silver nanoparticles. *ACS Nano.* 2009;3:1357-1364. DOI: [10.1021/nn900277t](https://doi.org/10.1021/nn900277t)
42. Tang J, Xiong L, Wang S, Wang J, Liu L, Li J, Yuan F, Xi T. Distribution, translocation and accumulation of silver nanoparticles in rats. *J Nanosci Nanotechnol.* 2009;9(8):4924-4932. DOI: [10.1166/jnn.2009.1269](https://doi.org/10.1166/jnn.2009.1269)
43. Folkmann JK, Risom L, Jacobsen NR, Wallin H, Loft S, Møller P. Oxidatively damaged DNA in rats exposed by oral gavage to C60 fullerenes and single-walled carbon nanotubes. *Environ Health Perspect.* 2009;117(5):703-708. DOI: [10.1289/ehp.11922](https://doi.org/10.1289/ehp.11922)
44. Unfried K, Albrecht C, Klotz LO, Von Mikecz A, Grether-Beck S, Schins RP. Cellular responses to nanoparticles: Target structures and mechanisms. *Nanotoxicol.* 2007;1(1):52-71. DOI: [10.1080/00222930701314932](https://doi.org/10.1080/00222930701314932)
45. Kim WY, Kim J, Park JD, Ryu HY, Yu JJ. Histological study of gender differences in accumulation of silver nanoparticles in kidneys of Fischer 344 rats. *J Toxicol Environ Health.* 2009;72(21-22):1279-1284. DOI: [10.1080/15287390903212287](https://doi.org/10.1080/15287390903212287)
46. Samberg ME, Oldenburg SJ, Monteiro-Riviere NA. Evaluation of silver nanoparticle toxicity in skin in vivo and keratinocytes in vitro. *Environ Health Perspect.* 2010;118(3):407-413. DOI: [10.1289/ehp.0901398](https://doi.org/10.1289/ehp.0901398)
47. Ramirez-Lee MA, Espinosa-Tanguma R, Mejía-Elizondo R, Medina-Hernández A, Martínez-Castañón GA, González C. Effect of silver nanoparticles upon the myocardial and coronary vascular function in isolated and perfused diabetic rat hearts. *Nanomed: Nanotechnol Biol Med.* 2017;13(8):2587-2596. DOI: [10.1016/j.nano.2017.07.007](https://doi.org/10.1016/j.nano.2017.07.007)

## التغيرات الدموية والكيميائية الحيوية والنسجية التي تحدثها مادة الفضة النانوية على ذكور الجرذان

أنعام عناد الجبوري<sup>1</sup>، هناء خليل اسماعيل<sup>2</sup>، لمى وليد خليل<sup>3</sup> و عبير عطا الله ايايد الحديدي<sup>3</sup>

<sup>1</sup> فرع الفلسفة والكيمياء الحياتية، كلية الطب البيطري، جامعة بغداد، بغداد، <sup>2</sup> فرع الأمراض وأمراض الدواجن، كلية الطب البيطري، <sup>3</sup> قسم علوم الحياة، كلية العلوم، جامعة الموصل، الموصل، العراق

### الخلاصة

هدفت هذه الدراسة إلى دراسة تأثير حقن في الخلب لمادة دقائق الفضة النانوية حيث كانت بجرعة 0,2,4,6,8,10,12,14,16,18,20,22,24,26,28,30,32,34,36,38,40,42,44,46,48,50,52,54,56,58,60,62,64,66,68,70,72,74,76,78,80,82,84,86,88,90,92,94,96,98,100 ملغم / كغم من وزن الجسم لمدة 21 يوماً على معايير الدم والأنسجة القلبية والكبدية ووظائفها. أظهرت النتائج أن هناك زيادة معنوية في معايير الدم للحيوانات المعالجة بالمقارنة مع مجموعة السيطرة. أظهرت الدراسة النسجية للعينات المأخوذة من المجاميع المختلفة أن التغير النسجي يكون أكثر وضوحاً في الحيوانات المعالجة بجرعة 6, 10, 16 ملغم / كغم من وزن الجسم. حيث امتازت هذه التغيرات بتفاعل التهابي مع تنكس ونخر لخلايا الكبد، في حين أظهر الفحص النسجي لعينات عضلة القلب تغيرات عديدة تمثلت باحتقان عام في الشعيرات الدموية وتنكس ونخر لخلايا عضلة القلب مع تفاعل التهابي. تم الاستنتاج من هذه الدراسة أن المواد النانوية لها تأثير سام للخلايا واضح على التركيب النسجي للكبد والقلب وكذلك على وظيفة هذه الأعضاء بالإضافة إلى تأثيرها على معايير الدم مثل الهيموغلوبين وكريات الدم البيض وعدد الصفيحات الدموية وكريات الدم الحمر وحجم الكرية الوسطي وهيموغلوبين الكرية الوسطي وتركيز هيموغلوبين الكرية الوسطي.