



The protective impacts of lipoic acid on diclofenac-induced hepatorenal toxicity in broiler chicks

M.R. Abdul-Ghani^{ID} and A.S. Naser^{ID}

Department of Physiology, Biochemistry and Pharmacology, College of Veterinary Medicine, University of Mosul, Mosul, Iraq

Article information

Article history:

Received January 29, 2022

Accepted May 8, 2022

Available online September 9, 2022

Keywords:

Diclofenac

Liver damage

Broiler chicks

Alpha-lipoic acid

Correspondence:

A.S. Naser

ahmadphd0@gmail.com

Abstract

Alpha-lipoic acid is an anti-inflammatory and antioxidant compound that shows free radical scavenging actions and potent antioxidant properties on the metabolites of other cellular oxidants. The investigation of the defensive activity of alpha-lipoic acid (ALA) counter to diclofenac triggered liver and kidney damage in broiler chicks was the goal of this research. Chicks (7 days old) were distributed into four groups of six chicks each. The first group was the control received propylene glycol, the second group was injected intraperitoneally with Alpha-lipoic acid 80 mg/kg, the third group was injected intraperitoneally with diclofenac sodium at a dose of 2 mg/kg, and the fourth group was treated with ALA at 80 mg/kg and diclofenac at 2 mg/kg together. The trial continued for seven days. One day after the latest treatment, all the chicks were sacrificed by cutting jugular veins; blood samples were taken for biochemical analysis. Diclofenac causes a significant increase in ALT, AST, creatinine, and urea, while the coadministration of ALA with Diclofenac caused a significant decrease in ALT, AST, Creatinine, and Uric acid. Alpha-lipoic acid may benefit from counteracting diclofenac-induced hepatorenal toxicity due to antioxidant effects.

DOI: [10.33899/ijvs.2022.132915.2148](https://doi.org/10.33899/ijvs.2022.132915.2148), ©Authors, 2022, College of Veterinary Medicine, University of Mosul.

This is an open access article under the CC BY 4.0 license (<http://creativecommons.org/licenses/by/4.0/>).

Introduction

Several recent studies have proven that one of the NSAIDs (nonsteroidal anti-inflammatory drugs), diclofenac, is directly related to the catastrophic decay in the numbers of three species of vultures in India. Although it is not licensed for veterinary uses, other types of other NSAIDs are used as anti-inflammatory, fever-reducing, and analgesic (1). Diclofenac exerts its effect through its mechanism of action by reversible inhibiting cyclooxygenase enzyme (Cox1 and Cox2), which subsequently diminish the production of the inducible and housekeeping prostaglandins (2). NSAIDs have many side effects during acute and chronic use, summarized as liver toxicity, kidney toxicity, GIT toxicity, and cardiovascular problem (3). The metabolism of diclofenac in humans and animals is accomplished through

the liver by two major pathways (Glucoronidation and Hydroxylation) (4). The exact cause for the decrease in vultures was subsequent consumption of dead cattle injected with diclofenac. These types of vultures are now in danger of disappearance. The researchers endorsed the diclofenac toxicity in vultures due to the kidney's extreme toxicity, which is manifested by necrosis of all renal tissues (5). Alpha-lipoic acid is the linking thread between the term medicines and the term supplements (6). It is naturally synthesized in plant and animal tissues (7), and it is synthesized and used as an anti-inflammatory and antioxidant (8). It is used as a free radicals scavengers (9). It is an essential mechanism in treating oxidative stress, and it is used in the poultry industry by adding it to the diet (10). It is used in humans to treat the side effects of diabetes (11), especially neuropathy, and in the treatment of cardiovascular

diseases (12), especially in the treatment of strokes, cancer, and some skin diseases (13). Alpha-lipoic acid possesses an analgesic for acute pain (14), anti-granuloma, antipyretic (15) and depressant effects on the central nervous system in chicks model (16). Recent study has showed that the peak of its effect was after 60 minutes of administration in broiler chicks (17).

Through research and investigation, we did not find any reports about the effect of alpha-lipoic acid on the kidney and liver hurt of diclofenac. Therefore, we examined the defensive effects of ALA on Diclofenac-induced hepatotoxicity and renal toxicity in broiler chicks by biochemical analysis.

Materials and methods

Animals

Unvaccinated one-day-old chicks were brought and raised to the seventh day of their life. Forage and water were provided continuously. The birds were raised in the laboratory animal house department of the College of Veterinary Medicine, University of Mosul.

Drugs and Chemicals

Alpha-lipoic acid (capsule 600 mg) produced by America medic and science, USA. Propylene glycol 99.5% produced by Thomas Baker, India. Diclofenac 75 mg/3 ml ampoule produced by Unique Pharma Lab, India.

Ethical approval

The approval was obtained by the Scientific Council of the Faculty of Physiology, Biochemistry, and Pharmacology at the Faculty of Mosul's College of Veterinary Medicine and is a component of a master's thesis.

Experimental design

When chicks reached 7 days old, the chicks were randomly distributed into four groups: Each group had six chicks, and the management strategy involved a sole dose/day for 7 repeated days. Group 1: treated with propylene glycol through i.p. Group 2: treated with ALA at 80 mg/kg intraperitoneally. Group 3: treated with diclofenac at 2 mg/kg intraperitoneally. Group 4: treated with ALA at 80 mg/kg IP and diclofenac at 2 mg/kg intraperitoneally. The trial continued for 7 days. One day after the latest treatment, all the chicks were sacrificed by cutting a jugular vein, followed by blood collection for serum biochemical analysis

(alanine aminotransferase, aspartate aminotransferase, urea, and creatinine).

Statistical analysis

We used the SPSS program to analyze the parametric data, where we used the (One-way analysis of variance ANOVA) test, and then the least significant difference LSD test was applied to it. The difference level for all tests was at a probability level of ≤ 0.05 . The values were presented as the mean \pm SE.

Results

By measuring the activity of alanine transaminase, it was observed that there was a significant increase in ALT activity in the group injected with diclofenac at a 2 mg/kg Ip for seven consecutive days as compared to the first group in (Figure 1), which indicates the occurrence of liver damage. A significantly decreased ALT activity was detected in the Alpha-lipoic acid and diclofenac group compared with the diclofenac group alone, indicating that alpha-lipoic acid can reduce liver damage caused by diclofenac (Table 1). Simultaneous injection of alpha-lipoic acid at 20 mg/kg of body weight intraperitoneally and diclofenac at a 2 mg/kg of body weight intraperitoneally caused a significant decrease in the concentration activity of aspartate aminotransferase as compared to the group injected with diclofenac alone at 2 mg/kg of body weight intraperitoneally (Figure 2 and Table 1). The injection of diclofenac at 2 mg/kg of body weight intraperitoneally led to a significantly increased in creatinine level after seven days of injection in comparison to the control group, which indicates the damaging outcome of diclofenac on the kidney tissues, while a significant decrease in creatinine concentration was observed in the group treated with alpha acid (Table 2 and Figure 3). Lipoic and diclofenac together, compared to the diclofenac group alone, indicates that alpha-lipoic acid can reduce the harmful effect of diclofenac on the kidneys. Whereas injecting chicks with ALA at 20 mg/kg body weight for a week led to a significant decrease in urea concentration compared to the first and fourth groups. Moreover, injecting chicks with diclofenac at 2 mg/kg for a week led to a significant increase in urea concentration in comparison to the 2nd group and 4th group, the simultaneous injection of ALA and diclofenac had a significant lowering effect on urea levels in comparison to the control group and the 3rd group (Figure 4).

Table 1: The influence of ALA and diclofenac on alanine aminotransferase and aspartate aminotransferase

Parameters	Control	ALA	DIC	ALA+DIC
ALT	43.2 \pm 3.73a	41.6 \pm 1.04a	46.6 \pm 2.70c	38.7 \pm 1.75a
AST	100.2 \pm 6.62a	101.0 \pm 6.69a	134.8 \pm 4.59bcd	103.2 \pm 6.80a

At $P \leq 0.05$ significance, data in each row accompanied by different superscript letters are significantly dissimilar.

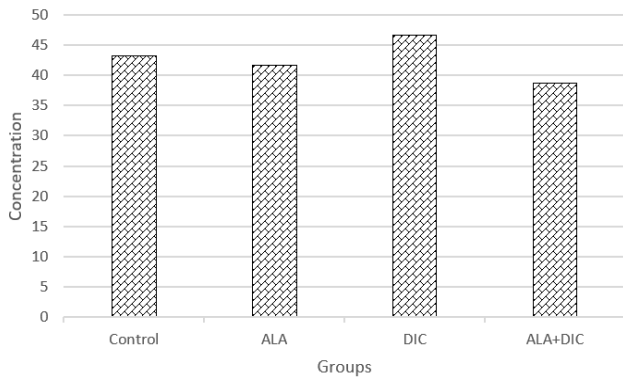


Figure 1: The influence of ALA and diclofenac on ALT.

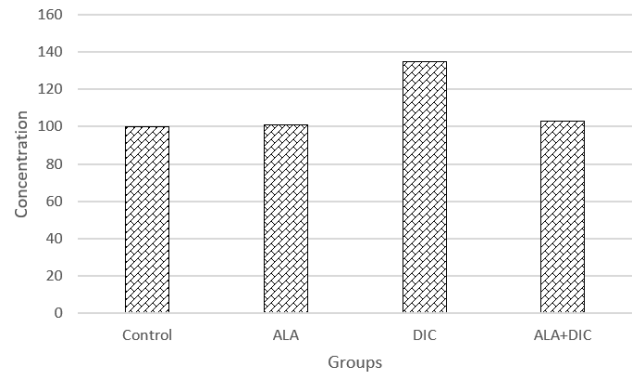


Figure 2: The influence of ALA and diclofenac on AST.

Table 2: The influence of ALA and diclofenac on serum urea and creatinine

Parameters	Control	ALA	DIC	ALA+DIC
Creatinine	1.20±0.02a	1.10±0.02b	1.22±0.03bc	1.15±0.02a
Urea	5.38±0.23a	3.61±0.23b	6.15±0.16bc	4.42±0.47bc

At $P \leq 0.05$ significance, data in each row accompanied by different superscript letters are significantly dissimilar.

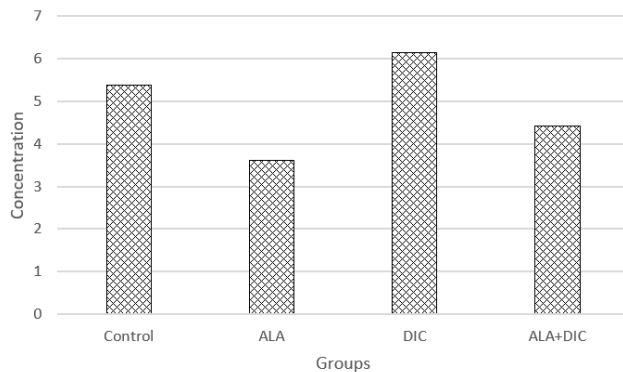


Figure 3: The influence of ALA and diclofenac on urea.

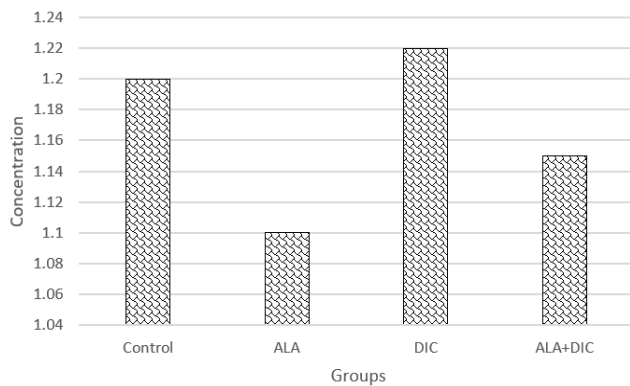


Figure 4: The influence of ALA and diclofenac on creatinine.

Discussion

The chick model is one of the essential experimental models in the life sciences; it has been used in analgesia (18), neurobehavioral experiments (19), and toxicological studies. Diclofenac sodium-induced increased ALT and AST activity in a dose-dependent manner. This indicates that liver injury is coherent with Saran's findings of an increase in Alanine aminotransferase and Aspartate aminotransferase activity in chicks injected with diclofenac (20). Hepatotoxicity has been associated with the therapeutic use of NSAIDs, and among these drugs, diclofenac appears as the drug with the most adverse effects on the liver (21). Oxidative stress is one of the most critical pathways closely related to the pathophysiology of tissue damage, and diclofenac has been shown to promote oxidative stress in the hepatic tissues (22). Diclofenac undergoes bioactivation, resulting in the responsive intermediate byproducts 4-OH and 5-OH diclofenac, then hydrolyzed by the CYP2C9 and CYP3A4 enzymes (23). The byproduct of diclofenac could be a trigger to apoptosis pathways of liver tissues (24). The toxicity of diclofenac on renal tissue was determined in a study conducted on four species of birds, and of these birds that were used in that experiment were pigeons and chicks, where visceral gout was seen in chicks and pigeons treated with diclofenac (25). The lesions were similar to those on Dead vultures due to natural or experimental poisoning with diclofenac (26). In diclofenac toxicity studies in vultures, there is an increase in serum uric acid concentration (27).

Our finding reveals a significant rise in the activity of alanine aminotransferase and creatinine concentration and a

slight rise in the activity of aspartate transporter enzyme and urea concentration in the blood plasma of chicks treated with diclofenac for seven consecutive days was observed, which indicates the occurrence of liver and kidney damage and this result agrees with Albadrany who reached the same conclusion (27). When diclofenac and alpha-lipoic acid were combined, our results showed a decline in alanine aminotransferase, aspartate transaminase, creatinine, and urea concentrations. Alpha-lipoic acid is an antioxidant through many of the mechanisms that have been previously explained. Our study agrees with previous studies on the protection provided by alpha-lipoic acid against hepatic damage induced by galactosamine and polysaccharides (28). A study conducted in rats also had a defensive consequence of alpha-lipoic acid against the liver damage induced by cisplatin (29).

Conclusion

In chick models, our results indicate that ALA can guard the liver and kidney against diclofenac-induced injury. Because of its antioxidant and anti-inflammatory properties, ALA may be beneficial in treating Diclofenac-induced liver and kidney damage.

Acknowledgment

This study was carried out with direct support from the Deanship of the College of Veterinary Medicine, University of Mosul.

Conflict of interest

Not applicable

References

1. Anderson MD, Piper SE, Swan GE. Nonsteroidal anti-inflammatory drug use in South Africa and possible effects on vultures: News and views. *S Afr J Sci*. 2005;101(3):112-4. DOI: [10.1098/rsbl.2006.0554](https://doi.org/10.1098/rsbl.2006.0554)
2. Lees P, Landoni MF, Giraudel J, Toutain PL. Pharmacodynamics and pharmacokinetics of nonsteroidal anti-inflammatory drugs in species of veterinary interest. *J Vet Pharmacol Ther*. 2004;27(6):479-90. DOI: [10.1111/j.1365-2885.2004.00617.x](https://doi.org/10.1111/j.1365-2885.2004.00617.x)
3. Singh G. Recent considerations in nonsteroidal anti-inflammatory drug gastropathy. *Am J Med*. 1998;105(1):31S-38S. DOI: [10.1016/s0002-9343\(98\)00072-2](https://doi.org/10.1016/s0002-9343(98)00072-2)
4. Kumar S, Samuel K, Subramanian R, Braun MP, Stearns RA, Chiu S-HL. Extrapolation of diclofenac clearance from in vitro microsomal metabolism data: role of acyl glucuronidation and sequential oxidative metabolism of the acyl glucuronide. *J Pharmacol Exp Ther*. 2002;303(3):969-78. DOI: [10.1124/jpet.102.038992](https://doi.org/10.1124/jpet.102.038992)
5. Swan GE, Cuthbert R, Quevedo M, Green RE, Pain DJ, Bartels P. Toxicity of diclofenac to Gyps vultures. *Biol Lett*. 2006;2(2):279-82. DOI: [10.1098/rsbl.2005.0425](https://doi.org/10.1098/rsbl.2005.0425)
6. Nicolson GL. Mitochondrial dysfunction and chronic disease: treatment with natural supplements. *Integr Med A Clin J*. 2014;13(4):35. PMID: [26770107](https://pubmed.ncbi.nlm.nih.gov/26770107/)
7. Laher I. Diabetes and alpha-lipoic acid. *Front Pharmacol*. 2011;2:69. DOI: [10.3389/fphar.2011.00069](https://doi.org/10.3389/fphar.2011.00069)
8. Tibullo D, Volti GL, Giallongo C, Grasso S, Tomassoni D, Anfuso CD. Biochemical and clinical relevance of alpha-lipoic acid: antioxidant and anti-inflammatory activity, molecular pathways and therapeutic potential. *Inflammation Res*. 2017;66(11):947-59. DOI: [10.1007/s00011-017-1079-6](https://doi.org/10.1007/s00011-017-1079-6)
9. Shay KP, Moreau RF, Smith EJ, Smith AR, Hagen TM. Alpha-lipoic acid as a dietary supplement: molecular mechanisms and therapeutic potential. *Biochim Biophys Acta*. 2009;1790(10):1149-60. DOI: [10.1016/j.bbagen.2009.07.026](https://doi.org/10.1016/j.bbagen.2009.07.026)
10. Sohaib M, Anjum FM, Nasir M, Saeed F, Arshad MS, Hussain S. Alpha-lipoic acid: An inimitable feed supplement for poultry nutrition. *J Anim Physiol Anim Nutr*. 2018;102(1):33-40. DOI: [10.1111/jpn.12693](https://doi.org/10.1111/jpn.12693)
11. Packer L, Tritschler HJ, Wessel K. Neuroprotection by the metabolic antioxidant α -lipoic acid. *Free Radic Biol Med*. 1997;22(1-2):359-78. DOI: [10.1016/s0891-5849\(96\)00269-9](https://doi.org/10.1016/s0891-5849(96)00269-9)
12. Mitsui Y, Schmelzer JD, Zollman PJ, Mitsui M, Tritschler HJ, Low PA. Alpha-lipoic acid provides neuroprotection from ischemia-reperfusion injury of peripheral nerve. *J Neurol Sci*. 1999;163(1):11-6. DOI: [10.1016/s0022-510x\(99\)00017-9](https://doi.org/10.1016/s0022-510x(99)00017-9)
13. Podda M, Zollner TM, Grundmann M, Thiele JJ, Packer L, Kaufmann R. Activity of alpha-lipoic acid in the protection against oxidative stress in skin. *Curr Probl Dermatol Basel*. 2001;29:43-51. DOI: [10.1159/000060652](https://doi.org/10.1159/000060652)
14. Abdul-gani MR, Naser AS. Assessment of the analgesic effect of Alpha-lipoic acid by three acute pain models. *Iraqi J Vet Sci*. 2022;36(3):803-7. DOI: [10.33899/ijvs.2022.132184.2062](https://doi.org/10.33899/ijvs.2022.132184.2062)
15. Abdul-Ghani MR. Bakers' yeast Induced Paw Edema and Fever in Chicks for Detection of Anti-inflammatory Effects of Alpha-lipoic Acid: A new Approach. *Egypt J Vet Sci*. 2022;53(2):185-91. DOI: [10.21608/ejvs.2022.107080.1314](https://doi.org/10.21608/ejvs.2022.107080.1314)
16. Abdul-Ghani M, Naser A. Determination of Central Nervous Effect and Antidotal Effect Against Chlorpyrifos Toxicity of Alpha-Lipoic Acid Through Pharmacological and Toxicological Challenges. *SVU-International J Vet Sci*. 2022;5(2):23-30. DOI: [10.21608/svu.2022.125628.1181](https://doi.org/10.21608/svu.2022.125628.1181)
17. Abdulghani M, Naser A. Estimation of pharmacokinetic parameters of alpha-lipoic acid in the chicks model. *Baghdad J Biochem Appl Biol Sci*. 2022;3. DOI: [org/10.47419/bjbabs.v3i02.91](https://doi.org/10.47419/bjbabs.v3i02.91)
18. Albadrany YM, Naser AS, Hasan MM. Study the analgesic effect of diclofenac and silymarin coadministration in chicks. *Iraqi J Vet Sci*. 2021;35(Suppl I-III):25-31. DOI: [10.33899/ijvs.2021.127065.1453](https://doi.org/10.33899/ijvs.2021.127065.1453)
19. Naser AS, Albadrany YM. The neurobehavioral effects of flumazenil in chicks. *Iraqi J Vet Sci*. 2021;35(4):783-788. DOI: [10.33899/ijvs.2020.128443.1577](https://doi.org/10.33899/ijvs.2020.128443.1577)
20. Saran RP, Purohit A, Ram H. A comparative pathophysiological study of diclofenac and meloxicam induced toxicity in Gallus domestics. *Am J Pharm Heal Res*. 2016;4(11):71-84.
21. Unzueta A, Vargas HE. Nonsteroidal anti-inflammatory drug-induced hepatotoxicity. *Clin Liver Dis*. 2013;17(4):643-56. DOI: [10.1016/j.cld.2013.07.009](https://doi.org/10.1016/j.cld.2013.07.009)
22. Islas-Flores H, Gómez-Oliván LM, Galar-Martínez M, Colín-Cruz A, Neri-Cruz N, García-Medina S. Diclofenac-induced oxidative stress in brain, liver, gill and blood of common carp (*Cyprinus carpio*). *Ecotoxicol Environ Saf*. 2013;92:32-8. DOI: [10.1016/j.ecoenv.2013.01.025](https://doi.org/10.1016/j.ecoenv.2013.01.025)
23. Lim MS, Lim PLK, Gupta R, Boelsterli UA. Critical role of free cytosolic calcium, but not uncoupling, in mitochondrial permeability transition and cell death induced by diclofenac oxidative metabolites in immortalized human hepatocytes. *Toxicol Appl Pharmacol*. 2006;217(3):322-31. DOI: [10.1016/j.taap.2006.09.012](https://doi.org/10.1016/j.taap.2006.09.012)
24. Gómez-Lechón MJ, Ponsoda X, O'Connor E, Donato T, Castell J V, Jover R. Diclofenac induces apoptosis in hepatocytes by alteration of mitochondrial function and generation of ROS. *Biochem Pharmacol*. 2003;66(11):2155-67. DOI: [10.1016/j.bcp.2003.08.003](https://doi.org/10.1016/j.bcp.2003.08.003)

25. Hussain I, Khan MZ, Khan A, Javed I, Saleemi MK. Toxicological effects of diclofenac in four avian species. Avian Pathol. 2008;37(3):315-21. DOI: [10.1080/03079450802056439](https://doi.org/10.1080/03079450802056439)
26. Swan GE, Cuthbert R, Quevedo M, Gree RE, Pain DJ, Bartels P, Cunningham AA, Duncan N, Meharg AA, Oaks JL, Parry J, Shultz S, Taggart MA, Verdoorn G, Wolter K. Toxicity of diclofenac to Gyps vultures. Biol Letters. 2006;279-82. DOI: [10.1098/rsbl.2005.0425](https://doi.org/10.1098/rsbl.2005.0425)
27. Albadrany Y, Naser A. Coenzyme Q10, coadministration with diclofenac, augmented impaired renal function in broiler chickens (*Gallus gallus domesticus*). Vet World. 2020;13(4):642. DOI: [10.14202/vetworld.2020.642-648](https://doi.org/10.14202/vetworld.2020.642-648)
28. Tanaka Y, Kaibori M, Miki H, Nakatake R, Tokuhara K, Nishizawa M. Alpha-lipoic acid exerts a liver-protective effect in acute liver injury rats. J Surg Res. 2015;193(2):675-83. DOI: [10.1016/j.jss.2014.08.057](https://doi.org/10.1016/j.jss.2014.08.057)
29. Pinar N, Çakırca G, Hakverdi S, Kaplan M. Protective effect of alpha-lipoic acid on cisplatin-induced hepatotoxicity in rats. Biotech Histochem. 2020;95(3):219-24. DOI: [10.1080/10520295.2019.1667025](https://doi.org/10.1080/10520295.2019.1667025)

التأثيرات الوقائية لحمض الالفا ليبويك على الدايكولوفيناك المحدث للتسمم الكبدي والكلوي في أفراخ التسمين

مروى رحاب عبد الغني و احمد صلاح ناصر

فرع الفلسفة والكيمياء والحياتية والأدوية، كلية الطب البيطري، جامعة
الموصل، الموصل، العراق

الخلاصة

حمض الالفا ليبويك هو مركب مضاد للالتهابات ومضاد للأكسدة ويمتلك تأثيرات كاسحة للجذور الحرة فضلاً عن فاعليته المضادة للأكسدة لنواتج الأيض لمضادات الأكسدة الخلووية الأخرى. كان الهدف من هذه الدراسة هو تقييم الفعل الوقائي لحمض الالفا ليبويك لأذى الكبد والكلوي المحدث بواسطة الدايكولوفيناك في أفراخ الدجاج. تم توزيع الأفراخ البالغة من العمر ٧ أيام على ٤ مجموعات بمعدل ستة أفراخ لكل مجموعة. المجموعة الأولى حقنت في الخلب بالبروبيلين كلابكول واعتبرت مجموعة سيطرة، المجموعة الثانية تم حقنها داخل الخلب بحمض ألفا ليبويك بجرعة ٨٠ ملغم/كغم، المجموعة الثالثة تم حقنها داخل الخلب بالدايكولوفيناك بجرعة ٢ ملغم/كغم، وتم حقن المجموعة الرابعة بحمض ألفا ليبويك بجرعة ٨٠ ملغم/كغم في الخلب والدايكولوفيناك بجرعة ٢ ملغم/كغم في الخلب معاً. استمرت المعاملة لمدة ٧ أيام في المجاميع كافة وفي اليوم الثامن تم التضحية بجميع الأفراخ من خلال قطع الوريد الوداجي. تم أخذ عينات الدم لغرض الفحوصات الكيموحيوية. سبب الدايكولوفيناك زيادة ملحوظة في نشاط خميرة ناقلة الأمين الالنين ونشاط خميرة ناقلة الاسبارتيت وتركيز والكرياتينين واليوريا بينما تسبب الإغذاء المتزامن لحمض الالفا ليبويك مع الدايكولوفيناك انخفاضاً معنوياً في نشاط خميرة ناقلة الأمين الالنين ونشاط خميرة ناقلة الاسبارتيت وتركيز والكرياتينين واليوريا. قد يكون لحمض ألفا ليبويك مفيد في الوقاية من السمية الكبدية-الكلوية التي يسببها الدايكولوفيناك بسبب فاعليته المضادة للأكسدة.