

## **HISTOPATHOLOGICAL STUDY OF PULMONARY LESIONS IN THE LUNGS OF WATER BUFFALOES (*Bubalus bubalis*) IN THE ABATTOIR OF BASRAH PROVINCE IN SOUTHERN IRAQI**

Tahssin S. Chayed\* ,Methaq A. Abd Alsamad \*\*

\* Department of Agricultural Extension and Training, Ministry of agriculture , Iraq,.

\*\*Department of Pathology and Poultry Diseases, College of Veterinary Medicine, University of Basrah,Basrah, Iraq.

(Received 22 September 2020, Accepted 4 October 2020)

**Keywords:** Water Buffalo, Pneumonia, Basrah.

Corresponding author: [tahssinalamery@yahoo.com](mailto:tahssinalamery@yahoo.com)

### **ABSTRACT**

Water Buffalo (*Bubalus bubalis*) is one of the important animals in Iraq because of its great economic value and historical symbolism, which reflects the history and the civilisation epoch of Mesopotamia. This study has focused on the macroscopic lesions that appear on the lungs of the water buffaloes with also an examination of these specimens microscopically, which reflect the extent of pulmonary disease among these animals, which form significant economic losses. This study was conducted in the abattoir of Basrah province, south of Iraq, from October 2019 until February 2020. Samples of 120 affected lungs (23.21%) of different macroscopic lesions were obtained of the total 517 water buffaloes. The microscopic lesions were divided into the following: bronchopneumonia 29 cases (24.17%) (Suppurative bronchopneumonias 14 cases (48.28% out of 29) and fibrinous bronchopneumonias 15 cases (51.72%). The interstitial pneumonia was 33 cases (27.5%)(Acute Interstitial pneumonia 21 cases (63.64% out of 33) and chronic interstitial pneumonia was 12 cases (36.36%), granulomatous pneumonia 5 cases (4.17%), emphysema 18 cases (15%), atelectasis 7 cases (5.83%), oedema cases 5 (4.17%), congestion 6 cases (5%), haemorrhage 11 cases (9.16%), pneumoconiosis (anthracosis) 6 cases (5%). Pneumonia in water buffalo is the most challenging condition to treat after it has worsened. Hence, regular veterinary examination and testing is an essential step in managing the disease as it has become unreactive to therapies in the later stage.

## INTRODUCTION

Water Buffalo (*Bubalus bubalis*) is an important, economic animal characterised by high milk and meat production (1). *Bubalus bubalis* generally prefers to live around marshes or nearest areas where reeds (*Phragmites australis*), papyrus (*Typha domingensis*), and other green plants are widely accessible (2). Water buffaloes are the oldest animal species domesticated since the era of the Mesopotamia civilisation. In Iraq, These animals concentrate in the southern and mid-areas of the country, particularly in marshlands of Basrah, Mayssan, and Dhi-Qar (3, 4). In the last three decades, most of the wetlands in southern Iraqi have been transformed into deserted lands due to over-drying for political reasons from 1991 to 2003, as well as the severe change of climate (5, 6). The drying of marshes has affected the biodiversity of the region, additional the breeding of domestic animals, particularly the buffaloes (7).

After 2003, although the flow of water to the marshlands has been restored and some animal breeders have returned, health and environmental problems have begun to arise for humans and animals (8, 9). Due to the environmental and historical importance of the Iraqi marshes, on 16 July 2016, UNESCO included the Mesopotamian marshes in the World Heritage List (<http://www.unesco.org>). The inclusion of the marshes and wetlands into the UNESCO List of World Heritage encouraged experts to provide improved service in all Iraqi fields (10), including the field of veterinary medicine (11). Hence, this research aimed to classify and explain pulmonary lesions macroscopically and microscopically of buffaloes slaughtered in Basrah abattoir.

## MATERIALS AND METHODS

Out of the 517 lungs of water buffalo lungs investigated at the Basrah abattoir in the south of Iraq, 120 lungs were diagnosed with macroscopic lesions, from the period October 2019 to February 2020. Immediately after the slaughter, a comprehensive gross examination of buffaloes' lungs was conducted, and lesions were recorded. Samples were obtained from the affected lungs and preserved in 10% formalin for the histopathological processes, according to (12).

## RESULTS

According to the macroscopic observations were seen on the lungs of the infected animals, and based on the microscopic examination of the affected lungs, the results were divided into table 1:

**Table 1:** The Percentage of lesions and the numbers.

No.	Types of lesions	Number	Percentage (%)
1.	Bronchopneumonia	29	24.17
	a-suppurative Bronchopneumonia	14	
	b- fibrinous bronchopneumonia	15	
2.	interstitial pneumonia	33	27.5
	a- Acute interstitial pneumonia	21	
	b- chronic interstitial pneumonia	12	
3.	granulomatous pneumonia	5	4.17
4.	Pulmonary emphysema	18	15
5.	Atelectasis	7	5.83
6.	Congestion	6	5
7.	Haemorrhage	11	9.16
8.	Oedema	5	4.17
9.	Pneumoconiosis (anthracosis)	6	5
Total		120	100%

Bronchopneumonia 29 cases (24.17%) (Suppurative bronchopneumonias 14 cases (48.28% out of 29 cases) and fibrinous bronchopneumonias 15 cases (51.72% out of 29 cases), interstitial pneumonia cases 33 (27.5%) (Acute Interstitial pneumonia 21 cases (63.64% out of 33 cases) and chronic interstitial pneumonia was 12 cases (36.36%), granulomatous pneumonia 5 cases (4.17%), emphysema 18 (15%), atelectasis cases 7 (5.83%), oedema cases 5 (4.17%) congestion 6 cases (5%), haemorrhage 11 cases (9.16%), pneumoconiosis (anthracosis) cases 6 (5%).

In the current study, out of 120 affected lungs, 29 cases (24.17%) of bronchopneumonias were observed. In 14 cases, suppurative bronchopneumonia was (48.28% out of 29 cases), whereas in 15 cases, fibrinous bronchopneumonia was reported (51.72% out of 29 cases).

The affected lung was highly congested and oedematous in the fibrinous bronchopneumonias; it gave the lung the dark red colour. The fibrin materials accumulated in the intralobular septa, allowing the lung to have a marble appearance. Besides, the accumulation of the fibrin on the pleura, yellowish zones formed on the surface of a deep red lung (figure 1). Microscopically, there was an accumulation of fibrin in the alveoli with lower numbers of inflammatory cells (fig. 2). The Suppurative bronchopneumonia was distinguished by purulent materials that cause blockage of the airways within bronchi, bronchioles, and alveolar ducts (fig. 3). Microscopically, there were abundant neutrophils, macrophages, and cell debris which obliterated most lumens of alveoli, bronchiole, and bronchi with a lesser amount of fibrin (fig. 4).

Interstitial pneumonia was recorded in 33 cases (27.5%). In this study, Acute Interstitial pneumonia was recorded in 21 cases (63.64% out of 33 cases) either chronic interstitial pneumonia was noticed in 12 cases (36.36% out of 33 cases).

In Acute Interstitial pneumonia, The lungs were macroscopically heavy, firm, and pale in appearance; in the cross-section, the lung has a meaty appearance (fig.5). Microscopically, alveolar walls were thickening as a consequence of oedematous fluid, and leakage of erythrocyte, with the congestion blood vessels, and formation of hyaline membranes that attached to the alveolar walls, which are the hallmark of acute interstitial pneumonia. There was hyperplasia of the pneumocytes II to substitute the destruction of the two types of pneumocytes (fig.6). In the chronic interstitial pneumonia, the lungs

appeared more firm in palpation than acute cases. Microscopically, the fibrosis occupied some regions of the lung tissue (fig. 7).

Granulomatous pneumonia is shown in 5 cases (4.17%) from 120 affected lungs. Granulomatous pneumonia macroscopically was distinguished by firm palpation, with nodules protruding from the surface of pulmonary tissue, besides they were well-circumscribed from the healthy lung tissues, their colours were often darker than usual. The lesions were distinguished microscopically by several concentric circular regions, with a significant number of epithelioid, giant cells, and multinucleated cells on the rings, all encircled by fibre tissue (fig.8).

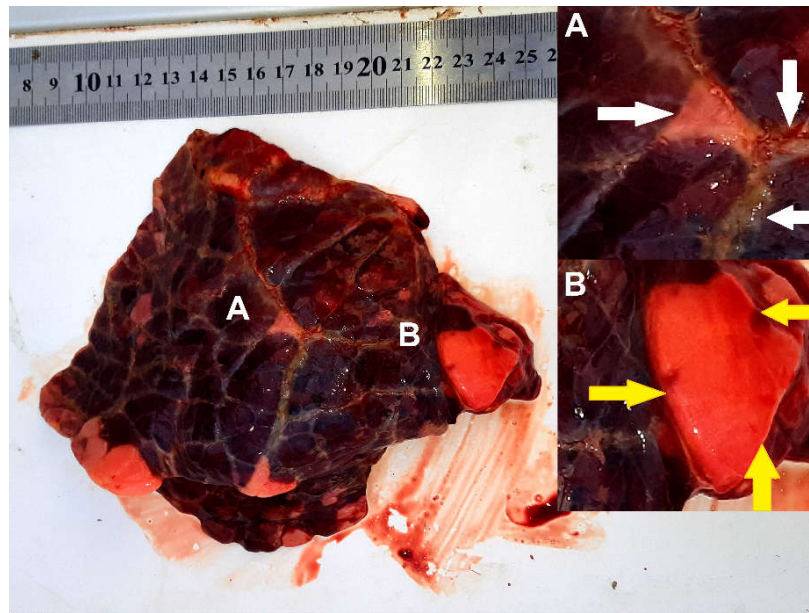
Emphysema was detected in 18 (15%) of this study. Interstitial emphysema had macroscopically characterised by the distension of interlobular septa because of air accumulation inside them. Either Alveolar emphysema demonstrated with multiple air bubbles were trapped in pulmonary parenchyma and emerging from external lung tissue. Microscopically, several alveolar walls had destroyed and merged into much larger spaces than normal alveoli. The walls of almost all of the alveoli were thin and atrophic (fig.9).

Atelectasis was observed in 7 cases (5.83%) out of 120 affected lungs. The lungs were firm in texture in one or both of the lungs. The alveolar sacs appeared microscopically decompressed, and their overall shapes were unorganised, and their typical architecture was lost (fig.10).

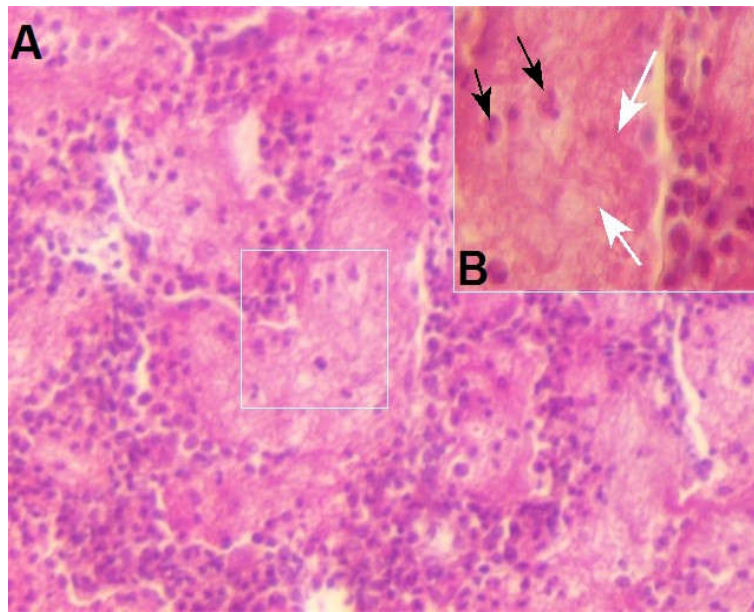
Of the 120 cases, there were 5 cases (4.17%) of oedema. The lungs were macroscopically heavy, pale in colour. For extreme cases, the lungs were severely distending with rounded edges (fig.11). The alveoli were microscopically filled with homogenous eosinophilic fluid with the thickening of interlobular septa (fig.12).

Congestion was identified in 6 cases (5%), whereas haemorrhage was in 11 cases (9.16%) of 120 affected lungs in the present study. The lungs were severely congested macroscopically (fig. 13), While in the haemorrhagic lung, there was severe bleeding during the cross-section (fig. 14), and in one case, a petechial and ecchymotic haemorrhages were reported (fig. 15). The blood vessels were microscopically congesting with blood, but in haemorrhagic cases, there was a leakage of erythrocytes in the alveoli, alveolar ducts and interstitial tissues (fig. 16).

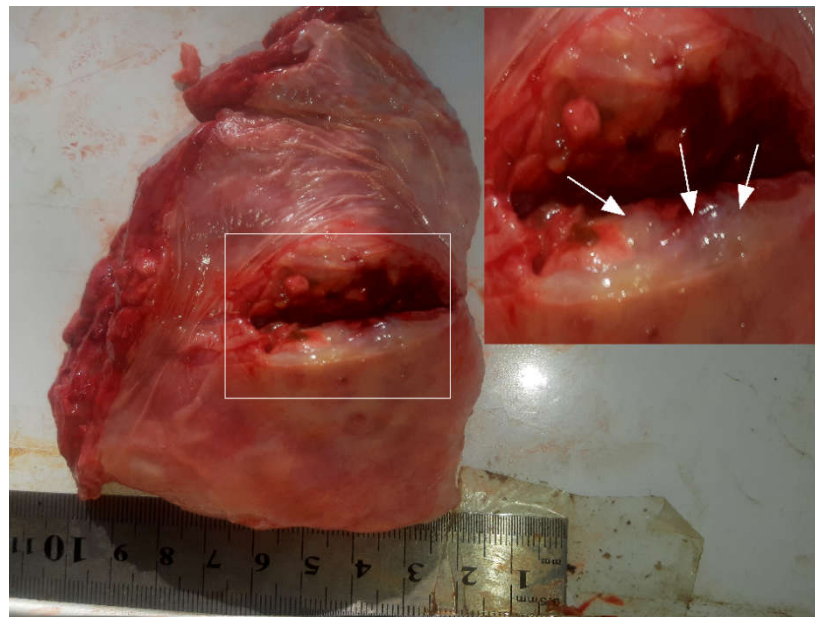
In this study, Pneumoconiosis (anthracosis) was reported in 6 cases (5%) out of a total of 120 affected buffaloes' lungs. The macroscopic lesion was characterised by the appearance of black pigments spreading as fine points across the lungs, which, due to the strength of pigmentation, often transformed into grey colour (fig. 17). Microscopically, black particles spread in the lumen of alveoli, alveolar walls, and the bronchiolar walls with the presence of the pigment-laden macrophages—infiltration and oedema in the interstitial tissues and sometimes leakage of erythrocytes (fig. 18).



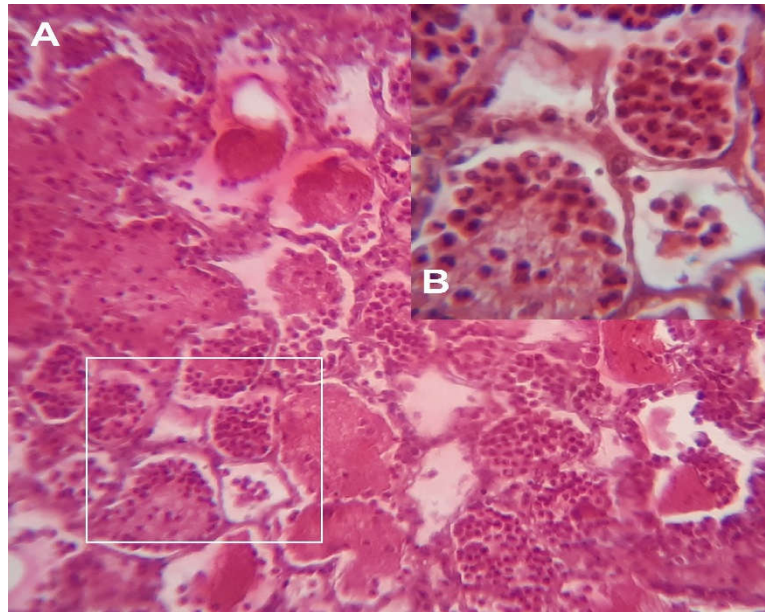
**Figure (1):** Macroscopic appearance of severe congestion in the lung. A- The lung appears dark red, the interlobular septa are broad and prominent and tend to be yellowish



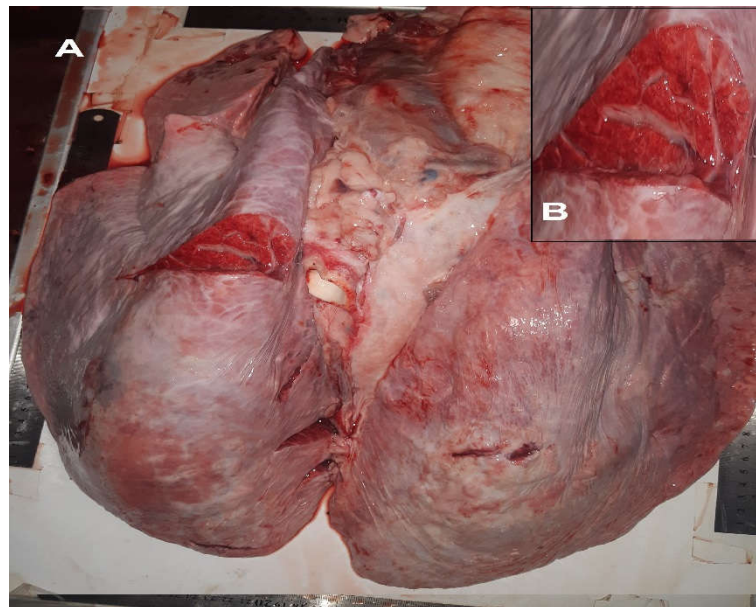
**Figure (2):** A- Microscopic observation of the fibrinous bronchopneumonia (E&H, 10x). B- The alveoli are filled with fibrinous materials (white arrows) with few multinucleated inflammatory cells (black arrows) (E&H, 40x).



**Figure (3):** Macroscopic appearance of lung abscess. The cut surface shows purulent exudate.

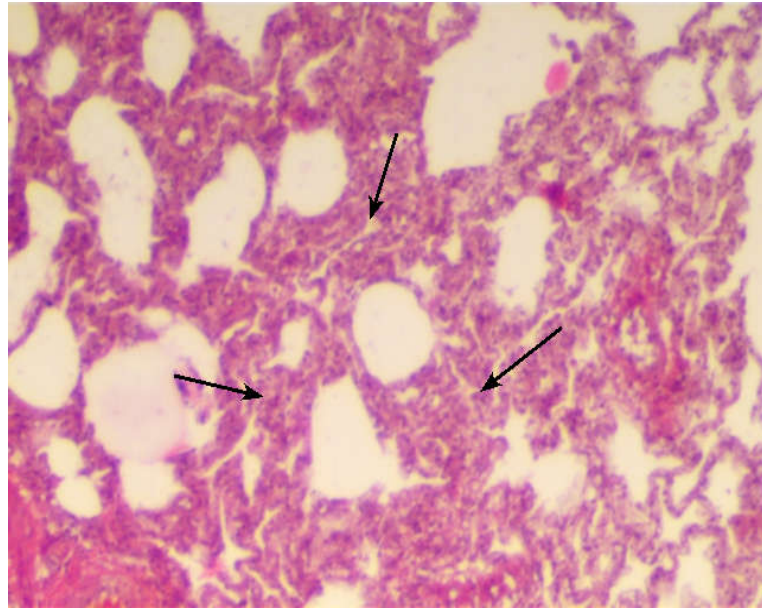


**Figure (4):** A- Microscopic observation of the suppurative bronchopneumonia (E&H, 10x). B- The alveoli are filled with multinucleated inflammatory cells (E&H, 40x).

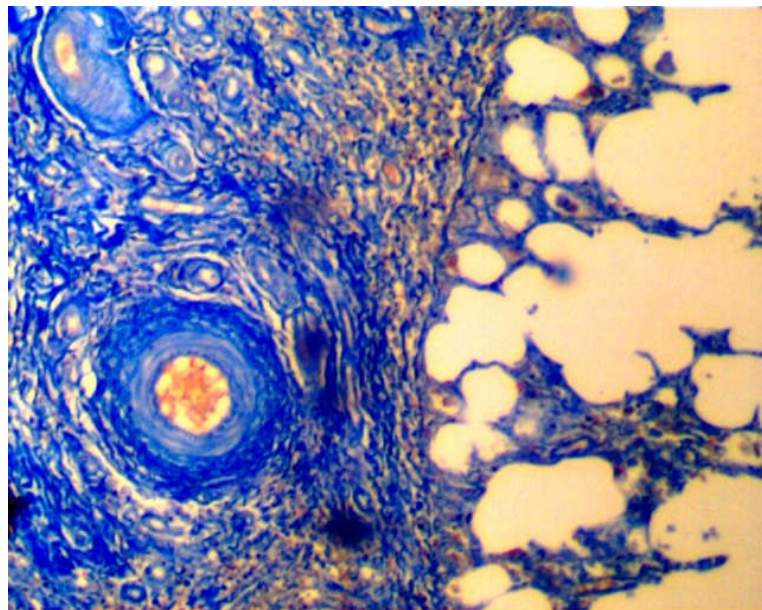


**Figure (5):** A- Macroscopic appearance of interstitial pneumonia in the lung. B- The cut surface shows the meaty appearance of the pulmonary tissue.

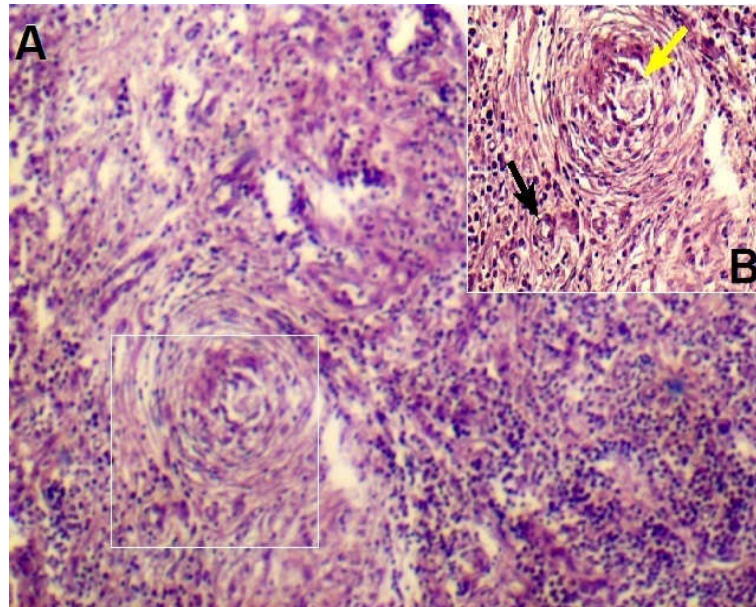




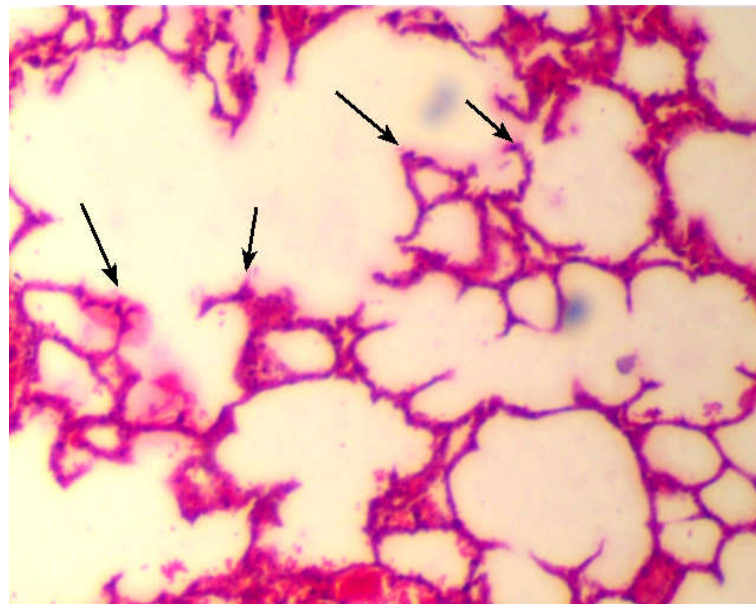
**Figure (6):** Acute interstitial pneumonia in low magnification shows the thickening of the alveolar walls as well as infiltration of inflammatory cells in the interstitial septae (black arrows) (E&H, 10x).



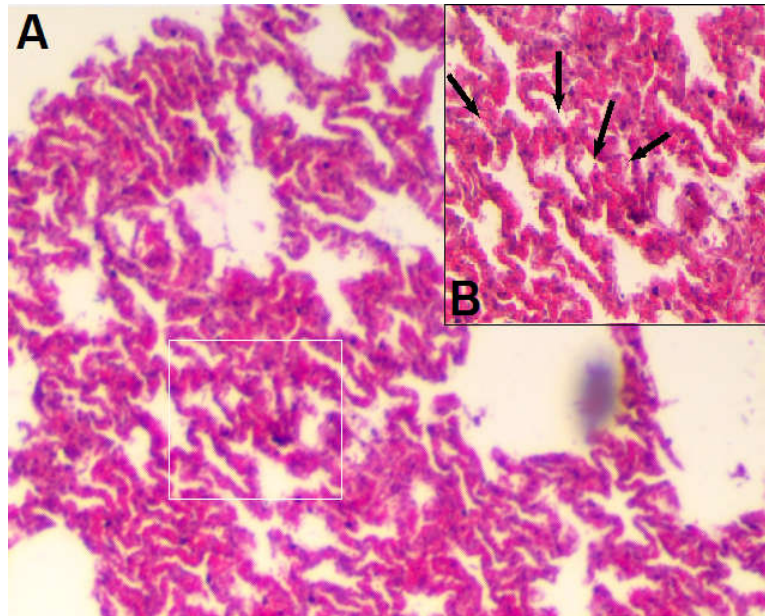
**Figure (7):** Chronic interstitial pneumonia in low magnification shows the fibrosis; the lung lost its typical architecture (Mallory' stain, 10x).



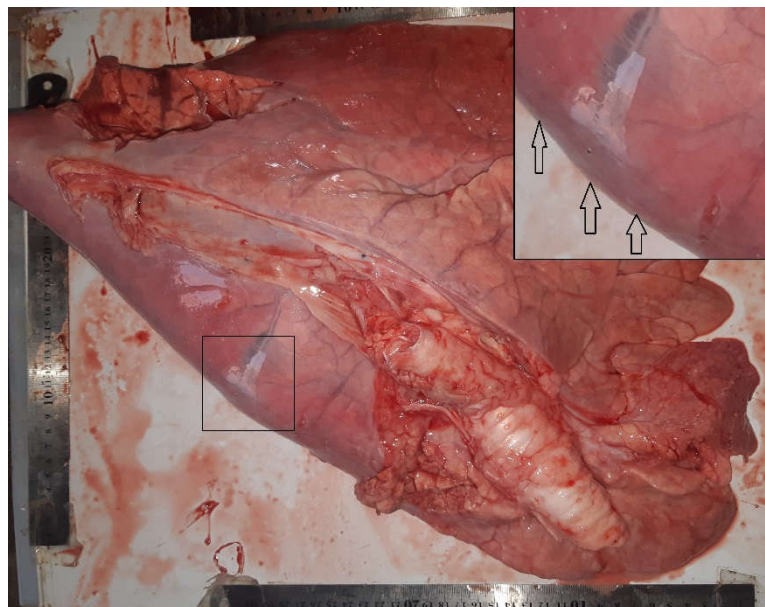
**Figure (8):** A- microscopic observation of granulomatous pneumonia (E&H, 4x). B- Central necrosis area (yellow arrow) with the aggregation of inflammatory cells (black arrow) (E&H, 10x).



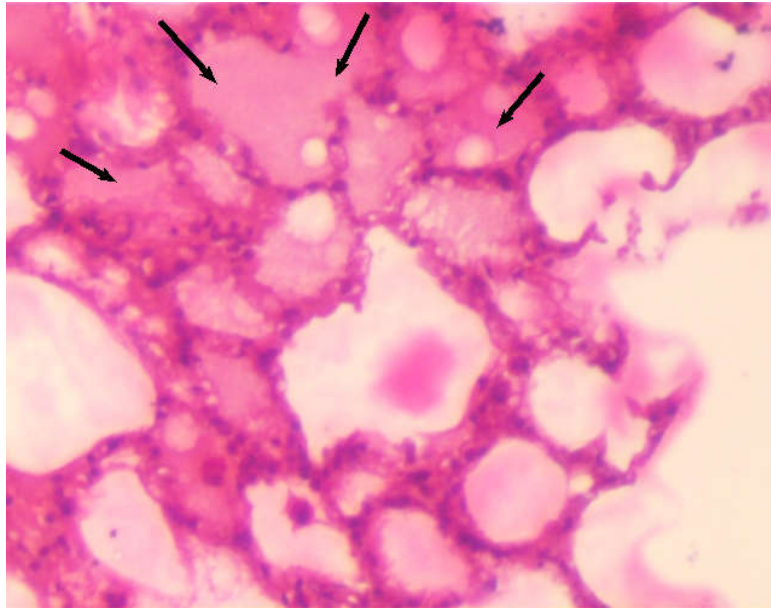
**Figure (9):** microscopic observation of emphysema. The walls of nearly all the alveoli are remarkably atrophic, thin and destroyed (black arrow) (E&H, 4x).



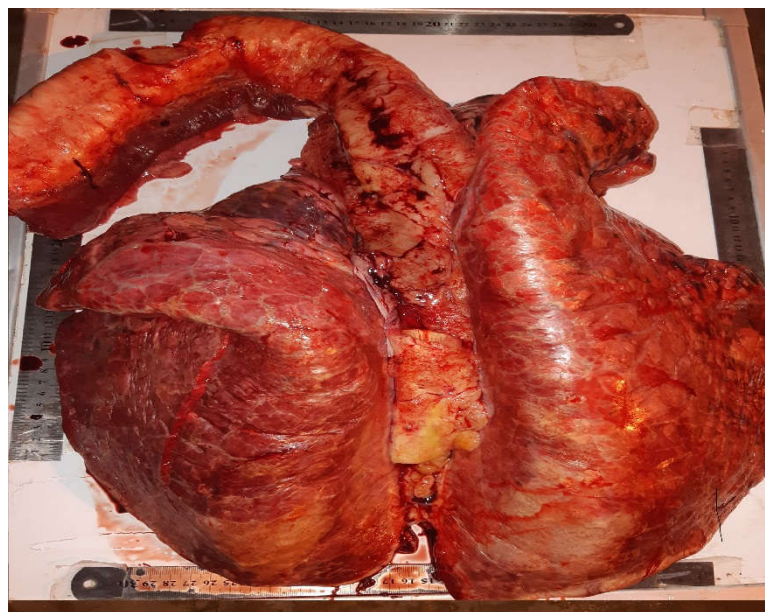**Figure (10):** A- low magnification of atelectasis (E&H 4x). B- The alveoli are depressed, and the alveolar spaces are lost (black arrows) (E&H, 10x).



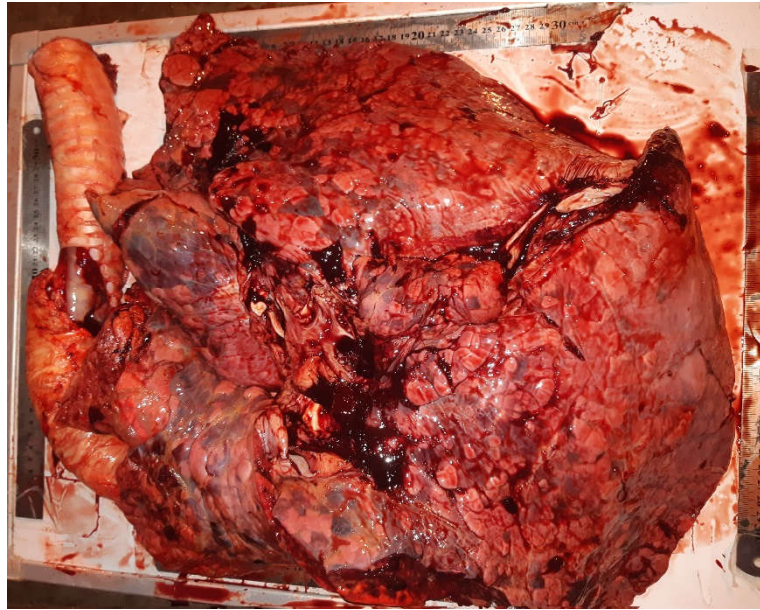
**Figure (11):** Macroscopic appearance of the oedematous lung. The oedema fluid distends the lungs, forming rounded edges (black arrows).



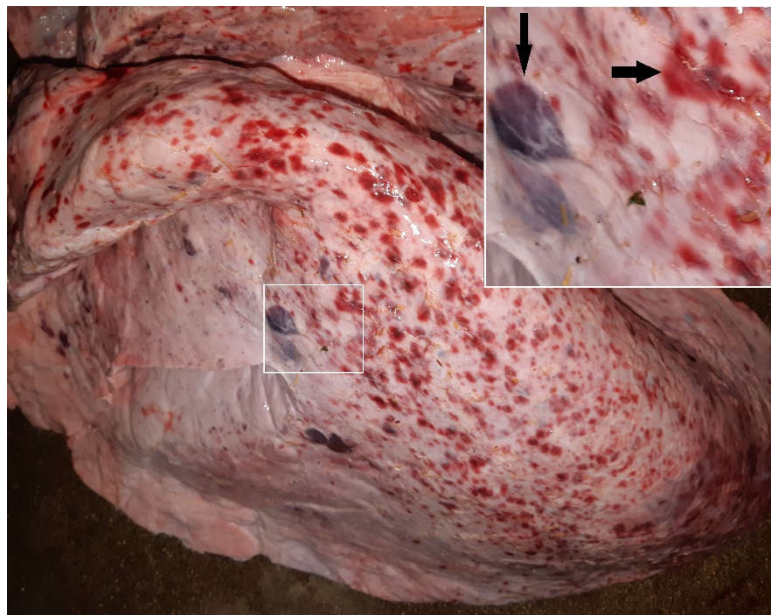
**Figure (12):** microscopic observation of oedema. The alveoli fill with eosinophilic fluid (black arrows)(E&H, 10x).



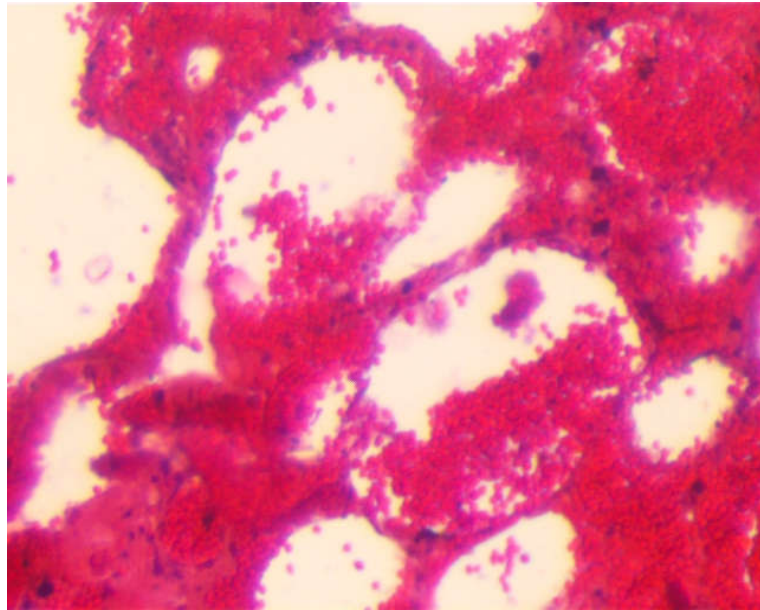
**Figure (13):** Macroscopic appearance of severe congestion. The whole lung appears dark red with rubbery palpation.



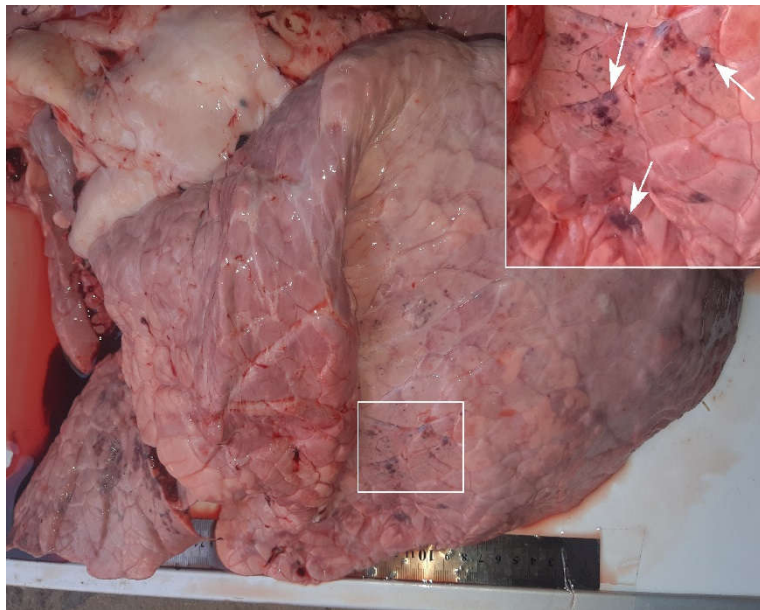
**Figure (14):** The gross appearance of severe haemorrhage in the lung. Severe haemorrhage occurred during the cut section.



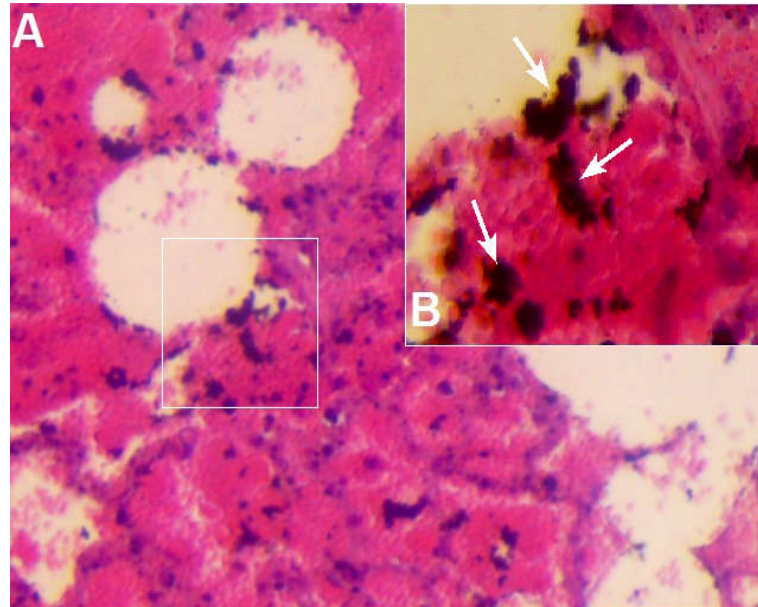
**Figure (15):** the gross appearance of petechial and ecchymotic haemorrhages in the lung (black arrows).



**Figure (16):** microscopic observation of pulmonary haemorrhage (E&H, 10x).



**Figure (17):** Macroscopic appearance of anthracosis in the lung. The lung appears greyish with the presence of small black discolouration (white arrows).



**Figure (18):** A- The low magnification of the anthracosis in the lung (E&H, 10x). B- High magnification shows the presence of carbonic materials in the alveoli and alveolar septae (white arrows) with leakage of erythrocytes (E&H, 40x).

## DISCUSSION

In general, there is a lack of scientific investigation into water buffalo diseases in Iraq, particularly respiratory disease studies, despite its large population and the substantial economic wealth, along with its historical characteristics, which depict the history and civilisation of Mesopotamia (13).

Out of 517 Water Buffaloes' lungs were studied in the abattoir of Basrah province in southern Iraq in the research study. One hundred twenty (120/517) or (23.21%) pulmonary lesions have been identified macroscopically and microscopically. The lesions were classified into bronchopneumonia, interstitial pneumonia, granulomatous pneumonia. Besides, they were subdivided into the types of exudates, either fibrinous or suppurative, circulation disturbances (oedema, haemorrhage, and congestion), abnormalities of inflation (emphysema, atelectasis).

The result of this study agreed with that of (14) who noted (20.53%) of the histopathological changes of the lung buffalo in south-western Iran. This similarity of the ratio is due to similar environmental and climatic conditions between the west and south-western regions of Iran and Basrah governorate (15).

While This study revealed disagreement with (16), who identified 105 of the 917 buffalo lungs, which were gross pneumonic lesions in the slaughterhouses of Basrah, Dhi-Qar, and Mayssan in southern Iraq during the period from October 1989 to March 1990, due to the factors affecting the buffaloes ecosystem over the last three decades, the results of the current study may differ:

Most Iraqi Marshlands were dried after 1991 for political purposes, followed by climatic and environmental changes, leading to a decline in natural plant sources like reed and papyrus (9). Moreover, the lack of agricultural rehabilitation led to the reduction of large areas of agricultural land (6,17).

These reasons had changed the way of raising buffaloes from the open-ended method in vast areas within the marshes to the raising of buffalo in the edges of marshlands in closed sheds (confined system) that do not contain any sanitary conditions for the animals (18). Animal breeding in closed areas (confined system) is accompanied by overcrowded and lack of airflow, increasing in summer high temperatures that cause increasing the animal's respiration rate (19,20).

Besides, there is no clear plan for preventive vaccination programs in the marshes, which helped in the spread of diseases, especially respiratory ones. All of the above reasons may support the increase in infection rates (21,11). Also, the present study differs from other southern Asia studies. In India, (22) reported (29.28 %) of pulmonary lesions from 1728 total deaths buffaloes from 28 livestock farms in 14 Indian states. In Bangladesh, (23) simultaneously observed (37,5%) pneumonic water buffalo lesions. (24) reported (30.92%) pulmonary lesions in the east and southeast of India. This increase in the incidence of pulmonary lesions in the researches which were carried out in the regions of Southern Asia may be due to the geographical position, ages of animals, gender, and breeds (24).



In the present study, 29 cases (24.17%) of the total number of 120 cases of bronchopneumonia were reported. Fibrinous bronchopneumonia was 15 cases (51.72%), whereas suppurative bronchopneumonia was 14 (48.28%). (16) reported that bronchopneumonia in 43 cases (40.95%) (fibrinous bronchopneumonia 28 cases and suppurative bronchopneumonia in 15 cases) of 105 affected buffaloes' lungs out of 917. In comparison, (24) reported bronchopneumonia in 54 cases (17.82%) from 303 affected lungs out of 980 water buffaloes (fibrinous bronchopneumonia 16 (29.63%) and suppurative bronchopneumonia in 38 (70.37%). (14) reported 79 cases of bronchopneumonia (27.72%) of 333 infected lungs out of (1622) water buffaloes, 55 cases of fibrinous bronchopneumonia (69.63%) and 24 cases of suppurative bronchopneumonia (30.37%). (25) noticed 22 cases of fibrinous bronchopneumonia (34.92%) out of Egypt's 63 buffaloes lungs. The present study agrees with (14), but it disagrees with both (16) and (25), the first recorded a high incidence of bronchopneumonia and the second reported a low incidence of fibrinous bronchopneumonia.

In the current study, interstitial pneumonia was observed 33 (27.5%). (23) observed chronic interstitial pneumonia in (3.75%) from 30 affected lungs out of 80 water buffaloes. From 333 affected lungs, (14) reported interstitial pneumonia in 201 cases (60.36%), while (25) reported broncho-interstitial pneumonia in 14 cases (22.22%) in 63 affected lungs out of 88 water buffaloes.

The result was compatible with (25). In comparison, the results largely contrasted with the results of (23,14).

In the current study, the incidence of granulomatous pneumonia is 5 cases (4.17%), this result is consistent with (16) who noted in 3 cases (4.41%) out of 105 affected lungs, on the other hand, it differs from (24) who recorded Granulomatous pneumonia in one case (0.33%) out of 303 affected lungs.

Emphysema was noticed in 18 cases (15%) in the current study. That result was reasonably compatible with the incidence of pulmonary emphysema (13.04%) in water buffaloes by (26). However, the results of this study differed significantly from the results were obtained by (23,27), who reported emphysema in buffaloes (5%) and (1.71%), respectively.

Atelectasis was reported in 7 cases (5.83%) of examined lungs. This ratio was stated by (28), who reported atelectasis in bovine lungs (5.03%), while it contrasted with (26) who noted atelectasis in (13.04%) in buffaloes' lungs.

Oedema has been identified in 5 cases (4.17%) in the current study out of 120 affected lungs. However, (23,24) reported oedema (3.75%) and (3.30%), respectively. Compared to (27), who recorded a low rate of oedema (1.20%).

In the present study, congestion was noticed in 6 cases (5%). Macroscopically, the lungs were severely congested. Microscopically, the blood vessels were engorged by blood. In comparison, (28) reported congested lung (7.89%) and (27) recorded (8.69%).

Haemorrhage was noticed in 11 cases (9.16%) of 120 affected lungs. Macroscopically, there were significant congestions of the lungs and one occurrence of petechial haemorrhage. Microscopically, there were leakages of erythrocytes in the alveolar lumen, alveolar ducts, and interstitial tissues. (27) reported (2.39%), whereas (26) recorded pulmonary haemorrhage (17.39%).

In one case, Petechial and ecchymotic haemorrhage has been reported. It characterised by various sizes of bloody foci distributed randomly throughout the lung. According to (34), This case may occur due to endocarditis.

In the current study, there have been 6 cases of anthracosis (5%) out of 120 infected Buffaloes' lungs. (27) noticed 3 cases (0.26%) of affected lungs in water buffaloes. As well as, (29), with samples from two abattoirs of Kadapa (India), reported anthracosis in 2 cases (1.66%) out of 120 sheep's lungs without any notable gross discolouration. Also, (30) noticed 3 cases of anthracosis (0.78%) out of 380 pneumonitic cattle' lungs (*Bos indicus*) in Rajasthan, India. In comparison, (31) observed a high incidence of anthracosis in 43 cases (28.67%) out of 150 camels' lungs in Najaf-Abbad, in Esfahan province of the western region in Iran.

This condition is caused by animal husbandry in areas with air pollution by large proportions of carbon particles where emitted from factories and industrial areas (32), as well as by the raising of animals in enclosed, crowded, low ventilated areas with high exposure of inhaled dust (33).

## دراسة نسيجية مرضية في الافات الرئوية للجاموس النهري في مجزرة محافظة البصرة جنوبي العراق

تحسين سعود جايد\*، ميثاق عبد الرضا عبد الصمد\*\*

\*وزارة الزراعة في العراق، دائرة الإرشاد الزراعي والتدريب، البصرة

\*\*فرع الامراض وامراض الدواجن، كلية الطب البيطري، جامعة البصرة، البصرة، العراق

### الخلاصة

يعتبر الجاموس النهري من الحيوانات المهمة وذلك لاهمية الاقتصادية الكبيرة ولرمزيته التاريخية التي تمثل تاريخ وحضارة بلاد ما بين النهرين. هذه الدراسة سلطت الضوء على الافات العيانية الظاهرة على رئات حيوانات الجاموس ودراستها نسيجيا حيث تعكس الافات الرئوية شدة الاصابة بالامراض التنفسية التي تسبب خسائر اقتصادية كبيرة. اجريت هذه الدراسة في مجزرة محافظة البصرة جنوب العراق، للفترة من بداية اكتوبر ٢٠١٩، ولغاية نهاية شباط ٢٠٢٠. حيث تم الحصول على ١٢٠ عينة رئوية من مجموع ٥١٧ حيوان مذبح اي بنسبة (٢٣.٢١%) من مختلف الافات العيانية. قسمت الافات المجهرية الى: التهاب رئوي قصبي ٢٩ حالة من مجموع ١٢٠ حالة (٢٤.١٧%) (التهاب رئوي قيحي ١٤ حالة (٤٨.٢٨%) بينما الالتهاب الرئوي الليفيني كان ١٥ حالة (٥١.٧٢%)، التهاب رئوي خلالي ٣٣ حالة (٢٧.٥%) (التهاب رئوي خلالي حاد ٢١ (٦٣.٦٤%) بينما الالتهاب الرئوي الخلالي المزمن كان ١٢ حالة (٣٦.٣٦%)، التهاب رئوي حبيبي ٥ حالة (٤.١٧%)، نفاخ رئوي ١٨ حالة (١٥%)، انخماص رئوي ٧ حالات (٥.٨٣%)، وذمة رئوية ٥ حالات (٤.١٧%)، احتقان رئوي ٦ حالات (٥%)، نزف رئوي ١١ حالة (٩.١٦%)، التغبر الرئوي ٦ (٥%).

### REFERENCES

- 1- Deng, T., Liang, A., Liang, S., Ma, X., Lu, X., Duan, A., Pang, C., Hua, G., Liu, S., Campanile, G. and Salzano, A., (2019). Integrative analysis of transcriptome and GWAS data to identify the hub genes associated with milk yield trait in buffalo. *Frontiers in genetics*, 10, p.36.
- 2- Borghese, A. (2005). Buffalo production and research (REU Technical Series 67). Inter-regional Cooperative Research Network on Buffalo (ESCORENA), FAO Regional Office for Europe, Rome.
- 3- Al-Saedy, J. K. M. (2014). Mesopotamian buffaloes (the origin). *Journal of Buffalo Science*, 3(1), 30-33.

- 4- **Abu Tabeekh, M. A. S. A., Maktoof, A. R., & Mohsen, H. A. M. A. (2017).** Solutions or alternatives to protect livestock, especially buffalo from the risk of drought in Basra Governorate. *Canadian Journal of Agriculture and Crops*, 2(2), 84-89.
- 5- **Adriansen, H. K. (2004).** (No. 2004: 26). DIIS Working Paper.
- 6- **Chenoweth, J., Hadjinicolaou, P., Bruggeman, A., Lelieveld, J., Levin, Z., Lange, M.A., Xoplaki, E. and Hadjikakou, M., (2011).** Impact of climate change on the water resources of the eastern Mediterranean and Middle East region: Modeled 21st-century changes and implications. *Water Resources Research*, 47(6).
- 7- **Richardson, C. J., Hussain, N. A. (2006).** Restoring the Garden of Eden: an ecological assessment of the marshes of Iraq. *BioScience*, 56(6), 477-489.
- 8- **Al-Saad, H. T., Al-Hello, M. A., Al-Taein, S. M., & DouAbul, A. A. Z. (2010).** Water quality of the Iraqi southern marshes. *Mesopotamian Journal of Marine Science*, 25(2), 188-204.
- 9- **Al-Ansari, N., Knutsson, S., Ali, A. (2012).** Restoring the Garden of Eden, Iraq. *Journal of Earth Sciences and Geotechnical Engineering*, 2(1), pp.53-88.
- 10- **Al-Zaidy, K.J., Parisi, G., Abed, S.A. and Salim, M.A., (2019, September).** Classification of The Key Functional Diversity of the Marshes of Southern Iraq Marshes. In *Journal of Physics: Conference Series* (Vol. 1294, No. 7, p. 072021). IOP Publishing.
- 11- **Abu Tabeekh, M. A.; Mohsen, H. A. M.; Al Jaber, A. A. (2017).** The reality of buffalo breeding in Basra Governorate. *Journal of Buffalo Science*, 6(1), 8-18.
- 12- **Bancroft, J. D.; Suvarna, K. S.; Layton, C., (Eds.) (2018).** Bancroft's theory and practise of histological techniques E-Book. Elsevier Health Sciences.
- 13- **Foster, B. R. (2016).** The age of Agade: inventing empire in ancient Mesopotamia. Routledge. Page: 299-300.
- 14- **Sayyari, M., Sharma, R. (2011).** Pathological and bacteriological study of lobe distribution of lesions in buffalo (*Bubalus bubalis*). *Iranian Journal of Veterinary Medicine*, 5(2), pp.125-128.

- 15- Madani, K. (2014).** Water management in Iran: what is causing the looming crisis?. *Journal of environmental studies and sciences*, 4(4), pp.315-328.
- 16- Thweni, M. M. (2006).** Etiologic study of some pulmonary lesions in buffaloes in southern Iraq. *Basrah Journal of Veterinary Research*. 5(1), 127-133.
- 17- Ahram, A.I. (2015).** Development, counterinsurgency, and the destruction of the Iraqi marshes. *International Journal of Middle East Studies*, 47(3), pp.447-466.
- 18- Al-Mudaffar Fawzi, N., Goodwin, K.P., Mahdi, B.A. and Stevens, M.L., (2016).** Effects of Mesopotamian Marsh (Iraq) desiccation on the cultural knowledge and livelihood of Marsh Arab women. *Ecosystem Health and Sustainability*, 2(3), p.e01207.
- 19- Potter, T., (2015).** Bovine respiratory disease. *Livestock*, 20(1), pp.14-18.
- 20- Yadav, B., Pandey, V., Yadav, S., Singh, Y., Kumar, V. and Sirohi, R., (2016).** Effect of misting and wallowing cooling systems on milk yield, blood and physiological variables during heat stress in lactating Murrah buffalo. *Journal of Animal Science and Technology*, 58(1), pp.1-10
- 21- Mahdi, A.J. (2010).** Foot and mouth disease in Iraq: strategy and control. A report submitted in partial fulfilment of the requirements for the degree Master of Science, Kansas State University Manhattan, Kansas.
- 22- Rathore, B.S. (1998).** An epidemiological study on buffalo morbidity and mortality based on four-year observations on 18 630 buffaloes maintained at 28 livestock farms in India. *Indian Journal of Comparative Microbiology, Immunology and Infectious Diseases*, 19(1), pp.43-49.
- 23- Akbor, M., Haider, M.G., Ahmedullah, F., Khan, M.A.H.N.A., Hossain, M.I. and Hossain, M.M., (2007).** Pathology of trachea and lungs of buffaloes. *Bangladesh Journal of Veterinary Medicine*, pp.87-91.
- 24- Anitha Devi, M. (2011).** Pathomorphological studies on lung lesions in buffaloes. (Thesis), Sri Venkateswara Veterinary University Tirupati–517 502. (AP) (India).

- 25- Abdelbaset, A.E., Abd Ellah, M.R., Abd ElGhaffar, S.K. and Sadiek, A.H., (2014).** Acute-phase proteins in different pathological conditions at the lungs of buffaloes. *Comparative Clinical Pathology*, 23(4), pp.823-828.
- 26- Islam, M.S., Das, S., Islam, M.A., Talukdar, M.M.I., Hashem, M.A., Chowdhury, S. and Asuduzzaman, M., (2014).** Pathological affections of lungs in slaughtered cattle and buffaloes at Chittagong Metropolitan Area, Bangladesh. *Advances in Animal and Veterinary Sciences*, 3(1), pp.27-33.
- 27- Machhaliya, M.H., Patel, B.J., Joshi, D.V., Raval, S.H. and Patel, J.G., (2015).** ‘Pathomorphological studies on spontaneously occurring pulmonary lesions in buffaloes (*Bubalus bubalis*)’, *Ruminant Science*, 4(1), pp. 51–53.
- 28- Belkhiri, M., Tlidjane, M., Benhathat, Y. and Meziane, T. (2009).** Histopathological study and pulmonary classification of bovine lesions. *African Journal of Agricultural Research*, 4(7), pp.584-591.
- 29- Amaravathi, M., Satheesh, K., Bharath Kumar Reddy, C. and Jyosthna, S., (2016).** Histopathological study of pulmonary anthracosis in sheep. *International Journal of Science, Environment and Technology*, Vol. 5, No 5, 2016, 3249 – 3253
- 30- Rani, S. (2017).** Occurrence and Pathology of Various Conditions of Respiratory System in Cattle (*Bos indicus*). (Doctoral dissertation, Rajasthan University of Veterinary and Animal Sciences, Bikaner).
- 31- Goodarzi, M., Azizi, S., Kouiaei, M.J. and Moshkelani, S., (2014).** Pathologic findings of anthraco-silicosis in the lungs of one-humped camels (*Camelus dromedarius*) and its role in the occurrence of pneumonia. *Kafkas Univ Vet Fak Derg*, 20, pp.171-176.
- 32- Ahasan, S.A., Chowdhury, E.H., Azam, S.U., Parvin, R., Rahaman, A.Z. and Bhuyan, A.R., (2010).** Pulmonary anthracosis in Dhaka Zoo collections-a public health forecasting for city dwellers. *Journal of threatened Taxa*, pp.1303-1308.
- 33- McClendon, C.J., Gerald, C.L. and Waterman, J.T., (2015).** Farm animal models of organic dust exposure and toxicity: Insights and implications for respiratory health. *Current opinion in allergy and clinical immunology*, 15(2), p.137.

- 34- Selvam, G., Swamy, M., Verma, Y., Karthik, C. M., Arya, R. S. (2014). Vegetative valvular endocarditis in an Indian buffalo. *Buffalo Bulletin* (June 2014), 33(2).