

COMPARATIVE TOPOGRAPHICAL AND HISTOMORPHOMETRICAL STUDY OF THE HAIR, HAIR FOLLICULE AND HAIR DENSITY IN THE SKIN OF LOCAL BLACK MALES GOAT

Ghada Abdulrhman sultan

Muayad Hasan Abulraheem

Department of Anatomy , College of Veterinary Medicine, University of Mosul , Mosul , Iraq.

(Received 15 November 2020 ,Accepted 21 November 2020)

Keywords: Bucks, hair follicles, Skin.

Corresponding Author: aliabc898@gmail.com

ABSTRACT

The study aimed to undergo a comprehensive study to provide abroad basic data for the different constituents of the skin of local black goat. To achieve this goal, histological, morphometrical and topographical study was carried out on twelve skin regions taken from twenty male apparently healthy bucks. All samples were collected during the autumn season. Two types of hair follicles were noticed: large follicles that extend deeply into the dermis; Which represented primary hair follicles, smaller and shorter but more numerous; called secondary hair follicles. The primary hair follicles produce the coarse hair while the secondary hair follicles produce the fine hairs. The diameter of the coarse hairs varied in the different skin regions and ranged between (39.98-106.40 μ m) being larger in the back and lateral surfaces and smaller in the abdomen and medial surfaces. The diameter of fine hairs ranged between (26.56-39.94 μ m). The secondary: primary hair follicle ratio varies in the different skin regions and accordingly the fine :coarse hair ratio varies as well. The fine: coarse hair ratio was found to be 6.88:1 in the middle back region, 5.89:1 in the lateral surface of forelimbs region, 5.86:1 in anterior back region, 5.46:1 in lateral surface of hind limb, 3.64:1 in medial surface of hind limb, 3.32:1 in the skin of the abdomen, 3.25:1 in the medial surface of the forelimb, 2.82:1 in the skin of the tail, 2.10:1 in the skin of scrotum, 0.20:1 in the skin of the muzzle, 0.15:1 in the dorsal surface of skin of the ear and 0.00:1 in the ventral surface of the skin of the ear. Most of the hair follicles of different regions were of a compound type in which several secondary hairs share the opening of a primary hair follicle. In less common circumstances, the secondary follicles open directly on the epidermis but they remain in a close position to the opening of the accompanied primary follicle. Simple hair follicles were observed in the ventral surface of the skin of the ear, and in a less extent in the scrotal regions, muzzle region and skin of the dorsal surface of the ear. Hair density varies greatly in the different skin regions being: 31.68/mm² in anterior back region, 32.66/mm² in the middle

back region, 13.38/mm² in the abdominal region, 32.76/mm² in the tail region, 30.30/mm² in the lateral side of forelimb, 12.50/mm² in the medial side of the forelimb, 11.52/mm² in the scrotal region, 31.12/mm² in the lateral side of hind limbs, 16.44/mm² in the medial side of hind limbs, 22.22/mm² in the muzzle region, 9.62/mm² in the skin of the dorsal surface of the ear and 2.92/mm² in the skin of the ventral surface of the ear.

INTRODUCTION

The Skin is protective cover of the body and plays an important role in protecting the body from external influences, on the one hand and controlling its temperature and humidity on the other (1). The skin consists of two main layers, the epidermis and the dermis, separated by the basal membrane.

The epidermis consists of keratinized stratified squamous epithelial tissue that cells goes through stages of division, migration, differentiation and keratinization until it reaches the surface layer, where it becomes dead cells that are constantly dissociated from the surface of the epidermis to be replaced by new keratinized cells, so the epidermis is a model of renewed tissue in the body (2). The dermis in most parts of the body contains hair follicles, sweat glands and sebaceous glands, the quality, size and numbers of these components vary depending on the types of animals and skin areas in one animal. It was reported that hair follicles and sweat glands differ in size, depth and density in the different types of cows studied (3). Also found difference in histological composition between certain skin areas in monosyllabic camel (4).

There are many studies on the histological structure of the skin and its attachments in humans (5). although there were histological studies of the skin of local animals, But it was limited in the locations of the skin (6). Due to the importance of the local black goat and the relationship of the skin and hair to the general health condition of the body where hair loss, the appearance of crusts and the spread of ectoparasites are not due to skin diseases, but rather diseases affecting the body in general, in addition to the economic importance (7). And the lack of current study of hair density in different areas of the skin and compare with each other. so the main objective of this research is to know the histological composition of hair and hair follicles, in addition to knowing the density of hair in different areas of the skin and comparing it with each other .

MATERIALS AND METHODS

Sample collection:The research samples (skin) were taken from local Black Goat males aged 1-2 years after being slaughtered immediately and clinically sound especially skin from the Mosul

massacre. All samples were taken in the autumn only to avoid changes that may occur on the skin in different seasons (8).

20 animal skins were used and the areas to be taken from the skin were marked with a colored marker pen before slaughter. After the slaughter, the hair was cut from the marked areas and 4-6 samples were taken from each area using the Punch set with the following diameter information and anatomical locations: (front back, middle back, abdomen, tail, lateral surface of the forelimb, medial surface of the forelimb, scrotum, lateral surface of the hind limb, medial surface of the hind limb, muzzle(snout), dorsal and ventral surface of the ear).

Histological and Morphological Study: Samples were held in Alcoholic Bouin's solution for 48 hours and then transferred to 4% phenol for 24 hours to reduce the hardness of the keratinized substance in the skin. The samples were treated with Ethyle alcohol for the purpose of increasing concentration for the purpose of dehydration starting from 50% concentration with several passes until the yellow color of the stabilizer than 70% , 90% and 100% concentration also with two passes at a rate of 3 hours.

Cedar wood oil was used at the rate of one pass for 24 hours for softening, after which the samples were transferred to Benzen for half an hour (9). And then the samples were passed into pure, paraffin wax the melting-grade 58 - 60 °C, inside the electric oven temperature 60°C. Some samples were placed in molten wax exposed to negative pressure using a vacuum pump type C7960 to facilitate the influence of wax to the samples (10). At a rate of 4 passes, one hour was allocated for each pass and then the samples were poured into clearly marked wax molds (9). Half of the models were immersed in a vertical position inside the wax and the other half in a horizontal position to survey all skin structures and infer on their measurements. The models were cut using the Rotary microtome to obtain 5-8 micrometer thick tissue strips and fixed on glass strips mediated by a light layer of Egg albumin or so-called Mayer's adhesive (10). The following stains were used to show the different histological textures:

1- Delafield's hematoxylin and eosin were colored for the general histological structure of the skin and for the preparation of microscopic measurements (10).

2- Masson's Trichrome stain to differentiate between collagen and muscle fibers in skin (9).

The standard morphometric study was carried out under the optical microscope using the Ocular micrometer and the Stage micrometer standard measurement and extraction of the Micrometer standard value of each object lens. And calculated the microscopic standard value of all the lenses of the microscope, so it was as it comes :

Power of the object lens	Microscopic standard value
4	34.4
10	13.3
40	3.3

Table (1):The use of the Micrometer Value (μm) standard for models measured with different object lenses of the optical microscope

The following variables has been measured:

- 1- The length and depth of the primary follicle.
- 2- The length and depth of the secondary follicle.
- 3- The diameter of the primary and secondary follicle and the diameter of the hair in the primary and secondary follicle.

To confirm the accuracy of the microscopic measurements, they were compared to the method of measuring Visopan (Reichert, Austria Nr. 366 F15).

The power of the object lens	Zoom power	Microscopic standard value
4/0.10	50	20
10/0.25	125	8
16/0.32	200	5
40/0.65	500	2
63/0.80	800	1.2
100/1.25	1250	0.8

Table (2):Extract the microscopic measurement value of Visopan object lens models as found in the device manual itself

Study of hair density: Hair density is calculated by enumerating the hair follicles of Adenomeres per unit area and as it comes, the horizontal sections below the level at which the sebaceous glands open to the hair follicles were selected to ensure the presence of primary and secondary hair follicles.

The area of the Microscopic field was calculated by calculating the diameter of the microscopic field of the microscope in the object lens in which it was examined and extracted the surface area of the microscopic field using the usual geometric method.

The study aimed at what comes:

- 1- Find the number of primary hair follicles per unit area in different skin areas.
- 2- Find the number of secondary follicles per unit area in different skin areas.

- 3- Find the total number of hair follicles per unit area in different skin areas.

Microphotography:photographed tissue sections using a digital camera and a light microscope (Reichert, Neovar) mediated by Adaptor.

Calculation of Magnification:

$$\text{Zoom power} = \frac{\text{Measure the value of a certain number of microscopic ruler divisions after}}{\text{The number of divisions themselves} \times 10}$$

Statistical analysis :The data for the study were analyzed using the one way analysis of variance test and using the Duncan test to identify statistical differences between different areas of the skin (11). and examined the moral differences in all tests at the level of $P < 0.001$.

RESULTS

This study showed that local black goat skin consists of two main layers, the epidermis and dermis, hypodermis is another layer which is located under the dermis formed from loose connective tissue which connect the skin to the underneath tissues .

Hair and Hair Follicles: The hair is an elongated keratinous structure that is mediated by the hair follicle in the primary and secondary follicles.The root of the hair in the primary and secondary follicles consists of three layers the outer layer is the cuticle composed of a single row of flat keratinized cells whose free edges are directed towards the distal end of the hair shaft, and the middle layer is the cortex composed of monolithic keratinized cells as their longitudinal axes appeared parallel to the hair shaft, containing the remnants of the nuclei and pigment granules. These cells become shorter, oval in shape and contain spherical nuclei near the hair follicle. The third inner layer, the medulla, contains disintegrated cubic or flat cells with air gaps (Fig. 1).

The results of the study of goat skin showed that there are two types of hair in the domestic black goat skin. Coarse hair composed of Marrow and cortex and cuticle starch from primary follicles and soft hair devoid of Marrow starch from secondary follicles and the diameters of both types differed by different areas of the body studied as the diameters of coarse hair ranged from (66.50-106.40 μm) as the outer skin areas such as the back and the lateral surfaces of the

forelimb and hind limb large diameters of coarse hair or hair resulting from the primary follicles if compared to the medial surfaces of the limbs, back and abdomen, as shown in Table (3).

On the other hand, the diameters of the fine hair produced by the secondary follicles in the lateral surfaces of the forelimb and hind limb, back and tail were larger than in the lateral surfaces of the forelimb and hind limb, abdomen and scrotum and their diameters ranged from (26.56-39.94 μm). As in the Table (3).

The results of this study showed a convergence in the diameters of the hair located in the area of the muzzle (39.88-46.62 μm) as well as in the ventral surface area of the ear skin where the average diameter of the hair (39.88 μm) may be due to the absence of secondary follicles. Hair follicles are morphological structures that extend oblique into the dermis.

The hair follicle consists of two sheaths surrounding the root of the hair, the internal root sheath, the components of which are visible in the distal third of the hair follicle and consists of three layers, the internal cuticle layer, which is formed by keratinized cells and overlapping with the hair cuticle is followed by Huxley's layer, which consists of one to three rows of keratinized cells rich in Trichohyaline granules, which are pigmented in red and gradually disappear towards the surface of the skin. while Henle's layer appeared to be composed of a single row of keratinized vertical cells whose longitudinal axes are directed towards the longitudinal axis of the follicle, the inner root sheath appeared wrinkled just below the site of the sebaceous glands, and in the large follicle several follicular folds appear, which then disappear into the upper level of the sebaceous gland ducts.

The results of the histological examination of the vertical sections prepared from different areas showed that the outer root sheath connects to the cells of the basal and spinal layer of the epidermis in the upper part of the follicle, as it consists of several layers of cells similar to the cells of the endothelial layer of the epidermis and gradually decreases in thickness towards The hair matrix cells appeared as cubic cells surrounding the dermal papilla of the hair, forming most of the hair follicle. The outer root sheath of the follicle is separated from the dermis by the Glassy membrane, which is glistening with the use of Masson's Trichrome stain of the horizontal segments (Fig.2) and the outer root sheath is surrounded by a layer of dense connective tissue composed of elastic fibers forming a third sheath of dermal connective tissue.

The results of the research showed that the hair follicles in the goat skin differ in size and degree of extension in the depth of the dermis, the primary hair follicles are large in size and extend deep into the dermis, the secondary follicles are smaller, more numerous and shorter length Table (4) and a number of them meet with the primary hair follicle place of opening of sweat and

sebaceous glands It forms a single hairy channel, through which several hairs exit from one opening (Fig. 3).

Most of the areas studied appeared in these follicles called compound follicles except the areas of the snout and ear surfaces, since most of the follicles were of the simple type, and some simple follicles appeared in the skin of the tail and scrotum as these follicles opened independently on the skin. (Fig. 4) a difference in the diameters of the primary follicles taken in the level of the sebaceous glands was shown as the dermis of the skin of the back and tail and the lateral surfaces of the forelimb and hind limb were characterized by containing large diameter follicles when compared to the skin of the ear with their surfaces, the snout, abdomen, scrotum and the lateral surfaces of the limbs as shown in Table.(5). Some secondary follicles appeared surrounded by sebaceous glands only, but there is no relationship between them and the sweat glands and all the areas studied.

The diameters of the secondary follicles ranged from (53.20-86.54 μm) as shown in Table(5) from the observation of the table we find the diameters of the secondary follicles larger in the forget surfaces of the forelimb and hind limb and the skin of the abdomen, scrotum, ear and snout. If compared with the diameters of the secondary follicles of the skin of the back, the lateral surfaces of the forelimb and hind limb and the skin of the tail .

Using Masson's Trichrome stain, the dermis of all the areas studied except the snout appeared to have a red smooth muscle, the arrector pill muscle , which was associated with the primary follicle. This bundle of smooth fibers paired with some elastic fibers extends at the protruding angle formed from the confluence of the primary follicle with the skin surface and extends from the lower third of the primary follicle to the papillary layer of the dermis.

As a result of microscopic examination of the prepared slide of the routinely colored horizontal segments and different areas of the skin, we observed a difference in the arrangement of the primary follicles, as the general triangular arrangement of the follicles emerged as there was a central follicle slightly larger than the lateral follicle and these follicles were arranged linearly in most of the studied areas (Fig.5).

But a triangular arrangement was found in dermis of abdomen skin (Fig.6) . Secondary follicles are not regularly distributed around the primary follicle in most follicular organizations, but secondary follicles are organized on one side of the primary follicle, called the Ectal side hair. The sebaceous glands, the canal of the sweat gland and the arrector pill muscle are organized on the opposite side, which is called the glandular side (Ental side) (Fig.5), in addition to the triangular

Organization of the follicles, the single, bilateral, quadruple and pentagonal arrangement was also found (Fig. 7,8,9,10) respectively.

It was found that there was a clear difference in the hair density per unit area, as these numbers varied in the different areas studied. The skin of the abdominal surface of the ear contains the lowest number of follicles (2.92/mm²) as shown in Table (6). On the other hand, the results of our study showed a difference in the ratio of secondary to primary follicles with different areas studied Table (6). The area of the middle back, front back and lateral surfaces of the limbs showed the highest proportion of secondary follicles, while this ratio decreased to almost zero in the area of the snout and the dorsal and ventral surface of the ear .

Sinus Hair Follicles: Some sinusoidal hair follicles appeared in the dermis of the scrotum and the muzzle and were characterized by their large size in the scrotum skin, reaching a length (2527 μ m) and a diameter (292.6 μ m) at the level of the blood sinus, which can be observed filled with blood between the inner and outer layers of the connective tissue sheath (Fig.11). Structural muscle fibers can also be seen in the outer part of the connective tissue sheath. Sinusoidal hair follicles were not seen in other skin areas studied.

Table (3): The average hair diameter in primary and secondary follicles and the level of sebaceous glands for different areas of local black goat skin (μ m)

The diameter of the hair in the secondary follicle		The diameter of the hair in the primary follicle		Anatomical sites for sampling of skin
1.51	39.92	14.91	98.46	Front back
5.48	35.96	4.08	A106.40	Middle back
2.23	29.56	5.97	90.36	Abdomen
2.82	33.34	14.02	99.7	Tail
3.27	35.86	4.08	106.4	lateral surface of the forelimb
3.41	29.64	1.92	89.04	medial surface of the forelimb
1.74	B*26.56	7.52	79.8	Scrotum
1.7	A*39.94	5.25	106.38	lateral surface of the hind limb
2.7	30.64	2.82	86.52	medial surface of the hind limb

3	39.88	6.91	46.62	Muzzle
4.73	39.88	7.68	66.5	dorsal surface of the ear
-----		6.07	B39.98	ventral surface of the ear

A laterally represents the highest rate of hair diameter in the primary follicle at a probability level P <0.001.

B horizontally represents the lowest average hair diameter in the primary follicle at a probability level P <0.001.

A * horizontally represents the highest average hair diameter in the secondary follicle at a probability level P <0.001.

B * horizontally represents the lowest mean of hair diameter in the secondary follicle at a probability level P <0.001.

All numbers within the table are standard \pm Standard deviation.

Table (4): The primary and secondary follicle lengths and depth within the dermis in different areas of local black goat skin using a (μ m)

ventral surface of the ear	dorsal surface of the ear	Muzzle	medial surface of the hind limb	lateral surface of the hind limb	Scrotum	medial surface of the forelimb	lateral surface of the forelimb	Tail	Abdomen	Middle back	Front back	Anatomical sites for sampling of skin
B465.00	597.8	931.4	1820.2	1835	1766	1795.4	1869.2	2127.6	1728.8	A2180.60	2068.4	Primary follicle length
125.78	140.36	200.09	59.58	126.48	85.91	418.38	147.61	266.5	181.18	144.79	220.13	
B*332.00	371.6	797.6	1677.4	1687.2	1621.2	1662.2	1700.8	1968.2	1595.6	A*2048.00	1807	Depth of the primary follicle
56.32	34.71	50.61	163.82	83.84	119.38	46.13	94.9	140.4	77.95	157.89	245.01	
-----	B**398.60	664.6	864	1063.8	798	931	1014.4	765.6	834.6	A*1329.60	1130.2	Secondary follicle length

	77.6	50.61	98.57	87.94	8.6	68.07	86.63	31.7 5	14 0. 45	113 .36	62. 19	
-----	B*- 265. 60	531.6	730.8	931	665.2	794.8	876.2	622. 8	70 4	A* - 119 7.4 0	99 6.8	Depth of the Secondary follicle
	21.0 3	42.21	105.83	110.96	101.8 6	30.65	124.7 9	86.1 9	10 4. 95	170	19 4.7 3	

A laterally represents the highest primary follicle length at a P <0.001 probability level. B laterally represents the minimum primary follicle length at a P <0.001 probability level.

* A laterally represents the highest primary follicle depth at a P <0.001 probability level. B * horizontally represents the minimum primary follicle depth at a P <0.001 probability level.

** A laterally represents the highest secondary follicle length at a P <0.001 probability level. B ** horizontally represents the lowest secondary follicle length at a P <0.001 probability level.

A * - horizontally representing the highest secondary follicle depth at a P <0.001 probability level. B * - horizontally representing the minimum depth of the secondary follicle at a P <0.001 probability level.

All numbers inside the table are rates \pm of standard deviation.

Table (5): The average of primary and secondary follicle diameters at the level of the sebaceous glands of the different areas of the local black goat skin (μm)

	Diameter of the secondary follicle		Diameter of the primary follicle	Anatomical sites for sampling of skin
8.47	66.52	9	252.72	Front back
3.11	67.84	13.28	259.36	Middle back
4.56	81.12	8.88	238.12	Abdomen
5.82	B*53.22	13.88	246.14	Tail
4.45	62.52	5.43	248.68	lateral surface of the forelimb
4.58	86.64	5.8	235.42	medial surface of the forelimb

13.61	A*86.54	21.36	239.44	Scrotum
5.77	66.5	5.75	A272.62	lateral surface of the hind limb
8.78	79.8	5.13	232.72	medial surface of the hind limb
2.11	69.2	3.43	B109.06	Muzzle
11.45	70.52	4.23	126.36	dorsal surface of the ear
	-----	5.35	113.06	ventral surface of the ear

A laterally represents the highest rate of primary follicle diameter at a probability level $P < 0.001$.

B horizontally represents the lowest rate of primary follicle diameter at a probability level $P < 0.001$.

A * horizontally represents the highest rate of secondary follicle diameter at a probability level $P < 0.001$.

B * horizontally represents the lowest mean of secondary follicle diameter at a probability level $P < 0.001$.

All numbers inside the table are the mean \pm standard deviation.

Table (6): The numbers of primary and secondary follicles using the square millimeter unit of measurement and the ratio of primary to secondary follicles in different areas of local black goat skin

The ratio of primary to secondary follicles		The number of secondary follicles		The number of Primary follicle		Total follicle count	Anatomical sites for sampling of skin
5.86:1	4.65	27.04	0.41	4.64	4.36	31.68	Front back
A-6.88:1	5.55	A**28.52	0.72	4.14	6.01	32.66	Middle back
3.32:1	1.2	10.28	0.45	3.1	0.88	13.38	Abdomen
2.82:1	4.6	22.76	0.6	10	4.16	A32.76	Tail
5.89:1	3.19	25.9	0.31	4.4	3.13	30.3	lateral surface of the forelimb
3.25:1	1.27	9.56	0.37	2.94	1	12.5	medial surface of the forelimb
2.10:1	0.95	7.8	0.58	3.72	1.18	11.52	Scrotum
5.46:1	2.38	26.3	0.3	4.82	2.26	31.12	lateral surface of the hind limb
3.64:1	1.26	12.9	0.36	3.54	1.21	16.44	medial surface of the hind limb
0.2:1	0.59	3.7	2.92	A*18.52	2.92	22.22	Muzzle
0.15:1	0.15	B**1.24	0.66	8.38	0.74	9.62	dorsal surface of the ear
B-0.00:1		-----	0.46	B*2.92	0.46	B2.92	ventral surface of the ear

A laterally represents the highest rate of total follicle count at a probability level $P < 0.001$. B laterally represents the lowest mean total follicle count at a $P < 0.001$ probability level.

* A horizontally represents the highest rate of primary follicle count at a probability level $P < 0.001$. * B horizontally represents the lowest mean number of primary follicles at a probability level $P < 0.001$.

** A horizontally represents the highest rate of secondary follicle count at $p < 0.001$ a probability level. ** B horizontally represents the lowest mean number of secondary follicles at a $P < 0.001$ probability level.

Horizontally, the highest ratio of primary to secondary follicles is represented by a $P < 0.001$ probability level.

Horizontally, B represents the lowest ratio of primary to secondary follicles at a probability level $P < 0.001$.

All numbers inside the table are the mean \pm standard deviation.

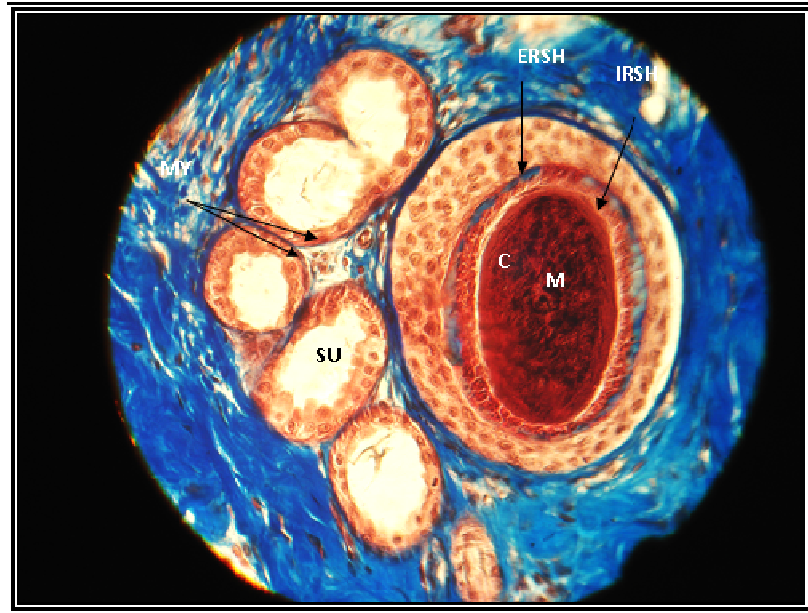


Figure 1. A horizontal section taken from the lower third of the epidermis of the lateral surface of the forelimb. The medulla M, the cortex C, the inner root sheath IRSH, the outer root sheath ERSH with the presence of the SU secretory units of the apical sweat glands and the presence of the myofilaments epithelial cells MY (Masson's Trichrome stain, X 240).

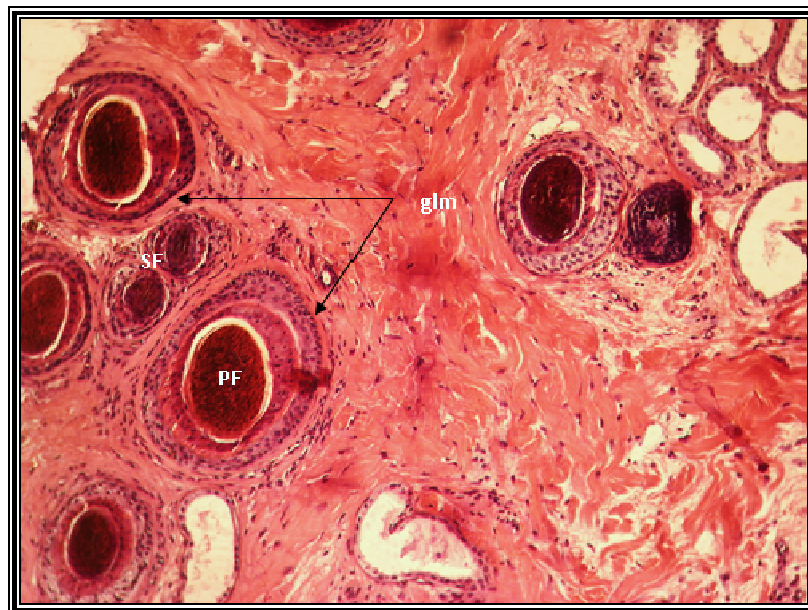


Figure 2. Horizontal section of the skin of the lateral surface area of the forelimb. The glassy membrane glm around primary follicle PF with cross sections of SF secondary follicles (Hematoxylin and Eosin stain, X165).

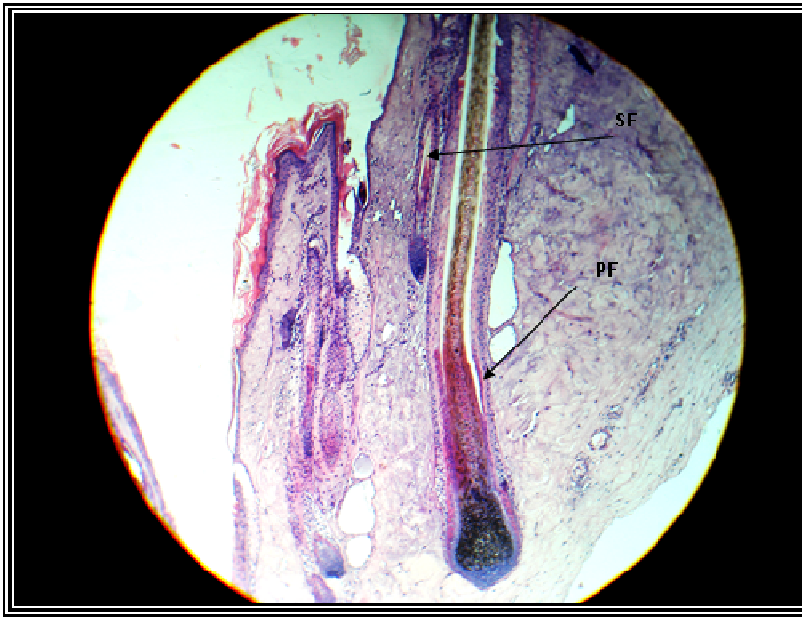

Figure 3. A vertical section of the skin of the medial surface region of the hind limb . The large size and deep extension of the primary follicle PF into the dermis and the small size of the secondary follicle SF and its low extension into the dermis (Hematoxylin and Eosin stain, X75).

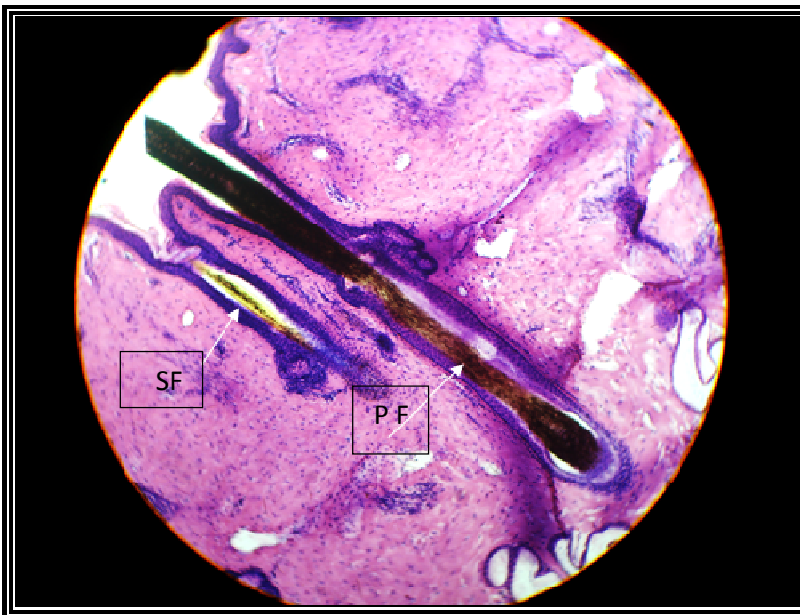

Figure 4. A vertical section of the skin of the scrotum. The Primary hairs follicle PF and secondary hair follicles SF which open in close proximity to the primary follicle. (Hematoxylin and Eosin stain, X46).

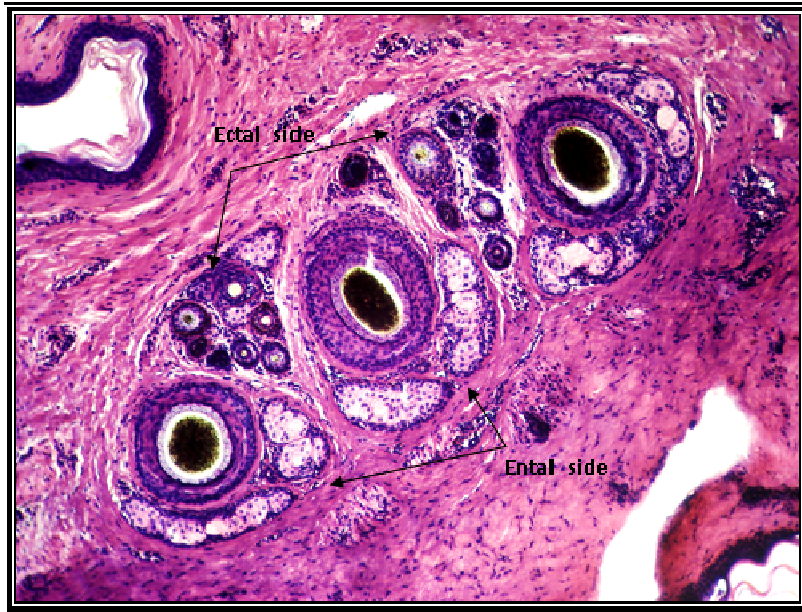

Figure 5. Horizontal section of the skin of the lateral surface area of the forelimb. The triangular arrangement arranged in alignment of the primary follicles with secondary follicles being present, the sebaceous glands, the sweat gland duct, and the epithelium muscle occupied the Ental side, while the secondary follicles occupied the opposite side, called the Ectal side (Hematoxylin and Eosin stain, X 165).

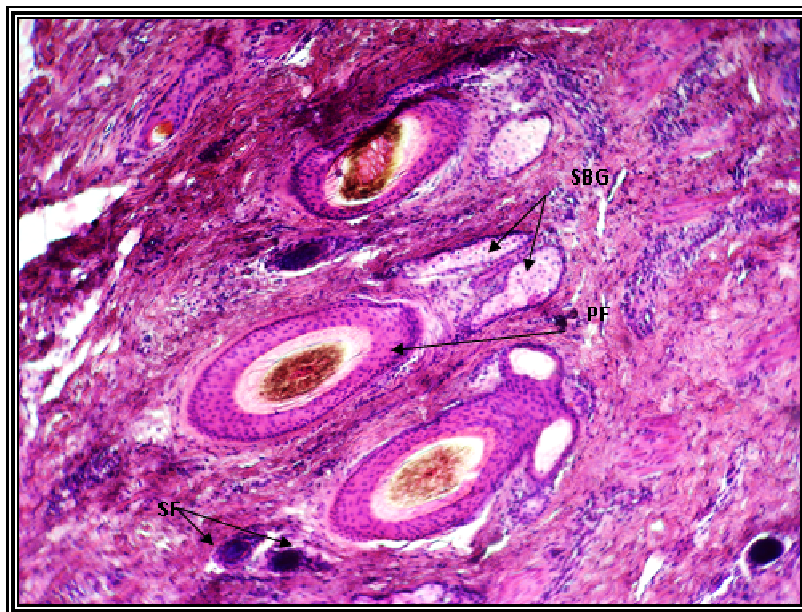


Figure 6 .A horizontal section of the skin of the abdominal region. The triangular arrangement of the primary follicles PF with the presence of secondary follicles SF and sebaceous glands SBG. (Hematoxylin and Eosin stained, X165).

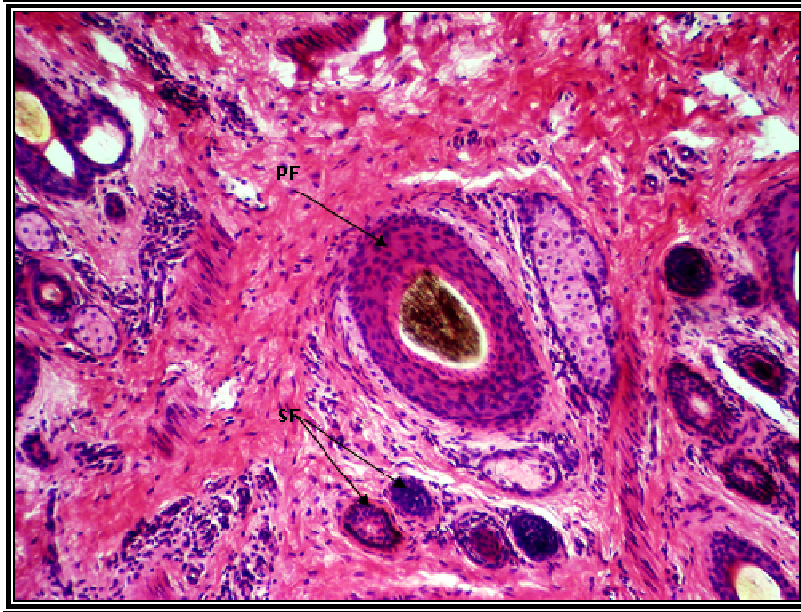


Figure 7.Horizontal section of the skin of the lateral surface of the hind limb, The single arrangement of primary follicles PF with Secondary follicle SF. (Hematoxylin and Eosin Stain, X 165).

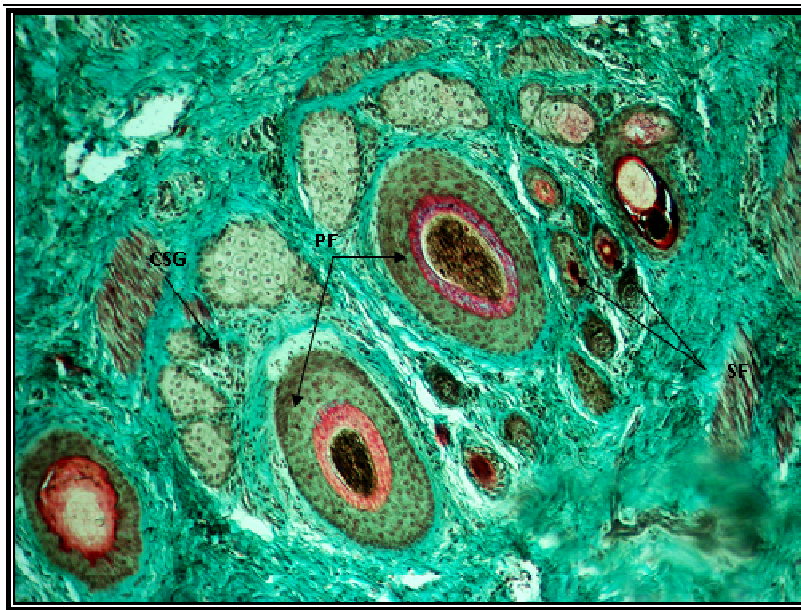


Figure 8.Horizontal section of the skin of the lateral surface area of the hind limb. The binary arrangement of primary follicles PF with secondary follicles SF and the duct of the apical secretory gland CSG. (Masson's Trichrome stain, X 165).

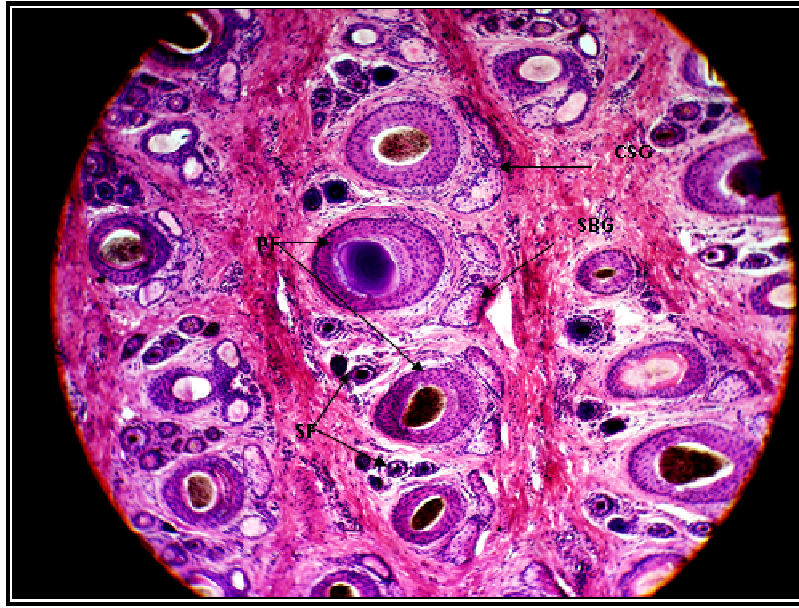


Figure 9.Horizontal section of the skin of the lateral surface area of the forelimb. The quadrilateral arrangement of primary follicles PF with secondary follicles SF and sebaceous glands SBG and sweat gland duct is apical secreting CSG. (Hematoxylin and Eosin stain, X90).

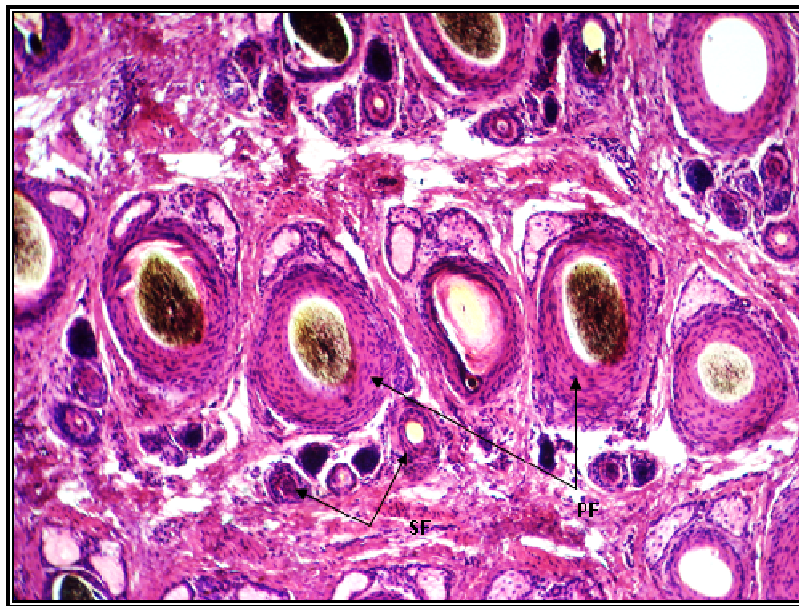



Figure 10.Horizontal section of the skin of the tail region. The pentagonal arrangement of primary follicles PF with low numbers of SF secondary follicles. (Hematoxylin and Eosin stain, X 115).

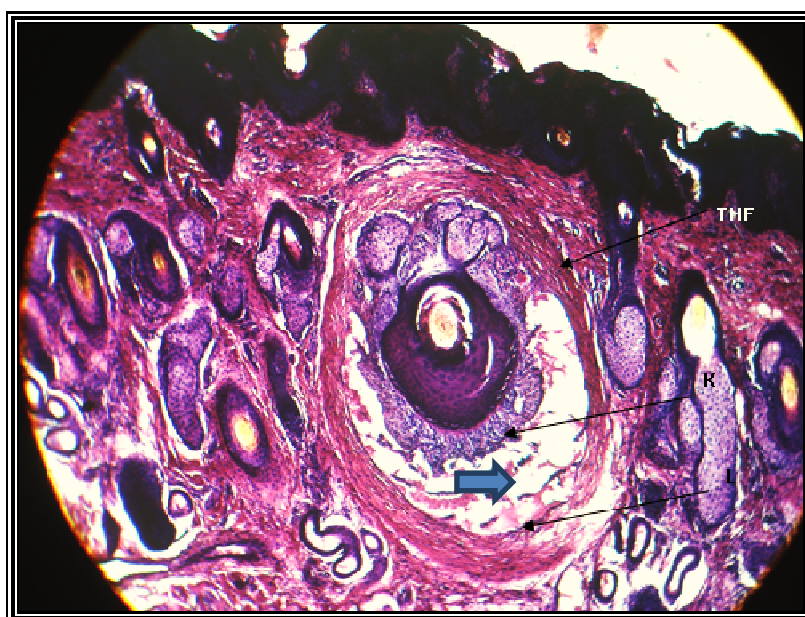

Figure 11.Vertical section of the skin of the muzzle . Tactile hairs follicular THF are distinguished by their large size and the presence of the blood sinus ()between the inner layer of the connective tissue sheath K and the outer layer has L. (Hematoxylin and Eosin stain, X 90).

DISCUSSION

Hair in mammals an elongated horny structure found in the skin covering all parts of the body except for the foot pads, hooves, and the outer parts of the genitals, nipples and lips (12).This is consistent with the results of our study where it appeared the hair located in the hair follicle Centre in the primary and secondary follicle and distributed unevenly in the regions studied.

The results of the researchers in different animals agreed with results of our research in goats that the hair is composed of three parts: the hair shaft, the hair root and the hair bulb(13). Our results also showed the presence of two types of hair in the local black goat skin: coarse and long hair composed of marrow, cortex and cuticle which originating from the primary follicle and forming the outer hair cover of the skin as confirmed by (14, 15). And soft hair smaller diameter free from the marrow which arise from the secondary follicle forming the inner hair cover ,as indicated by this is (16). In his search for the skin of Kashmiri goats under stressed (17). The presence of this difference in his study of the types of woolen fibers of some genetic aggregates of Iraqi sheep.

The diameters of both types of hair differed: coarse hair appeared with diameters ranging from (39.98-106.39 μm) and fine hair appeared with diameters ranging from (26.56-39.94 μm). The diameter of the hair in both types of follicles in the skin of the back and the lateral surfaces of the limbs and the tail was larger than in the skin of the scrotum, the ear with its two surfaces and the lateral surfaces of the limbs and the skin of the abdomen. In the snout, the hair diameters ranged from (39.88-46.62 μm) which is consistent with what said in his study of the qualities of some body measurements and the physical qualities of local goat hair (18).

Where this researcher pointed out that the hair diameters are different between areas of the body and the rate of hair diameter was high (105.46 μm) in the right side of the animal and at the level of the last rib, while our results showed that the rate of hair diameter in the primary follicle ranged from (39.98 μm) for the skin of the ventral surface of the ear and (106.40 μm) in the skin of the back and the lateral surface of the limbs in the primary follicles and for the rest of the areas between these two numbers.

The average hair diameter in the secondary follicles ranged from (26.56 μm) in the skin of the scrotum and (39.94 μm) for the skin of the lateral surface of the hind limb and for the rest of the areas between these two numbers.

Our results clearly showed at the level of the distal third of the hair follicle that the hair follicle at this level consists of the inner root sheath consisting of three layers from the inside to outside, the inner cuticle layer followed by Huxley's layer and Henle's layer, which is consistent with (19, 20) in humans and different areas of the body and in different animals (21, 22). The internal root sheath appeared wrinkled just below the site of the sebaceous gland and in the large follicles where several follicular folds appeared, which then disappear where they do not appear in the upper levels of the sebaceous gland ducts in American goats (23).

The outer root sheath appeared composed of several layers of cells similar to the cells of the germinativum layer of skin epidermis. This is due to the connection of the outer root sheath with the cells of the basal and spinal layer of the epidermis in the upper part of the follicle. This is consistent with (21) in different animals. The follicle was separated from the dermis by a glassy, shiny membrane where it appeared clear by using Masson's Trichrome stain (19) in humans and (22) in different animals and for different areas of skin.

classified hair follicles in this study, depending on the size and degree of extension in the depth of the dermis and its relation to the skin glands to long and large hair follicles are primary hair follicles and smaller, more numerous and shorter follicles are secondary hair follicles. also

noted this in American goats(23). And matched that (24,17) in Iraqi sheep for different areas of the body.

This results and some of the studied areas showed that some secondary follicles open independently on the skin, but close to where the primary follicles open. this is consistent with (25) in Iraqi goats, and (23) in American goats. secondary follicles often meet with the primary hair follicle at the level of the opening of the sebaceous and sweat glands, forming a single hair channel from which several hairs emerge from a single opening.

These are called composite follicles, which have appeared in all the studied areas and in different numbers. Except for the skin of the snout and the dorsal surface of the ear, where composite follicles appeared in very small numbers when compared to simple follicles that appeared in large numbers in these areas. The ventral surface of the ear is characterized by the presence of only simple follicles, while the skin of the tail and scrotum have very few simple follicles.

The presence of simple follicles in some areas of the skin of domestic goats has not been indicated in the available research, as research indicates the presence of compound follicles only in the skin of American goats (23). Iraqi goats (25). In Awassi sheep (17). In Camel (4).

While researchers (3). Study hair follicles in the skin of large ruminants, cow , buffalo is kind of simple as well as in human (26,27). The primary follicle diameters varied according to the areas studied and appeared in the skin of the back, the lateral surfaces of the limbs and the skin of the tail with large diameters when compared to the primary follicle diameters in the skin of the abdomen, the snout, the scrotum, the medial surfaces of the limbs and the dorsal and ventral surfaces of the ear, as they were smaller in diameter .accordingly, the hair diameters of the medial surfaces are smaller than in the back and lateral surfaces of the limb.

The results of our study are consistent with the presence of differences in the diameters of hair follicles with (25). indicated in local goats and specific areas of the body where they indicated the presence of primary follicles with large diameters in the skin of the back followed by the skin of the abdomen and smaller than that in the skin of the scrotum, in this area. These results also showed a difference in the intradermal extension of primary and secondary follicles in the skin areas studied .In general, it has been observed that there is a direct relationship between the amount of follicle extension and the thickness of the dermis. There is no indication of this relationship in the available research

The hair density calculated in a particular area varied according to the areas studied where the tail skin was characterized by a high hair density of (32.90/mm²) while the lowest hair density appeared in the skin of the abdominal surface of the ear reaching (2.92/mm²) only. While reported that the hair density of goat skin was (10.00/mm²) in the skin of the abdomen, (30.99/mm²) in the skin of the back, the researchers indicated that the hair density was low (14.12/mm²) in the inguinal area followed by (22.00/mm²) in the skin of the armpit and the highest hair density in the back skin (25). The hair density of the skin of the back in the battered sheep was (53.00/mm²) (28). While the hair density of the front back (17.16/mm²) was lower than the middle back (20.00/mm²) in the awassi sheep (24).

This is consistent with the results of our study, where the hair density of the front back (31.68/mm²) was lower than the middle back (32.66/mm²), but the number of total follicles was higher in our results and this may be due to the difference of gender, sex and age where these elements have a clear effect .

The ratio of primary to secondary follicular density varied in the different areas studied and since the primary follicular density :secondary in the areas of the middle back.

The highest density of fine hair was (28.52 / mm²) in the area of the middle back and the lower density in the areas of the front back and the lateral surface of the hind limb and then the lateral surface of the forelimb and the lower density of fine hair in the skin of the dorsal surface of the ear (1.24/mm²), which indicates that the secondary hair follicles are more abundant in the areas of the back and the lateral surfaces of the limbs , This leads us to the fact that hair in these areas is of good quality and can be used in economic industries.

The arrangement of the follicles in the goat skin differed, the triangular arrangement was predominant in all the studied areas and this was confirmed by (29) in the black bankali goat, but the single and bilateral arrangement was also present and this is consistent with what was indicated by (25) in the local goat. Quadrangular and Pentagram groups have also appeared in varying proportions in the skin of the back, tail and lateral surface of the front limbs only and studies are not available on the presence of Quadrangular or pentagram groups in the skin of local black goats. Most of the secondary follicles are organized in the Ectal side of the primary follicle, the glandular side is located in the sebaceous gland, the sweat gland canal and the hair follicle, which is consistent with what he pointed out (12).

An exception is the skin of the dorsal surface of the ear, where we observe secondary follicles distributed around the primary follicles and this may be due to the absence of the

sebaceous gland on one side for its large size, which does not allow the secondary follicles to regularize on one side.

The erector pill muscle stretched from the lower third of the primary follicle to the papillary layer of the dermis. It is thought to act on the erection of hair during cold or fear, as mentioned (15) in various animals.

Tactile hair follicles appeared in the dermis of the skin of the snout and scrotum, characterized by their large size and length with the appearance of a bloody sinus and not found in the rest of the studied areas (23). indicated that they are present in the dermis of the skin of the snout and eyelid of the American Goat. The presence of sinus hair follicles in specific areas corresponds to the highly specialized nature of their function in tactile sensitization (21).

دراسة نسيجية وشكلية قياسية وطبغرافية مقارنة للشعرة ، الجريبات الشعرية والكثافة الشعرية لجلد ذكور الماعز الأسود المحلي

غادة عبدالرحمن سلطان، مؤيد حسن عبدالرحيم

فرع التشريح ، كلية الطب البيطري ، جامعة الموصل ، الموصل ، العراق

الخلاصة

هدف البحث إلى إجراء دراسة شاملة لتوفير قاعدة معلومات أساسية لمكونات جلد الماعز الأسود المحلي، ولغرض الوصول إلى هذا الهدف فقد تم إجراء دراسات نسيجية وشكلية قياسية وطبغرافية مقارنة لاثنتي عشرة منطقة من جلد الماعز الأسود المحلي واستعمل لهذا الغرض جلد ٢٠ حيواناً ذكراً بالغاً سليماً صحياً وتم اخذ النماذج في فصل الخريف لوحظ وجود نوعين من جريبات الشعر: جريبات كبيرة الحجم وتمتد عميقاً في الأدمة هي جريبات الشعر الابتدائية واخرى اكثر عددا واصغر حجماً واقل عمقا هي جريبات الشعر الثانوية. تنتج الجريبات الابتدائية الشعر الخشن، بينما تنتج الجريبات الثانوية الشعر الناعم. تباينت أقطار الشعر الخشن في المناطق المختلفة بين (106.40-39.98) ميكروميتر بينما تراوحت اقطار الشعر الناعم في المناطق المختلفة بين (39.94-26.56) ميكروميتر وتباينت نسبة الجريبات الابتدائية الى الثانوية وبالتالي الشعر الخشن الى الشعر الناعم باختلاف مناطق الجلد، فقد بلغت نسبة عدد الشعر الخشن الى الناعم 6.88:1 في جلد الظهر الوسطي و 5.89:1 في جلد السطح الوحشي للقائمة الأمامية و 5.86:1 في جلد الظهر الأمامي و 5.46:1 في جلد السطح الوحشي للقائمة الخلفية و 3.64:1 في جلد السطح الأنسي للقائمة الخلفية و 3.32:1 في جلد البطن و ٣.٢٥:١ في جلد السطح الأنسي للقائمة الأمامية و 2.82:1 في جلد الذيل و 2.10:1 في جلد الصفن و 0.20:1 في جلد الخطم و 0.15:1 في جلد السطح الظهري للأذن واخيرا 0.00:1 في السطح البطني للأذن. كانت الجريبات في معظم المناطق المدروسة من النوع المركب حيث تلقتي الجريبات الثانوية مع الجريبات الابتدائية في مستوى انفتاح الغدد الزهمية والعرقية مكونة قناة شعرية واحدة تخرج منها عدة شعرات من فتحة واحدة. وقد تفتح الجريبات الثانوية على السطح مباشرة ولكنها قريبة جدا من مكان انفتاح الجريبة الابتدائية. توجد الجريبات البسيطة في جلد السطح البطني للأذن وبأعداد اقل في جلد الصفن والخطم والسطح الظهري للأذن. تختلف الكثافة الشعرية باختلاف المناطق المدروسة حيث

كانت الكثافة الشعرية كالاتي: الظهر الأمامي 31.68 / ملم²، الظهر الوسطي 32.66/ملم²، والبطن 13.38/ملم²، الذيل 32.76/ملم²، السطح الوحشي للقائمة الأمامية 30.30 /ملم²، جلد السطح الأنسي للقائمة الأمامية 12.50 / ملم²، جلد الصفن 11.52 /ملم²، جلد السطح الوحشي للقائمة الخلفية 31.12 / ملم²، السطح الأنسي للقائمة الخلفية 16.44 /ملم²، الخطم 22.22 / ملم²، جلد السطح الظهري للأذن 9.62 / ملم²، السطح البطني للأذن 2.92 /ملم².

REFERENCES

- 1- Geneser, F.(1986) . Textbook of histology. Munks Gaard. , pp:388-396-397-398.
- 2- Hohl , D. (1990) . Cornified cell envelope. dermatologica .,180: 201-211 .
- 3- Jenkinson, D. M. and Nay, T.(1975). The sweat glands and hair follicles of different species of bovidae . Assuit J. Biol. Sci.; 28:55-68 .
- 4- Abdul Raheem, M.H.; Al-Hety, M. S. and Ahmed, N. S.(1999). Histological and morphological study of the skin of the one humped camel (*Camelus Doredarius*) . Iraqi J. Vet. Sci., 12:1-11.
- 5- Junqueira , L.C.; Carneiro , J. & Kelly , R. O. (1998) . Basic histology. appleton & lange , New York . USA .
- 6- Ali , S. H.; Abdulattif , F. H. and Taher , K.N. (2002) . Effect of age and sex in number of primary and secondary wool follicles in awassi sheep . Al-Qadisya J. Vet. Med. Sci., 1: 58-60 .
- 7- Al-kass , J. E. and Abdel Razzaq F. S. (1983). Goat raising. Mosul University Press.
- 8- Ali, H.A. (2002). Hair production in local goat . 1- seasonal variation in number of hair follicule . Al-Qadisya J. Vet. Med .Sci., 1:58-60 .
- 9- Culling , C. F. A. ; Allison , R. T. and ; Barr , W. T. (1985) . Cellular pathology technique 4th ed. Butterworth ., pp:16,167,214,215,216 .
- 10- Luna , L.G. (1968) . Manual of histological staining methods. 3rd ed. , M.C. McGraw-Hill book company.
- 11- Steel, R.G.D and Torrie , J.H.(1980). Principles and producers of statistics. 2nd ed. New York: McGraw-Hill Book Company Inc., PP:78-80, 107-109,125-127.
- 12- Ryder, M.L.(1973). Hair. 1st ed. London. Edward Arnold. PP: 11-14 .
- 13- Al-Ani, I. M. and Ibrahim, H. M. (1990). Veterinary histology and embryology. Ministry of Higher Education and Research Scientific, House of books for Printing and Publishing, University of Baghdad.
- 14- Winter, T.A. (2002). Physiology, growth and development farm animals, www.siu.edu .
- 15- Caceci, T. (2005). Veterinary histology, V.5, Part I,

- 16- **Sharma , T.(1982).** Histology and histochemistry of skin of the kashmir merino sheep . Ann. Zool.; 19;97-127 .
- 17- **S. H. ; Abdelattif , F. H. and Dagher , A. L.(2002).** Histological study of the skin in awassi sheep . Al- Qadisiaya J. Vet. Med . Sci., 1:39-44.
- 18- **Al- Saigh , M. N. R. (1999).** A study of some body measurements and hair physical characteristics of black Iraqi local goat . The Veterinarian, 2: 45 –54 .
- 19- **Jungueira , L.C. ; Carneiro , J. and Kelly , R.O. (1995) .** Basic histology . 9th ed. America., pp: 347-355.
- 20- **Freinkel , R.K (2001).** Hair . In : The Biology of the skin. D.T. Parthenon Publish, Group , pp: 77-86.
- 21- **Dellmann , H.D. (1994) .** Textbook of veterinary histology. lea & Fibiger. Philadelphia .
- 22- **Banks , W.J. (1993) .** Applied Veterinary Histology . William and Wilkins, Baltimore. London., pp: 341-371.
- 23- **Sar , M. and Calhoun, M. L.(1966).** Microscopic anatomy of the integument of the common american goat . Am. J. Vet. Res., 27: 444-456.
- 24- **Hassan, A. A. (1989).** Seasonal changes in the growth and diameter of the Awassi sheep wool fibers. Master Thesis, College of Agriculture, University of Baghdad.
- 25- **Abdul Raheem, M. H. and Al-Hety, M.S.(1997).** Histological and morphological study of the skin of the black goat . Iraqi J. Vet. Sci., 10: 59-71 .
- 26- **Montagna, W. and Parakkal , P.F. (1974).** The structure and function of skin. Academic press, New York.
- 27- **Steven, A. & Lowe , J . (1997).** Human Histology , Mosby . London .
- 28- **Steinhagen, O. and Brednhann, A. E. J.(1987).** The effect of histological processing on sheep samples SAFR. J. Animal Sci., 17:151-152.
- 29- **Barikhan, M.A. and Talukdar , A. H. (1977) .** Follicle population in black bengal goats . J. Agric. Sci. Camb., 88:251-252.