

IMPACT OF AQUEOUS EXTRACT OF ROSEMARY ON TESTICULAR TISSUE IN MALE RATS WITH HYPERTHYROIDISM

Fouad Ziedan Hamza^{*}, Sumayah Faruq Kasim^{**}, Sarah Qahtan M. Salih^{**}

^{*}Faculty of Veterinary Medicine, University of Kufa, Kufa, Iraq

^{**}College of Health and Medical Technology, Middle Technical University, Baghdad, Iraq.

Corresponding Author: fouadz.alquraishi@uokufa.edu.iq

Keywords: Hyperthyroidism, Rosemary, Levothyroxine.

ABSTRACT

The aim of the study to evaluate the enhanced effect of aqueous extract of rosemary on testis tissue in male rats after inducing hyperthyroidism by L-thyroxin and compare with propylthiouracil effect. The animals (32 male rats) were divided into two groups. The first group was a control group consists of 8 male rats that were treated with distilled water for 12 days and the rest of the animals induced with hyperthyroidism by levothyroxine 0.5 mg / kg subcutaneously for 12 days. After the induction, the animals were divided into four groups each consists of eight male rats. The first group was the control group and they were treated with distilled water for another 12 days, the second group included male rats induced hyperthyroidism were treated with distilled water for 12 days orally, while the third group included male rats induced hyperthyroidism that were treated with propylthiouracil at a dose of 10 mg / kg for 12 days orally, and the fourth group included male rats induced hyperthyroidism that were treated with rosemary extract at a dose of 12 mg / kg for 10 days, orally. The results showed that rosemary extract led to complete healing of testicular tissue, unlike propylthiouracil.

INTRODUCTION

The testes are chiefly involved in tightly twisted seminiferous tubules, which are provided by the loose interstitial connective tissue wherever the steroidogenic Leydig cells are lying (1). Every tubule made up of a basement membrane, peritubular myoid cells, and elastic fibers. inside the basement membrane, seminiferous tubules are filled by

a columnar epithelium that consists of somatic Sertoli cells and germ cells. the close Sertoli cells are linked by tight specialized junctions to form the diffusion barrier, the so-called blood-testis barrier, that divides the seminiferous tubule into two functional sections, the basal and the adluminal. The basal compartment composed of spermatogonia, Sertoli cells, and preleptotene/leptotene spermatocytes (2).

Hyperthyroidism is characterized by increased circulating T4 levels, compromised responsiveness of LH and follicle-stimulating hormone, altered endocrine profile, all of which result in impaired testicular functions, morphology, reduced seminiferous tubule diameter, delayed spermatogenesis, stunted sperm development and reduced sperm motility (3).

Thyroid hormone is a major metabolic regulator of testicular development and function that could influence spermatogenesis (4).

R. officinalis L., publicly known as rosemary, is a herbal plant belonging to the Lamiaceae family and originated from the Mediterranean zone. However, it can be found everywhere in the world. It is an aromatic and perennial plant, bush-shaped with full leaves branches, having up to two meters height and green leaves that exude a characteristic aroma. *R. officinalis* might be applied as a spice in cooking, as food industry natural preservative, and as an ornamental and medicinal herbal plant (5, 6).

Administration of rosemary orally reduced fertility in male albino rats. The weights of reproductive organs were markedly decreased. The weight, size, and secretory function of testes, epididymides, seminal vesicles, ventral prostates, and vasa deferentia are closely regulated by androgens (7).

Propylthiouracil (PTU) is an anti-thyroid drug which prohibits both the synthesis and release of thyroid hormones in thyroid gland (8). Previous studies have shown that transient neonatal hypothyroidism, induced by treatment with PTU, increases testicular size, Sertoli cell numbers, and daily sperm production in the adult rat and mouse (9). This study revealed the effect of aqueous leaves extract of rosemary and Propylthiouracil on testicular tissue in male rats with hyperthyroidism.

MATERIALS AND METHODS

1. Chemicals:-propylthiouracil (PTU) **and**-L-Thyroxine (T4)

2.Preparation of extracts: The leaves of Rosemary were brought from a market in Kufa, the leaves were ground and stored in the dark. 10 g of the powder was stirred in 100 ml of distilled water at 50 °C for half an hour. Then through a rough cloth and a filter paper, the extract was filtered, and then the filter was dried completely by freezing and then it was used (10).

3.Histopathological analysis: The animals were sacrificed under light anesthesia and testis were immediately removed and saved in formalin 10%, and then it was prepared for standard methods of tissue segmentation and examined under a light microscope.

4. Experimental animal design:

Induction of hyperthyroidism by L-thyroxin:

Thirty-two male rats were divided into two groups. The first group included 8 rats, the control group was received 0.1 ml/day distilled water orally by gavage. The second group included 24 rats that were treated with Levothyroxine for 12 days 0.5mg/kg subcutaneously for the purpose of induction of hyperthyroidism (11).

After the induction of hyperthyroidism we divided the animals into 4 groups, each group containing 8 male rats that treated for 24 days as a negative control group, animals were received 0.1 ml/day distilled water orally by gavage for 24 days.

A positive control group (hyperthyroidism), animals were treated subcutaneously for successive 12 days with Levothyroxine 0.5 mg/kg. From the 13th to 24th day the animals were received 0.1 ml/day distilled water orally by gavage. Hyperthyroidism treated with PTU, animals were treated subcutaneously for successive 12 days with Levothyroxine 0.5 mg/kg. From the 13th to 24th day the animals were received 10 mg/kg propylthiouracil orally by gavage. Hyperthyroidism treated with rosemary, animals were treated subcutaneously for successive 12 days with Levothyroxine 0.5 mg/kg. From the 13th to 24th day the animals were received 10 mg/kg aqueous leaves extract of rosemary (*Rosemarinus officinalis*) orally by gavage.

RESULTS

Histological Findings:

The testicular tissue sections findings were different among the experimental groups and the negative control group. In negative control group, the histological section for testis showed normal seminiferous tubular architecture, spermatogenetic activity, and normal interstitial cells and no significant occupied lesion whereas the histopathological section of positive control group showed amyloid accumulation between seminiferous tubules with blood vessels congestion and damage in the some connective tissue septa of seminiferous tubules as presented in (Fig. 1.) Histological section of testis treated with 10 mg/kg propylthiouracil showed sever blood vessels congestion with necrotizing cells of seminiferous tubules including spermatogonia cells, sertoli cells and primary spermatocytes, seminiferous tubules flattened and elongated with damage of connective tissue of septa between seminiferous tubules to give strong attachment between these tubules as presented in (Fig. 2.). Finally in (Fig. 3.) The histological section of testis that treated with 10 mg/kg aqueous leaves extract of rosemary (*Rosemarinus officinalis*) showed the testicular texture back to normal structure after successive twelve days of treatment.

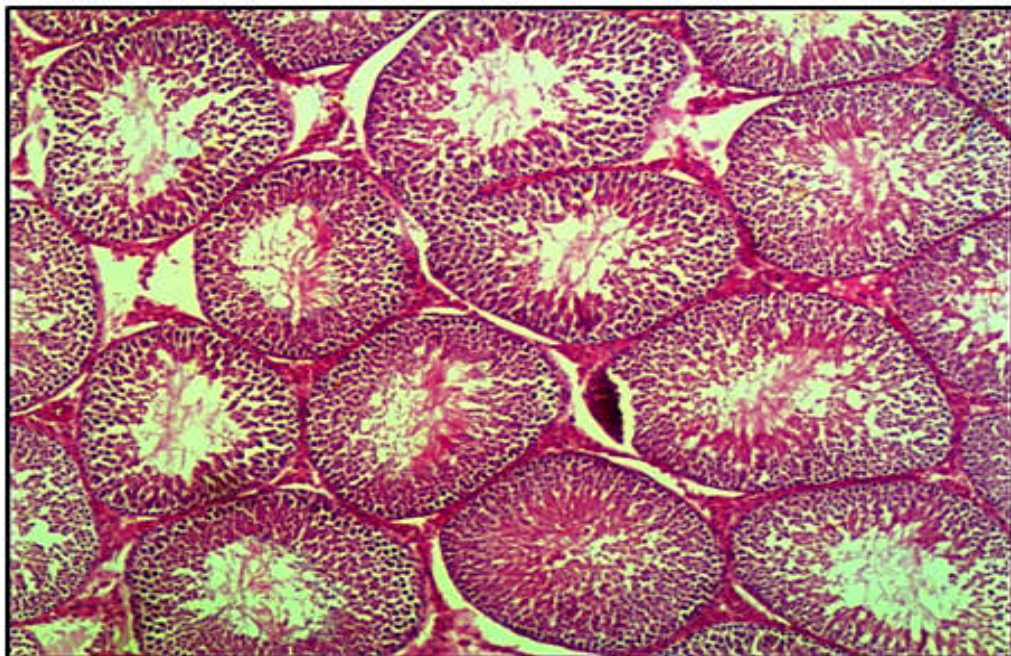


Fig.1. (A) Negative control group. Histological section for testis is showing normal seminiferous tubular architecture, spermatogenetic activity, and normal interstitial cells and no significant occupied lesion in the testis section, H&E, 20X.

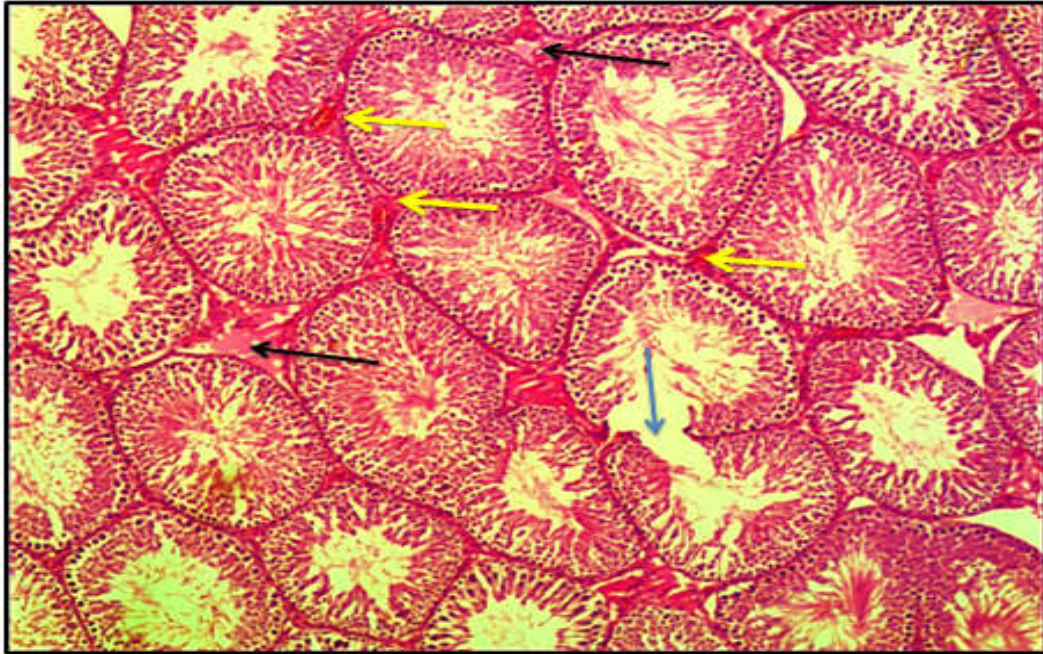


Fig 1(B) Positive control group given Levothyroxine 0.5 mg/kg s.c. the histopathological section of testis is showing amyloid accumulation between seminiferous tubules (black arrow) with blood vessels congestion (yellow arrow) and damage in the some connective tissue septa of seminiferous tubules (blue arrow),

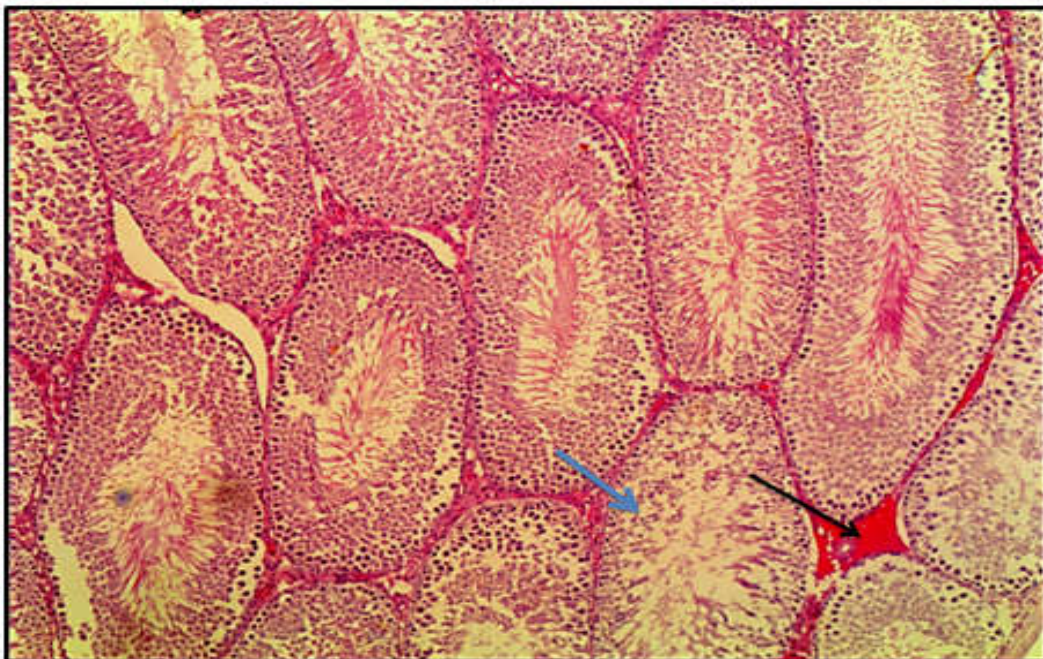


Fig.2. Group treated with 10 mg/kg propylthiouracil (A) Histological section for testis is showing sever blood vessels congestion (black arrow) with necrotizing cells of seminiferous tubules including spermatogonia cells, sertoli cells and primary spermatocytes (blue arrow), H&E, 20X.

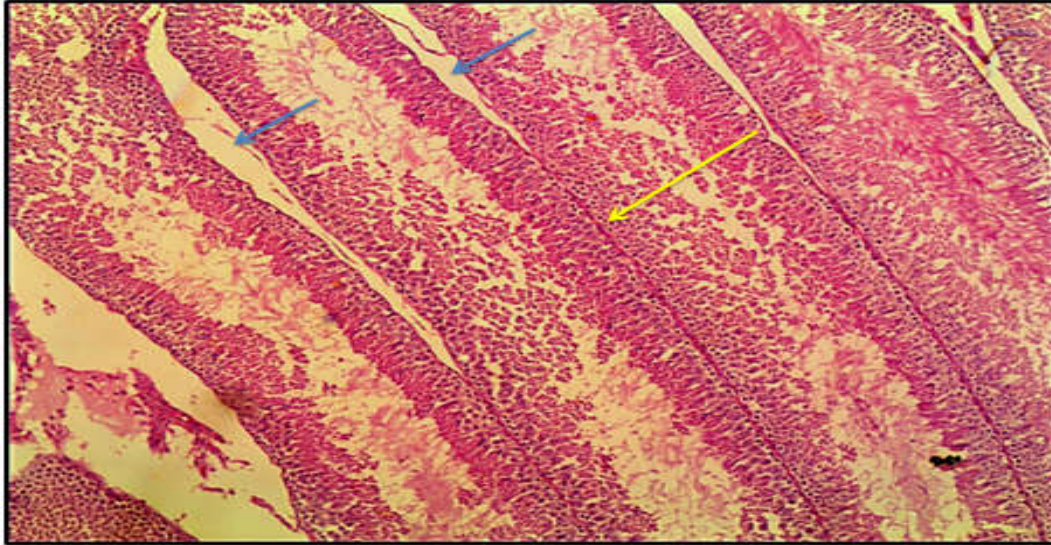


Fig 2 : Group treated with 10 mg/kg propylthiouracil (B) Histopathological section for testis is showing seminiferous tubules flattened and elongated (blue arrow) with damage of connective tissue of septa (yellow arrow) between seminiferous tubules to give strong attachment between these tubules, H&E, 20X

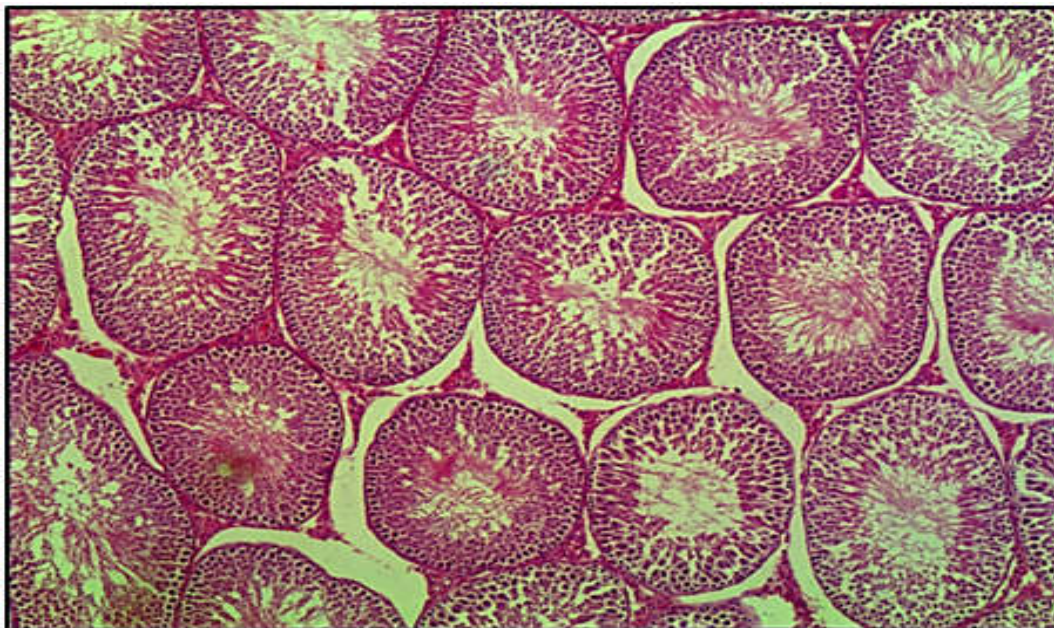


Fig.3. Group treated with 10 mg/kg aqueous leaves extract of rosemary (*Rosemarinus officinalis*). The histological section of testis treated is showing the testicular texture back to normal structure after (12) days of treatment, H&E, 20X .

DISCUSSION

Thyrotoxicosis in rats is dealt with late Leydig cell maturation and alterations of spermatogenetic (12). Hypothyroidism and thyrotoxicosis are dealt with changes affected functions of the endocrine, sexual, or reproduction (13). The propylthiouracil treatment, an antithyroid remedy, caused a maturation to cease of spermatogenesis, lowering the number of Leydig cells, reduce the tubular diameter, lead to interstitial edema and condensation of the basement membrane (14).

In contrast, rosemary showed a substantial beneficial effect in comparison of PTU on the testicular tissue; in which the latter caused many defectives. A previous study showed that oral administration of rosemary reduced fertility in male albino rats (15). Rosemary (*Rosemarinus officinalis*) is one of the household herbs that include a number of phytochemicals, including camphor, betulinic acid, caffeic acid, ursolic acid, the antioxidants carnosic acid and rosmarinic acid, it used in traditional medicine to treat a set of troubles (16). Extracts of rosemary leaves contain flavonoids and phenols which possess a diversity of bioactivities in vitro including antibacterial, antitumor, antinociceptive, antioxidant, antidiabetic, antithrombotic, antiulcerogenic, anti-inflammatory agents, and antidiuretic (17).

Therefore, this paper established scientifically the use of the aqueous leaf extract of rosemary as an ameliorator in recovering the testicular changes that had induced by levothyroxine, rosemary showed full recovery in these changes represented in normal testes tissue with no significant occupied lesion in comparison to the effect of PTU. The reason for the improvement in the testicle using the aqueous extract of rosemary can be attributed to the fact that it contains many antioxidants.

Acknowledgements:

Many thank to Dr. Saif Sattar Rasheed for his help and all the facilities in reading the histopathological sections.

REFERENCES

- 1-Riley, S. C., Leask, R., Denison, F. C., Wisely, K., Calder, A. A., & Howe, D. C. (1999). Secretion of tissue inhibitors of matrix metalloproteinases by human fetal membranes, decidua and placenta at parturition. *Journal of Endocrinology*, 162(3), 351-359.
- 2-Cheng, C. Y., & Mruk, D. D. (2002). Cell junction dynamics in the testis: Sertoli-germ cell interactions and male contraceptive development. *Physiological reviews*, 82(4), 825-874.
- 3-Wortsman, J., Rosner, W., & Dufau, M. L. (1987). Abnormal testicular function in men with primary hypothyroidism. *The American journal of medicine*, 82(2), 207-212.
- 4-Wagner, M. S., Wajner, S. M., & Maia, A. L. (2008). The role of thyroid hormone in testicular development and function. *The Journal of endocrinology*, 199(3), 351.
- 5-González-Trujano, M. E., Peña, E. I., Martínez, A. L., Moreno, J., Guevara-Fefer, P., Deciga-Campos, M., & López-Muñoz, F. J. (2007). Evaluation of the antinociceptive effect of *Rosmarinus officinalis* L. using three different experimental models in rodents. *Journal of ethnopharmacology*, 111(3), 476-482.
- 6- Rašković, A., Milanović, I., Pavlović, N., Čebović, T., Vukmirović, S., & Mikov, M. (2014). Antioxidant activity of rosemary (*Rosmarinus officinalis* L.) essential oil and its hepatoprotective potential. *BMC complementary and alternative medicine*, 14(1), 225.
- 7-Agrawal, S., Chauhan, S., & Mathur, R. (1986). Antifertility effects of embelin in male rats. *Andrologia*, 18(2), 125-131.
- 8-Moriyama, K., Tagami, T., Usui, T., Naruse, M., Nambu, T., Hataya, Y., ... & Nakao, K. (2007). Antithyroid drugs inhibit thyroid hormone receptor-mediated transcription. *The Journal of Clinical Endocrinology & Metabolism*, 92(3), 1066-1072.
- 9- Hess, R. A., Cooke, P. S., Bunick, D. A. V. I. D., & Kirby, J. D. (1993). Adult testicular enlargement induced by neonatal hypothyroidism is accompanied by increased Sertoli and germ cell numbers. *Endocrinology*, 132(6), 2607-2613.

- 10-Amin, A., & Hamza, A. A. (2005).** Hepatoprotective effects of Hibiscus, Rosmarinus and Salvia on azathioprine-induced toxicity in rats. *Life sciences*, 77(3), 266-278.
- 11- Panda, S., & Kar, A. (2014).** Antithyroid effects of naringin, hesperidin and rutin in L-T4 induced hyperthyroid rats: Possible mediation through 5' DI activity. *Pharmacological Reports*, 66(6), 1092-1099.
- 12-Rijntjes, E., Wientjes, A. T., Swarts, H. J., de Rooij, D. G., & Teerds, K. J. (2008).** Dietary-induced hyperthyroidism marginally affects neonatal testicular development. *Journal of andrology*, 29(6), 643-653.
- 13-La Vignera, S., Vita, R., Condorelli, R. A., Mongioì, L. M., Presti, S., Benvenga, S., & Calogero, A. E. (2017).** Impact of thyroid disease on testicular function. *Endocrine*, 58(3), 397-407.
- 14-Tahmaz, L., Gökalp, A., Kibar, Y., Kocak, I., Yalçın, O., & Özeran, Y. (2000).** Effect of hypothyroidism on the testes in mature rats and treatment with levothyroxine and zinc. *Andrologia*, 32(2), 85-89.
- 15- Nusier, M. K., Bataineh, H. N., & Daradka, H. M. (2007).** Adverse effects of propranolol on reproductive function in adult male mice. *Pakistan journal of biological sciences: PJBS*, 10(16), 2728-2731.
- 16- Ahmed, N. A., Nahed, M., & El-Aal, R. A. A. (2015).** Assessing the effect of Thyme and Rosemary as antiaflatoxicosis on fertility in male rats. *J. Am. Sci*, 11(12), 294-302.
- 17-Razavi-Azarkhiavi, K., Ali-Omrani, M., Solgi, R., Bagheri, P., Haji-Noormohammadi, M., Amani, N., & Sepand, M. R. (2014).** Silymarin alleviates bleomycin-induced pulmonary toxicity and lipid peroxidation in mice. *Pharmaceutical biology*, 52(10), 1267-1271.