



HYDROPERICARDIUM HEPATITIS SYNDROME IN CHICKENS/ARTICLE REVIEW

Zahraa A. AL-Noaimy^{1*}, Ayman A. AL-hially^{2*}

*Department of pathology and poultry diseases, college of Vet. Medicine, university of Mosul

ABSTRACT

Article information
Article history:
Received: 16/2/2022
Accepted: 16/3/2022
Available: 31/3/2022

Keywords:

hepatitis, adeno virus, chickens,
inclusion body, hydropericardium

DOI:

[10.33899/magrj.2022.132871.1164](https://doi.org/10.33899/magrj.2022.132871.1164)

Correspondence Email:

zahraadil65@uomosul.edu.iq

Hydropericardium hepatitis syndrome is an acute infectious disease of broiler chickens characterized by high mortality, accumulation of fluids in the pericardial sac and necrosis of hepatocytes, during 1987 the virus was isolated from chickens in Angara near Karachi city in Pakistan and the disease takes its name of this city. It is reported in China in 2015 in birds of 3-6 weeks in broiler chickens causing sudden death with high mortality reaches up to 75%. Avian adenovirus divided into 3 genera: Atadodnavirus, Siadenovirus, and Aviadenovirus the last one divided into 5 species A to E subgroup 1 strain 4 causing (Hydropericardium hepatitis syndrome). Subgroup 2 causing turkey (hemorrhagic enteritis, marble spleen disease). Subgroup 3 causing (Egg drop syndrome EDS). strain D and E produce inclusion body hepatitis while strain 1 causing (quill bronchitis). outbreaks of the disease producing economic losses for the poultry industry. Both vertical and horizontal transmission have an important role in the spreading of the disease. gross examination of the liver showing friable, enlargement, paleness of the liver. the kidney is swelling and hemorrhage with pale areas of necrosis in the parenchyma, pericardium is filled with clear or jelly fluids but histological changes showing hepatitis, nephritis and presence of basophilic intranuclear inclusion bodies. There are many tests can be used for the diagnosis such as PCR, ELISA, neutralization test. We concluded that the disease has economic importance due to high mortality and high losses of chicken's meat production, so, biosecurity and vaccination are essential for preventing the infection.

College of Agriculture and Forestry, University of Mosul.

This is an open access article under the CC BY 4.0 license (<https://magrj.mosuljournals.com/>).

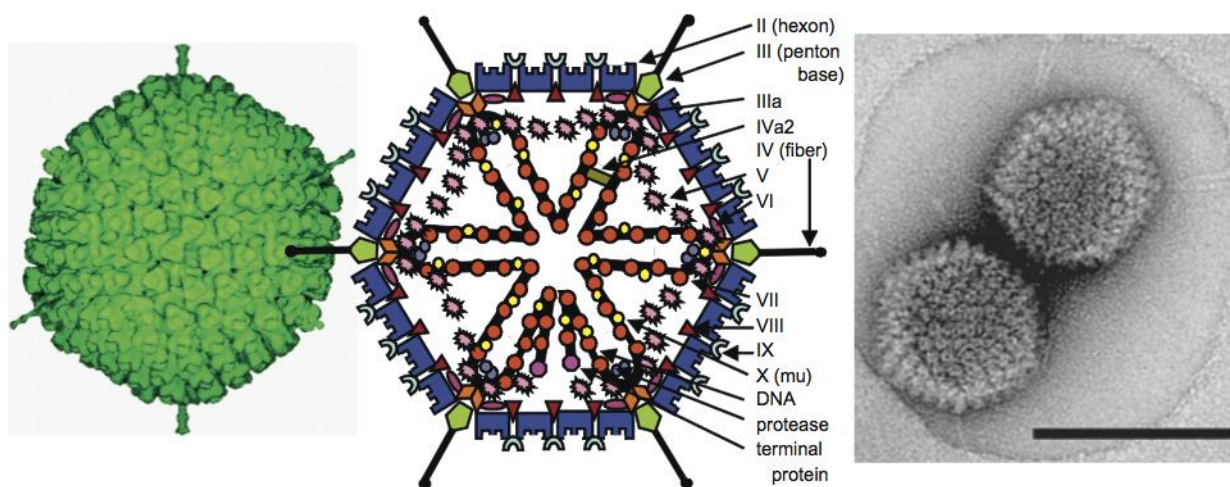
INTRODUCTION

Avian adenovirus is a group of pathogens causing problems for poultry production and economic losses. The first isolation of the virus during 1949 the virus was propagated in Chicken embryo which taken from a case of lumpy skin disease. (Balamurugan and Kataria, 2004). FAV produce inclusion body hepatitis (IBH) in broiler chickens. IBH along with the hydropericardium syndrome. (HPS). Popularly called litchi heart disease in India (Hafez,2011). Isolation of the virus from a quail respiratory infections outbreak during 1950 and affects birds of 3 to 6 weeks old of broiler chicks (Abdul- Aziz and AL-Attar,1991). the disease was recorded in Iraq for the first time in 1991 in Mosul city (Danial *et al.*,2005).and the serotypes 2, 3 and 5 were isolates and diagnosed in the country in 1995. (Li ,2018). FAV nonenveloped double stranded DNA linear viruses, lie under the genus adenovirus in the family

adenoviridae the disease vertically transmission via the egg. Horizontal transmission through contaminated eggs and tools (Shamin *et al.*, 2009). It may cause in immunosuppression leading to increase the susceptibility to secondary infections (Rahul *et al.*, 2005). The symptoms and lesions vary according to serotypes of the virus as in hydropericardium syndrome, inclusion body hepatitis, egg drop syndrome, gizzard erosion, enteritis and poor growth (Domanska-Blicharz *et al.*, 2011; Asthana *et al.*, 2013; Lim *et al.*, 2012). For detection of viral genome by using (PCR) (Dahiya *et al.*, 2002). An outbreak during last years have been reported in different parts of India (Memon *et al.*, 2006; Gowthaman *et al.*, 2012; Senne *et al.*, 1994)

ETIOLOGY:

The avian adenovirus is nonenveloped double-strand DNA under the genus *Aviadenovirus* in the family *Adenoviridae* viral genome have a number of nonstructural and structural proteins. The virion is composed of 252 capsomeres surrounded with a core 60-65nm. The capsomeres are attached to triangular surface and six capsomeres along with every edge, 240 hexons 8-9.5 nm diameter. And 12 vertex capsomeres (penton bases). Vertex carry projections known as fibers. the virus exhibits resistant to lipid solvents such as chloroform., ether, 50% alcohol, phenol 2%. They are resistant to variations in PH between 3 and 9 but inactivated when exposure for 30 minute to heat. (Hafez, 2011; Senne *et al.*, 1994). The family adenoviridae was divided into two family: the genus mastadenovirus isolated from mammalian and aviadenovirus isolated from bird (Benkő *et al.*, 2005). The genus aviadenovirus regarded as group 1 Aviano virus (AAV), Contains 11 of 12 european adenovirus serotypes, they classified into five molecular groups (A to E), the genus siadenovirus regarded as group 2, including hemorrhagic enteritis virus of turkeys (HEV). Adenovirus of avian splenomegaly in the chickens (AASV). The genus Atadenovirus regarded as group 3 including egg syndrome virus (EDS) (Jensen and Villegas, 2005), group 4 regarded to cause hydropericardium syndrome (HPS). (Balamurugan and Kataria, 2004; Gowda and Satyanarayana, 1994).



(Stewart & Burnett 1993).

Economic Significance:

In the present time it is difficult to detect the economic importance of the virus due to variability in disease so the increase in mortality and poor growth in flocks suffering from the disease results in economic losses (Balamurugan and Kataria, 2004).

Significance of public health:

There is no history of human infection by the virus, therefore the public health dangerous appeared minimal.

TRANSMISSION:

HPS is a contagious disease (Ganesh et al., 2002), transmitted vertically causing spreading of the disease so the virus can be detected in embryonating egg. Transmission of the disease horizontally is another way for spreading via contaminated food with infected feces which are taken orally (Toro *et al.*, 2001).

PATHOGENCITY:

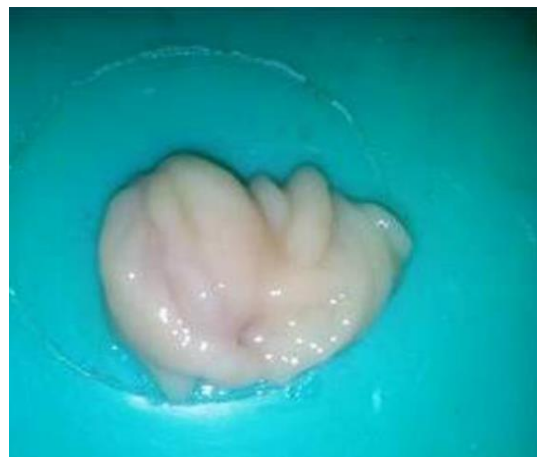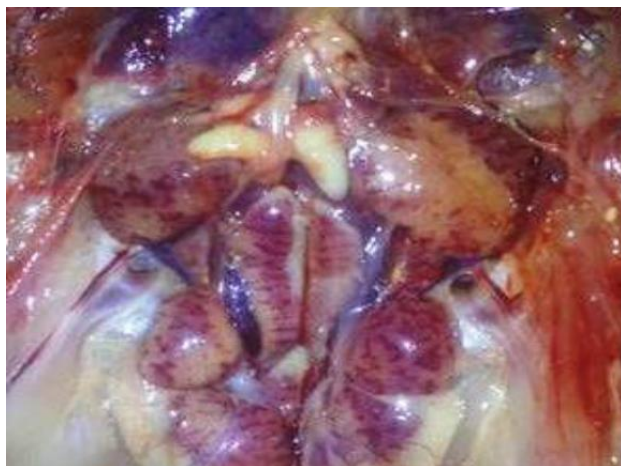
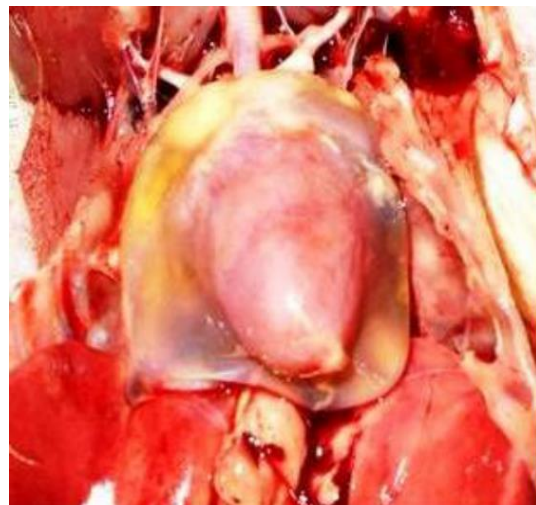
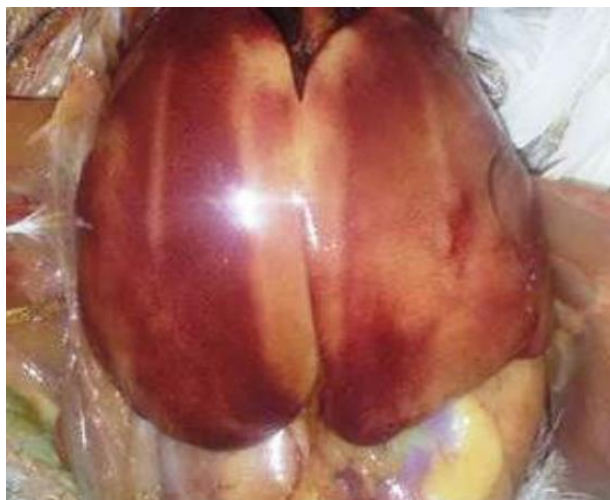The incubation period 5-18 days, so the virus has the affinity for hepatic and endothelial cells (Akhtar,1992; Todd,2000). The ability of the virus to induce the disease is depend on the variations of different serotypes and the relationship between genotype and virulence not between virulence and serotype. Many factors associated with (HHS) play an important role to induce the disease such as: toxic fat agent mycotoxins, sodium chloride and the infection with the immunosuppressive diseases such as: Gumboro (IBD, and Reo virus infection (CAV) resulting in attenuating of immune response toward the disease (Shane and Jaffery,1997; Naeem *et al.*,1995; Deepak,1998). The (HPS) virus has affinity to affect the lymphatic tissue that result in immunosuppression (Aliev *et al.*,1997; Ganesh *et al.*,2001b). So, these diseases may be predisposing for HPS, when the virus enters the body initial multiplication occur in small and large intestine. Viraemia occur and spreading to different organs like kidney, liver, bursa, bone marrow and respiratory tract the virus can be isolated from these organs (Naeem *et al.*,2021; Ganesh *et al.*,2001).

SIGNS AND INCUBATION PERIOD:

The period of incubation of the disease is from 5-18 days with mean of 10 days (Akhtar,1992). Which is depend on the dose, age of the birds, route of infection, (Akhtar,1995). In experimental infection the incubation period is 48-72 hr (Aliev *et al.*,1997). Another study, the incubation period varied between 2-4 days (Ganesh *et al.*,2001b). The diseased birds have no appearance of specific symptoms but a sudden death was observed from 2-5 DPI (Anjum,1991; Afzal *et al.*,1991; Ganesh *et al.*, 2002). The percentage of mortality is up to 80% occur in mature broiler flock of 3-5weeks of age (Jaffery,1988; Asrani *et al.*,1997; Voss *et al.*,1996) birds of sporadic cases may become dull and depressed in the terminal stages, huddle in corner, have a ruffled feather they showing different postures the beak and chest are resting on the ground, the eye lids were closed. there are no prominent signs been reported in (HHS) (Asrani *et al.*,1997).

GROSS LESIONS:

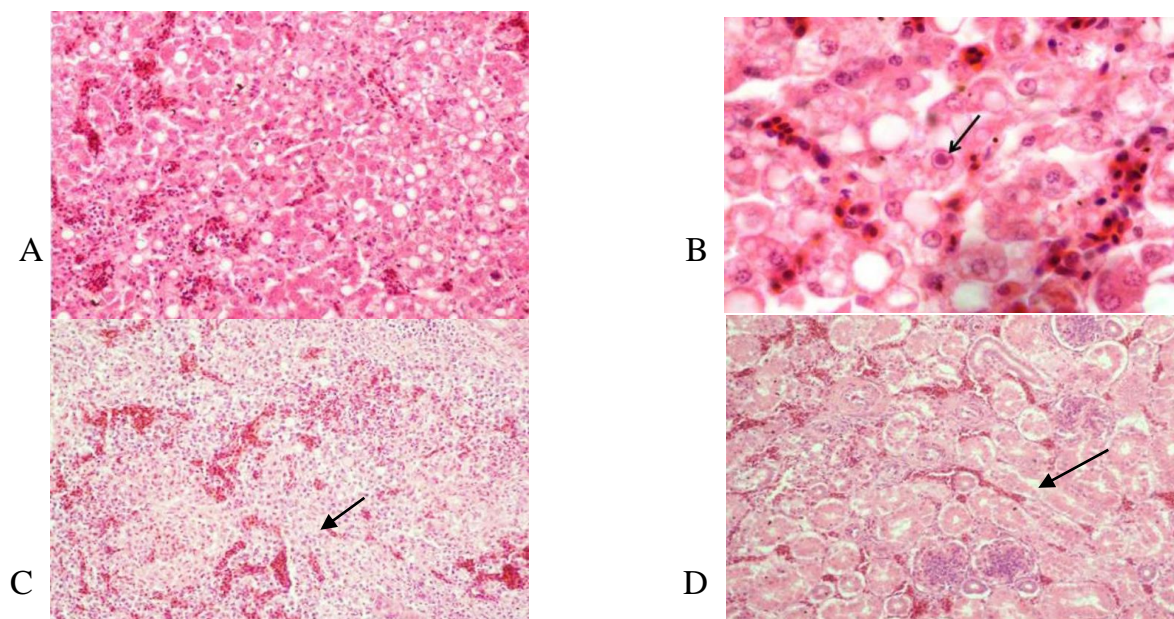
There is accumulation of fluids have a green color or colorless, watery to jelly-like fluid in the pericardium with range between 4-20 ml and PH of 7 in 90% of the affected birds (Ganesh *et al.*,2002; Gallina *et al.*,1973). Misshapen of the heart with floating in the apex of pericardial sac (Anjum *et al.*,1989; Kumar *et al.*,1997). There is a petechial hemorrhage and yellowish discoloration of cardiac fat. (Asrani *et al.*,1997). The liver changes include yellow paleness friable, swollen and large areas of mottled focal necrosis and ecchymotic or petechial hemorrhage. the lungs are congested. Urates are deposits in the ureters and tubules of kidney (Anjum *et al.*,1989; Abdul-Aziz and Hasan,1995). An experimental study showing thymic and bursal atrophy (Asrani *et al.*,1997) in the pancreas there are a white pin point of necrosis and ventricular erosions in chickens (Nakamura *et al.*, 2000; Palanivelu *et al.*,2014).



Pictuer2: A. enlarged liver with areas of paleness and congestion; B. clear fluids accumulated in the pericardial sac; C. Swelling of the kidneys with pale areas of necrosis .and hemorrhage in the parenchyma; Oedema and enlargement in the bursa of Fabricius (Palanivelu *et al.*,2014).

MICROSCOPIC LESIONS:

The liver is the most important organ which many histological changes are detected such as infiltration of mononuclear inflammatory cells, focal areas of coagulative necrosis, presence of round or irregular basophilic intranuclear inclusion bodies. The hepatocyte is filling in the entire enlarged nucleus. (Anjum *et al.*, 1989). necrosis and degeneration of the hepatocyte. (Abdul-Aziz and Hasan, 1995). The lung lesions showed edema and infiltration of inflammatory cells. Congestion of blood vessels (Asrani *et al.*, 1997). There is hemorrhagic exudates in the alveoli and bronchi (Kumar *et al.*, 1997). Infiltration of macrophage. (Nakamura *et al.*, 2000). In the heart microscopic showed mononuclear cells infiltration, massive edema and sever vascular changes (Kumar *et al.*, 1997), the kidney showed swelling of the tubular epithelium, increase in the glomerular area hemorrhage and necrosis in the parenchyma (Abdul-Aziz and Hasan, 1995). Catarrhal infiltration of the mucosa of gastrointestinal tract specially in villi of intestine (Kumar *et al.*, 1997), necrosis and atrophy of follicles and cyst formation in bursa of fabricius, and thymus. necrosis of spleen cells (Ganesh *et al.*, 2002), Pancreatic necrosis of acinar cells (Nakamura *et al.*, 2000).

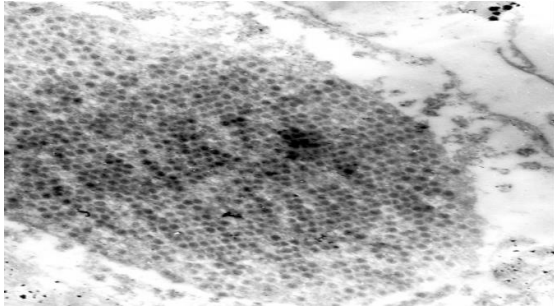


Picture3: A. liver section showing congestion of blood vessels, necrosis, and fatty changes of hepatic cells mononuclear cells infiltration; B the same section of the liver under high power the section showed large basophilic intranuclear inclusion body in a necrotic hepatic cell (arrow); C. the section of spleen showing congestion of blood vessels, hemorrhage in the parenchyma and degeneration of lymphocytes (arrow); D. kidney section showing interstitial hemorrhages, degeneration, necrosis of renal tubular cells (arrow) (Palanivelu *et al.*, 2014).

DIAGNOSIS:

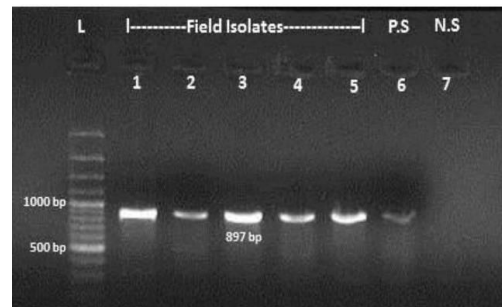
Before birds dying the diagnosis is difficult because there are no specific clinical signs and hardly in spontaneous out breaks (Kumar *et al.*, 1997; Ganesh *et al.*, 2001a). But it can be done in case of HPS-IBH according to gross lesions, histopathology represented by the intranuclear inclusion bodies in the cells of liver (Chandra *et al.*, 1997; Kumar *et al.*, 1997). the virus particles can be detected in the hepatic cells by using transmission electron microscope (Kataria *et al.*, 1997; Jadhao *et al.*, 1997). Cell

culture or inoculation in egg embryo can be used for isolation of the virus we can use the specimens from feces cecal tonsil, kidney, liver and heart for isolation (Kataria *et al.*,1997). For confirmation we can use neutralization test by using serotype- specific sera (Hassan *et al.*,1993). Other tests can be used for diagnosis such as indirect hemagglutination test, fluorescent antibody technique (Deepak,1998).and virus modifications of ELISA (Balamurugan *et al.*,1999; Ganesh *et al.*,2002). PCR has also been developed for the diagnosis of HPS. Other confirmation of a virus by using electron microscope and immunocytochemistry to detect the infected cells with virus (Dahiya *et al.*,2002, Ganesh *et al.*,2002).



Picture 4: virus particles are found in hepatocyte

by using transmission electron microscope (x44000)
(Jensen and Villegas,2005).



picture 5: PCR test appears 897 bp

hexon gene particle
(Palanivelu *et al.*,2014)

PREVENTION AND CONTROL

Biosecurity one of the important aspects for prevention and controlling the disease (HPS). One of them by using of disinfection of equipment's prevent the movement of the visitors inside the farm, proper lighting in the houses and proper ventilation (38,46). Another important aspect of prevention and control is the using of vaccination programs with killed vaccine which prepared from suspension of liver affected cells or FAdV-4 killed oil emulsion vaccine. produce high level of protection. breeders' vaccination for 1-3 times between 9-12 weeks of age by alive vaccine consist of CAV and FAdV-4 induced high level of protection (Mashkoor *et al.*, 1994; Kumar *et al.*, 1997). While, a single dose of vaccine at 15-18 days of age (Anjum, 1990; Kumar *et al.* ,1997). more effective for prevent the re infection at 35-40 days of age (Ahmad *et al.*,1990; Odisho *et al.*, 1996).

CONCLUSION

We concluded that adeno virus infection in chickens causing a sever decrease in meat production due to high mortality resulting in poultry industry economic losses. so, biosecurity and vaccination are essential for prevent the infection, and avoided economic losses

ACKNOWLEDGMENT

The Authors are very grateful to the College of Veterinary Medicine, University of Mosul for their provided facilities which helped to improve the quality of this work.

CONFLICT OF INTEREST

None of the authors has a financial or personal relationship with other people or organizations that could inappropriately influence or bias the content of the paper.

متلازمة موه التامور والتهاب الكبد في الدواجن

زهراء عادل النعيمي
ايمن عبدالله علي الحيايلى
فرع الأمراض وأمراض الدواجن، كلية الطب البيطري، جامعة الموصل، الموصل، العراق

الخلاصة:

متلازمة موه القلب والتهاب الكبد هي اصابة حادة لفروج اللحم تتميز بهلاكات عالية وتجمع للسوائل حول القلب مع تنخر لخلايا الكبد. في عام 1987 تم عزل الفيروس في مدينة انكارا القريبة من كراچي في باكستان, اذ تم تسمية المرض باسم هذه المدينة, كما تم تسجيله في الصين عام 2015 في افراخ اللحم بعمر 3-6 اسابيع, إذ يؤدي الى موت مفاجئ مع نسبة هلاكات عالية تصل الى اكثر من 75% , ما تم تسجيل المرض لأول مرة في العراق في العام 1991 في مدينة الموصل. اكتشفت الأنواع المصلية 2 و3 و5 في العام 1995 من قبل الدكتور مزاحم العطار وجماعته. صنف الفيروس الغداني الى ثلاثة اجناس وهي: فيروس أتا الغداني و سيا الغداني والطييري الغداني كما صنف الجنس الاخير الى خمسة فصائل من ا-ه وهي: تحت المجموعة 1 عترة 4 تسبب متلازمة موه القلب والتهاب الكبد, تحت المجموعة 2 تسبب التهاب الامعاء النزفي والطحال المرمرى, تحت المجموعة الثالثة تسبب متلازمة انخفاض البيض كما ان العترة د و ه تسبب التهاب الكبد الاشمالي بينما العترة ا تسبب التهاب القصبات في السمان كما ادت الاندلاعات الوبائية الى حدوث خسائر اقتصادية في صناعة الدواجن , إذ يلعب كل من الانتقال العمودي والافقي دورا مهما في انتقال العدوى وانتشار المرض. يبدو المظهر العياني للمرض بهشاشة الكبد مع تضخم وشحوب كما تظهر الكلى تورما مع نزف ومناطق نخرية شاحبة كما يظهر تجمع سوائل شفافة او جلاتينية في شغاف القلب. اما الفحص النسجي يظهر وجود التهاب في كل من الكبد والكلى مع وجود اجسام اشتمالية نواتية قاعدية كبيرة الحجم . يمكن تشخيص المرض باستخدام عدة اختبارات منها تفاعل البوليمرايز المتسلسل,المتنر المناعي,اختبار التعادل نستج من ذلك ان للمرض اهمية اقتصادية مهمة لما يسببه من هلاكات عالية تتسبب في خسائر في انتاج لحم الدجاج لذلك يعد الامن الحيوي والتلقيح من اهم الوسائل للسيطرة على المرض ومنعه.

الكلمات الدالة: فيروس الادينو,التهاب الكبد, دجاج, اجسام اشتمالية ,موه القلب.

تاريخ تسلم البحث: 2022/2/ 6، وقبوله: 2022/3/16

REFERENCES

Abdul-Aziz, T. A., & Al-Attar, M. A. (1991). New syndrome in Iraqi chicks. *Veterinary Record*, (12).272 :129 وDOI: 10.1136/vr.128.25.591

- Afzal, M., Muneer, R., & Stein, G. (1991). Studies on the aetiology of hydropericardium syndrome (Angara disease) in broilers. *The Veterinary Record*, 128(25), 591-593.
- A Jassim, F., Y Al-Attar, M., & A Danial, F. (2005). Comparative study of hydropericardium hepatitis syndrome vaccine in poultry. *Iraqi Journal of Veterinary Sciences*, 19(2), 135-141.
- Ahmad, I., Malik, M. I., Iqbal, K., Ahmed, K., & Naz, S. (1990). Efficacy of formalinized liver-organ-vaccine against Angara disease in broilers. *Veterinarski Arhiv*, 60(3), 131-138.
- Akhtar, S. (1992). Studies on the rate of lateral spread of hydropericardium syndrome agent (s). *Etiology, pathogenesis and control of hydropericardium syndrome in poultry. Board on Science and Technology for International Development (BOSTID), Washington, DC.(1)*,248-254 [https://doi.org/1135\(00\)00288-1](https://doi.org/1135(00)00288-1)
- Akhtar, S. (1995). Lateral spread of the aetiologic agent (s) of hydropericardium syndrome in broiler chickens. *The Veterinary Record*, 136(5), 118-120. DOI: 10.1136/vr.136.5.118
- Aliev, A. S., Djavadov, E. D., & Nikitina, N. V. (1997, August). Etiology of hydropericarditis in broiler chicks. In *Proceedings of the Tenth International Conference of the World Veterinary Poultry Association, Budapest, Hungary (1)*,257-260 <https://doi.org/13.384>
- Anjum, A. D. (1990). Experimental transmission of hydropericardium syndrome and protection against it in commercial broiler chickens. *Avian Pathology*, 19(4), 655-660. <https://doi.org/10.1080/03079459008418721>
- Anjum, A. D., Sabri, M. A., & Iqbal, Z. (1989). Hydropericarditis syndrome in broiler chickens in Pakistan. *The Veterinary Record*, 124(10), 247-248.
- Asrani R. K., Gupta B. K., Sharma S. K., Singh S.P. and Katoch R. C. (1997) Hydropericardium hepatopathy syndrome in Asian poultry. *Vet. Rec.*, (141): 271–273.
- Asthana, M., Chandra, R., & Kumar, R. (2013). Hydropericardium syndrome: current state and future developments. *Archives of virology*, 158(5), 921-931.
- Balamurugan, V., & Kataria, J. M. (2004). The hydropericardium syndrome in poultry—a current scenario. *Veterinary research communications*, 28(2), 127-148.
- Balamurugan, V., Kataria, J. M., Verma, K. C., Tiwari, A. K., & Nanthakumar, T. (1999). Detection of Fowl Adenovirus Group 1 Antigens in chicken by Dot-ELISA. *Indian Journal of Comparative Microbiology Immunology and Infectious Diseases*, (20), 11-13.
- Benkő, M.B., Harrach W.C., Russell B.M., Adair É., Ádám J.C., DeJong M., Hess M., Johnson A., Kajon A.H., Kidd H.D., Lehmkuhl Q.G. Li., Mautner V.P., Pring-Akerblomand G.and Wadell. (2005). Family Adenoviridae. In: *Virus Taxonomy. Classification and Nomenclature of Viruses. The 8th Report of the International Committee on Taxonomy of Viruses.* (Fauquet CM, Mayo MA, J Maniloff, U Desselberger, LA Ball;eds.). *Els/Aca. Pre. London*,(1), 213-228.
- Chandra, R., Shukla, S. K., Kumar, M., & Garg, S. K. (1997). Electron microscopic demonstration of an adenovirus in the hepatocytes of birds experimentally

- infected with hydropericardium syndrome. *The Veterinary Record*, 140(3), 70-71.
- Cowen, S. (1992). Inclusion body hepatitis-anemia and hydropericardium syndrome; etiology and control. *World's Poultry Science Journal*, 48: 247–253 DOI: 10.1136/vr.140.3.70-b
- Dahiya, S., Srivastava, R. N., Hess, M., & Gulati, B. R. (2002). Fowl adenovirus serotype 4 associated with outbreaks of infectious hydropericardium in Haryana, India. *Avian Diseases*, 46(1), 230-233.
<https://doi.org/10.1637/0005-2086>
- Deepak, J. N. (1998). *Studies on pathogenicity and immunosuppressive effects of fowl adenovirus serotype-4 isolated from hydropericardium syndrome in chicken* (Doctoral dissertation, IVRI). (2), 324-327.
[https://doi.org/10.1016/F0378-1134\(00\)00287-2](https://doi.org/10.1016/F0378-1134(00)00287-2)
- Domanska-Blicharz, K., Tomczyk, G., Smietanka, K., Kozaczynski, W., & Minta, Z. (2011). Molecular characterization of fowl adenoviruses isolated from chickens with gizzard erosions. *Poultry Science*, 90(5), 983-989.
<https://doi.org/10.3382/ps.2010-01214>
- Gallina, A. M., Winterfield, R. W., & Fadly, A. M. (1973). Adenovirus infection and disease. II. Histopathology of natural and experimental disease. *Avian Diseases*, (17), 343-353. <https://doi.org/10.2307/1589218>
- Ganesh, K., Raghavan, R., Gowda, R. N. S., Satyanarayana, M. L., & Suryanarayana, V. V. S. (2002). Purification and characterization of the aetiological agent of hydropericardium hepatitis syndrome from infected liver tissues of broiler chickens. *Tropical animal health and production*, 34(1), 7-17. DOI: 10.1023/a:1013777509538.
- Ganesh, K., Raghavan, R., Gowda, R. N. S., Satyanarayana, M. L., & Suryanarayana, V. V. S. (2002). Purification and characterization of the aetiological agent of hydropericardium hepatitis syndrome from infected liver tissues of broiler chickens. *Tropical animal health and production*, 34(1), 7-17.
- Ganesh, K., Suryanarayana, V., Raghavan, R., & Gowda, S. (2001). Nucleotide sequence of L1 and part of P1 of hexon gene of fowl adenovirus associated with hydropericardium hepatitis syndrome differs with the corresponding region of other fowl adenoviruses. *Veterinary Microbiology*, 78(1), 1-11. [https://doi.org/10.1016/S0378-1135\(00\)00288-1](https://doi.org/10.1016/S0378-1135(00)00288-1)
- Gowda, R. S., & Satyanarayana, M. L. (1994). Hydropericardium syndrome in poultry. *Indian Journal of Veterinary Pathology*, 18(2), 159-161.
<https://doi.org/10.1186/s12917-018-1733-4>.
- Gowthaman, V., Singh, S. D., Dhama, K., Barathidasan, R., Kumar, M. A., Desingu, P. A., ... & Ramakrishnan, M. A. (2012). Fowl adenovirus (FAdV) in India: evidence for emerging role as primary respiratory pathogen in chickens. *Pakistan Journal of Biological Sciences: PJBS*, 15(18), 900-903. DOI: 10.3923.
- Hafez, H. M. (2011). Avian adenoviruses infections with special attention to inclusion body hepatitis/hydropericardium syndrome and egg drop syndrome. *31*: 85–92 DOI: 10.1136/vr.129.12.272.

- Jadhao, S. J., Kataria, J. M., Verma, K. C., & Sah, R. L. (1997). Serotyping of Indian isolates of fowl adenovirus recovered from inclusion body hepatitis-hydropericardium syndrome (Litchi disease) in chickens. *Indian Journal of Comparative Microbiology, Immunology and Infectious Diseases*, 18(1), 33-37. <https://www.cabdirect.org/cabdirect/abstract/19972218448>
- Jaffery, M. S. (1988). A treatise on Angara disease (hydropericardium-pulmonary oedema-hepatonephritis syndrome). *J Pak Vet Med Assoc*, 34(1), 1-33.
- Jensen, E. L., & Villegas, P. (2005). Inclusion body hepatitis: control in breeder and broiler chickens. *Avia Tech Eric*, (2), 1-6. <https://doi.org/0253-831/2074-7764>
- Kataria, J. M., Verma, K. C., Shah, R. L., & Jadhao, S. J. (1997, November). Experimental studies with fowl adenovirus serotype 4 isolated from cases of IBH-HPS in chicks. In *Proceedings of the 18th Conference of the Indian Association of Veterinary Microbiologists, Immunologists and Specialists in Infectious Diseases, Ludhiana* 69 (2): 69-73.
- Kumar, R., Chandra, R., Shukla, S. K., Agrawal, D. K., & Kumar, M. (1997). Hydropericardium syndrome (HPS) in India: a preliminary study on the causative agent and control of the disease by inactivated autogenous vaccine. *Tropical Animal Health and Production*, 29(3), 158-164. <https://doi.org/10.1007/BF02633014>
- Li, L., Wang, J., Chen, P., Zhang, S., Sun, J., & Yuan, W. (2018). Pathogenicity and molecular characterization of a fowl adenovirus 4 isolated from chicken associated with IBH and HPS in China. *BMC veterinary research*, 14(1), 1-8.
- Lim, T. H., Kim, B. Y., Kim, M. S., Jang, J. H., Lee, D. H., Kwon, Y. K., ... & Song, C. S. (2012). Outbreak of gizzard erosion associated with fowl adenovirus infection in Korea. *Poultry science*, 91(5), 1113-1117. <https://doi.org/10.1186/s12917-018-1733-4>.
- Mashkoo, S., Hameed, A., Ahmad, K., & Qureshi, M. S. (1994). Immune response of Angara disease (hydropericardium syndrome) vaccines in broilers. *Veterinarski Arhiv*, (64), 103-107.
- Memon, Z. N., Gachal, G. S., Yusuf, M., & Arian, M. A. (2006). Incidence of hydropericardium syndrome disease in broilers of Hyderabad, Sindh. *Int. J. Poultry Sci*, 5(7), 673-676. <https://doi.org/10.1186/s12917-018-1733-4>
- Naeem, K., Rabbani, M., Hussain, M., & Cheema, A. H. (1995). Development of cell culture vaccine against hydropericardium syndrome in poultry. *Pakistan Veterinary Journal*, 15, 150-150. <https://doi.org/10.10825>.
- Nakamura, K., Mase, M., Yamaguchi, S., & Yuasa, N. (2000). Induction of hydropericardium in one-day-old specific-pathogen-free chicks by adenoviruses from inclusion body hepatitis. *Avian diseases*, (43), 192-196. <https://doi.org/10.2307/1592524>
- Odisho, S. M., AL-Bana A. and Majeed A. K.H. (1996). Hydro pericardium in broiler chickens in Iraq: isolation & identification of the causative virus. *Iraq Journal of Veterinary Medicine*, 19& 20 (1): 130- 142. doi: 10.33899/ijvs.2005.46705
- Palanivelu, M., Singh, S. D., Kumar, M. A., Barathidasan, R., Varghese, B. P., Prabhu, S. N., & Dhama, K. (2014). Investigation of hepatitis-

- hydropericardium syndrome caused by fowl adenovirus (FAdV) infection in broiler chicken flocks in northern parts of India. *Res J Vet Pract*, 2, 58-62.
- Rahul, S., Kataria, J. M., Senthilkumar, N., Dhama, K., Sylvester, S. A., & Uma, R. (2005). Association of fowl adenovirus serotype 12 with hydropericardium syndrome of poultry in India. *Acta virologica*, 49(2), 139-143
<https://doi/europepmc.org/article/med/16047743>
- Senne, D. A., Panigrahy, B., & Morgan, R. L. (1994). Effect of composting poultry carcasses on survival of exotic avian viruses: highly pathogenic avian influenza (HPAI) virus and adenovirus of egg drop syndrome-76. *Avian diseases*, (38), 733-737 <https://doi.org/10.2307/1592108>..
- Shamim, S., Rehmani, S. F., Siddiqi, A., Qureshi, M. A., & Khan, T. A. (2009). Characterization of avian adenovirus type-4 causing hydro-pericardium syndrome in broilers in Karachi, Pakistan *10(1):26-28*.
<https://www.sid.ir/en/journal/ViewPaper.aspx?id=133395>.
- Stewart, P. L. S. P. L., & Burnett, R. M. B. R. M. (1993). Adenovirus structure as revealed by X-ray crystallography, electron microscopy, and difference imaging. *Japanese journal of applied physics*, (12),2589-2599 ..
- Todd, D. (2000). Circoviruses: immunosuppressive threats to avian species: a review. *Avian Pathology*, 29(5), 373-394.
<https://doi.org/10.1080/030794500750047126>
- Toro, H., Gonzalez, O., Escobar, C., Cerda, L., Morales, M. A., & Gonzalez, C. (2001). Vertical induction of the inclusion body hepatitis/hydropericardium syndrome with fowl adenovirus and chicken anemia virus. *Avian diseases*,(45), 215-222.
<https://doi.org/10.2307/1593031>
- Voss, M., Vielitz, E., Hess, M., Prusas, C. H., & Mazaherri, A. (1996, June). Aetiological aspects of hepatitis and HPS caused by pathogenic adenoviruses in different countries. In *Proc Int Symp Adenovirus and Reovirus Infections in Poultry, Rauischholzhausen, Germany* .(1), 75-78.