

CHRONIC COPPER POISONING OF SHEEP AT BASRAH GOVERNORATE, IRAQ

Hussein Ali Naji*, Jihad Abdulameer Ahmed** and Kamal M. Alsaad*

*Department of internal and preventive medicine, College of Veterinary Medicine, University of Basrah, Basrah, Iraq

**Department of pathology and Poultry diseases, College of Veterinary Medicine, University of Basrah, Basrah, Iraq

Keywords: Sheep, gall bladders, copper poisoning.

Corresponding Author: kamalsad58@yahoo.com

ABSTRACT

Chronic copper poisoning had been detected in sheep of Basrah governorate . The study was conducted on (52) local sheep breeds. Forty two (42) local sheep breeds of different ages and of both sexes with the indoor system of feeding at Basrah governorate, Iraq, show different clinical manifestations belong to chronic copper poisoning. Ten clinical healthy local sheep breeds of same ages were considered as controls. Complete clinical examinations have been applied to all animals in the study. Diseased sheep show different clinical manifestations such as complete loss of appetite (90.4%), depression, Weakness and Lethargy (78.5%), Increase abdominal respiration (78.5%), Moreover, Pale and / or icteric mucous membranes were registered in (71.4%) of animals when examining the vaginal mucous membranes, conjunctiva and nictitating membrane. Furthermore, discolored urine of coffee like appearance was detected in (66.6%), salivation (52.3%) and grinding of teeth (28.5%). Furthermore, clinical examinations of diseased animals show a significant increase ($P<0.05$) of respiratory and heart rate. However ruminal contractions and capillary refill time were decreased significantly ($P<0.05$). Evaluation of hemogram of diseased sheep and controls indicated a clear anemia of macrocytic hypochromic type, which occur due to a significant decrease ($P<0.05$) of the total erythrocyte count, hemoglobin concentration and packed cell volume. However, total and differential leukocyte count values were all within normal limit when compared with controls. A significant difference of copper concentration in plasma, liver and kidneys was also indicated.

Cross examinations of dead sheep reveal that the blood of dead animals was more darker than the normal. Moreover, autopsied sheep show clear enlargement of the liver, which appear yellow, fragile and brittle. However, gallbladders was distended and contain a dense, dark bile. Furthermore, the little enlargement has been detected on both kidneys with dark appearance which become a gun like. In addition, The histopathological results of autopsied animals revealed a mild atrophied glomerulus with thickening of glomerular basement membrane. Moreover, there is an accumulation of inflammatory cells near the glomerulus and between renal cortical tubules. Additionally, a cystic like dilation in the renal interstitium was also detected. Furthermore, a coagulative necrosis appeared in some renal tubules, as well to present of hyaline like cast in the kidney. It has been concluded that chronic copper poisoning of sheep was a dangerous type of disease with both high morbidity and mortalities as well as it's considered as an economic loss.

INTRODUCTION

Copper is an important nutrient metallic mineral that needed in a very small amount for all species of farm animals. Since, Is essential for life for different types of animal species, As, most domestic animals have a dietary requirement for copper (1). Moreover, Copper is required for normal physical and chemical processes that occur normally in the body, where, it's necessary for erythrocyte formation and normal iron metabolism, as well as it aid in the production of both hair pigments and skin or the melanin's. Furthermore, copper is essential for the formation of the myelin sheath that supports and protects the nerve structure of the central nervous system (2), On the other hand, copper is also necessary for cross-linking collagen and elastin that is required for normal bone formation. Additionally, copper is assisted in wool production and is involved in the animal's immune response to disease challenges (3).

Copper can also be poisonous if ingested in excessive amount that exceed the animal's requirement. There is a large variation in the amount of copper needed by different species of farm animals. Similarly, there is a massive variation in the susceptibility to copper poisoning among the farm animal species (4).

It had been documented that the sheep is the most susceptible farm animal species to copper poisoning, However, the goats being less susceptible than sheep and cattle being less susceptible than either sheep or goats (5). Poisoning, mostly occur when sheep or even the goats ingest small

amounts of copper over a prolonged time of period. Since, Copper that is ingested is always stored in the animal's liver, and repeated ingestion of small amounts of copper above the animal's requirement may cause accumulation of what finally becomes a toxic amount of copper for the animal (6).

The most important sources of copper that might cause poisoning of animals are, trace mineral supplemented salt that is formulated for cattle or horses, vitamin and mineral supplements intended for horses, cattle, swine, or poultry, complete feeds for swine, horses, poultry, or cattle, Pasture that has been fertilized with swine manure and poultry litter, copper-containing disinfectant foot baths for cattle (1).

The most common type of copper toxicity in sheep is called chronic copper poisoning (when the animal consume a doses of copper below the acutely toxic level) and is indeed the result of a two stage process. The static accumulation of copper in the liver over a time and then, the release of copper from the liver into the bloodstream (7). In fact, toxicity results when stress, such as a sudden change of the weather, disease or transportation of animals causes the liver to release the copper directly into the bloodstream with rapid and severe consequences, where, the breakpoint upon which the liver can no longer keep or hold its copper load is hard to expect (8). Moreover, Christodouloupoulos and Roubies (9) added that normally, copper will absorb from the diet and transported in the blood circulation to the liver for storage. However, excess copper from the diet is stored in the liver and is released into the blood as needed for regular body functions. The circulating copper level tends to remain constant regardless of the amount of excess copper accumulating in the liver. This makes it difficult to ascertain a sheep's copper status.

When animals, especially sheep, affected with copper poisoning they are simply found dead. However, the most obvious post mortem lesions includes jaundice and what call, the gun metal blue kidneys. Furthermore, In the live animals, pale and also icteric mucous membranes, with deep red or brown urine (coffee like), loss of appetite, weakness and recumbency are the common clinical manifestations exhibited by diseased animals (10).

It had been mentioned that, treatment of copper poisoning is very difficult and may be challenged in most toxic cases, Thereby, severely affected animals often die despite treatment. Nevertheless, medications are administered to diseased animals in order to increase the rate of excretion of the toxic copper from the liver. However, administration Oxygen therapy and other

supportive care may also require. On the other hand, feeding of sodium sulfate and ammonium molybdate might help to reduce the rate of absorption of copper from the digestive system (9).

Sheep with signs of chronic copper toxicosis was suspected in Basrah governorate, therefore, clinical and laboratory study was applied for diagnosis.

MATERIALS AND METHODS

Study design and animals :-

The study was conducted on (52) local sheep breeds. Forty two (42) local sheep breeds of different ages and of both sexes with the indoor system of feeding at Basrah governorate, Iraq show different clinical manifestations belong to chronic copper poisoning. Ten clinical healthy local sheep breeds of same ages were considered as controls. Complete clinical examinations have been applied to all animals in the study.

Diseased sheep show signs of complete loss of appetite, depression, increase abdominal respiration, weakness, lethargy, polydipsia. Moreover, discolored urine of coffee like appearance was detected. Pale and / or icteric mucous membranes were registered when examining the vaginal mucous membranes, conjunctiva and nictitating membrane.

Collection of blood samples :-

Ten (10 ml) of blood was collected via jugular vein puncture from each sheep. Complete blood analysis of EDTA blood, was used on an automatic full digital cell counter (Beckman, USA), to evaluate the total erythrocyte count (TRBc), hemoglobin concentration (HB), packed cell volume PCV, and total leukocyte count (TLC). However, differential leukocyte count was done using Giemsa stain blood smears according to Weiss and Wardrop, (11).

Estimation of copper :-

Plasma copper concentration was estimated using Flame atomic absorption spectrophotometer (FAAS) according to the procedure mention by, Xueping and Reny, 2002, (12). As, the sample was digested by adding 2 ml of concentrated nitric acid (HNO_3) and 1 ml of concentrated Perchloric acid (HClO_4) to 0.5 ml serum in Pyrex tube. Heated for 1 hour at 160 °C using oil bath, then samples cooled and the volumes were completed to 10 ml of 0.3 N HCl. The

absorbance of copper in standards and sample solutions were measured by flame atomic absorption spectrophotometer at wavelength 324 nm .

Moreover, evaluation of copper in tissues was done according to method of Akinloye *et al* ,2011, (13), Since, 0.5 gm from the liver and kidneys was placed in a 250 ml digestion tube and 3.5 ml of concentrated sulfuric acid was added. The mixture was allowed to stand for 30 min at room temperature, then 3.5 ml of 30% Hydrogen peroxide was added to the digestive tube and then samples were heated by electro-thermal at 200 °C for 45 minutes. After that they were cooled and when the solution became clear, they were filtered twice through Whatman No. 42 filter paper and transferred to a 25 ml volumetric flask and adding distilled water to the volume.

Histopathological examination:-

Four sheep were dead after sampling, Thereby, tissue samples for histopathological examination are taken from most of body tissues from autopsied sheep, Fixed at 10% buffered formalin solution for 72 hrs, then trimmed to apposite and suitable sizes and washed, dehydrated and cleared in xylol. In addition, the tissue samples were embedded in paraffin wax, after that it sectioned at 4-5 μ thickness, stained with hematoxyline and eosin, and examined under a light microscope (14).

Statistical analysis :-

Evaluation of statistics was done according to Leech, *et al* (15), using SPSS programs, the student t- test.

RESULTS

Diseased sheep show different clinical manifestations (Table 1) such as, complete loss of appetite (90.4%), depression, weakness and lethargy (78.5%), increase abdominal respiration (78.5%). Moreover, pale and / or icteric mucous membranes were registered in (71.4%) of animals when examining the vaginal mucous membranes, conjunctiva and nictitating membrane. Furthermore, discolored urine of coffee like appearance was detected in (66.6%), salivation (52.3%) and grinding of teeth (28.5%).

Table 1: Clinical manifestations of diseased sheep with chronic copper poisoning

Clinical manifestation	No.of diseased sheep	%
Complete loss of appetite	38	90.4
Depression, Weakness and Lethargy	33	78.5
Increase abdominal respiration	33	78.5
Pale and /or icteric mucus membranes	30	71.4
Discolored urine of coffee like appearance was detected	28	66.6
Salivation	22	52.3
Grinding of teeth	12	28.5

Moreover, clinical examinations of diseased animals show a significant increase ($P<0.05$) of respiratory and heart rate compared to control. However, ruminal contractions and capillary refill time were decreased significantly ($P<0.05$) in the diseased sheep when compared to control. Table 2.

Table 2 : Clinical parameters of diseased sheep with chronic copper poisoning and controls

Parameters	Control n= 10	Diseased sheep n= 42
Body temperature C	39.45 \pm 1.26	39.23 \pm 1.22
Respiratory rate / mint	24.38 \pm 7.53	88.32 \pm 9.56*
Heart rate / mint	87.3 \pm 8.4	132.54 \pm 6.42*
Ruminal contractions/ 5 mint	3.2 \pm 1.44	1.26 \pm 1.33*
Capillary refill time / Sec	1.1 \pm 0.41	5.33 \pm 2.56*

Values are mean \pm standard error of mean. * ($P<0.05$).

Evaluation of hemogram of diseased sheep and controls indicated a clear macrocytic hypochromic anemia, which occur due to a significant decrease ($P<0.05$) of the total erythrocyte count, hemoglobin concentration and packed cell volume. However, total and differential leukocyte count values were all within normal limit in comparison with controls. Table 3

Table 3 : Hemogram of diseased sheep with chronic copper poisoning and controls

Parameters	Control n=10	Diseased sheep n=42
TRBc x10 ⁶	8.11± 1.76	5.56 ± 1.89 *
Hb g/dl	10.3 ± 1.73	6.51 ± 1.69 *
PCV %	30.12± 5.22	23.33 ± 3.71 *
MCV fl	37.13 ± 2.58	41.96±3.22 *
MCHC	34.19 ± 4.24	27.9 ± 4.38*
TLC x10 ³	9.858 ± 2.45	9.504 ± 4.23
Nutrophils %	4122±777.38	4174.35 ± 423.21
Lymphocytes %	5320 ± 521.11	5421.3± 215.12
Eosinophiles %	170 ± 56.23	173 ± 62.92
Monocytes %	211± 84.21	201.75± 122.47
Basophiles %	35 ± 7.33	36.67± 17.32

Values are mean ± standard error of mean. * (P<0.05).

Furthermore, the results were also indicated that diseased sheep show a significant difference (P<0.05), of the values of copper concentration in both plasma liver and kidneys, as mentioned in table 4.

Table 4: Copper concentration in serum, Liver and kidneys of diseased sheep with chronic copper poisoning and controls

Parameters	Controls n= 10	Diseased sheep n= 42
Plasma Cu µg/dl	40.8±11.34	167.48±6.89
Liver Cu µmol/kg	2461±20.56	6475±16/78
Kidney Cu µmol/kg	253.11.54±8.12	744.72±8.12

Values are mean ± standard error of mean. ** (P<0.05).

Cross examination of dead sheep reveals that the blood of dead animals was more darker than the normal. Moreover, autopsied sheep show a clear enlargement of the liver, which appear yellow, fragile and brittle. Moreover, the gallbladders was distended and contain a dense, dark bile, furthermore, little enlargement has been detected on both kidneys with dark appearance which become a gun like. Fig 1.



Fig. (1): A gun like appearance kidney of chronic copper poisoning sheep

However, histopathological results of autopsied animals revealed a mild atrophied glomerulus with thickening of glomerular basement membrane. Moreover, there is an accumulation of inflammatory cells near the glomerulus and between renal cortical tubules. In addition to a cystic like dilation in the renal interstitium. Furthermore, a coagulative necrosis appeared in some renal tubules, as well to present as to hyaline like cast in the kidney. Fig. (2) and Fig.(3).

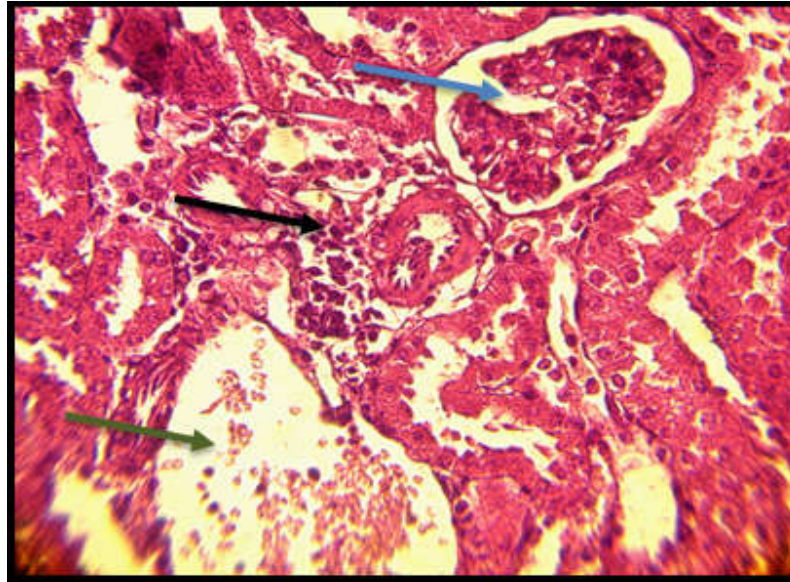


Figure (2): Histopathological section of the kidney in the chronic copper poisoning group showed mild atrophied glomerulus with thickening of glomerular basement membrane (blue arrows), also there is an accumulation of inflammatory cells near the glomerulus and between renal cortical tubules (black arrow), in addition to cystic like dilation in the renal interstitium (green arrow). H&E stain. 10X

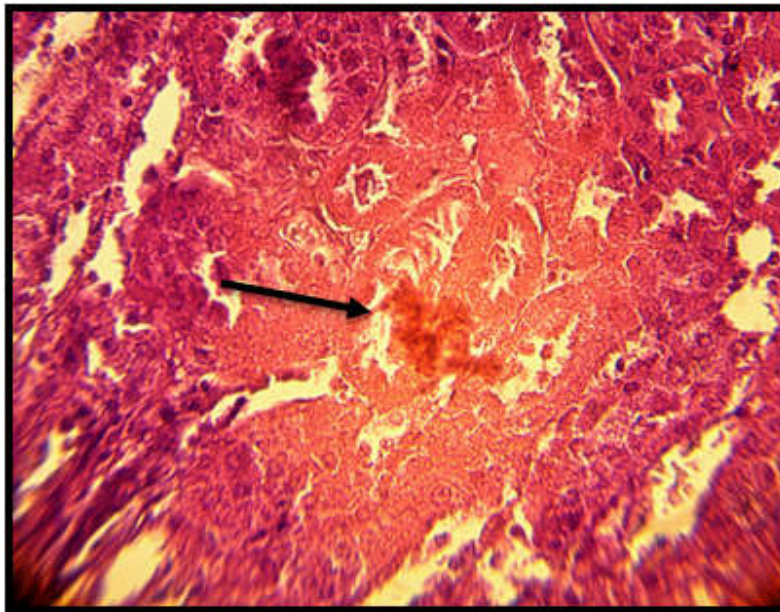


Figure (3): Histopathological section of the kidney in chronic cooper poisoning group showed coagulative necrosis in some renal tubules, as well to present of hyaline like cast (black arrow). H&E stain. 40X.

On the other hand, results of histopathological sections of the liver revealed a multiple petechial hemorrhages in the liver parenchyma with dilation of sinusoids with the vacuolation of some mid-zonal hepatocytes. Fig (4) and Fig. (5).

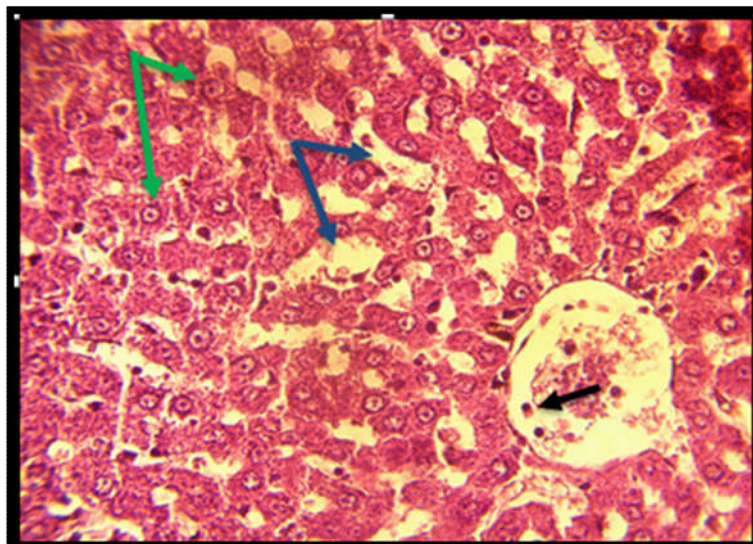


Figure (4): Histopathological section of liver in chronic cooper poisoning group showed active macrophage in the central vein (black arrow), as well to dilation of sinusoids with the vacuolation of some mid-zonal hepatocytes (blue arrows), also there are pyknotic nuclei of hepatocytes (green arrows) . H&E stain. 10X.

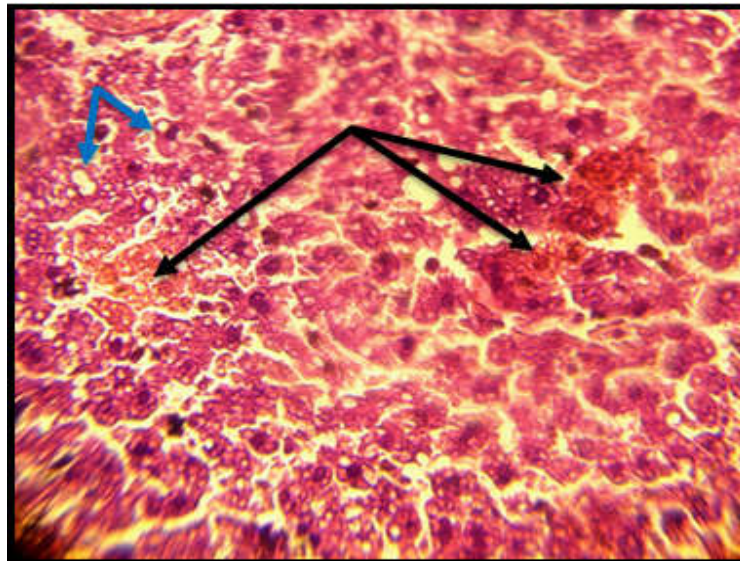


Figure (5): Histopathological section of liver in chronic copper poisoning group showed multiple petechial hemorrhages in the liver parenchyma (black arrows), also there is a cytoplasmic vacuolation (blue arrows). H&E stain. 40X.

DISCUSSION

To our knowledge, this is the first record for chronic copper toxicity at Basrah Governorate, Iraq. Sheep are the most susceptible species to chronic copper toxicity, because their liver cells have a high affinity for copper and they excrete copper into the bile at a very low rate, leading to a build-up of liver copper concentration over time (1,2). Furthermore, Sheep are more susceptible to the effects of copper toxicity than other species of farm animals because their copper excretory mechanism is less efficient (16).

Chronic copper poisoning is essentially a problem of sheep under practical farm conditions, Since, sheep accumulate copper in their livers when fed copper slightly in excess of requirements. Sheep of all ages are affected but a higher incidence is reported in housed than in pastured sheep.(5,17). One of the most common causes of toxicity in sheep is the accidental feeding of foodstuffs intended for other livestock (18). It had been documented that Molybdenum will reduce the accumulation of copper in the liver, Thereby, the ratio of copper to molybdenum in the feed is, therefore, an important factor determining the risk of copper poisoning (4, 19). On the other hand, It had been shown that sheep could be protected from chronic copper poisoning by increasing the crude protein intake, As, high protein might not be

the only factor in decreasing copper storage, Since, the supplemental protein, contained high molybdenum levels which could affect the metabolism and retention of copper (20).

Chronic copper toxicity were described in sheep grazing on pasture and the conditions classified according to their primary effect on sheep, as, phytogetic chronic copper poisoning occurred when sheep consumed forages with an imbalance of copper and molybdenum, This type of poisoning was related to lush growth of specific plants growing at early autumn, These plants contained little or no molybdenum and sheep grazing on them stored high levels of copper in the liver which predisposed them to the hemolytic crisis of chronic copper poisoning(2,7,19).

Diseased sheep show different clinical manifestations which will mentioned by others (6,9,10). There are two recognizable phases in chronic copper poisoning, an asymptomatic phase when copper is accumulating in the liver and a toxic phase of an acute hemolytic crisis. Kumaratilake, 2014(1) and and Villar *et al* , 2002 (2), recorded a loss of appetite, fatigue and difficulty breathing at the onset of hemolytic crisis. Extensive hemolysis resulted in the presence of free hemoglobin in plasma and urine.

Results of hematological parameters indicated a clear anemia of diseased sheep which manifested with macrocytic hypochromic cells of diseased sheep compared with controls, the same results were also indicated by (21,22), Since anemia and weakness are the most common clinical signs, As it were documented that, In copper toxicosis, the concentration of copper increased suddenly, causing lipid peroxidation and intravascular hemolysis. A hemolytic crisis may be promoted by many factors including transportation, pregnancy, lactation, strenuous exercise, or a deteriorating plane of nutrition. (6,7).

Methemoglobinemia occurs and may be the cause of the chocolate brown color of the blood and mucous membranes at the start of hemolysis. The mucous membranes become jaundiced, and this is more prominent if the animals survive for over two days. The temperature may or may not be elevated. Death from consumption of a large dose of copper is rapid and preceded by diarrhea, dyspnea and marked weakness(9,21).

Copper is a strong oxidizing agent. It binds to proteins and stored within the hepatocytes (1). As the copper remains stored in the hepatocytes it does not cause any tissue damages, However, copper could be released at the times of stress, including a sudden change of the weather, at the time of shearing and animal transportation. Therefore, chronic copper poisoning could be described as a stress-related disease (2,6). Moreover, when copper enters the blood, it will

fractionated with the red cells, Thereby, elevating erythrocyte copper levels more than 20 times, whereas plasma copper levels only will increased more than 2-3 times, Therefore, it results in oxidative injury to hemoglobin, inducing erythrocytes inclusions such as, Heinz-body formation and converting the hemoglobin to methemoglobin, which cannot bind the oxygen,(that why diseased animals will suffer from increase respiratory rate with increased abdominal respiration as mentioned in the results of the current study). Moreover, The sulfhydryl groups of the erythrocyte membrane also might have an oxidative changes, resulting in significant hemolysis and anemia. Finally, this massive release of hemoglobin can result in hemoglobinuric nephrosis and renal failure.(21,22).

Chronic copper toxicity was related mostly to the ingestion of feeds that have a high copper - molybdenum ratio, Since, any feed which have copper levels more than 25-30 ppm is will strongly consider as a toxic food for sheep. (19). In addition, when copper is ingested in large amounts in the diet, it may accumulate within the liver over a period of a few weeks to more than a year without clinical signs followed by a sudden release of liver copper stores with final result in the state of toxicity, As different factors could alter the copper metabolism and can influence chronic copper toxicosis by enhancing the absorption or retention of the copper (9)

Studies of hepatic histochemistry of copper loaded animals showed sequestration of excess copper in the lysosomes, However, It was observed a diffuse copper distribution in the hepatocyte in early stages whereas in later stages deposits observed near the bile canaliculi and in the Kupffer cells were in lysosomes(2,3).

Degenerative changes of hepatocytes were observed early in the course of copper poisoning , As centrilobular necrosis of the parenchymal cells was an early observation and corresponded to areas of increased acid phosphatase activity and copper deposition (4,8).Moreover, swollen Kupffer cells were also seen early, and they exhibited increased acid phosphatase activity and copper deposition. Massive necrosis in the centrilobular and periportal areas was evident in hemolytic crisis and changes in Kupffer cells were more pronounced. Such massive necrosis may be associated with copper release into the bloodstream. Centrilobular necrosis observed in chronic copper poisoning were also observed in experimental acute copper poisoning without elevated hepatic copper levels (14,18).

REFERENCES

- 1- Kumaratilake, J. S.(2014). Chronic Copper Poisoning in Sheep: Liver Injury. *Trace Elem. Anal.* 3 (1) 1-22.
- 2-Villar, D.I., Carson, T.L.I., Janke, B.H., Pallarés, F.J., Fernández, G. and Kinker, J.A.(2002). Retrospective study of chronic copper poisoning in sheep. *AN. VET. (MURCIA)* 18: 53-60
- 3 Nose, Y., Wood, L. K., Kim, B., Prohaska, J. R., Fry, R. S., Spears, J. W. and Thiele, D. J. (2010). Ctrl an apical copper transporter in mammalian intestinal epithelial cells in vitro that is controlled at the level of protein stability. *Bio. Chem.* 285(42): 32385-32392.
- 4-Ortolani, L.E., Machado, C.H., Sucupira, M.C.A (2003). Assessment of some clinical and laboratory variables for early diagnosis of cumulative copper poisoning in sheep. *Vet Hum Toxicol.* 45:289–293.
- 5-Solaiman, S.G., Moloney, M.A., Qureschi, M.A. (2001). Effect of high copper supplements on performance, health, plasma copper and enzymes in goats. *Small Rumin. Res.* 41:127–139
- 6-Humann-Ziehanke, E., Coenen, M., Ganter, M., Bickhardt, K. (2001). Long-term observation of subclinical chronic copper poisoning in two sheep breeds. *J. Vet. Med. A Physiol. Pathol. Clin. Med.* 48:429–439.
- 7- Oruc, H.H., Cengiz M., Beskaya, A.(2009). Chronic copper toxicosis in sheep following the use of copper sulfate as a fungicide on fruit trees. *J. Vet. Diagn. Invest.* 21:540–543.
- 8- Haywood S., Muller, T., Muller, W., Heinz-Erian, P., Tanner, M.S., Ross, G. (2001). Copper associated liver disease in North Ronaldsay sheep: a possible animal model for non-Wilsonian hepatic copper toxicosis of infancy and childhood. *J. Pathol.* 195: 264-269.
- 9- Christodoulouopoulos, G and Roubies, N.(2007). Diagnosis and treatment of copper poisoning caused by accidental feeding on poultry litter in a sheep flock. *Aust. Vet. J.* 85(11):451-3.
- 10- Mozaffari, A. A., Derakhshanfar, A., Salar amoli, J.(2009). Industrial Copper Intoxication of Iranian Fat-Tailed Sheep in Kerman Province, Iran. *Turk. J. Vet. Anim. Sci.* 33(2): 113-119
- 11- Weiss, D.J and Wardrop, K.J.(2010). *Schalm's Veterinary Hematology*, 6th Ed, Ames, Wiley-182, Blackwell.
- 12- Xueping, J.I. and Reny, J. (2002). Determination of copper and zinc in serum by derivative atomic absorption spectrometry using the microsampling technique. *Analyst.* 127:416-419.
- 13-Akinloye, O., Abbiyesuku, F.M., Oguntibju, O.O. and Truter, E.J. (2011). The impact of blood and seminal plasma zinc and copper concentration on sperm gram and hormonal changes in infertile nigerian men. *Rep. Biol.*, 11(2):83-98.
- 14- Maxie .M.G .(2016). *Pathology of domestic animals Sixth Ed (Vol. 2,3)*. Academic press. Elsevier
- 15-Leech, N.L., Barrett, K.C and Morgan, G.A. (2007). *SPSS for intermediate statistics: use and interpretation*. 1st Ed. Lawrence Erlbaum Asso. USA. 20-51.
- 16-Ortolani, E.L., Antonelli, A.C. and de Souza Sarkis, J.E. (2004). "Acute sheep poisoning from a copper sulfate footbath." *Vet. Hum .Toxicol.* 46 (6): 315-318.
- 17- Burke, J.M, Terrill, T.H, Kallu, R. .(2000). Use of copper oxide wire particles to control gastrointestinal nematodes in goats. *J. Anim. Sci.* 85: 2753–2761.
- 18- Cornish, J., Angelos, J., Puschner, B.(2007). Copper toxicosis in a dairy goat herd. *J. Am. Vet. Med. Assoc.* 231: 586–589.
- 19- Govasmark, E., Steen, A., Bakken, AK. (2005) . Copper, molybdenum and cobalt in herbage and ruminants from organic farms in Norway. *Acta. Agric. Scand. Anim. Sci* 55:21–30.

- 20- Moeller, R.B(2004). Copper *In*: Clinical veterinary toxicology, ed. Smith, KH, pp. 195–197. Mosby, St. Louis, MO.
- 21-Bozynski, C.C., Evans, T.J., Kim, D.Y., Johnson, G.C., Hughes-Hanks, J.M., Mitchell, W.J., Rottinghaus, G.E., Perry, J., Middleton, J.R. (2009). Copper Toxicosis with Hemolysis and Hemoglobinuric Nephrosis in Three Adult Boer Goats. *J Vet Diagn Invest.* 2009 May;21(3):395-400
- 22-Sameh, Y. (2009). Pathologic and clinicopathologic studies on chronic copper toxicosis in a group of milking Ewes. *Egypt. J. Comp. Path. & Clinic. Path.* 22 (1): 1 – 18.