

Oral Exostosis

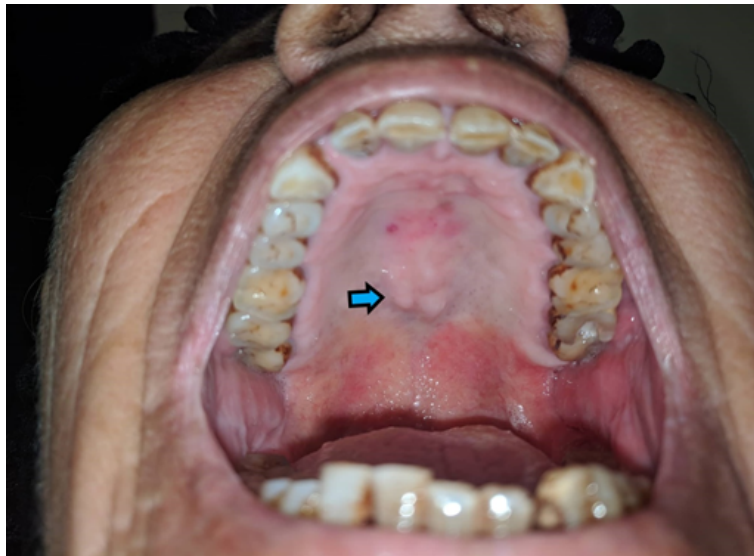
Omar M. Bargas*

*Department of Surgery (Otolaryngology and Head and Neck Surgery),
College of Medicine, University of Anbar, Ramadi, Anbar, Iraq*

(Received : 28 April 2019; Accepted : 12 May 2019; First published online: 15 May 2019)

DOI: [10.33091/amj.2019.170888](https://doi.org/10.33091/amj.2019.170888)

© 2019, Al- Anbar Medical Journal



A 62-year-old heavy smoker woman presented to the outpatient otorhinolaryngology clinic with a two week history of dysphagia. On routine examination, an incidental finding of a 2.5 cm hard mass that seems to be liberated in the midline of the hard palate. The mass is painless and it was noticed for a long time duration, but it doesn't appear to be increasing in size or has a troublesome effect therefore it was neglected. Oral exostosis or torus palatinus is a benign bony outgrowths with a prevalence of around 27 out of 1000 adults, more common in female and in Asian people. The pathogenesis is thought to be genetically inherited. Torus palatinus usually requires no treatment, but surgical excision is required if it is symptomatic or affects the denture in edentulous individual.

* Corresponding author: E-mail: dromaralrawi@yahoo.com
Phone number: +9647803388198